



# Bilateral Microvascular Submandibular Gland Transfer with Implantation of Wharton's Duct in Superior Conjunctival Fornix: A Vision-Saving Procedure for Severe Dry Eye Disease

Mohit Sharma<sup>1</sup> Anil Radhakrishnan<sup>2</sup> Shravan Rai<sup>1</sup> Gopal S. Pillai<sup>2</sup> Deepak Balasubramanian<sup>3</sup>  
 Krishnakumar Thankappan<sup>3</sup> Srilekha Reddy G.<sup>1</sup> Vasundhra Jain<sup>1</sup> Abhinandan Badam<sup>1</sup>  
 Kannisha Shah<sup>2</sup> Amritha V. Rajan<sup>2</sup>

<sup>1</sup>Department of Plastic and Reconstructive Surgery, Amrita Institute of Medical Sciences, Kochi, Kerala, India

<sup>2</sup>Department of Ophthalmology, Amrita Institute of Medical Sciences, Kochi, Kerala, India

<sup>3</sup>Department of Head and Neck Surgery, Amrita Institute of Medical Sciences, Kochi, Kerala, India

Address for correspondence Mohit Sharma, MBBS, MS, MCh, Department of Plastic and Reconstructive Surgery, Amrita Institute of Medical Sciences, Kochi 682024, Kerala, India (e-mail: ammasmohit@gmail.com).

Indian J Plast Surg 2022;55:400–405.

## Abstract

Dry eye can initially cause mild symptoms of irritation and may rapidly progress to corneal scarring and blindness. Tear substitutes can only help for mild cases. With the advancement in microsurgical techniques, an option of transferring vascularized salivary glands has shown positive results. We present a case of a 5-year-old boy with congenital alacrimia with ocular surface damage. Vascularized autologous submandibular gland transfer was considered as a viable option for this patient. We performed the gland transfer in two separate stages for the two eyes (1 year 5 months apart). The patient was evaluated for up to 2 years for the right eye and for 7 months for the left eye. Dry eye workup showed drastic improvement (right > left). Biochemical analysis showed gradual transition to resemble that of natural tears. This procedure can result in significant symptomatic improvement and can be a promising treatment option for cases of severe dry eye.

## Keywords

- ▶ microvascular submandibular gland transfer
- ▶ salivary gland
- ▶ dry eyes
- ▶ keratoconjunctivitis sicca

## Introduction

Dry eye disease is a chronic debilitating problem of multifactorial origin which if left untreated can lead to corneal ulceration and blindness. It affects 7.4 to 33.7% of people depending on various studies and populations being surveyed. Initial phases can be managed well with conservative measures.<sup>1</sup> In advanced cases, surgical options play a more vital role.<sup>2</sup> Submandibular gland secretion is mucino-serous and provides

an ideal replacement of the original tear film. But transferring the submandibular glands needs good microvascular skills; therefore, it should be used as a last resort in severe keratoconjunctivitis sicca cases only,<sup>3</sup> with possible indications such as:

- Schirmer's test <2 mm.
- Corneal ulceration documented by rose bengal staining.
- Tear break up time (T-BUT) <5 seconds.

article published online  
December 22, 2022

DOI <https://doi.org/10.1055/s-0042-1759551>.  
ISSN 0970-0358.

© 2022. Association of Plastic Surgeons of India. All rights reserved. This is an open access article published by Thieme under the terms of the Creative Commons Attribution-NonDerivative-NonCommercial-License, permitting copying and reproduction so long as the original work is given appropriate credit. Contents may not be used for commercial purposes, or adapted, remixed, transformed or built upon. (<https://creativecommons.org/licenses/by-nc-nd/4.0/>)  
 Thieme Medical and Scientific Publishers Pvt. Ltd., A-12, 2nd Floor, Sector 2, Noida-201301 UP, India

## Case Report

A 5-year-old boy was referred to the ophthalmology department with a diagnosis of bilateral membranous conjunctivitis and dry eyes. Ocular examination revealed a visual acuity of 1/60 in both the eyes, not improving with spectacles or pinhole. He was orthotropic with full range of ocular movements and no nystagmus. Ocular examination revealed normal lids with conjunctival xerosis involving bulbar, palpebral, and forniceal conjunctiva in both eyes. Although the fornices were deep with no keratinization, there was evidence of subconjunctival fibrosis in the superior forniceal conjunctiva. Tear meniscus was not visible in either eye. Cornea was lusterless with hypertrophic epithelium and 360 degrees superficial vascularization extending to the central cornea. The other anterior segment details and retina evaluation were grossly within normal limits.

Dry eye work-up showed spontaneous T-BUT of  $<1$  second<sup>4</sup> and confluent punctate corneal erosions, though there was no obvious keratinization. Schirmer's test values under anesthesia were  $<1$  mm in both the eyes after 5 minutes.<sup>5</sup> The National Eye Institute (NEI) score was 12.5/15 for conjunctiva and 15/15 for cornea in both the eyes.<sup>6</sup> A clinical diagnosis of severe ocular surface disease, because of congenital alacrima, was made by the ophthalmologist.

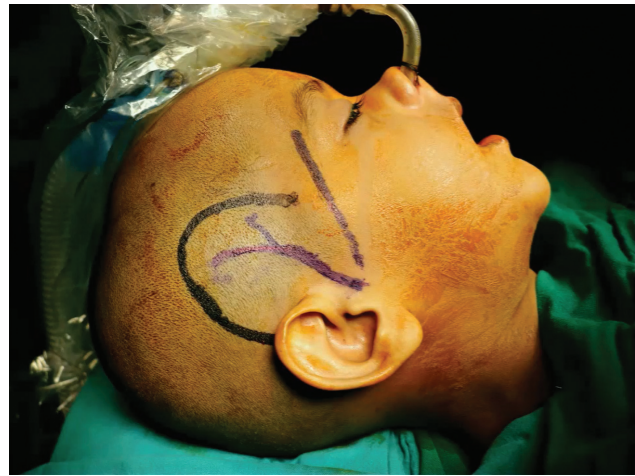Conjunctival biopsy with direct immunofluorescence was done to rule out early-onset childhood cicatricial pemphigoid, which was unremarkable. As there were limited treatment options and rapid deterioration of the ocular surface, he was advised microvascular autologous transplantation of the submandibular gland in both the eyes. A possibility of autoimmune degeneration of salivary glands was to be ruled out, hence a 99 m Tc-pertechnetate scintigraphy was performed, which revealed good dye uptake in submandibular, sublingual, and parotid glands, but no uptake was seen in the lacrimal glands.

Due to the complex nature of the surgery, and to avoid the problems associated with prolonged anesthesia, it was decided that we would perform the surgery for each eye separately. The right side was operated upon first, followed by the left eye. Initially a decision of operating at an interval of 1 month was taken, but the left eye surgery was delayed by 1 year and 5 months because the parents wanted to be sure about the improvement in the right eye before going for the left-eye surgery.

## Surgical Technique

### Recipient Vessel and Bed Preparation

Superficial temporal vessels were located preoperatively using a Doppler and marked. Flap marked and raised superficial to the deep temporal fascia. Superficial temporal vessels were dissected and mobilized. A  $3 \times 3$  cm trough created by excising the central portion of temporalis muscle to accommodate the salivary gland. A subcutaneous tunnel was made up to the upper lateral fornix to create an opening for the duct (**→ Figs. 1 and 2**).



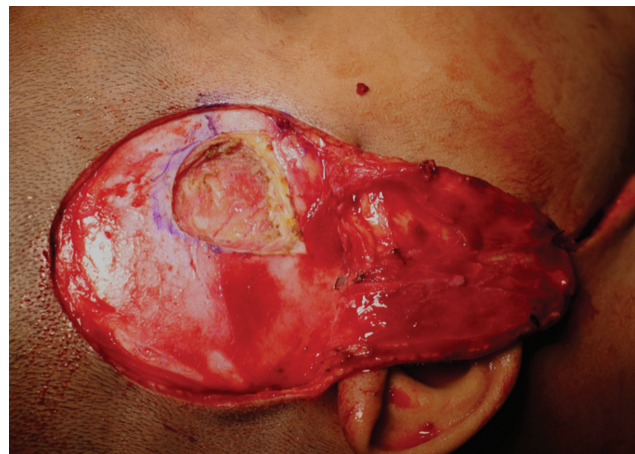**Fig. 1** Preoperative marking.

### Submandibular Gland Harvest

Intraorally the Wharton's duct opening was cannulated, to prevent damage during the dissection. Cervical neck incision was given, and the submandibular gland was identified and dissected. Facial artery and vein were isolated and dissected both proximally and distally. The Wharton's duct was traced up to the floor of the mouth, carefully preserving the lingual nerve. Intraorally the incision was given around the cannulated duct, preserving a cuff of oral mucosa around it. A suction drain was placed and wounds were closed (**→ Fig. 3**).

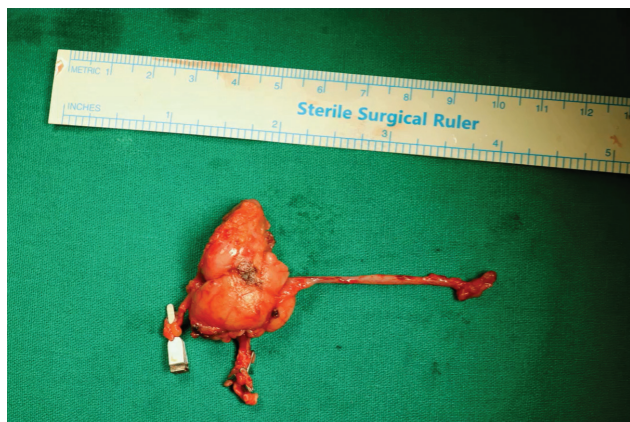### Gland Transfer

Gland was placed and fixed in the trough created by excising a part of the temporalis muscle, this was done to avoid the postoperative bulging. The superficial temporal artery and vein were anastomosed to the facial artery and vein, end to end using 10/0 Nylon sutures. A silk suture was used to engage the Wharton's duct and it was tunneled to the lateral fornix by gently pulling on the suture. Care was taken to avoid twisting of the duct. Duct opening was sutured to the

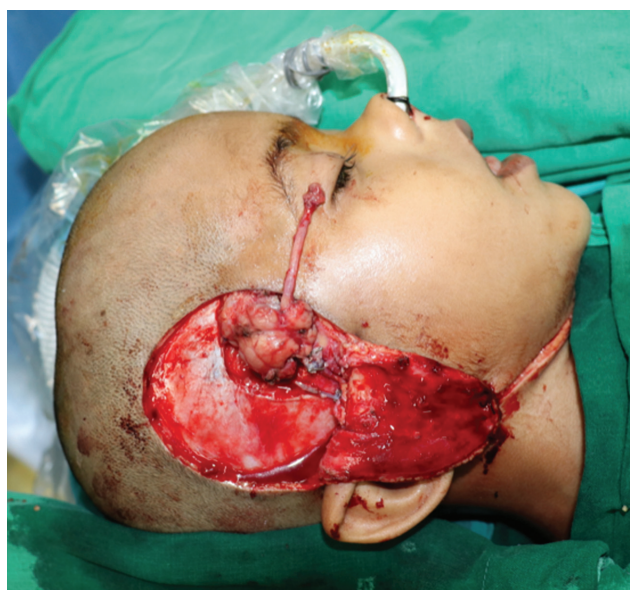


**Fig. 2** Space created in the temporalis muscle for the submandibular gland.





**Fig. 3** Harvested submandibular gland.



**Fig. 4** Gland after microvascular anastomosis.

palpebral conjunctiva using 8-0 nylon interrupted sutures. The duct was cannulated using a silicone tube, to act as a stent for 2 weeks, which was fixed just outside the lateral canthus. The temporal wound was closed in two layers (► **Figs. 4 and 5**).

#### Postoperative Care

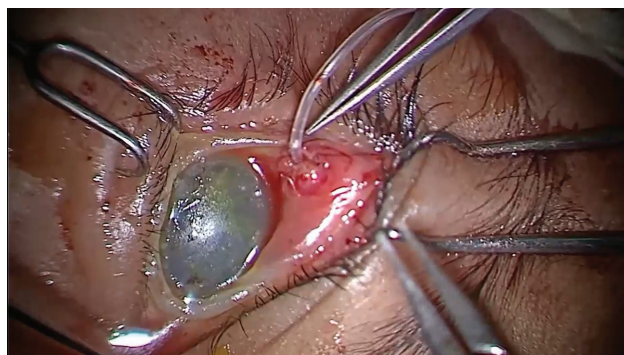
The patient was kept in the intensive care unit for 5 days to allow for close monitoring of the circulation using a Doppler.

Evaluation under anesthesia was done within 2 weeks with the following objectives:

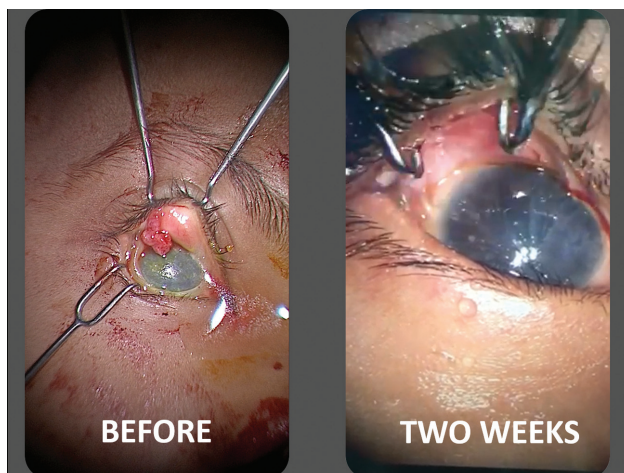
- Remove the silicon tube placed in Wharton's duct.
- Ensure patency of the duct in conjunctival cul de sac.
- Irrigate Wharton's duct and remove any thick mucus plugs.

Tc-Pertechnetate scintigraphy was done to document the gland viability at 3 months.

The same surgical technique was applied for the surgery of the left eye (► **Figs. 6–9**).



**Fig. 5** Salivary duct fixation in superior fornix of right eye.



**Fig. 6** Preoperative and 2 weeks postoperative right eye.

## Results

The immediate postoperative period for both the surgeries was uneventful with no microvascular complications. The stent on each side was retained for a period of 2 weeks. The patient has been followed up for a period of 2 years for the right eye and 7 months for the left eye.

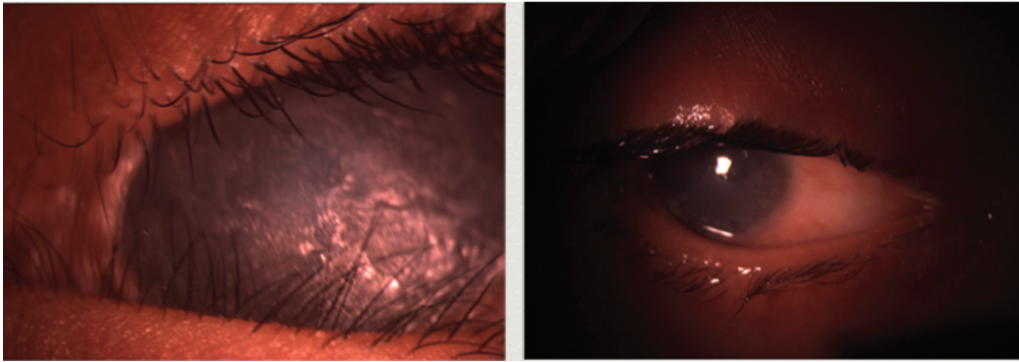
The patient has been objectively assessed as follows.

#### Right Eye

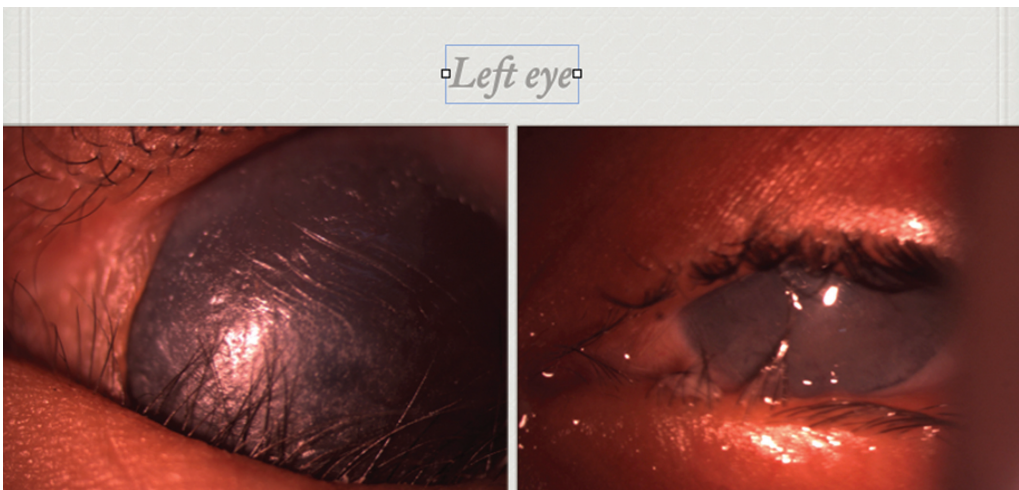
**Visual acuity:** Improved from counting fingers close to face (6/120) to counting fingers at 3 m (3/60). A definite improvement in functional vision was also noted by the parents.

**Gland secretion:** Initial epiphora was present for a few days which subsided, as the gland secretion entered the latent phase. He was prescribed systemic pilocarpine (5 mg thrice daily) to stimulate salivary secretion for the first 3 months. After 2 months the secretion started improving and stabilized, with epiphora occurring only during increased activity.

**Ocular examination findings:** Slit lamp examination showed hypertrophic corneal epithelium with clear stroma and endothelium. Other anterior segment findings and retinal

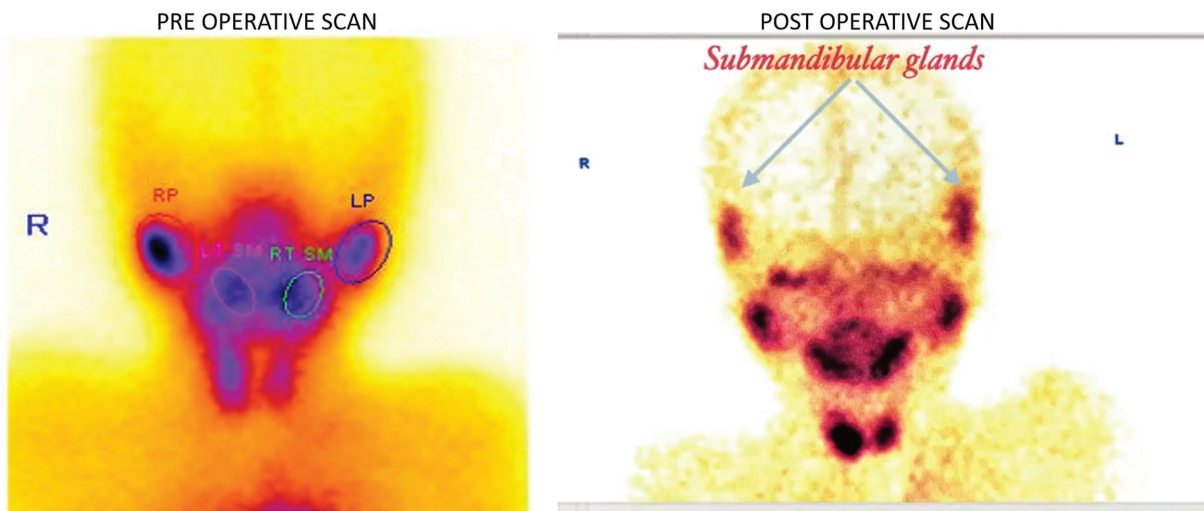


**Fig. 7** Preoperative and 1 year postoperative right eye.



**Fig. 8** Preoperative and 3 months postoperative left eye.

### ***99m Tc Pertecnetate Scintigraphy***



**Fig. 9** Pre- and postoperative Tc-pertechnetate scintigraphy.



**Table 1** Objective analysis

Test	Normal	Preoperative	Right eye postoperative 2 years	Left eye postoperative 7 months
Visual acuity	6/6	Counting fingers at 0.5 m	Counting fingers at 4 m	Counting fingers at 3 m
Tear meniscus height	0.21–0.46 mm	0 mm	1 mm	1 mm
Schirmer's test	>10 mm at 5 min	0 mm at 5 min	>10 mm at 5 min	>10 mm at 5 min
Tear break-up time	>10 s	0 s	4 s	4 s
Corneal epithelial staining	No visible staining	Marked staining	Reduced staining	Reduced staining
National Eye Institute scoring	0/15 (best)	15/15 (worst)	4/15	6.5/15

examination were within normal limits. There was a notable difference in ocular surface. The dry lusterless conjunctiva and cornea was replaced by a moist shiny surface. The tear meniscus height improved from 0 to 1 mm.

Dry eye work-up: T-BUT increased to 4 seconds. Schirmer's values also dramatically improved to >10 mm at 5 minutes. Ocular surface staining also showed remarkable improvement. NEI score was 0/15 for conjunctiva (preoperative 12.5/15) and 7.5/15 for cornea (15/15 preoperatively).

#### Left Eye

There was marked difference between the two eyes. While the right eye showed dramatic improvement, as detailed earlier, in the left eye, conjunctiva revealed xerosis all around with keratinization. There was partial obliteration of fornices with subconjunctival fibrosis. Tear meniscus was not visible. Cornea showed keratinization of the surface with 360 degrees superficial vascularization. The other anterior segment details and retinal examination were very hazy but grossly within normal limits.

In the postoperative period, the eye became moist with a Schirmer's value of >10 mm. Ocular surface improved with some reversal of surface keratinization and reduction in corneal fluorescein staining (► **Table 1**).

Postoperative biochemical analysis of the secretion from the transposed submandibular glands was done from both the eyes separately and it was compared with the normal submandibular gland secretion and normal tear secretion

based on five parameters, namely, sodium, potassium, osmolality, amylase, and secretory immunoglobulin. This suggests that the characteristics of transferred submandibular gland secretions slowly drift toward that of the normal lacrimal secretion. Geerling et al performed a similar analysis in their study, but a comparison with normal tear composition was not performed and the follow-up time was only 1 year (► **Table 2**).<sup>7</sup>

#### Discussion

The treatment for advanced cases of dry eye is challenging. Surgical treatment was initiated with the replacement of tear film secretion with salivary secretion. All three major salivary glands have been used as alternate sources for tear production.

Parotid duct transposition was originally described by Filatov and Chevaljev<sup>8</sup> in 1951. By this method the parotid duct was transposed from its original position to the lower conjunctival fornix. Pierce et al described a modification by which the procedure could be performed completely intra-orally.<sup>9</sup> The problems associated with parotid gland secretion are its excessive in quantity and being more serous; this does not match natural tear secretion.

Sublingual gland transplantation was first described by Murube et al,<sup>10</sup> which involved excision of a block of sublingual gland along with overlying mucosa which was transplanted to the recipient conjunctival bed. As these transfers were nonvascularized, suboptimal results were seen.

**Table 2** Postoperative tear analysis

Test	Normal SMG	Left eye salivary tears at 7 months	Right eye salivary tears at 2 years	Normal lacrimal tears
Sodium, mmol/L	7.26 ± 2.23	18	24	156 ± 20.34
Potassium, mmol/L	12.8 ± 3.63	23	19	18.4 ± 8.93
Osmolality, mOsm/kg	96 ± 24	42	81	303.7 ± 22.9
Amylase, u/L	30,900 ± 20,000	2,289	209	1,854 ± 1,200
S IgA, mg/dL	4.26 ± 3.85	10.7	14.4	26 ± 13

Abbreviation: S IgA, secretory immunoglobulin A.

Murube-Del-Castillo is credited with the first use of microvascular submandibular gland transfer.<sup>11</sup> The use of microvascular submandibular gland transfer for tear replacement is considered to be ideal due to its reliable blood supply, sero-mucinous nature of saliva, and denervation of the gland during harvest, which avoids gustatory reflex salivation.<sup>12</sup>

Zhang et al conducted a long-term study to evaluate the effect of microvascular autologous submandibular gland transfer in 185 patients, which proved that it grants long-term improvement and symptomatic relief in cases of severe dry eye.<sup>13</sup>

Our case is of a 5-year-old boy with severe bilateral dry eye. Vascularized submandibular gland transfers were performed for both eyes. The follow-up period is 2 years for the right eye and 7 months for the left eye. There is significant improvement in visual acuity, and improvement in corneal morphology and function. Slit lamp examination shows improvement and healing of ulcers. Specific tests for dry eye such as T-BUT, Schirmer's test, and NEI scoring also showed significant improvement following submandibular gland transfer.

The presence of amylase does not damage the cornea as it does not have any proteolytic and lipolytic activity against the corneal epithelium. In fact, it has bactericidal activity<sup>14</sup> and secretory immunoglobulin A, which also give immunoprotection against bacteria.

The disadvantages of this procedure are the prolonged operative time and physical activity-related epiphora, which may be controlled by topical application of atropine gel, botulinum toxin injections, or by direct reduction in the size of the gland by partial excision.<sup>15</sup>

## Conclusion

In severe cases of keratoconjunctivitis sicca, this promising technique could be of vital importance in salvaging vision. Even if visual acuity of the patient does not improve further, it gives hope by making the ocular surface moist enough to allow for corneal transplantation. If adopted by more microvascular surgeons, it could open a relatively untapped field of reconstructive surgical endeavor, with the potential to improve the quality of life of a large number of patients.

## Conflict of Interest

None declared.

## References

- Farris RL. Staged therapy for the dry eye. *CLAO J* 1991;17(03):207-215
- Freeman JM. The punctum plug: evaluation of a new treatment for the dry eye. *Trans Sect Ophthalmol Am Acad Ophthalmol Otolaryngol* 1975;79(06):OP874-OP879
- MacLeod AM, Robbins SP. Submandibular gland transfer in the correction of dry eye. *Aust N Z J Ophthalmol* 1992;20(02):99-103
- Khurana AK, Khurana AK, Khurana B. "Disease of lacrimal apparatus". In: Khurana AK, Khurana AK, Khurana B, eds. *Comprehensive Ophthalmology*. 7th ed. New Delhi: Jaypee Brothers Medical Publishers; 2019
- Wright JC, Meger GE. A review of the Schirmer test for tear production. *Arch Ophthalmol* 1962;67(05):564-565
- Chun YS, Yoon WB, Kim KG, Park IK. Objective assessment of corneal staining using digital image analysis. *Invest Ophthalmol Vis Sci* 2014;55(12):7896-7903
- Geerling G, Sieg P, Bastian GO, Laqua H. Transplantation of the autologous submandibular gland for most severe cases of keratoconjunctivitis sicca. *Ophthalmology* 1998;105(02):327-335
- Filatov VP, Chevaljev VE. Surgical treatment of parenchymatous ophthalmic xerosis. *J Ophthalmol (Odessa)* 1951;3:131-137
- Pierce MK, Goldberg JL, Brooks CJ. A direct approach for transposition of the parotid duct. A description of an intra-oral approach to the inferior conjunctival cul-de-sac. *Arch Ophthalmol* 1960;64(04):566-570
- Murube J, Manyari A, ChenZhuo L, Rivas L, Murube I. Labial salivary gland transplantation in severe dry eye. *Oper Techn Oculoplast Orbital Reconstr Surg* 1998;1:104-110
- Murube-del-Castillo J. Transplantation of salivary gland to the lacrimal basin. *Scand J Rheumatol Suppl* 1986;61:264-267
- Sieg P, Geerling G, Kosmehl H, Lauer I, Warnecke K, von Domarus H. Microvascular submandibular gland transfer for severe cases of keratoconjunctivitis sicca. *Plast Reconstr Surg* 2000;106(03):554-560, discussion 561-562
- Zhang L, Su JZ, Cai ZG, et al. Factors influencing the long-term results of autologous microvascular submandibular gland transplantation for severe dry eye disease. *Int J Oral Maxillofac Surg* 2019;48(01):40-47
- Geerling G, Daniels JT, Dart JK, Cree IA, Khaw PT. Toxicity of natural tear substitutes in a fully defined culture model of human corneal epithelial cells. *Invest Ophthalmol Vis Sci* 2001;42(05):948-956
- Keegan DJ, Geerling G, Lee JP, Blake G, Collin JR, Plant GT. Botulinum toxin treatment for hyperlacrimation secondary to aberrant regenerated seventh nerve palsy or salivary gland transplantation. *Br J Ophthalmol* 2002;86(01):43-46