



Imaging Recommendations for Diagnosis, Staging, and Management of Ovarian and Fallopian Tube Cancers

Renganathan Rupa¹ Renganathan Prema¹ Palak Bhavesh Popat² Smita Manchanda³
Kasi Venkatesh⁴ Anuradha Chandramohan⁵ Anbukkani Subbian⁶ Bharath Rangarajan⁷

¹ Department of Diagnostic and Interventional Radiology, Division of Breast and Women's Imaging and Interventions, Kovai Medical Center and Hospitals, Coimbatore, Tamil Nadu, India

² Department of Radiology, Tata Memorial Hospital, Mumbai, Maharashtra, India

³ Department of Radiodiagnosis and Interventional Radiology, All India Institute of Medical Sciences, New Delhi, India

⁴ Department of Diagnostic and Interventional Radiology, Division of Abdominal Imaging and ablative therapies, Kovai Medical Center and Hospitals, Coimbatore, India

⁵ Department of Radiology, Christian Medical College and Hospital, Vellore, Tamil Nadu, India

⁶ Department of Gynecological Oncology, Kovai Medical Center and Hospitals, Coimbatore, Tamil Nadu, India

⁷ Department of Medical Oncology, KMCHIMS, Coimbatore, Tamil Nadu, India

Address for correspondence Renganathan Rupa, DNB, FRCR, Department of Diagnostic and Interventional Radiology, Division of Breast and Women's Imaging and Interventions, Kovai Medical Center and Hospitals, Coimbatore, Tamil Nadu 641014, India (e-mail: drrrupa@gmail.com).

Ind J Med Paediatr Oncol 2023;44:100–109.

Abstract

Ovarian malignancy the third most common gynecological malignancy and is the leading cause of death in women. Non-specific clinical presentation delays the diagnosis, and they often present in the advanced stage of disease. No imaging modality is recommended for screening as there is no significant mortality reduction. Ultrasound (USG) is usually the initial modality in suspected ovarian mass. MRI is recommended for the characterization of indeterminate ovarian or adnexal mass on USG. CT abdomen and pelvis with oral and IV contrast is the recommended imaging modality in staging the disease, predicting the resectability and in selecting the patients who would benefit from neoadjuvant chemotherapy. Early ovarian cancers are staged by post-surgical histology and undergo upfront surgery. Advanced disease benefit by neoadjuvant chemotherapy and less morbidity by interval cytoreduction where image-guided biopsy is performed for histological diagnosis. Follow-up recommendations are based on tumor histology. CT/PET CT is recommended for diagnosing recurrence.

Keywords

- ▶ screening
- ▶ CT
- ▶ staging
- ▶ resectability
- ▶ cytoreduction
- ▶ follow-up
- ▶ PET CT

Introduction

Ovarian cancer is the second most common gynecological cancer worldwide and third most common in developed

countries. About 95% of ovarian malignancies are epithelial origin and the rest arise from other subtypes. The two broad subtypes of epithelial ovarian cancers are type 1 that are low-grade tumors and type 2 that are aggressive tumors and most

DOI <https://doi.org/10.1055/s-0042-1759518>.
ISSN 0971-5851.

© 2023. The Author(s).

This is an open access article published by Thieme under the terms of the Creative Commons Attribution License, permitting unrestricted use, distribution, and reproduction so long as the original work is properly cited. (<https://creativecommons.org/licenses/by/4.0/>)

Thieme Medical and Scientific Publishers Pvt. Ltd., A-12, 2nd Floor, Sector 2, Noida-201301 UP, India

often present in advanced stages.¹ Though ovarian cancers are traditionally staged surgically, up to 40% of patients may be under staged at laparotomy.² The role of the imaging is to characterize the ovarian lesion, determine the extent, predict primary resectability or unresectability, to evaluate the response to chemotherapy and localize the recurrence.³

Risk Factors and Etiopathogenesis

Several theories have been postulated about the origin of ovarian cancers. According to the World Health Organization (WHO), epithelial ovarian cancers are classified into high-grade serous and low-grade serous, mucinous, endometrioid, clear cell carcinomas and malignant Brenner tumor and carcinosarcomas.⁴

High-grade serous carcinomas are postulated to arise from the fimbrial end of the fallopian tube through precursor lesions called STIC (serous tubal intraepithelial carcinoma). Low-grade serous tumors may arise from benign or borderline tumors of the ovary.

Risk factors for ovarian cancer include genetic mutations such as BRCA 1 and 2 and Lynch syndrome, nulliparity, endometriosis, obesity, and smoking.

Protective factors include use of oral contraceptive pills, breastfeeding, tubectomy, and tubal ligation.⁵

Epidemiology in India and Globally

Ovarian cancer currently ranks as the seventh most common cancer in women, worldwide. Often called a “silent killer,” it has high mortality rates due to its insidious onset and lack of specific symptoms. It occurs more commonly in developed countries such as the US and Europe.⁶ However, mortality rates are highest in Asian and African countries with the existing disparities in access to healthcare and affordability. In Asia, the highest ovarian cancer-related mortality rate is seen in India.⁷ Carcinoma ovary is the third most common cancer in Indian women followed by breast and cervix. The cumulative risk of developing ovarian cancer between 0 and 74 years of age is about 1 in 133.⁸

Imaging Referral Guidelines

No imaging is recommended for screening for ovarian carcinoma in the general population as there was no significant reduction in mortality rates due to screening according to ovarian cancer population screening and mortality after long-term follow-up in the UK Collaborative Trial of Ovarian Cancer Screening (UKCTOCS) trial.⁹ Ultrasonogram (USG) with CA-125 levels may be considered for women with hereditary cancer syndromes starting at 30 to 35 years of age if they have not undergone risk-reducing salpingo-oophorectomy.¹⁰

USG is the initial imaging modality of choice in suspected ovarian lesions. If the lesion is suspected to be malignant on USG, staging CT abdomen and pelvis with oral and IV contrast is indicated to evaluate the extent of disease and identify patients who would benefit from neoadjuvant chemothera-

py.^{11,12} If the lesion is indeterminate on USG, MRI is recommended for further evaluation.¹³

FDG- PET-CT is helpful for patients with primary peritoneal carcinomatosis or elevated tumor markers with inconclusive CT findings.¹⁴

Serum CA-125 levels and CT are the standard tools for assessing the response to chemotherapy.¹⁵ FDG-PET-CT is useful in early prediction of response after neoadjuvant chemotherapy due to its functional imaging.¹⁶ In MR imaging, DWI is useful in early prediction of response by an increase in ADC values.¹⁷

Rising CA-125 levels, symptoms and signs of relapse after treatment prompts imaging evaluation for recurrence. CT chest, abdomen, and pelvis is the imaging modality of choice in clinically suspected/known recurrence of disease in carcinoma ovary.¹⁴ PET-CT has similar or higher accuracy compared to CT in detecting recurrences.¹⁸

Clinical and Diagnostic Work-up Excluding Imaging

Women with ovarian malignancies usually have a wide range of symptoms from vague abdominal discomfort, painless abdominal distension, mass per abdomen and bowel or bladder disturbances. Rarer clinical symptoms include acute abdomen secondary to ovarian torsion, bowel obstruction, gastrointestinal bleeds, vaginal bleeds, lymphadenopathy, and paraneoplastic syndromes.

The serum tumor markers remain the easiest and sensitive screening tool, albeit non-specific. Serum levels of cancer antigen 125 (CA 125) show sensitivity of 78% and specificity of 77% for epithelial tumors. Higher sensitivity and specificity are observed in postmenopausal women, advanced stage, and higher grade.^{19,20} The human epididymis protein 4 (HE 4) level may be useful in patients with low/normal CA 125. CEA and CA 19.9 are other markers that can also be elevated.

Specific tumor markers such as inhibin B, alpha-fetoprotein (AFP) and beta human chorionic gonadotropin (beta HCG) lactate dehydrogenase (LDH) are used for diagnosis and follow-up of non-epithelial tumors.

Biopsy of ovarian masses is generally not recommended as rupture and peritoneal seeding can upstage the tumor. In patients with ascites, diagnostic cytology yields vary in 30 to 70%. In women who are not eligible for surgical cytoreduction, image-guided biopsies or laparoscopic biopsy may establish diagnosis.²¹⁻²³

Additional evaluation with upper GI endoscopy and colonoscopy should be considered for all women with clinic-radiological suspicion or elevated serum markers suggestive of gastrointestinal primary.

Irrespective of family history, these patients should be offered genetic testing that has an impact on treatment plan and choice and after treatment care.²⁴ Patients with epithelial carcinoma of the ovary should be offered testing for BRCA1 or BRCA2 mutations and for Lynch syndrome. Patients with mucinous, clear cell, endometrioid cancers are offered testing for DNA mismatch repair deficiency.

Imaging Guidelines

Screening for Ovarian Cancer

Ovarian cancer is the most common cause of cancer deaths due to gynecological malignancies. Because it presents with non-specific symptoms, it is diagnosed in the advanced stage in 58% of patients which results in a low 5-year survival rate (30%). When diagnosed early as a localized disease, the 5-year survival rate is 93%.²⁵ This led to the development of screening tools for ovarian cancer.

The common screening tools considered are transvaginal USG and serum CA-125 levels. Both have the disadvantage of high false-positive rates leading to unnecessary interventions. According to the randomised controlled trials on ovarian cancer screening, there was no significant reduction in mortality rates due to ovarian cancer with screening.^{9,26} Because of the negative net benefit and risk ratio, it is not recommended to screen asymptomatic high risk women.²⁷⁻²⁹

For high risk women, risk-reducing salpingo-oophorectomy (RRSO) is recommended at 35 to 40 years of age and upon completion of child bearing. High-risk women who have not elected RRSO, screening with transvaginal sonography and CA-125 levels, although of uncertain benefit, is recommended at the clinician's discretion starting at the age of 30 to 35 years.⁸

Diagnosis

The initial imaging modality of choice is ultrasonography in a suspected adnexal or ovarian mass (USG).¹⁰ The International Ovarian Tumour Analysis (IOTA) and Ovarian-Adnexal Reporting and Data System (O-RADS) may be used for the characterization and risk stratification of adnexal masses.³⁰ If the lesion is benign, it can be followed up or no further evaluation is recommended.

If the USG findings are indicative of a lesion with high risk of malignancy, evaluation by a gynecologist along with CT of the abdomen and pelvis or CT thorax, abdomen and pelvis is recommended for staging of the disease and treatment planning.¹¹ In patients with indeterminate features, MRI of the abdomen and pelvis is recommended for further characterization.¹¹

In the evaluation of indeterminate adnexal lesions, MRI is a superior modality than USG/CT. MRI has increased specificity compared with the USG, decreasing the number of false-positive diagnoses for malignancy and thereby avoiding unnecessary or over-extensive surgery.³¹

The Ovarian-Adnexal Reporting and Data System (O-RADS) is released by American College of Radiology for USG and MRI.^{30,31} It assigns a probability of malignancy based on the imaging features of an adnexal lesion and provides information to facilitate optimal patient management and a uniform reporting system with standardized lexicons. The primary goal of the O-RADS risk stratification system is to improve communication between radiologists and referring physicians in a reproducible fashion, so that women with benign lesions or borderline tumors can avoid

unnecessary or over-extensive surgery, respectively, and women with potential malignancy are promptly referred for gynecologic oncologic surgical evaluation.

The classical benign adnexal lesions on ultrasound include unilocular cyst < 10 cm with smooth inner walls and also typical dermoid cysts, typical hemorrhagic and endometriosis cysts, hydrosalpinx and paraovarian/peritoneal inclusion cysts. On MRI, typical benign feature is cysts with T2 dark/DWI dark solid components.^{30,31}

High-risk features that indicates malignancy in adnexal masses on ultrasound include unilocular cyst with > 4 papillary projections, multilocular cyst with solid component with color score of 3 to 4, solid lesion with smooth outer contour with color score of 4, solid lesion with irregular outer contour and when the lesion is associated with ascites and/or peritoneal nodules. Solid tissue with high-risk time intensity curve in dynamic post contrast MRI is a high-risk feature.^{30,31}

Indeterminate features of adnexal masses on ultrasound include unilocular cyst > 10 cm in size or with irregular inner walls, multilocular cyst, multilocular cyst with solid component with a color score of 1 to 2. Unilocular cyst with 1 to 3 papillary projections or solid components and solid lesion with smooth outer contour with color score of 1 to 3. High-risk features on MRI include solid components showing low-risk or intermediate-risk time intensity curve on dynamic post contrast images.^{30,31}

Image-Guided Intervention for Diagnosis

In ovarian cancer patients amenable to primary cytoreductive surgery, definitive diagnosis is by surgical histopathology.

Image-guided biopsy is recommended only in patients who are not amenable for primary cytoreductive surgery. Trans-abdominal or trans-vaginal ultrasound-guided biopsy of omental, peritoneal, or adnexal mass can be done to confirm diagnosis and histopathological type of ovarian cancer before starting optimal neoadjuvant chemotherapy. If biopsy is not feasible, ascitic or pleural fluid aspiration, cystoscopy, and CA-125:CEA ratio of > 25 can be used for diagnosis.³ In patients with pleural effusion, nature of effusion must be confirmed with pleural fluid aspiration and cytology.

Staging

Contrast-enhanced CT (CECT) of the abdomen and pelvis or CECT thorax, abdomen and pelvis is the recommended imaging for staging of ovarian cancer. CT plays an important role in the assessment of operability and for identifying lesions in regions that are difficult to resect

CT characterizes the tubo-ovarian lesion and detects the involvement of the adjacent pelvic organs such as infiltration into the uterus, rectum, and sigmoid colon, involvement of the ureter. It also detects the extension of the disease outside the pelvis with involvement of the peritoneum, omentum, mesentery, visceral organs, and lymph nodes (– Fig. 1). The reported accuracy of CT in staging of ovarian cancer is up to 94%.¹⁴

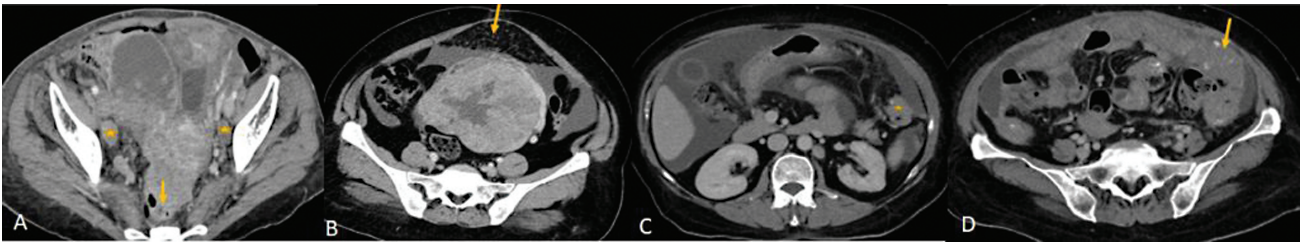


Fig. 1 (A) CECT of a patient with ovarian carcinoma: Lesion with irregular solid tissue in right adnexa and irregular solid lesion in left adnexa with infiltration into the anterior wall of the rectum (yellow arrow) and uterus and necrotic bilateral external iliac lymph-nodes (*). (B-D) Spectrum of omental involvement in advanced ovarian carcinoma along with massive ascites. (B) omental fat stranding and nodularity (yellow arrow), (C) omental deposit (*), (D)- omental caking (arrow).

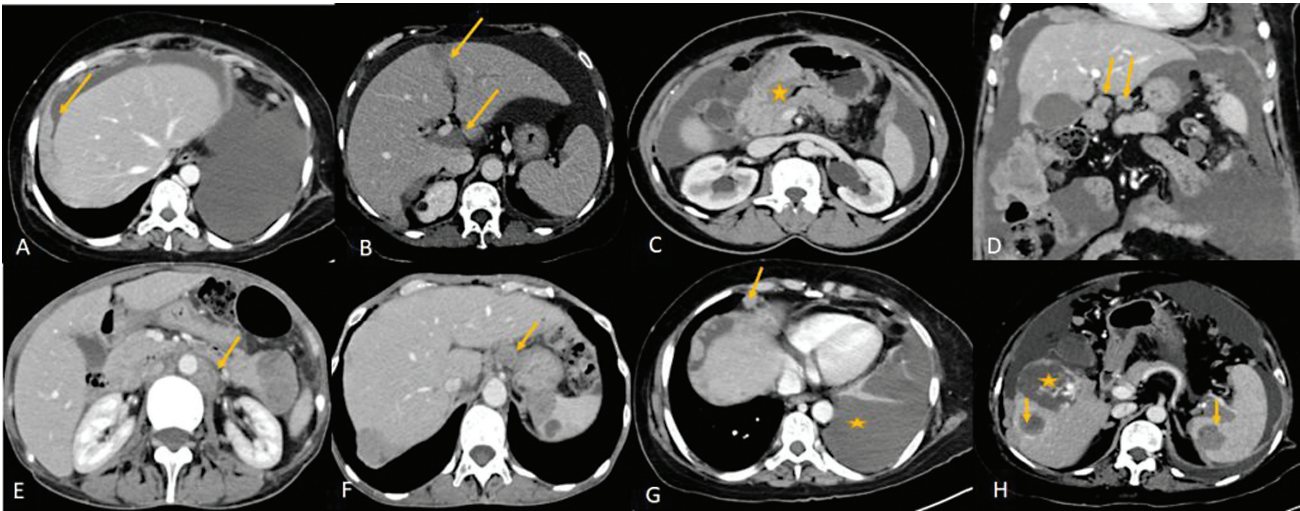


Fig. 2 (A-E) CECT showing some of the unfavorable sites of involvement which makes complete cytoreduction less likely. (A) Plaque like subdiaphragmatic disease (arrow), (B) intersegmental fissures of liver and porta (arrows), (C) Disease encasing the stomach (*), (D) Lesser omentum (arrows), (E) lymph-nodes above the level of renal hilum (arrow). (F-H) Metastatic disease in carcinoma ovary: F: Celiac lymph-node (arrow). (G) Anterior cardiophrenic lymph-node (arrow) and malignant left pleural effusion (*) (H) Liver and splenic intraparenchymal deposits (arrows), * - incidental hemangioma in liver.

Further CT detects the involvement of certain sites such as the mesenteric root, gastrosplenic ligament, lesser sac, porta hepatis, hepatic intersegmental fissures, subdiaphragmatic regions, infiltrating liver, and splenic deposits and also helps in detecting lymphadenopathy at or above the celiac axis, extraperitoneal disease, and pelvic sidewall invasion and thereby predicts non resectability (► Fig. 2).¹⁴ The limitation of the CT is to detect deposits that are less than 5 mm within the peritoneum, bowel surface especially when there is no ascites.³² For deposits that are < 5 mm, the sensitivity of CT is only 11%.³³ Positive oral and rectal contrast improves detection of visceral peritoneal deposits. CT chest can be used in cases of suspected pleural or pulmonary metastasis.

Alternatively, MRI and FDG-PET-CT may be appropriate for staging. MRI has equivalent accuracy to CT in staging of ovarian cancer with sensitivity of 0.88, specificity of 0.74, and accuracy of 0.84.³⁴ However, the limitations are that MRI is more sensitive to motion and has long duration of study compared to CT. FDG PET has a specificity as low as 54% and sensitivity of 86% in diagnosis and treatment of ovarian cancers. PET CT can be false positive in certain benign tumors such as fibroma and dermoid and in non-neoplastic conditions such as hydrosalpinx and endometriosis. However,

various studies demonstrate that when combined with CT, it has a higher accuracy than FDG-PET or CT alone.^{35,36} Others imaging modalities such as non-contrast CT, ultrasound of abdomen and pelvis are not recommended for staging.¹⁴

CT is also recommended to assess response in patients who are undergoing neoadjuvant chemotherapy before interval debulking (► Fig. 3).¹⁴

The 2014 revised FIGO staging classification is used for staging of ovarian, fallopian tube, and peritoneal malignancies.³⁷ In the recent FIGO 2021 staging report, there are no changes in the staging system. FIGO classification along with equivalent stages in the Union of International Cancer Control (UICC) TNM staging is given in ► Table 1.

Follow-up

Except for a few tumors with low malignant potential, patients are seen every 2 to 4 months in the first 2 years, then every 3 to 6 months in the next 3 years, and annually after 5 years. Follow-up is mainly with clinical examination and tumor markers for epithelial tumors. The role of imaging for routine surveillance is unclear due to poor sensitivity of imaging in picking up small volume recurrence and due to no proven positive effect on survival. Thus, imaging is indicated

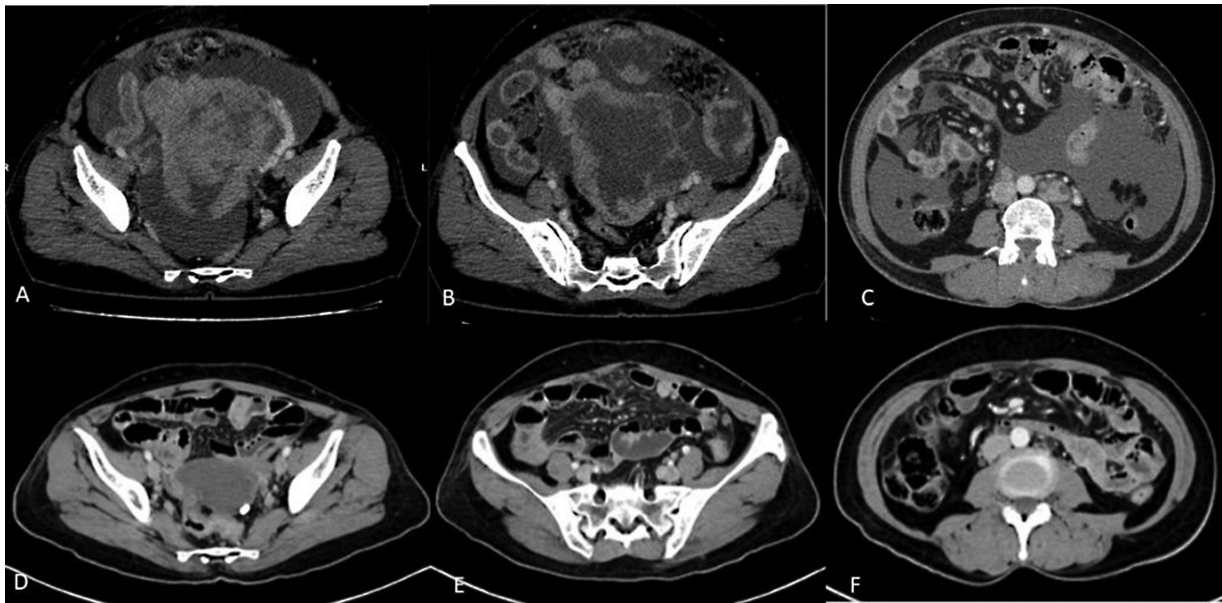


Fig. 3 (A-F) Role of contrast-enhanced CT in assessing the response after neoadjuvant chemotherapy. CECT images before (A-C) and after (D-F) 3 cycles of neoadjuvant chemotherapy show significant reduction in size of the primary mass lesion in the pelvis (A and D) and omental deposits (B and E) and resolution of ascites and retroperitoneal lymph-nodes (C and F).

Table 1 Staging of ovarian cancer (FIGO and UICC TNM staging)

UICC stage	FIGO Stage	Stage description
T1N0M0	I	The tumor is limited to the ovary (or ovaries) or fallopian tube(s).
T1aN0M0	IA	The tumor is limited to one ovary with an intact capsule or one fallopian tube. There is no tumor on the surface of the ovary or fallopian tube. No cancer cells are found in the ascitic fluid or peritoneal washings.
T1bN0M0	IB	The tumor is limited to both ovaries or fallopian tubes but not on their outer surfaces. No cancer cells are found in the ascitic fluid or peritoneal washings.
T1cN0M0	IC	The cancer is in one or both ovaries or fallopian tubes and any of the following are present: IC1: rupture and spillage of tumor during surgery IC2: capsule rupture before surgery or tumor on ovarian or fallopian tube surface IC3: tumor cells in the ascites or peritoneal washings
T2N0M0	II	Involvement of 1 or both ovaries or fallopian tubes with extension to pelvis (below pelvic brim) or primary peritoneal cancer.
T2aN0M0	IIA	Extension/implants on the uterus and/or the fallopian tubes and/ or the ovaries.
T2bN0M0	IIB	Involvement of other intraperitoneal pelvic structures
T1-3N0-1M0	III	Involvement of 1 or both ovaries or fallopian tubes, or peritoneal cancer with spread to the peritoneum outside the pelvis confirmed by cytology or histology and/or metastasis to the retroperitoneal lymph nodes
T1-2N1M0	IIIA1	Positive retroperitoneal lymph nodes (cytologically or histologically proven) IIIA1(i) Metastasis up to 10 mm in greatest dimension IIIA1(ii) Metastasis more than 10 mm in greatest dimension
T3a2N0-1M0	IIIA2	Microscopic involvement of extra pelvic peritoneum with or without positive retroperitoneal lymph nodes
T3bN0-1M0	IIB	Macroscopic deposits in the extra pelvic peritoneum, with largest deposit less than 2 cm in size with or without retroperitoneal lymph nodes
T3cN0-1M0	IIIC	Macroscopic deposits in the extra pelvic peritoneum with largest deposit more than 2 cm in size (includes extension of tumor to capsule of the liver and spleen without parenchymal involvement of either organ)
Any T Any N M1	IVA	Pleural effusion with positive cytology
Any T Any N M1	IVB	Parenchymal metastases to solid organs and metastases to extra-abdominal organs (including inguinal lymph nodes and lymph nodes outside of the abdominal cavity)

Table 2 Follow-up recommendations for various types of ovarian tumors and indications for imaging^{3,38}

Histological type	Follow-up recommendation	Indications for imaging
Epithelial high-grade serous carcinoma of ovary, fallopian tube, and peritoneum	Once in 3 months in first year Once in 4–6 months until 5 years Annually after 5 years	Not routinely indicated. Indicated only if there are 1. symptoms and/or signs of recurrence 2. Rising CA-125 levels 3. when tumor markers or physical exam is unreliable
Low-grade serous cancers	Similar as high-grade tumors but at less frequent intervals	Same as above
Borderline tumors	Similar as high-grade tumors but at less frequent intervals	Same as above + transvaginal sonography if one ovary is preserved
Mucinous tumors	Similar as high-grade serous tumors	Similar as high-grade serous tumors
Granulosa cell tumors	Once in 6–12 months if early stage, low risk Once in 4–6 months if high risk	Reserved for patients with symptoms and signs or elevated biomarkers
Dysgerminoma	Year 1-Every 2–3 months Year 2-Every 3–4 months Year 3-Every 6 months Year 4–5-Every 6 months After 5 years-annually	Year 1-abdominal/pelvic CT (every 3–4 months) Year 2-abdominal/pelvic CT (every 6 months) Year 3-abdominal/pelvic CT (annually) Year 4–5-abdominal/pelvic CT (annually) After 5 years-as clinically indicated
Non-dysgerminoma	Year 1-Every 2 months Year 2-Every 2 months Year 3-Every 4–6 months Year 4–5-Every 6 months After 5 years-annually	Year 1-Chest/abdominal/pelvic CT (every 3–4 months) Year 2-Chest/abdominal/pelvic CT (every 4–6 months) Year 3-Abdominal/pelvic CT (every 6–12 months) Year 4–5-Abdominal/pelvic CT (every 6–12 months) After 5 years-As clinically indicated

only in patients with biochemical recurrence. Imaging is also of benefit also in patients with high clinical suspicion of recurrence but show no elevation of tumor markers.

As of now, use of other imaging modalities for follow-up is unsupported. Refer to ►**Table 2** for follow-up recommendations for tumors with various histological types.

Recurrence

CECT of the thorax, abdomen, and pelvis is the recommended imaging modality of identifying recurrence. The tumor usually recurs as peritoneal implants within the peritoneal

cavity and along the surface of the visceral organs. The sensitivity and specificity of CECT ranges from 58% to 84% and 59% to 100%, respectively.³⁹

MRI was comparable to CT for detecting recurrence > 2 cm. However, for overall detection of recurrence, MRI had significantly lower accuracy than CT/FDG PET/PET CT.⁴⁰ The reported diagnostic accuracy of FDG-PET/CT is similar or more than the CECT in detecting recurrent ovarian tumors (►**Fig. 4**).^{18,41} The sensitivity and specificity of FDG-PET/CT ranges from 95% to 97% and 80% to 100%, respectively.¹⁸ However, these figures are predominantly from high-grade

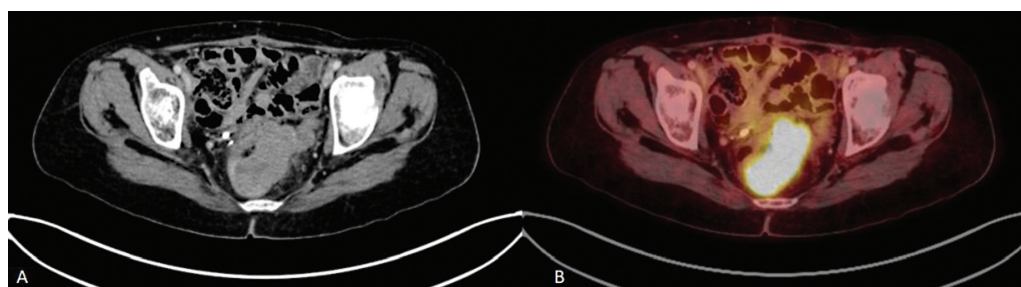


Fig. 4 (A, B) CECT and FDG PET-CT showing recurrence along the wall of the rectum in a patient with carcinoma ovary post neoadjuvant chemotherapy, interval debulking followed by adjuvant chemotherapy with elevated CA-125 levels on follow up.

Table 3 Summary of principles of management of ovarian cancer³

Primary treatment	Early stage (Stages I and II)	Surgery-staging laparotomy	Stage IA and IB of low-grade serous, mucinous, and grade I-endometrioid, stage IA of clear cell histology	Observation observation/chemotherapy
			All high-grade serous, grade 2,3-endometrioid stage IC and above of low-grade serous, mucinous and grade I-endometrioid stage IB and above of clear cell histology	6# adjuvant chemotherapy
	Advanced stage (stages III and IV)	Surgery–primary cytoreduction	6# adjuvant chemotherapy ± targeted therapy	
			3# NACT in select stage IIIC/IV	Surgery–interval cytoreduction
Treatment of relapsed disease	Platinum-refractory/resistant relapse (no response progression during or within 6 months of completion of platinum based chemotherapy)		Single-agent chemotherapy/best supportive care [paclitaxel, gemcitabine, topotecan, pegylated liposomal doxorubicin (PLD)]	
	Platinum-sensitive relapse (progression more than 6 months after completion of previous platinum chemotherapy)		Platinum based combination chemotherapy ± targeted therapy	
	Isolated serological relapse (elevation of CA-125 levels alone)		Can be observed until symptomatic/radiological evidence of relapse (decision to be individualized)	
	Long disease-free interval and localized relapse		Surgical resection of relapsed disease may be considered	

serous ovarian carcinomas. However, limiting factors such as spatial resolution, metabolic activity on or between bowel loops, and the presence of post-surgical inflammation/adhesion may reduce the diagnostic accuracy of PET/CT.⁴⁰ False-negative results are seen in mucinous adenocarcinomas and necrotic, cystic or low volume recurrence. Thus, FDG-PET/CT can be used as an adjunct when CT findings are indeterminate with persistent clinical concern.⁴²

Principles of Management

Depending on the stage and extent of disease, ovarian cancer patients are managed with primary cytoreduction (removal of uterus, tubes and ovaries, omentum, peritoneal biopsy and lymph-node dissection), secondary cyto-reduction following neo-adjuvant chemotherapy, palliative intent chemotherapy, and best supportive care.

Chemotherapy may be omitted in low-grade, stage IA or IB cancers. All other stages are given four to six cycles of adjuvant chemotherapy. Fertility-sparing surgery may be an option in ovary-confined disease, if the woman wishes to consider future child-bearing options.

The principle of management in advanced stages is “optimal debulking (removal of all macroscopic disease)” followed by adjuvant chemotherapy.^{43,44}

The preferred chemotherapy regimen is six cycles of paclitaxel and carboplatin. Neoadjuvant chemotherapy with interval cytoreductive surgery has become a preferred option, especially in high-volume disease.^{44–46}

Targeted therapies such as bevacizumab and PARP inhibitors, have shown to improve overall or progression survival,

especially in women with genetic mutations such as BRCA 1 and 2.^{47,48} Hyper-thermic intraperitoneal chemotherapy (HIPEC) is also given in optimally debulked advanced stage III/IV ovarian cancers. **Table 3** summarizes the principles of management.

Follow-up Management and Treatment of Relapse

Clinical examination is routinely performed posttreatment and at 3 to 4 monthly intervals. Serum markers, if elevated at diagnosis, is the simplest methodology to follow-up.^{49,50} The role of serial imaging posttreatment is debatable and is left to the institutional protocol.

The roles of surgical management including secondary cytoreduction, HIPEC in patients with relapsed epithelial cancers remains controversial. The management of relapsed cancers remains systemic chemotherapy and appropriate choice of PARP inhibitor and/or VEGF inhibition.

The flowchart below summarizes the imaging and management guidelines for ovarian cancer (**Fig. 5**).

Summary of Recommendations

1. No screening tests or imaging are recommended even for high-risk patients for detection of ovarian/tubal cancers.
2. Ovarian cancers are primarily staged through primary cytoreductive surgery and the pathology is confirmed surgical histopathology.
3. Staging through imaging is best done with CT of the abdomen and pelvis with oral and IV contrast and CT

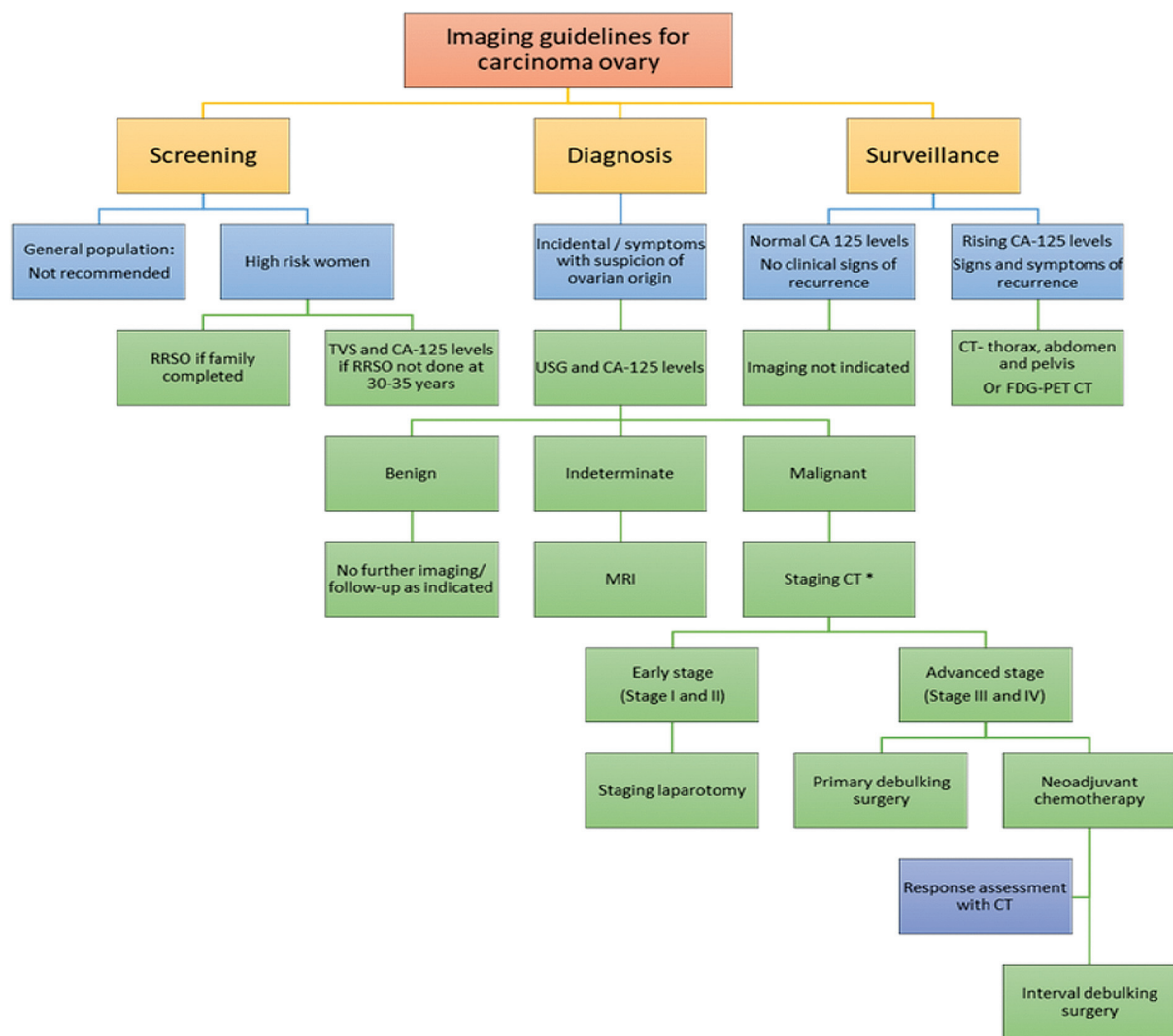


Fig. 5 Imaging guidelines for carcinoma ovary. RRSO, risk reducing salpingo-oophorectomy; TVS, transvaginal sonography. *Apart from CT, other equivalent appropriate modalities for staging include, MRI abdomen and pelvis with contrast and FDG PET-CT.

- chest is a useful addition in those with pleural effusion.
- CT abdomen and pelvis with oral and IV contrast is also used to assess the response to neoadjuvant chemotherapy before interval debulking surgery.
 - In case of suspected recurrence, contrast-enhanced CT thorax, abdomen, and pelvis with oral contrast is the imaging modality of choice. FDG PET CT may be considered when CT findings are inconclusive and there is high clinical suspicion of recurrence.

Funding
None.

Conflict of Interest
None declared.

References

- Torre LA, Bray F, Siegel RL, Ferlay J, Lortet-Tieulent J, Jemal A. Global cancer statistics, 2012. *CA Cancer J Clin* 2015;65(02): 87–108
- Forstner R, Hricak H, Occhipinti KA, Powell CB, Frankel SD, Stern JL. Ovarian cancer: staging with CT and MR imaging. *Radiology* 1995;197(03):619–626
- NCCN Clinical Practice Guidelines in Oncology Epithelial ovarian cancer (including fallopian tube cancer and primary peritoneal cancer). Version 1.2022. Accessed November 09, 2022, at: https://www.nccn.org/professionals/physician_gls/pdf/ovarian.pdf
- Duska LR, Kohn EC. The new classifications of ovarian, fallopian tube, and primary peritoneal cancer and their clinical implications. *Ann Oncol* 2017;28(suppl_8):viii8–viii12. Doi: 10.1093/annonc/mdx445
- Momenimovahed Z, Tiznobaik A, Taheri S, Salehiniya H. Ovarian cancer in the world: epidemiology and risk factors. *Int J Womens Health* 2019;11:287–299. Doi: 10.2147/IJWH.S197604
- Bray F, Ferlay J, Soerjomataram I, Siegel RL, Torre LA, Jemal A. Global cancer statistics 2018: GLOBOCAN estimates of incidence and mortality worldwide for 36 cancers in 185 countries. *CA Cancer J Clin* 2018;68(06):394–424. Doi: 10.3322/caac.21492
- Malvezzi M, Carioli G, Rodriguez T, Negri E, La Vecchia C. Global trends and predictions in ovarian cancer mortality. *Ann Oncol* 2016;27(11):2017–2025. Doi: 10.1093/annonc/mdw306
- Mathur P, Sathishkumar K, Chaturvedi M, et al; ICMR-NCDIR-NCRP Investigator Group. Cancer Statistics, 2020: Report From National Cancer Registry Programme, India. *JCO Glob Oncol* 2020; 6(06):1063–1075. Doi: 10.1200/GO.20.00122

- 9 Menon U, Gentry-Maharaj A, Burnell M, et al. Ovarian cancer population screening and mortality after long-term follow-up in the UK Collaborative Trial of Ovarian Cancer Screening (UKCTOCS): a randomised controlled trial. *Lancet* 2021;397(10290):2182–2193. Doi: 10.1016/S0140-6736(21)00731-5
- 10 Daly MB, Pal T, Berry MP, et al; Genetic/familial high-risk assessment: breast, ovarian, and pancreatic, Version 2.2021, NCCN Clinical Practice Guidelines in Oncology. *J Natl Compr Canc Netw* 2021;19(01):77–102. Doi: 10.6004/jnccn.2021.0001
- 11 Atri M, Alabousi A, Reinhold C, et al; Expert Panel on Women's Imaging. ACR appropriateness criteria® clinically suspected adnexal mass, no acute symptoms. *J Am Coll Radiol* 2019;16(5S):S77–S93. Doi: 10.1016/j.jacr.2019.02.011
- 12 Schmidt S, Meuli RA, Achdari C, Prior JO. Peritoneal carcinomatosis in primary ovarian cancer staging: comparison between MDCT, MRI, and 18F-FDG PET/CT. *Clin Nucl Med* 2015;40(05):371–377
- 13 Liu J, Xu Y, Wang J. Ultrasonography, computed tomography and magnetic resonance imaging for diagnosis of ovarian carcinoma. *Eur J Radiol* 2007;62(03):328–334
- 14 Kang SK, Reinhold C, Atri M, et al; Expert Panel on Women's Imaging. ACR appropriateness criteria® staging and follow-up of ovarian cancer. *J Am Coll Radiol* 2018;15(5S):S198–S207. Doi: 10.1016/j.jacr.2018.03.015
- 15 Rockall A, Munari A, Avril N. New ways of assessing ovarian cancer response: metabolic imaging and beyond. *Cancer Imaging* 2012;12(02):310–314. Doi: 10.1102/1470-7330.2012.9004
- 16 Vallius T, Hynninen J, Kempainen J, et al. ¹⁸F-FDG-PET/CT based total metabolic tumor volume change during neoadjuvant chemotherapy predicts outcome in advanced epithelial ovarian cancer. *Eur J Nucl Med Mol Imaging* 2018;45(07):1224–1232. Doi: 10.1007/s00259-018-3961-z
- 17 Winfield JM, Wakefield JC, Dolling D, et al. Diffusion-weighted MRI in advanced epithelial ovarian cancer: apparent diffusion coefficient as a response marker. *Radiology* 2019;293(02):374–383. Doi: 10.1148/radiol.2019190545
- 18 Sebastian S, Lee SI, Horowitz NS, et al. PET-CT vs. CT alone in ovarian cancer recurrence. *Abdom Imaging* 2008;33(01):112–118. Doi: 10.1007/s00261-007-9218-0
- 19 Bast RC Jr, Klug TL, St John E, et al. A radioimmunoassay using a monoclonal antibody to monitor the course of epithelial ovarian cancer. *N Engl J Med* 1983;309(15):883–887
- 20 Dodge JE, Covens AL, Lacchetti C, et al; Gynecology Cancer Disease Site Group. Preoperative identification of a suspicious adnexal mass: a systematic review and meta-analysis. *Gynecol Oncol* 2012;126(01):157–166
- 21 Hewitt MJ, Anderson K, Hall GD, et al. Women with peritoneal carcinomatosis of unknown origin: Efficacy of image-guided biopsy to determine site-specific diagnosis. *BJOG* 2007;114(01):46–50
- 22 Fagotti A, Ferrandina G, Fanfani F, et al. A laparoscopy-based score to predict surgical outcome in patients with advanced ovarian carcinoma: a pilot study. *Ann Surg Oncol* 2006;13(08):1156–1161
- 23 Rutten MJ, van Meurs HS, van de Vrie R, et al. Laparoscopy to predict the result of primary cytoreductive surgery in patients with advanced ovarian cancer: a randomized controlled trial. *J Clin Oncol* 2017;35(06):613–621
- 24 Konstantinopoulos PA, Norquist B, Lacchetti C, et al. Germline and somatic tumor testing in epithelial ovarian cancer: ASCO guideline. *J Clin Oncol* 2020;38(11):1222–1245
- 25 Siegel RL, Miller KD, Fuchs HE, Jemal A. Cancer Statistics, 2021. *CA Cancer J Clin* 2021;71(01):7–33
- 26 Buys SS, Partridge E, Black A, et al; PLCO Project Team. Effect of screening on ovarian cancer mortality: the prostate, lung, colorectal and ovarian (PLCO) cancer screening randomized controlled trial. *JAMA* 2011;305(22):2295–2303. Doi: 10.1001/jama.2011.766
- 27 Grossman DC, Curry SJ, Owens DK, et al; US Preventive Services Task Force. Screening for ovarian cancer: US Preventive Services Task Force Recommendation Statement. *JAMA* 2018;319(06):588–594. Doi: 10.1001/jama.2017.21926
- 28 Committee on Gynecologic Practice, Society of Gynecologic Oncology. Committee Opinion No. 716: the role of the obstetrician-gynaecologist in the early detection of epithelial ovarian cancer in women at average risk. *Obstet Gynecol* 2017;130(03):e146–e149
- 29 Smith RA, Andrews KS, Brooks D, et al. Cancer screening in the United States, 2017: a review of current American Cancer Society guidelines and current issues in cancer screening. *CA Cancer J Clin* 2017;67(02):100–121. Doi: 10.3322/caac.21392
- 30 Andreotti RF, Timmerman D, Strachowski LM, et al. O-RADS US risk stratification and management system: a consensus guideline from the ACR Ovarian-Adnexal Reporting and Data System Committee. *Radiology* 2020;294(01):168–185. Doi: 10.1148/radiol.2019191150
- 31 Sadowski EA, Thomassin-Naggara I, Rockall A, et al. O-RADS MRI risk stratification system: guide for assessing adnexal lesions from the ACR O-RADS Committee. *Radiology* 2022;303(01):35–47. Doi: 10.1148/radiol.204371
- 32 Hynninen J, Kempainen J, Lavonius M, et al. A prospective comparison of integrated FDG-PET/contrast-enhanced CT and contrast-enhanced CT for pretreatment imaging of advanced epithelial ovarian cancer. *Gynecol Oncol* 2013;131(02):389–394
- 33 Koh JL, Yan TD, Glenn D, Morris DL. Evaluation of preoperative computed tomography in estimating peritoneal cancer index in colorectal peritoneal carcinomatosis. *Ann Surg Oncol* 2009;16(02):327–333. Doi: 10.1245/s10434-008-0234-2
- 34 Low RN, Barone RM. Combined diffusion-weighted and gadolinium-enhanced MRI can accurately predict the peritoneal cancer index preoperatively in patients being considered for cytoreductive surgical procedures. *Ann Surg Oncol* 2012;19(05):1394–1401
- 35 Castellucci P, Perrone AM, Picchio M, et al. Diagnostic accuracy of ¹⁸F-FDG PET/CT in characterizing ovarian lesions and staging ovarian cancer: correlation with transvaginal ultrasonography, computed tomography, and histology. *Nucl Med Commun* 2007;28(08):589–595. Doi: 10.1097/MNM.0b013e3281afa256
- 36 Nam EJ, Yun MJ, Oh YT, et al. Diagnosis and staging of primary ovarian cancer: correlation between PET/CT, Doppler US, and CT or MRI. *Gynecol Oncol* 2010;116(03):389–394
- 37 Mutch DG, Prat J. 2014 FIGO staging for ovarian, fallopian tube and peritoneal cancer. *Gynecol Oncol* 2014;133(03):401–404
- 38 Berek JS, Renz M, Kehoe S, Kumar L, Friedlander M. Cancer of the ovary, fallopian tube, and peritoneum: 2021 update. *Int J Gynaecol Obstet* 2021;155(Suppl 1):61–85. Doi: 10.1002/ijgo.13878
- 39 Tawakol A, Abdelhafez YG, Osama A, Hamada E, El Refaei S. Diagnostic performance of ¹⁸F-FDG PET/contrast-enhanced CT versus contrast-enhanced CT alone for post-treatment detection of ovarian malignancy. *Nucl Med Commun* 2016;37(05):453–460
- 40 Gu P, Pan LL, Wu SQ, Sun L, Huang G. CA 125, PET alone, PET-CT, CT and MRI in diagnosing recurrent ovarian carcinoma: a systematic review and meta-analysis. *Eur J Radiol* 2009;71(01):164–174
- 41 Nakamoto Y, Saga T, Ishimori T, et al. Clinical value of positron emission tomography with FDG for recurrent ovarian cancer. *Am J Roentgenol* 2001;176(06):1449–1454
- 42 Salani R, Backes FJ, Fung MFK, et al. Posttreatment surveillance and diagnosis of recurrence in women with gynecologic malignancies: Society of Gynecologic Oncologists recommendations. *Am J Obstet Gynecol* 2011;204(06):466–478
- 43 Chi DS, Eisenhauer EL, Zivanovic O, et al. Improved progression-free and overall survival in advanced ovarian cancer as a result of a change in surgical paradigm. *Gynecol Oncol* 2009;114(01):26–31. Doi: 10.1016/j.ygyno.2009.03.018
- 44 Elattar A, Bryant A, Winter-Roach BA, Hatem M, Naik R. Optimal primary surgical treatment for advanced epithelial ovarian cancer. *Cochrane Database Syst Rev* 2011;(08):CD007565. Doi: 10.1002/14651858.CD007565.pub2
- 45 Kehoe S, Hook J, Nankivell M, et al. Primary chemotherapy versus primary surgery for newly diagnosed advanced ovarian cancer

- (CHORUS): an open-label, randomised, controlled, non-inferiority trial. *Lancet* 2015;386(9990):249–257. Doi: 10.1016/S0140-6736(14)62223-6
- 46 Makar AP, Tropé CG, Tummers P, Denys H, Vandecasteele K. Advanced ovarian cancer: primary or interval debulking? Five categories of patients in view of the results of randomized trials and tumor biology: primary debulking surgery and interval debulking surgery for advanced ovarian cancer. *Oncologist* 2016;21(06):745–754. Doi: 10.1634/theoncologist.2015-0239
- 47 Tewari KS, Burger RA, Enserro D, et al. Final overall survival of a randomized trial of bevacizumab for primary treatment of ovarian cancer. *J Clin Oncol* 2019;37(26):2317–2328. Doi: 10.1200/JCO.19.01009
- 48 Moore K, Colombo N, Scambia G, et al. Maintenance olaparib in patients with newly diagnosed advanced ovarian cancer. *N Engl J Med* 2018;379(26):2495–2505. Doi: 10.1056/NEJMoa1810858
- 49 Rustin GJS. Follow-up with CA125 after primary therapy of advanced ovarian cancer has major implications for treatment outcome and trial performances and should not be routinely performed. *Ann Oncol* 2011;22(Suppl 8)viii45–viii48. Doi: 10.1093/annonc/mdr471
- 50 Esselen KM, Cronin AM, Bixel K, et al. Use of CA-125 tests and computed tomographic scans for surveillance in ovarian cancer. *JAMA Oncol* 2016;2(11):1427–1433. Doi: 10.1001/jamaoncol.2016.1842