



# Imaging Recommendations for Diagnosis, Staging, and Management of Prostate Cancer

Nilesh P. Sable<sup>1</sup> Ganesh K. Bakshi<sup>2</sup> N. Raghavan<sup>3</sup> Hemang Bakshi<sup>4</sup> Rakesh Sharma<sup>5</sup>  
Santosh Menon<sup>6</sup> Prabhash Kumar<sup>7</sup> Aparna Katdare<sup>1</sup> Palak Popat<sup>1</sup>

<sup>1</sup>Department of Radiodiagnosis, Tata Memorial Hospital, Parel, Mumbai, Maharashtra, India

<sup>2</sup>Department of Urology, P.D. Hinduja Hospital and Research Centre, Mumbai, Maharashtra, India

<sup>3</sup>Department of Surgical Oncology, Apollo Hospitals, Chennai, Tamil Nadu, India

<sup>4</sup>Department of Surgical Oncology, Cancer Centre, Ahmedabad, Gujarat, India

<sup>5</sup>Department of Surgical Oncology, INDO American Basavatarakam Cancer Centre, Hyderabad, Telangana, India

<sup>6</sup>Department of Pathology, Tata Memorial Hospital, Parel, Mumbai, Maharashtra, India

<sup>7</sup>Department of Medical Oncology, Tata Memorial Hospital, Parel, Mumbai, Maharashtra, India

Address for correspondence Nilesh P. Sable, MD, Department of Radiodiagnosis, Tata Memorial Hospital, Parel, Mumbai, Maharashtra, India (e-mail: drnileshsable@gmail.com).

Ind J Med Paediatr Oncol 2023;44:130–137.

## Abstract

### Keywords

- ▶ mpMRI prostate
- ▶ prostate cancer
- ▶ prostate cancer imaging guidelines
- ▶ prostate cancer imaging recommendations
- ▶ PSMAPETCT
- ▶ PSMAPETMRI

The Prostate Carcinoma Guidelines Panel have formulated these guidelines to assist medical professionals in the evidence-based management of prostate cancer. These have been formulated by a panel consisting of Indian multidisciplinary group of radiologists, uro-oncologists, urologists, radiation oncologists, medical oncologists, and pathologists. These recommendations present the best evidence available to the clinicians; however, using these recommendations will not always result in the best outcome. They aid in decision making for individual patients; however, these will never replace clinical expertise when making treatment decisions. Taking personal values and preferences or individual circumstances of patients into account is necessary for final treatment decision. Guidelines are not mandatory and should not to be referred as a legal standard of care.

## Introduction

The Prostate Carcinoma Guidelines Panel have formulated these guidelines to assist medical professionals in the evidence-based management of prostate cancer [PCa].

These guidelines present the best evidence available to the clinicians; however, using guideline these recommendations will not always result in the best outcome. They aid in decision making for individual patients; however, these will never replace clinical expertise when making treatment decisions. Taking personal values and preferences or indi-

vidual circumstances of patients into account is necessary for final treatment decision. Guidelines are not mandatory and should not to be referred as a legal standard of care.

The Guidelines Panel consists of an Indian multidisciplinary group of radiologists, uro-oncologists, urologists, radiation oncologists, medical oncologists, and pathologists.

## Risk Factors and Etiopathogenesis

PCa remains the second most common cancer in men and the fifth leading cause of death around the globe.<sup>1</sup> It may be

DOI <https://doi.org/10.1055/s-0042-1759517>.  
ISSN 0971-5851.

© 2023. The Author(s).

This is an open access article published by Thieme under the terms of the Creative Commons Attribution License, permitting unrestricted use, distribution, and reproduction so long as the original work is properly cited. (<https://creativecommons.org/licenses/by/4.0/>)

Thieme Medical and Scientific Publishers Pvt. Ltd., A-12, 2nd Floor, Sector 2, Noida-201301 UP, India

asymptomatic at the early stages and can be very slow growing which may need only active surveillance. According to the GLOBOCAN 2020 data,<sup>1</sup> 1,414,259 new cases of prostate cancer were reported worldwide in 2020, causing 3,75,304 deaths, with higher prevalence in developed countries.

Family history and racial/ethnic background are associated with an increase incidence PCa.

Across the globe, incidence and mortality of PCa correlate with advanced age. The mean age at the time of diagnosis approximately is 66 years in most studies. In African-American men, the incidence rates are higher than in White men, and their mortality is approximately twice as that in White men.<sup>2</sup>

Elevated plasma levels of prostate-specific antigen (PSA more than 4 ng/mL), a glycoprotein normally expressed by prostate tissue forms the basis of the diagnosis in most patients. However, as elevated PSA levels can also be found in men without PCa, a tissue diagnosis by biopsy remains the current standard of care to confirm cancer.

Uncertainty still exists about the relation of diet, obesity, and use of some vitamins or minerals as the cause of prostate cancer.

## Epidemiology and Clinical Presentation

Significant variation is seen in the incidence of prostate cancer across the regions and populations around the globe.<sup>1</sup> In 2020, 1,414,259 new cases of prostate cancer were registered worldwide, representing 7.3% of all cancers in men.<sup>3</sup> The age-standardized rate (ASR) was the highest in Oceania (443.5 per 100,000 people) and North America (397.9) followed by Europe (328.5). As compared to these developed countries, the Asian and African countries have low incidence (185.2 and 126.8, respectively) with incidence in India up to 95.7, the lowest incidence in Niger being 66.9.

Diet modifications and physical activity are important in prostate cancer development and progression. These are mainly related to the observed worldwide and ethnic differences in the incidence rates of prostate cancer.<sup>4-6</sup>

Prostate cancer incidence increases with age.<sup>1</sup> Though only 1 in 350 men under the age of 50 years will be diagnosed with prostate cancer,<sup>7</sup> the incidence rate increases up to 1 in every 52 men for ages 50 to 59 years. The incidence rate reaches 60% in men over the age of 65 years.<sup>8</sup>

Clinical presentation: At the early stage, many patients may be asymptomatic, often with an indolent course, who need minimal or even no treatment. In symptomatic patients, the presenting symptoms are difficulty with micturition, increased frequency, and nocturia, mimicking benign prostatic hypertrophy. PCa can also present with hematuria, hematospermia, or erectile dysfunction. In advanced stages, patients may present with severe urinary symptoms such as urinary retention and with weakness, back pain, and weight loss. Bony metastases is commonly present in metastatic disease.

## Clinical/Diagnostic Work-Up

Digital rectal examination (DRE): PCas are most commonly located in the peripheral zone and easily detected if the

tumor volume is more than 0.2 mL. Abnormal DRE remains the first indicator for the PCa (approximately 18% of cases being detected by DRE alone<sup>9</sup> and is an indication of biopsy).

Prostate-specific antigen (PSA): PSA is a serum marker specific to the prostate; however, it is not specific to PCa. Hence, it can be seen elevated in other non-malignant conditions such as benign prostatic hypertrophy (BPH) and prostatitis. PSA seems a better predictor of cancer than either DRE or transrectal ultrasonography (TRUS) as an independent variable. Yet there are no standards defined for measuring PSA.<sup>10</sup> It is a continuous parameter, with higher levels indicating greater likelihood of PCa. However, PCa can also be seen with PSA levels below 4 ng/mL.

In addition to these variables, PSA density (the level of serum PSA divided by the prostate volume) or PSA doubling time and free/total PSA ratio can be also assessed for evaluation of the disease, in clinical settings.

## Risk Stratification

Risk stratification is an integral part of PCa treatment and should be performed before starting management.

Low-risk	Gleason score $\leq$ 6, PSA $\leq$ 10 and stage T1-T2a
Intermediate-risk	Gleason score 7, PSA > 10–20 and stage T2b
High-risk	Gleason score 8 to 10, PSA > 20 and stage T2c

Patients are stratified in low-risk, intermediate-risk, and high-risk depending on PSA values, T stage of the disease and Gleason score.<sup>11</sup>

## Diagnostic Evaluation

### Screening and Early Detection

#### Screening

Systematic examination of asymptomatic men (at risk) performed by health authorities is called screening, which is aimed at the reduction of mortality as well as maintaining the quality of life in PCa patients. Aggressive screening in USA showed decreased in mortality in PCa patients.<sup>12</sup>

The updated Cochrane review endorsed the following points<sup>13</sup>: Screening is associated with an increased diagnosis of PCa, detection of more localized disease and less detection of the advanced disease. However, no cancer specific survival benefit and overall survival benefit was seen because of screening.

Where screening is considered, a single PSA test is not enough according to the results of a randomized trial of PSA testing "CAP trial"<sup>14</sup>. In this trial, they concluded that single PSA screening intervention detected more number of low-risk PCa cases but had no significant effect on PCa mortality after a median follow-up of 10 years.

**Recommendations for screening**

	Recommendation	Level of Evidence	Strength of recommendation
1.1	Do not subject men to screening with PSA without counseling them on the potential risks and benefits.	3	Strong
1.2	Offer an individualized risk-adapted strategy for early detection to a well-informed man and a life-expectancy of at least 10 to 15 years.	3	Weak
1.3	Offer early PSA testing to well-informed men at elevated risk of having PCa in men > 50 years of age, men > 45 years of age, and a family history of PCa, men of African descent > 45 years of age, men carrying <i>BRCA2</i> mutations > 40 years of age.	2a	Strong
1.4	Offer a risk-adapted strategy (based on initial PSA level), with follow-up intervals of 2 years for those initially at risk in men with a PSA level of > 1 ng/mL at 40 years of age, men with a PSA level of > 2 ng/mL at 60 years of age, Postpone follow-up to 8 years in those not at risk.	3	Weak
1.5	Stop early diagnosis of PCa based on life expectancy and performance status and in men who have a life-expectancy of < 15 years are unlikely to benefit.	3	Strong

**Ultrasonography and Biopsy**

The transabdominal USG has no defined role in detection of PCa, which cannot characterize the prostatic lesions adequately. Transrectal USG is also not accurate in prediction of an organ-confined disease as compared to DRE. It is commonly used in guidance of prostate biopsies. Alternatively, transperineal route can also be used for biopsy. PCa detection rates are almost similar using both the routes; however, according to a few studies, transperineal route requires more extensive local anesthesia and is associated with decreased infection rates.<sup>15</sup> Reliability of gray-scale TRUS for detection of PCa is very low;<sup>16</sup> however, recent innovations in sonog-

raphy techniques such as color Doppler, elastography, and contrast-enhanced USG either alone or in various combinations can give satisfactory results in PCa diagnosis. The diagnostic yield of additional biopsies performed on hypoechoic lesions is not significant.<sup>17</sup>

The requirement of prostate biopsy depends on the findings of PSA levels, abnormal DRE or imaging (transrectal USG/MRI). Age of patient, various comorbidities, and therapeutic implications should also be noted and discussed with the patient before the procedure to reduce unnecessary biopsies.<sup>18,19</sup>

**Multiparametric Magnetic Resonance imaging**

Multiparametric magnetic resonance imaging (mpMRI) has good sensitivity for the detection and localization of ISUP grade > 2 cancers.<sup>20</sup> Recent Cochrane meta-analysis that compared mpMRI to template biopsies, mpMRI had a pooled sensitivity and specificity of 0.91 and 0.37, respectively, for ISUP grade > 2 cancers.<sup>21</sup> Similarly, for ISUP grade > 3 cancers, mpMRI pooled sensitivity and specificity were 0.95 and 0.35, respectively. In contrast, mpMRI is less sensitive in identifying ISUP grade 1 cancer. Targeting biopsies with prior mpMRI increases the detection rates of PCa with higher ISUP grades as compared to standard systematic biopsies in both the biopsy naïve patients and repeat biopsy patients. Many centers now use a combined approach of standard systematic biopsy along with mpMRI directed biopsy (MRTBx).

Repeat biopsy after previously negative biopsy:

Indications for repeat biopsy:

- > Increasing and/or persistently elevated PSA.
- > Suspicious DRE, 5–30% PCa risk.
- > Atypical small acinar proliferation (such as atypical glands suspicious for cancer), 31–40% PCa risk on repeat biopsy<sup>22,23</sup>;
- > Extensive (multiple biopsy sites > 3) high-grade prostatic intraepithelial neoplasia (HGPIN), approximately 30% PCa risk<sup>23,24</sup>;
- > A few atypical glands immediately adjacent to high-grade prostatic intraepithelial neoplasia (PINATYP), approximately 50% PCa risk<sup>25</sup>;
- > Intraductal carcinoma as a solitary finding, > 90% risk of associated high-volume and high grade PCa<sup>26</sup>;
- > Positive mpMRI findings.

mpMRI Protocol:

We are currently using following protocol on 1.5 T Philips MRI machine.

Sr. No.	Name of sequence	FOV (Filed of view) in mm	Slice Thickness and interslice interval (in mm)	Matrix
1	Sagittal T2W (small FOV)	200	3/0	284 × 220
2	Oblique axial T2W (small FOV)	180	3/0.3	256 × 190

(Continued)

Sr. No.	Name of sequence	FOV (Filed of view) in mm	Slice Thickness and interslice interval (in mm)	Matrix
3	Oblique coronal T2W (small FOV)	180	3/0.3	256 × 190
4	Axial T1W (large FOV)	363	5/1.5	406 × 296
5	Axial T2W (large FOV)	363	5/1.5	406 × 296
6	Diffusion-weighted sequence (DWI) at 0, 500, and 800	364	5/1.5	127 × 125
7	Zoom DWI at 0, 800, and 1500	180	3/0.3	64 × 62
8	Dynamic post-contrast T1W sequence (8 phases) *(small FOV)	180	4/2	64 × 64
9	Axial postcontrast fat sat T1W (large FOV)	364	5/1.5	376 × 300
10	Oblique axial postcontrast fat sat T1W (small FOV)		3/0.3	200 × 156
11	Sagittal post-contrast fat sat T1W (small FOV)		3/0.0	208 × 150
12	Coronal post-contrast fat sat T1W (small FOV)		3/0.5	208 × 152

\* Dynamic T1W postcontrast sequence starts at 10 seconds from contrast injection after a mask phase, each phase is obtained 15 seconds apart.

### CT SCAN

Role of CT scan in imaging of PCa is limited to nodal and metastatic staging. Although it is not advocated in detection or primary staging of PCa, a few studies show that it has some role in detection of PCas.<sup>27</sup>

### PET CT SCAN

PET CT scan has emerged as an important staging modality for primary as well as recurrent prostate cancer. Previously, NaF was used a radiotracer that showed a high sensitivity but low specificity. Recently, tracers such as choline, fluciclovine, and especially PSMA have shown increased detection for smaller metastatic lesions that are not easily seen on CT or MR imaging.<sup>28</sup> Clinical implications of these occult PET/CT detected disease may be beneficial to patients. Efforts are now targeted to define their natural history and response to treatment and an overall impact of metastasis-directed therapy detected by these investigations. In comparison, with the conventional staging approach, addi-

tional lymph nodal metastases and skeletal/visceral metastases were detected in 25% and 6% of patients, respectively.<sup>29</sup> Thus, PSMA PET/CT is cost-effective and can be considered as a standard modality compared to conventional imaging for initial staging of men with high-risk prostate cancer.<sup>30</sup>

### PET MRI

After promising results from the PSMA PET CT, researchers have now added MRI to PET component that provides highly accurate morphological information to the functional information of PET. The first two PSMA agents for PET imaging were 18F-DCFBC and 68Ga-PSMA-11. Two other agents with theranostic capabilities, the chelator-based PSMA-617 and the PSMA inhibitor for imaging and therapy PSMA-I&T are also now used. Some second-generation 18F-labeled PSMA legends were also introduced to overcome the high blood-pool activity and low tumor-to-background ratios of 18F-DCFBC, viz., 18F-DCFPyL, and 18F-PSMA-1007 (most recent), which has very low urine clearance. The MRI component has high soft tissue resolution, hence can be used for accurate delineation of the lesion (local staging, i.e., T staging). In contrast, the PSMA PET component has a higher value in detection of the metastatic lymph nodes and other metastatic lesions (can be used in N staging and M staging). Thus, PSMA PET-MRI overcomes the shortcomings of each modality when used singly. Because of these reasons, it has got higher sensitivity (up to 76%) as compared to mpMRI and PET, when these modalities are used alone.<sup>31</sup>

### Recommendations for PCa detections

#### Recommendations for all patients

	Recommendation	Level of evidence	Strength of recommendation
2.1.1	Systematic biopsy is an acceptable approach in case mpMRI is not available.	3	Strong
	Do not use multiparametric magnetic resonance imaging (mpMRI) as an initial screening tool.	3	Strong
2.1.3.	Adhere to PI-RADS guidelines for mpMRI acquisition and interpretation and evaluate mpMRI results in multidisciplinary meetings with pathological feedback.	3	Strong
Recommendations in biopsy naïve patients			
2.2.1	2.2.1. Perform mpMRI before prostate biopsy.	1a	Strong

(Continued)

(Continued)

	Recommendation	Level of evidence	Strength of recommendation
2.2.2	2.2.2. When mpMRI is positive (PI-RADS > 3), combine targeted and systematic biopsy.	2a	Strong
2.2.3	2.2.3. When mpMRI is negative (PI-RADS < 2), and clinical suspicion of prostate cancer is low, omit biopsy based on shared decision making with the patient.	2a	Weak
Recommendations in patients with prior negative biopsy:			
2.3.1	Perform mpMRI before prostate biopsy.	1a	Strong
2.3.2	When mpMRI is positive (i.e., PI-RADS > 3), perform targeted biopsy only.	2a	Weak
2.3.3	When mpMRI is negative (i.e., PI-RADS < 2), and clinical suspicion of prostate cancer is high, perform systematic biopsy based on shared decision making with the patient.	2a	Strong

Staging: The extent of PCa is evaluated by DRE and PSA, along with mpMRI, bone scanning and CT scan.

Stage: Can be clinical (cT) or pathological (pT)T staging as per the AJCC 8th cancer staging edition.<sup>32</sup> Complete clinical and pathological T staging is given in ► **Table 1** in detail:

For T staging, only DRE findings are taken into account as of now. TRUS has no value in prediction of an organ-confined disease. Though mpMRI has good specificity for detection of T3 tumors, it is still not recommended for staging of the disease, in view of low sensitivity.<sup>33</sup> However, it can be used for planning of disease treatment.

N Stage: The regional nodes are assessed in N staging, which are defined as the nodes confined to the true pelvis (pelvic nodes below the bifurcation of the common iliac arteries). Detailed N staging in ► **Table 2**.

Abdominopelvic CT scan and MRI have been tried for nodal staging in PCa patients, which consider the size of the nodes to label them malignant (short axis more than 8 mm in the pelvic cavity and more than 10 mm outside the pelvic cavity). However, these techniques have very low sensitivity.<sup>34</sup> Choline PET CT also has low sensitivity.<sup>35</sup> According to a few studies, PSMA PET/CT has higher sensitivity for LN metastases as compared to mpMRI, abdominal contrast-enhanced CT or choline PET/CT.<sup>36</sup>

Various imaging modalities are used for M staging including 99mTc-Bone labelled bone scan, Fluoride PET and PET/CT, choline PET/CT, whole body MRI and PSMA PET CT, amongst these PSMA PET CT outperforms the other modalities with sensitivity (33-99%) and specificity (> 90 %).<sup>37</sup> Detailed M staging is shown in ► **Table 3**.

**Table 1** T Staging(Clinical and Pathological)

Clinical T staging (cT):		
	Tx	Primary tumour cannot be assessed
		No evidence of primary tumour
T1		A clinically inapparent tumour that is not palpable
	T1a	Tumour incidental histologic finding in 5% or less of tissue resected
	T1b	Tumour incidental histologic finding in more than 5% of tissue resected
	T1c	Tumour identified by needle biopsy found in one or both sides, but not palpable
T2		Tumour is palpable and confined within the prostate
	T2a	Tumour involves one-half of one side or less
	T2b	Tumour involves more than one-half of one side but not both sides
	T2c	Tumour involves both sides
T3		Extraprostatic tumour that is not fixed or does not invade adjacent structures
	T3a	Extraprostatic extension (unilateral or bilateral)
	T3b	Tumour invades seminal vesicle(s)
T4		

**Table 1** (Continued)

Clinical T staging (cT):		
		Tumour is fixed or invades adjacent structures other than seminal vesicles such as external sphincter, rectum, bladder, levator muscles, and/or pelvic wall
Pathological T staging(pT):		
T2		Organ confined.
T3		Extraprostatic extension.
	T3a	Extraprostatic extension (unilateral or bilateral) or microscopic invasion of the bladder neck
	T3b	Tumour invades seminal vesicle(s)
T4		<b>T4:</b> Tumour is fixed or invades adjacent structures other than seminal vesicles such as external sphincter, rectum, bladder, levator muscles, and/or pelvic wall

**Table 2** N Staging

Nx	Regional nodes were not assessed.
N0	No positive regional nodes.
N1	Metastases in regional node(s).

Note: A node along the common iliac arteries would be considered as M1a.

**Table 3** M Staging

M0		No distant metastasis.
M1		Distant metastasis
	M1a	Metastasis to non-regional lymph node(s).
	M1b	Metastasis to Bone(s).
	M1c	Other site(s) with or without bone disease e.g., lungs, liver, brain

	Recommendation	Level of evidence	Strength of recommendation
3.1	Any risk group staging: use pre-bi-opsy mpMRI for local staging information.	2a	Strong
3.2	Low-risk localized disease. Do not use additional imaging for staging purposes.	2a	Strong

(Continued)

(Continued)

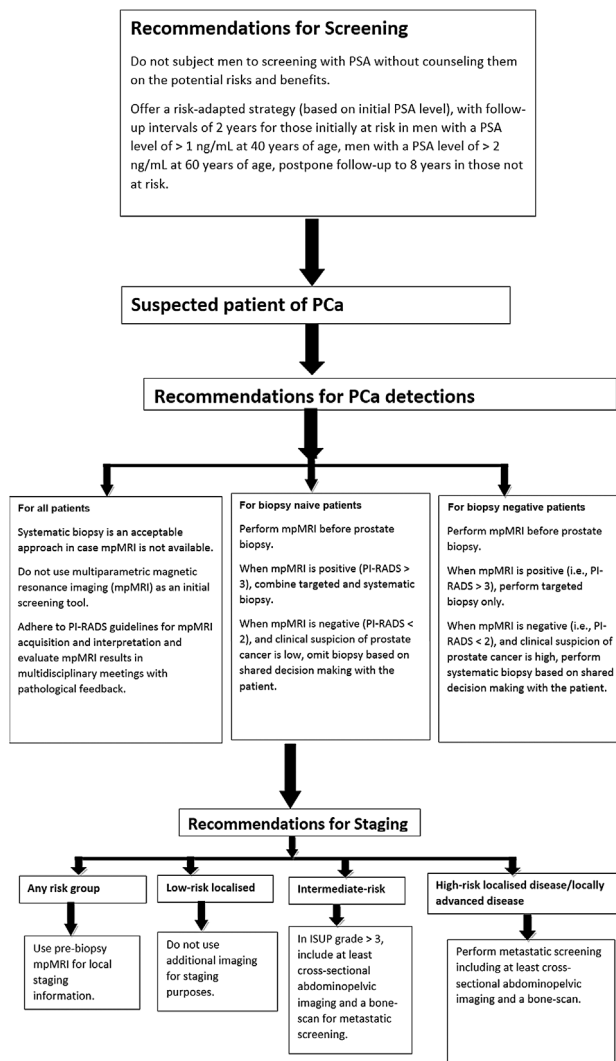
	Recommendation	Level of evidence	Strength of recommendation
3.3	Intermediate-risk disease. In ISUP grade > 3, include at least cross-sectional abdomino-pelvic imaging and a bone-scan for metastatic screening.	2a	Weak
3.4	High-risk localized disease/locally advanced disease. Perform metastatic screening including at least cross-sectional abdomino-pelvic imaging and a bone-scan.	2a	Strong

#### Guidelines for staging of prostate cancer:

**Follow Up:** Imaging techniques are not recommended in routine follow-up of localized PCa as long as the PSA is not rising. Imaging is only suggested in patients for whom the findings will affect treatment decisions, either in case of biochemical recurrence or in symptomatic patients. PSMA PET CT is better than the other modalities such as TRUS, CT scan, MRI, or choline PET CT as imaging of choice in such patients.<sup>38</sup>

To conclude, we can follow the flow chart for staging, diagnosis, and management of PCA



**Conflict of Interest**

None declared.

**References**

- 1 <https://gco.iarc.fr/today>
- 2 Panigrahi GK, Praharaj PP, Kittaka H, et al. Exosome proteomic analyses identify inflammatory phenotype and novel biomarkers in African American prostate cancer patients. *Cancer Med* 2019;8(03):1110–1123. Doi: 10.1002/cam4.1885
- 3 Sung H, Ferlay J, Siegel RL, et al. Global Cancer Statistics 2020: GLOBOCAN Estimates of Incidence and Mortality Worldwide for 36 Cancers in 185 Countries. *CA Cancer J Clin* 2021;71(03):209–249. Doi: 10.3322/caac.21660
- 4 Giovannucci E, Rimm EB, Colditz GA, et al. A prospective study of dietary fat and risk of prostate cancer. *J Natl Cancer Inst* 1993;85(19):1571–1579. Doi: 10.1093/jnci/85.19.1571
- 5 Kolonel LN, Nomura AM, Cooney RV. Dietary fat and prostate cancer: current status. *J Natl Cancer Inst* 1999;91(05):414–428. Doi: 10.1093/jnci/91.5.414
- 6 Willis MS, Wians FH. The role of nutrition in preventing prostate cancer: a review of the proposed mechanism of action of various dietary substances. *Clin Chim Acta* 2003;330(1-2):57–83. Doi: 10.1016/S0009-8981(03)00048-2

- 7 Perdana NR, Mochtar CA, Umbas R, Hamid AR. The Risk Factors of Prostate Cancer and Its Prevention: A Literature Review. *Acta Med Indones* 2016;48(03):228–238
- 8 Rawla P. Epidemiology of Prostate Cancer. *World J Oncol* 2019;10(02):63–89. Doi: 10.14740/wjon1191
- 9 Richie JP, Catalona WJ, Ahmann FR, et al. Effect of patient age on early detection of prostate cancer with serum prostate-specific antigen and digital rectal examination. *Urology* 1993;42(04):365–374. Doi: 10.1016/0090-4295(93)90359-i
- 10 Semjonow A, Brandt B, Oberpenning F, Roth S, Hertle L. Discordance of assay methods creates pitfalls for the interpretation of prostate-specific antigen values. *Prostate Suppl* 1996;7:3–16
- 11 D'Amico AV, Whittington R, Malkowicz SB, et al. Biochemical outcome after radical prostatectomy, external beam radiation therapy, or interstitial radiation therapy for clinically localized prostate cancer. *JAMA* 1998;280(11):969–974. Doi: 10.1001/jama.280.11.969
- 12 Ilic D, Neuberger MM, Djulbegovic M, Dahm P. Screening for prostate cancer. *Cochrane Database Syst Rev* 2013;(01):CD004720. Doi: 10.1002/14651858.CD004720.pub3
- 13 Martin RM, Donovan JL, Turner EL, et al; CAP Trial Group. Effect of a Low-Intensity PSA-Based Screening Intervention on Prostate Cancer Mortality: The CAP Randomized Clinical Trial. *JAMA* 2018;319(09):883–895. Doi: 10.1001/jama.2018.0154
- 14 Lopes PM, Sepúlveda L, Ramos R, Sousa P. The role of transrectal ultrasound in the diagnosis of prostate cancer: new contributions. *Radiol Bras* 2015;48(01):7–11. Doi: 10.1590/0100-3984.2013.0010
- 15 Xiang J, Yan H, Li J, Wang X, Chen H, Zheng X. Transperineal versus transrectal prostate biopsy in the diagnosis of prostate cancer: a systematic review and meta-analysis. *World J Surg Oncol* 2019;17(01):31. Doi: 10.1186/s12957-019-1573-0
- 16 Smeenge M, Barentsz J, Cosgrove D, et al. Role of transrectal ultrasonography (TRUS) in focal therapy of prostate cancer: report from a Consensus Panel. *BJU Int* 2012;110(07):942–948
- 17 Rouvière O, Puech P, Renard-Penna R, et al; MRI-FIRST Investigators. Use of prostate systematic and targeted biopsy on the basis of multiparametric MRI in biopsy-naive patients (MRI-FIRST): a prospective, multicentre, paired diagnostic study. *Lancet Oncol* 2019;20(01):100–109. Doi: 10.1016/S1470-2045(18)30569-2
- 18 Bratan F, Niaf E, Melodelima C, et al. Influence of imaging and histological factors on prostate cancer detection and localisation on multiparametric MRI: a prospective study. *Eur Radiol* 2013;23(07):2019–2029. Doi: 10.1007/s00330-013-2795-0
- 19 Roobol MJ, Steyerberg EW, Kranse R, et al. A risk-based strategy improves prostate-specific antigen-driven detection of prostate cancer. *Eur Urol* 2010;57(01):79–85. Doi: 10.1016/j.eururo.2009.08.025
- 20 Drost FH, Osses DF, Nieboer D, et al. Prostate MRI, with or without MRI-targeted biopsy, and systematic biopsy for detecting prostate cancer. *Cochrane Database Syst Rev* 2019;4(04):CD012663. Doi: 10.1002/14651858.CD012663.pub2
- 21 Ericson KJ, Wenger HC, Rosen AM, et al. Prostate cancer detection following diagnosis of atypical small acinar proliferation. *Can J Urol* 2017;24(02):8714–8720
- 22 Al-Hussain TO, Epstein JI. Initial high-grade prostatic intraepithelial neoplasia with carcinoma on subsequent prostate needle biopsy: findings at radical prostatectomy. *Am J Surg Pathol* 2011;35(08):1165–1167. Doi: 10.1097/PAS.0b013e3182206da8
- 23 Srigley JR, Merrimen JL, Jones G, Jamal M. Multifocal high-grade prostatic intraepithelial neoplasia is still a significant risk factor for adenocarcinoma. *Can Urol Assoc J* 2010;4(06):434. Doi: 10.5489/cuaj/1068
- 24 Kronz JD, Shaikh AA, Epstein JI. High-grade prostatic intraepithelial neoplasia with adjacent small atypical glands on prostate biopsy. *Hum Pathol* 2001;32(04):389–395. Doi: 10.1053/hupa.2001.23522

- 25 Szentirmai E, Giannico GA. Intraductal carcinoma of the prostate. *Pathologica* 2020;112(01):17–24. Doi: 10.32074/1591-951X-5-20
- 26 Huang G, Lebovic G, Vlachou PA. Diagnostic Value of CT in Detecting Peripheral Zone Prostate Cancer. *AJR Am J Roentgenol* 2019;213(04):831–835. Doi: 10.2214/AJR.18.21013
- 27 Li R, Ravizzini GC, Gorin MA, et al. The use of PET/CT in prostate cancer. *Prostate Cancer Prostatic Dis* 2018;21(01):4–21. Doi: 10.1038/s41391-017-0007-8
- 28 Eiber M, Weirich G, Holzapfel K, et al. Simultaneous <sup>68</sup>Ga-PSMA HBED-CC PET/MRI Improves the Localization of Primary Prostate Cancer. *Eur Urol* 2016;70(05):829–836. Doi: 10.1016/j.eururo.2015.12.053
- 29 Roach PJ, et al. The Impact of (68)Ga-PSMA PET/CT on Management Intent in Prostate Cancer.
- 30 Hofman MS, Lawrentschuk N, Francis RJ, et al; proPSMA Study Group Collaborators. Prostate-specific membrane antigen PET-CT in patients with high-risk prostate cancer before curative-intent surgery or radiotherapy (proPSMA): a prospective, randomised, multicentre study. *Lancet* 2020;395(10231):1208–1216. Doi: 10.1016/S0140-6736(20)30314-7
- 31 Roach PJ, Francis R, Emmett L, et al. The Impact of <sup>68</sup>Ga-PSMA PET/CT on Management Intent in Prostate Cancer: Results of an Australian Prospective Multicenter Study. *J Nucl Med* 2018;59(01):82–88
- 32 Buyyounouski MK, Choyke PL, McKenney JK, et al. Prostate cancer - major changes in the American Joint Committee on Cancer eighth edition cancer staging manual. *CA Cancer J Clin* 2017;67(03):245–253. Doi: 10.3322/caac.21391
- 33 Engelbrecht MR, Jager GJ, Severens JL. Patient selection for magnetic resonance imaging of prostate cancer. *Eur Urol* 2001;40(03):300–307. Doi: 10.1159/000049790
- 34 Hövels AM, Heesakkers RA, Adang EM, et al. The diagnostic accuracy of CT and MRI in the staging of pelvic lymph nodes in patients with prostate cancer: a meta-analysis. *Clin Radiol* 2008;63(04):387–395. Doi: 10.1016/j.crad.2007.05.022
- 35 Budiharto T, Joniau S, Lerut E, et al. Prospective evaluation of <sup>11</sup>C-choline positron emission tomography/computed tomography and diffusion-weighted magnetic resonance imaging for the nodal staging of prostate cancer with a high risk of lymph node metastases. *Eur Urol* 2011;60(01):125–130. Doi: 10.1016/j.eururo.2011.01.015
- 36 Tulsyan S, Das CJ, Tripathi M, Seth A, Kumar R, Bal C. Comparison of <sup>68</sup>Ga-PSMA PET/CT and multiparametric MRI for staging of high-risk prostate cancer <sup>68</sup>Ga-PSMA PET and MRI in prostate cancer. *Nucl Med Commun* 2017;38(12):1094–1102. Doi: 10.1097/MNM.0000000000000749
- 37 De Visschere PJJ, Standaert C, Fütterer JJ, et al. A Systematic Review on the Role of Imaging in Early Recurrent Prostate Cancer. *Eur Urol Oncol* 2019;2(01):47–76. Doi: 10.1016/j.euo.2018.09.010
- 38 Zhou J, Gou Z, Wu R, Yuan Y, Yu G, Zhao Y. Comparison of PSMA-PET/CT, choline-PET/CT, NaF-PET/CT, MRI, and bone scintigraphy in the diagnosis of bone metastases in patients with prostate cancer: a systematic review and meta-analysis. *Skeletal Radiol* 2019;48(12):1915–1924. Doi: 10.1007/s00256-019-03230-z