



Utility of First Dorsal Metacarpal Artery Flap for Thumb Defects

Krittika Aggarwal¹ Kuldeep Singh¹

¹Department of Burns and Plastic Surgery, Pt. Bhagwat Dayal Sharma Post Graduate Institute of Medical Sciences, Rohtak, Haryana, India

Indian J Plast Surg 2022;55:368–375.

Address for correspondence Krittika Aggarwal, MS, Mch,

Department of Plastic Surgery, Pt. Bhagwat Dayal Sharma Post

Graduate Institute of Medical Sciences, Rohtak 124001, Haryana,

India (e-mail: krittika.agga@gmail.com).

Abstract

Background Reconstruction of thumb tip, while providing a durable and sensate flap, is a challenging task. It is important as thumb accounts for 50% of hand functions. Options for coverage are: healing by secondary intention, local/regional flaps, microsurgical toe wraparound flap, etc. First dorsal metacarpal artery (FDMA) flap is one regional flap that has been used for thumb cover, usually for defects till interphalangeal joint or just distal to it. We present our case series for FDMA flap and its variations for thumb reconstruction. We also report reverse FDMA flap cover for reconstruction of defects over distal phalanx of thumb.

Methods The procedure was performed in patients with partial loss of thumb soft tissue in 16 patients presenting during 2017 to 2020. The FDMA flap was performed according to the standard technique. In case after “planning in reverse,” it was seen that the reach of FDMA flap was insufficient, reverse FDMA flap was done. Physiotherapy for index finger and thumb was started on day 10. Patient satisfaction, in terms of cosmesis and function was recorded (graded as poor, good, and very good). Static two-point discrimination (2-PD) was assessed at 6 months’ follow-up. Patients were followed up for 6 months.

Results The operative time was 1 to 2 hours. Out of total 16 cases, 8 patients underwent racquet-shaped (intact skin paddle) FDMA flap. Islanded flap was performed in five and reverse FDMA flap in three. Twelve patients had uneventful recovery and four patients (three islanded and one reverse FDMA) had partial skin loss. Static 2-PD was assessed at the 6 months postoperative period.

Conclusion FDMA flap is a useful regional flap for thumb reconstruction. It provides good supple, durable, and sensate cover. The reverse FDMA flap that increases the pedicle length can be used for more distal defects, where conventional FDMA flap is doubtful.

Keywords

- ▶ reconstruction
- ▶ FDMA
- ▶ thumb
- ▶ flap

Introduction

Opposable thumb is a distinct characteristic which separates us from lower animals. Thumb constitutes approximately

50% of the hand function. Loss of thumb or any defect which renders it nonfunctional is debilitating, may even result in change of work. First dorsal metacarpal artery (FDMA) flap is

article published online
December 22, 2022

DOI <https://doi.org/10.1055/s-0042-1759500>.
ISSN 0970-0358.

© 2022. Association of Plastic Surgeons of India. All rights reserved. This is an open access article published by Thieme under the terms of the Creative Commons Attribution-NonDerivative-NonCommercial-License, permitting copying and reproduction so long as the original work is given appropriate credit. Contents may not be used for commercial purposes, or adapted, remixed, transformed or built upon. (<https://creativecommons.org/licenses/by-nc-nd/4.0/>)

Thieme Medical and Scientific Publishers Pvt. Ltd., A-12, 2nd Floor, Sector 2, Noida-201301 UP, India

a time-tested option which is widely used for thumb cover. It was introduced by Foucher and Braun in 1979 for cover of thumb for partial tissue loss.¹ FDMA flap is based on ulnar branch of FDMA. FDMA arises from the radial artery just distal to the extensor pollicis longus tendon, before the artery dives between the two heads of the first dorsal interosseous muscle. The diameter of FDMA varies from 1.2 to 1.5 mm. More than one accompanying veins can be found during dissection. Usually, the artery runs superficial to the fascia of first dorsal interosseous muscle and divides into three terminal branches: radial branch, ulnar branch, and intermediate branch. The radial branch runs along the thumb metacarpal and becomes or anastomoses with the dorsoulnar artery. The ulnar branch runs along the index metacarpal up to the metacarpophalangeal (MCP) joint, giving branches to the periosteum and adjacent extensor tendons. It terminates in a plexus over the dorsal fascia of the index finger. It can be used for volar and dorsal defects. Various modifications have been suggested for various types of defect such as extended FDMA,² reverse FDMA,³ and bilobed FDMA.⁴ It has been also used for defects over dorsum of hand.⁵ We report our experience with FDMA flap for reconstruction of partial tissue loss of thumb soft tissue in 16 patients. The article also highlights reverse FDMA flap borne out of need for flap for thumb tip defects.

Methods

The procedure was performed in partial tissue loss of thumb soft tissue in 16 patients over a time period of 2017 to 2020. It was performed under loupe magnification with regional block and tourniquet control. All the patients were in the age group of 25 and 50 years. Demographic details, cause of tissue loss (traumatic, electric/thermal burn, malignancy), its extent, presence of bony injury, and presence of any comorbidity were noted. Only patients with isolated digital injuries were included in the study. Contraindications were defects at the proximal or distal phalanx which can be closed primarily or by advancement of local tissue and previous injury at the second metacarpal level.

Preoperative photographs were taken. The flap was performed by standard technique as described below. In case, after "planning in reverse"⁶ it was seen that the reach of FDMA flap was insufficient, reverse FDMA flap was done. Donor site over index finger was grafted, usually with full-thickness graft that was harvested from volar wrist crease. Dressing was changed on day 3 and sutures were removed on day 10. Physiotherapy for index finger and thumb was started on day 10. Patient satisfaction, in terms of cosmesis and function was recorded (graded as poor, good, and very good). Patients were followed up for 6 months. Static two-point discrimination (2-PD) was assessed at 6 months' follow-up.

Surgical Technique

After inflating the tourniquet, the raw area over thumb is debrided. The size of the flap required is measured and "planning in reverse"⁶ is done. The flap of appropriate size

is marked over the dorsal aspect of proximal phalanx of index finger with maximum limits of dorsolateral on sides, and proximal interphalangeal (PIP) and MCP joint creases distally and proximally, respectively. The pedicle of the flap (along with skin extension) is marked from the second MCP joint to the apex of first web space along the axis of second metacarpal in racquet-shaped flaps. Skin over the pedicle helps increase the venous drainage and is approximately 3 to 5 mm in width. The flap is raised from distal to proximal in the areolar plane above the extensor paratenon. Small part of radial extensor hood is included in the flap. At the level of neck of the second metacarpal, the flap is raised subperiosteally from ulnar to radial side. The fascia is released from the metacarpal at the osseofascial groove and entire interosseous fascia over the first dorsal interosseous along with subcutaneous tissue, superficial veins, and branches of superficial radial nerve are included in the flap. Superficial branch of radial nerve was always included in the flap. Skin incision is made on the thumb to allow flap inseting, which is then closed primarily. Donor site over dorsum of hand is closed primarily. Full-thickness graft from wrist crease is used for coverage of proximal phalanx of index finger.

Islanded FDMA flap: The flap of appropriate size is marked over the proximal phalanx of index finger. Another incision extending from second MCP joint to apex of first web space is marked. The dissection is started ulnarly and distally preserving the paratenon. A lazy S incision is made parallel to the radial border of the second metacarpal and fascial strip containing pedicle is harvested with the flap. The dissection stops at the apex of first web space. Incision is made on the thumb to allow inseting which is then closed over the pedicle. Donor site defect is covered with full-thickness graft from volar wrist crease.

Reverse FDMA flap: After raising the flap till apex of first web space, dissection is done and branches of FDMA, that is, radial, intermediate, and ulnar are visualized. To increase the reach of the flap, branches are ligated and cut as close as from their origin from radial artery and flap is based toward first metacarpal.⁴ The presence of vascular network between the three branches of FDMA at origin from radial artery has been confirmed.³ There is reverse flow in the flap through deep communications of radial branch of FDMA and princeps pollicis artery. Hence, the flap is raised on radial and ulnar branch of FDMA. ► **Fig. 1A** shows the details of site of ligation of FDMA and communication between FDMA radial branch and branches of princeps pollicis artery. ► **Fig. 1B** shows the diagrammatic representation of the reverse FDMA flap raised on radial and ulnar branches. It is raised as a racquet-shaped flap. The radial branch is preserved with flap as seen with skin everted in ► **Fig. 1B**. Skin incision is made on the thumb for flap inseting. Donor site defect is covered with full-thickness graft from volar wrist crease.

Results

The relevant details of the patients who underwent the procedure are shown in ► **Table 1**. The operative time ranged between 1 and 2 hours (mean 1.5 hours with standard

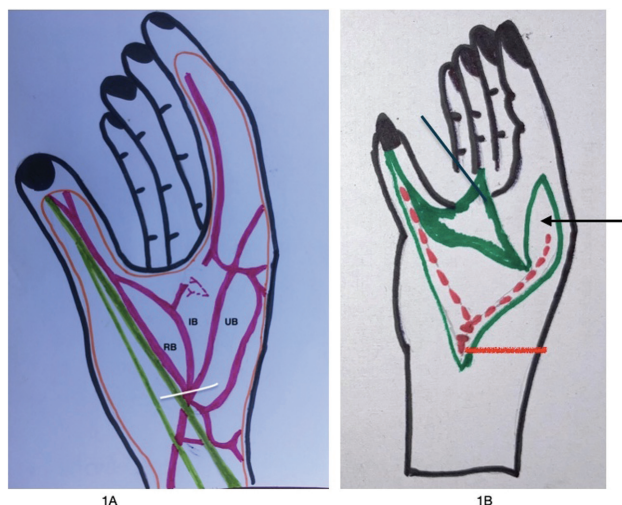


Fig. 1 (A) Schematic diagram showing the branches and course of first dorsal metacarpal artery. White line shows the site of ligation of first dorsal artery for reverse first dorsal metacarpal artery (FDMA) flap. (B) Illustration for flap raised on radial and ulnar branch of first dorsal metacarpal artery. Black arrow shows flap raised and red arrow shows ligated FDMA.

deviation of 0.5). Out of total 16 cases, 8 patients underwent racquet-shaped FDMA flap. Islanded flap was performed in five and reverse FDMA flap in three. Twelve patients had uneventful recovery and four patients (three islanded and one reverse FDMA) had partial skin loss. The flap survival in islanded and racquet-shaped flaps was compared and was found to be statistically significant (p -value = 0.0035). In case of islanded flaps the distal full-thickness necrosis of the flap ranged from 20 to 50% and 16% for reverse FDMA flap. It was managed with debridement, dressings, and they subsequently healed with secondary intention. In one patient with partial loss of islanded FDMA flap, split skin grafting was done. Static 2-PD was assessed at 6 months postoperatively. It was found better in racquet-shaped flaps, that is, 6.5 mm (mean) versus 10 mm (mean) in islanded flaps (p -value of 0.004 using Mann-Whitney U test). Patient satisfaction was very good in 11 patients and good in 3 patients. Most of the patients were satisfied with cosmetic appearance of the scar and function of the index finger and thumb (87.5%). Most of the patients were able to return to work after 2 months. No one had to change their jobs. In one patient (case 6) stiffness of interphalangeal joint was noted due to joint fusion. Poor satisfaction was seen in two patients who had postoperative partial flap loss. In one patient with reverse FDMA flap done first web contracture was noted, at the base of flap pedicle. This was managed by Z plasty done 4 months after first surgery. No donor site morbidity was noted.

Case 6

A 40-year-old lady presented with wound over right middle finger and right thumb near interphalangeal joint on the dorsal aspect. The distal phalanx of the thumb showed nail bed injury and osteomyelitis bone. The injury was 2 months old following low voltage electric burn. Preoperative photographs are shown in ►Fig. 2. Scar over middle phalanx of

middle finger can be noted. The patient was planned for debridement and racquet-shaped FDMA flap for thumb and cross-finger flap from index finger for middle finger. ►Fig. 3 shows intraoperative photographs while raising the flap and immediate postoperative photographs. Flap survival was 100%. ►Fig. 4 shows postoperative photographs at 3 months. ►Fig. 5 shows result at 9 months.

Case 8

A 30-year-old male patient presented with postinfective raw area over palmar aspect of proximal phalanx of thumb. It was noted that the underlying bone was exposed. Racquet-shaped FDMA flap was planned. Preoperative photographs are as shown in ►Fig. 6. ►Fig. 7 shows full flap survival. ►Fig. 8 shows good aesthetic and functional result at 3 weeks.

Case 16

A 38-year-old lady presented with nonhealing wound for 2 months over distal phalanx of thumb following electric burn with distal phalanx bone exposed. She also had amputation of index finger just proximal to the PIP joint. After “planning in reverse” it was seen that FDMA flap could not reach till the defect on distal phalanx. Hence, reverse FDMA flap was planned. Figure shows preoperative photographs. Intraoperative photograph showing FDMA artery (marked by black arrow) is shown in ►Fig. 9. ►Fig. 10 shows complete flap survival with acceptable donor site healing.

Discussion

FDMA flap was introduced by Foucher and Braun in 1979 for cover of thumb for partial tissue loss.¹ Subsequently, various articles have reported the applied anatomy of FDMA and its applications.^{3,7,8} The FDMA arises from the radial artery just distal to the extensor pollicis longus tendon, before the artery dives between the two heads of the first dorsal interosseous muscle. The FDMA diameter varies from 1.2 to 1.5 mm. More than one accompanying veins can be found during dissection. Usually, the artery runs superficial to the fascia of first dorsal interosseous muscle and divides into three terminal branches: radial branch, ulnar branch, and intermediate branch. The radial branch runs along the thumb metacarpal and becomes or anastomoses with the dorsoulnar artery. The dorsoulnar artery originates from the princeps pollicis through a perforating branch at the level of the neck of the first metacarpal bone. The radial branch can be suprafascial or subfascial. The ulnar branch runs along the index metacarpal up to the MCP joint, giving branches to the periosteum and adjacent extensor tendons. It terminates in a plexus over the dorsal fascia of the index finger. The intermediate branch runs toward the first web space and anastomoses with branches from the other two.^{3,7,8}

FDMA flap can be raised as islanded or racquet-shaped flap. We noted that islanded flaps have high chances of necrosis, probably due to venous congestion. The difference in flap survival in these groups was statistically significant. The presence of skin extension in racquet-shaped flap is

Table 1 Relevant details of all the patients

Serial No.	Age	Sex	Cause of tissue loss	Site of defect	Size of defect	Associated comorbidities	Procedure/flap	Complications	Patient satisfaction	Two-point discrimination at 6 mo (mm)
1	20	M	Traumatic amputation	Proximal phalanx	2 × 2 cm	–	Islanded FDMA		Very good	9
2	30	M	Electric burn	Exposed IP joint	2 × 2.5 cm	–	Islanded FDMA	Necrosis of distal 20%-healed by secondary intention	Poor	12
3	27	M	Traumatic amputation	Proximal phalanx	2 × 2 cm	–	Islanded FDMA		Very good	8
4	40	M	Crush injury	Proximal phalanx	3 × 2 cm	–	Islanded FDMA	Necrosis of distal 50%-SSG done	Poor	10
5	45	M	Electric burn	Dorsum of proximal phalanx	3 × 3 cm	–	Racquet-shaped FDMA		Good	6
6	40	F	Electric burn	IP joint dorsal aspect and middle phalanx of middle finger	3 × 2 cm for thumb, 3 × 2.5 cm for middle finger	–	Racquet-shaped FDMA with cross-finger flap for middle finger	IP joint stiffness	Very good	7
7	30	F	Post infective	Proximal phalanx	3 × 3 cm	–	Racquet-shaped FDMA		Very good	6
8	30	M	Post infective	Proximal phalanx	4 × 3.5 cm	–	Racquet-shaped FDMA	–	Very good	6
9	50	F	Electric burn with distal phalanx gangrene	Interphalangeal joint	2 × 2 cm	–	Islanded FDMA	Necrosis of distal 20%-healed by secondary intention	Good	9
10	26	M	Crush injury	Proximal phalanx	2 × 2.5 cm	–	Racquet-shaped FDMA		Very good	7
11	36	M	Traumatic	Proximal phalanx	3 × 2.5 cm	–	Racquet-shaped FDMA		Very good	6
12	50	M	Traumatic	Dorsum of proximal phalanx	3 × 3 cm	–	Racquet-shaped FDMA		Very good	7
13	30	F	Crush injury	Distal phalanx	2 × 2.5 cm	–	Reverse FDMA	–	Very good	9
14	28	M	Crush injury	Interphalangeal joint	2 × 2 cm	–	Racquet-shaped FDMA		Very good	7
15	40	M	Electric burn	Distal phalanx	4 × 2 cm	–	Reverse FDMA	Necrosis of distal 16%-healed by secondary intention	Good	10
16	38	F	Electric burn	Distal phalanx	3 × 3 cm	–	Reverse FDMA	–	Very good	10

Abbreviations: F, female; FDMA, first dorsal metacarpal artery; IP, interphalangeal; M, male; SSG, split skin graft.

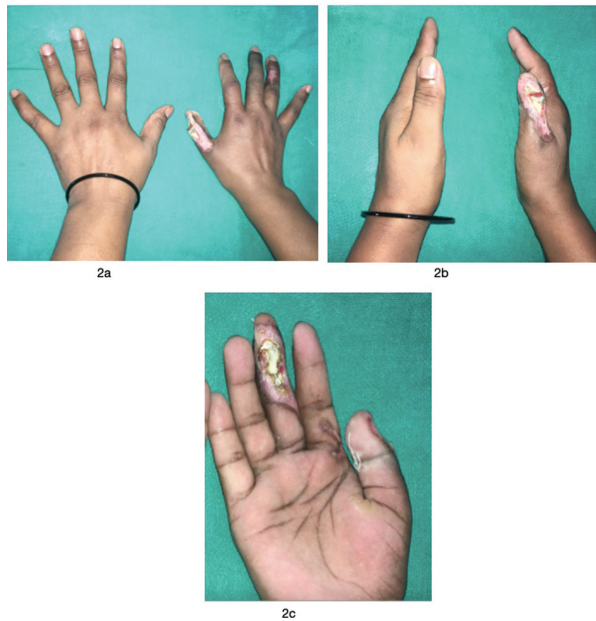


Fig. 2 Preoperative photographs showing defect over right thumb interphalangeal joint dorsal aspect with involvement of nail (A, B) and middle phalanx of middle finger (C) with scarring over dorsum of ring finger for case 6.

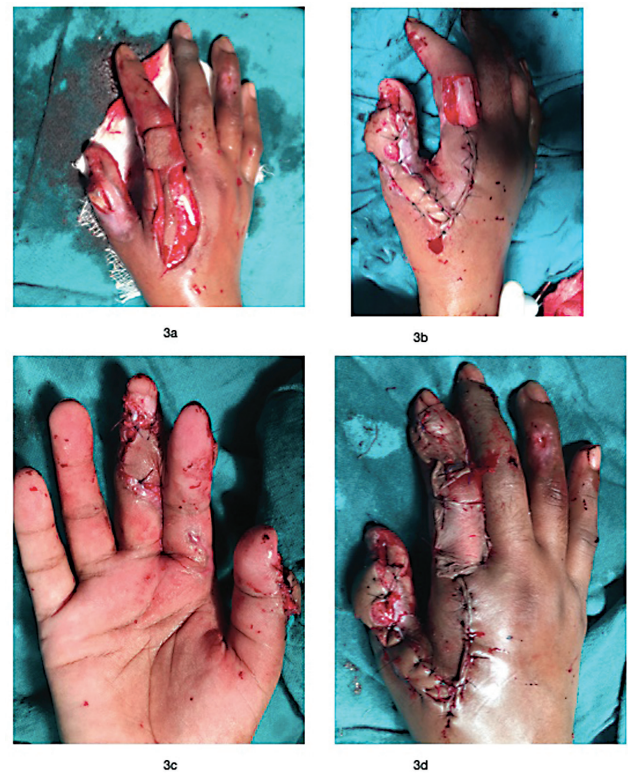


Fig. 3 Intraoperative photographs showing raised racquet-shaped first dorsal metacarpal artery (FDMA) flap in (A). (B) Insetting of FDMA flap over thumb dorsum and split skin graft (SSG) from volar wrist over flap donor site as shown in (C). Cross-finger flap was raised from index finger for middle finger as shown in (D) for case 6.

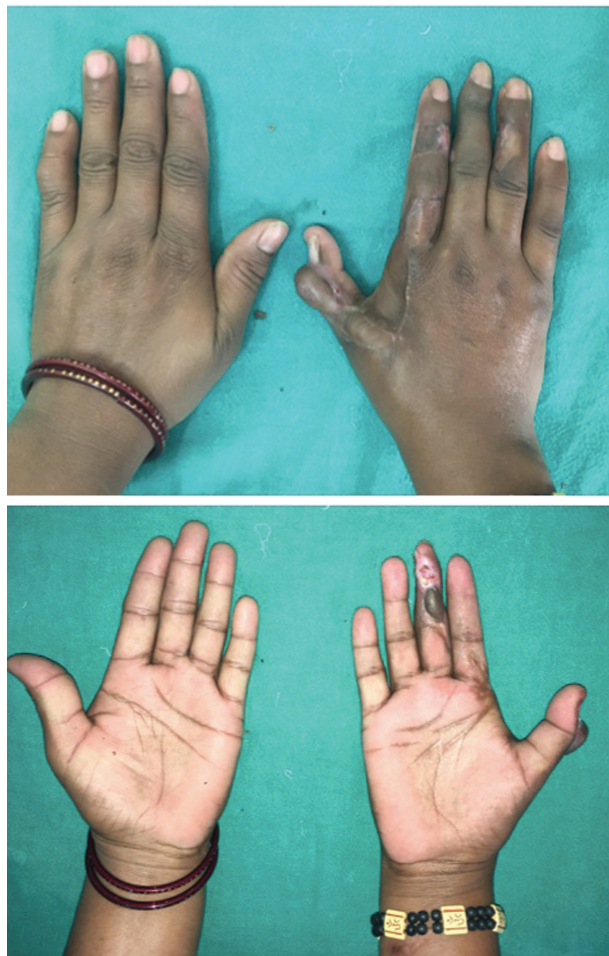

Fig. 4 Postoperative photographs at 3 months for case 6 showing full flap survival, both racquet-shaped first dorsal metacarpal artery (FDMA) flap and cross-finger flap, good functional and cosmetic results.



Fig. 5 Postoperative photographs at 9 months for case 6 showing full flap survival, both racquet-shaped first dorsal metacarpal artery (FDMA) flap and cross-finger flap, good functional and cosmetic results.

thought to preserve superficial veins, help in venous drainage, and so in flap survival, that is seen in our study. This is supported by previous studies as well.⁴

During follow-up it was also noted that there is a significant difference in the static 2-PD in islanded and racquet-shaped FDMA flap. After searching the literature no study comparing 2-PD between these was found. We hypothesize that presence of skin paddle over the pedicle in racquet-shaped flap helps improve sensations and 2-PD. However, further studies are needed to prove it.

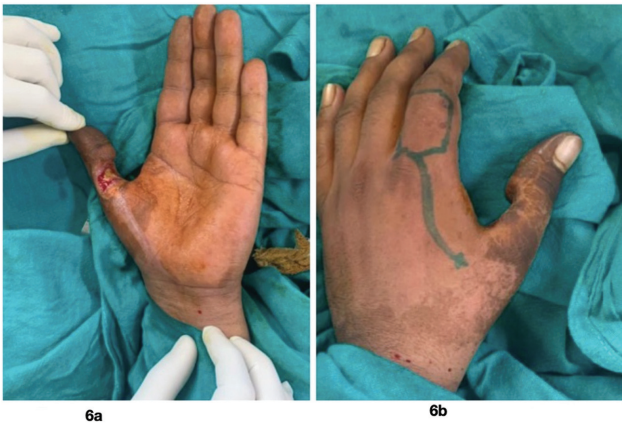

Fig. 6 Preoperative photograph showing defect in (A) and (B) shows flap planning for case 8.

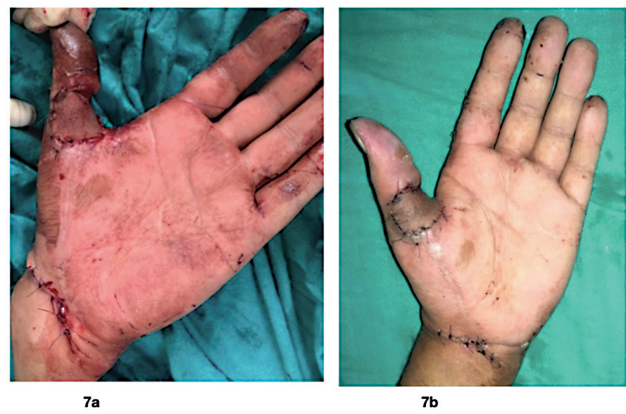


Fig. 7 Immediate photograph shown in (A) and (B) shows postoperative result at day 7 for case 8.

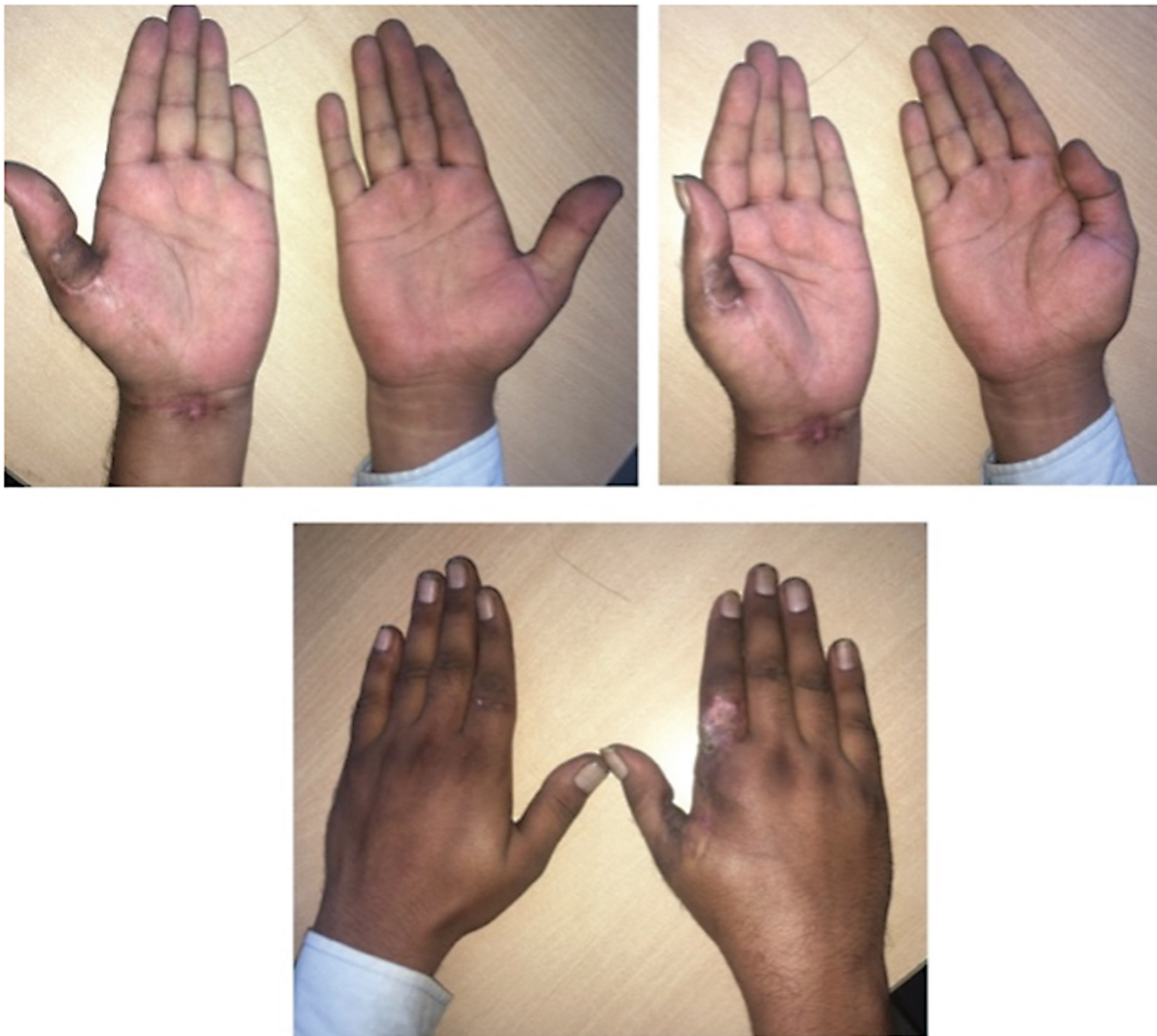

Fig. 8 (A–C) Postoperative photographs for case 8 at 3 weeks showing good flap mobility and acceptable donor site scar.

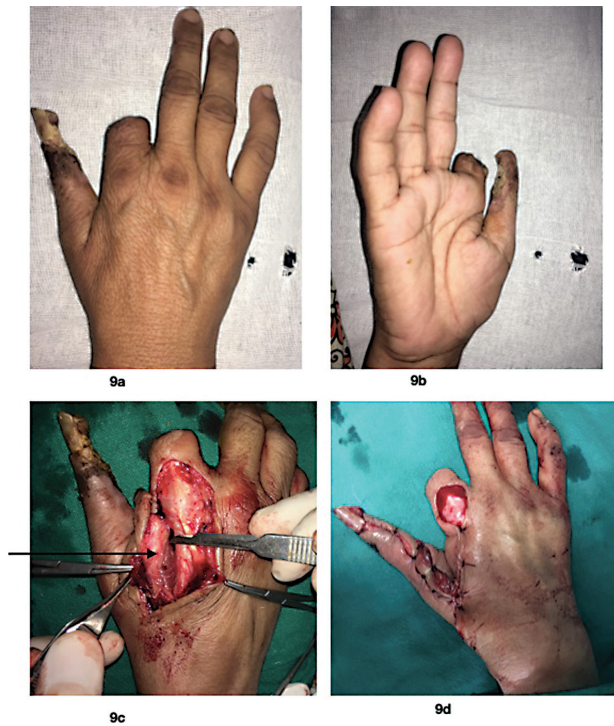

Fig. 9 Preoperative photographs shown in (A) and (B) for case 16. Reverse first dorsal metacarpal artery (FDMA) flap was raised. (C) First dorsal metacarpal artery marked with black arrow. (D) Flap inseting.

FDMA flap is mainly used for defects as far as interphalangeal joint of thumb.⁹ In three of our patients, the defect was present over distal phalanx of thumb and one patient had amputation of index finger just proximal to PIP. After “planning in reverse,” we noted that the FDMA flap could not sufficiently reach the defect. Hence, reverse FDMA flap was planned and two patients had uneventful recovery with good, supple flap. Various authors have documented the utility of reverse FDMA flap for distal phalangeal defects of thumb.^{3,10}

Moberg advancement flap is a known option for distal thumb defects but the advancement gained is only 1 to 1.5 cm. Moreover, it may lead to interphalangeal joint contracture in case of large defects. FDMA flap provides soft, pliable, and sensate skin cover for thumb defect with minimal donor site morbidity.^{11,12} However, in case of injury over anatomical snuffbox it cannot be used. It leaves a scar over the dorsum of hand which was acceptable to most patients in our study.

FDMA has been compared with Littler neurovascular flap for thumb defects.¹³ It was seen that the dissection for FDMA flap was faster and easier as compared with Littler flap. The authors reported that Littler flap resulted in better sensibility and tactile gnosis of the reconstructed thumb-pulp but FDMA flap ensured negligible donor site morbidity, complete cortical reorientation, and better overall hand function.¹³

To decrease scar over index finger, Chi et al used second dorsal metacarpal flap to cover donor defect.¹⁴

Limitation

The small sample size is the main drawback of the study. Follow-up longer than 1 year would provide more accurate

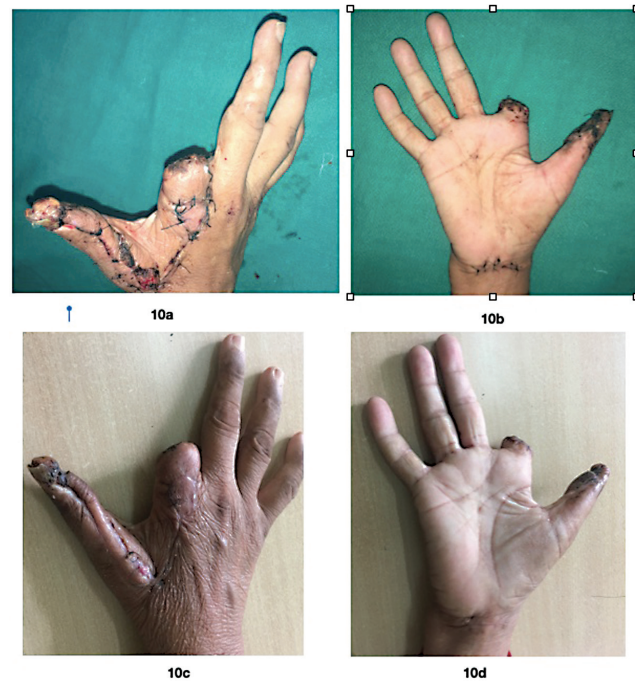


Fig. 10 Postoperative photographs for case 16 on day 5 as seen in (A) and (B). (C and D) Results at 1 month.

static 2-PD which can then be compared between flaps. Complete cortical reorientation occurs in 2 years. This could not be assessed in our study due to short follow-up.

Conclusion

FDMA flap is a useful regional flap for thumb reconstruction. It provides good supple, durable, and sensate cover. The reverse FDMA that increases the pedicle length can be used for more distal defects, where conventional FDMA reach is doubtful. In our opinion, the use of FDMA can be done as racquet shape to ensure survival and overall better outcomes. We also recommend the inclusion of periosteum over the second metacarpal and elevation of fascia at osseofascial groove to ensure the inclusion of ulnar branch of FDMA as recommended previously as well.¹⁵

Conflict of Interest

None declared.

References

- 1 Foucher G, Braun JB. A new island flap transfer from the dorsum of the index to the thumb. *Plast Reconstr Surg* 1979;63(03):344–349
- 2 El-Khatib HA. Clinical experiences with the extended first dorsal metacarpal artery island flap for thumb reconstruction. *J Hand Surg Am* 1998;23(04):647–652
- 3 Checucci G, Galeano M, Zucchini M, Zampetti PG, Ceruso M. Reverse flow first dorsal metacarpal artery flap for covering the defect of distal thumb. *Microsurgery* 2014;34(04):283–286
- 4 Couceiro J, de Prado M, Menendez G, Manteiga Z. The first dorsal metacarpal artery flap family: a review. *Surg J (NY)* 2018;4(04):e215–e219
- 5 Shehata Ibrahim Ahmed M, Salah Ibrahim E, Ibrahim Eltayeb H. Evaluation of versatility of use of island first dorsal metacarpal

- artery flap in reconstruction of dorsal hand defects. *Asian J Surg* 2019;42(01):197–202
- 6 McGregor AD, McGregor IA. *Fundamental Techniques of Plastic Surgery and Their Surgical Applications*. 10th ed. Philadelphia: Churchill Livingstone; 2000:72
 - 7 Brunelli F. Le lambeau dorso-cubital du pouce. Anatomic basis for the dorsal radial flap of the thumb: clinical applications. *Ann Chir Main* 1993;12:105–114
 - 8 Brunelli F, Gilbert A. Vascularization of the thumb. Anatomy and surgical applications. *Hand Clin* 2001;17(01):123–138
 - 9 Slutsky DJ. First dorsal metacarpal artery flap. In: Slutsky DJ, ed. *The Art of Microsurgical Hand Reconstruction*. New York: Thieme Publishing Group; 2013:59–66
 - 10 Luan Z, Liu B, Jiang H, Gao F, Yang B. Reverse first dorsal metacarpal artery flap repair of a right thumb epidermis granuloma: a case study. *Oncol Lett* 2019;18(03):2384–2387
 - 11 Wang H, Chen C, Li J, Yang X, Zhang H, Wang Z. Modified first dorsal metacarpal artery island flap for sensory reconstruction of thumb pulp defects. *J Hand Surg Eur Vol* 2016;41(02):177–184
 - 12 Chang SC, Chen SL, Chen TM, Chuang CJ, Cheng TY, Wang HJ. Sensate first dorsal metacarpal artery flap for resurfacing extensive pulp defects of the thumb. *Ann Plast Surg* 2004;53(05):449–454
 - 13 Delikonstantinou IP, Gravvanis AI, Dimitriou V, Zogogiannis I, Douma A, Tsoutsos DA. Foucher first dorsal metacarpal artery flap versus littler heterodigital neurovascular flap in resurfacing thumb pulp loss defects. *Ann Plast Surg* 2011;67(02):119–122
 - 14 Chi Z, Lin D, Chen Y, et al. Routine closure of the donor site with a second dorsal metacarpal artery flap to avoid the use of a skin graft after harvest of a first dorsal metacarpal artery flap. *J Plast Reconstr Aesthet Surg* 2018;71(06):870–875
 - 15 Muyldermans T, Hierner R. First dorsal metacarpal artery flap for thumb reconstruction: a retrospective clinical study. *Strateg Trauma Limb Reconstr* 2009;4(01):27–33