



# Unstimulated Gluteus Maximus Sphincteroplasty for Bowel Incontinence

Thalavirithan Margabandu Balakrishnan<sup>1</sup> Snigdha Yanamadala<sup>1</sup> Jaganmohan Janardhanam<sup>1</sup>

<sup>1</sup>Department of Plastic, Reconstructive and Faciomaxillary Surgery, Madras Medical College, Chennai, Tamil Nadu, India

Indian J Plast Surg 2023;56:22–30.

Address for correspondence T. M. Balakrishnan, MBBS, MS (Gen Surg), FRCS (E), DNB (Gen Surg), DNB (Plastic surg), MCh (Plastic Surg), old no. 15/ New no. 10. Thiruvalluvar Street, Kodambakkam, Chennai 600024, Tamil Nadu, India (e-mail: thalavirib@gmail.com).

## Abstract

**Background** Gluteus maximus, by virtue of its continued adjunct contraction with the anal sphincter, has many characteristics and histomorphological features mimicking type I musculature. Hence, anal sphincter replacement therapy with gluteus maximus has all avenues for lasting successful results. This study aimed to evaluate the efficiency of unstimulated gluteus maximus sphincteroplasty for anal incontinence reconstruction and neosphincter reconstruction in perineal colostomy cases.

**Methods** From March 2015 to March 2020, the records of patients who underwent gluteus maximus sphincteroplasty for fecal incontinence were analyzed in this retrospective cohort study. The mean age was 31.55 years. Eleven patients (females = 4, males = 7) underwent anal incontinence reconstruction. All these cases were followed up for an average period of 28.46 months.

**Results** Good continence was observed in all patients with an average Cleveland Clinic Florida Faecal Incontinence Score of 3.18 ( $p = 0.0035$ ). At the end of the follow-up period, the average median resting pressure found via manometry was 44.64 mm Hg, and the average median squeeze pressure was 103.55 mm Hg. The mean of the average continence contraction time at the end of the follow-up period was found to be 3.64 minutes. None of our patients had complete continence failure. None of our patients used perineal pads or made any lifestyle alterations at the end of the follow-up period. Most of the patients expressed satisfactory continence.

**Conclusion** Despite being untrained with implantable electrodes, the gluteus maximus muscle produced very good continence results with our way of construct. In addition, with its good lumen occluding effect, it achieves good resting and squeeze anal pressure around the anal canal/bowel with trivial reeducation. Hence, it has become our institution's procedure of choice for anal sphincter reconstruction.

## Keywords

- ▶ sphincteroplasty
- ▶ anal incontinence
- ▶ gluteus maximus sphincteroplasty

## Introduction

Fecal incontinence is a devastating condition in which patients have an inferior quality of life. They live with difficulty in social interaction, daily physical activity, and employment. It is

defined as the recurrent uncontrolled involuntary passage of fecal material for at least 1 month in an individual with a developmental age older than 4 years.<sup>1</sup> Despite using medical therapies such as motility inhibitors, stool-bulking agents,

article published online  
December 30, 2022

DOI <https://doi.org/10.1055/s-0042-1759499>.  
ISSN 0970-0358.

© 2022. Association of Plastic Surgeons of India. All rights reserved. This is an open access article published by Thieme under the terms of the Creative Commons Attribution-NonDerivative-NonCommercial-License, permitting copying and reproduction so long as the original work is given appropriate credit. Contents may not be used for commercial purposes, or adapted, remixed, transformed or built upon. (<https://creativecommons.org/licenses/by-nc-nd/4.0/>)  
Thieme Medical and Scientific Publishers Pvt. Ltd., A-12, 2nd Floor, Sector 2, Noida-201301 UP, India

biofeedback, and Kegel exercises, these interventions may only provide limited relief from this disabling condition.<sup>2</sup> Injury to the anal sphincter may be due to trauma, obstetrical injury, or iatrogenic rectal surgery, and therefore, the sphincter may be amenable to primary repair or secondary surgical reconstruction. If there is a combined loss of nerve supply and sphincter, gracilis or gluteus maximus sphincteroplasty is the preferred reconstruction method.<sup>3</sup> Gluteus maximus muscle acts synchronously with the external anal sphincter in the process of defecation. It has acquired nonfatigable characters during the evolution of human beings on assuming the erect posture. It has many characteristics resembling those of type I striated musculature.<sup>4</sup> Gluteus maximus sphincteroplasty, given a sufficient quantity of muscle cuff, provides good lumen occlusion. This enables continence for formed and fluid stool. Keeping these considerations in mind, this procedure has excellent potential for satisfactory results. Our study aimed to evaluate the efficiency of unstimulated gluteus maximus sphincteroplasty for anal incontinence reconstruction and neosphincter reconstruction.

## Materials and Methods

Institutional ethical committee approval was obtained for this clinical study. This retrospective cohort study was conducted in cases undergoing gluteus maximus sphincteroplasty for neo sphincter reconstruction in perineal colostomy cases ( $n = 2$ ) or anal incontinence reconstruction ( $n = 9$ ) from March 2015 to March 2020 in 11 patients. All patients had a history of severe fecal incontinence. All of them had native sphincter loss confirmed by preoperative magnetic resonance imaging (MRI). This treatment group included four females and seven males, who underwent gluteus maximus sphincteroplasty and had various etiopathogenesis (–Table 1) for bowel incontinence. Patients with amyotrophic lateral sclerosis, severe scarring of bilateral gluteus maximus region, and pelvic fracture with documentable injury to internal iliac vessels were not taken up for this procedure. The age of the patients varied from 15 to 48 years. The average follow-up period was 28.46 months. They were subjected to manometric studies post surgery till the end of the follow-up period. Patients with severe fecal incontinence refractory to medical therapy underwent preoperative assessment by a multidisciplinary team that included members from surgical and medical gastroenterology, urogynecology, and plastic surgery. The preoperative evaluation involved a combination of sigmoidoscopy, pudendal nerve studies (in appropriate cases), clinical assessment of gluteus maximus muscle nutrition and power, and MRI abdomen and pelvis. The information obtained was used to identify operative candidates who had a good capacitance of the rectal vault, intact sensation of the rectum, and favorable anatomy for transposition of the gluteus maximus muscle. Patients were informed about the details of the procedure and its possible complications in detail, and written consent was taken. Temporary diversion colostomy was done in appropriate cases planned for surgery. All patients were taught to contract their gluteus maximus muscle on both sides, simulating the continence control maneuvers.

Under sterile aseptic precautions, under general anesthesia, the patient was transferred to prone Jackknife position, and all pressure points were adequately padded. A sigmoid incision was marked over the inferior third of the gluteus maximus muscle, close to the infra gluteal crease, starting 5 cm lateral to the anal verge, extending toward the greater trochanter of the Femur. The second incision was marked on the contralateral side perirectal area to enable exposure of the ischial tuberosity. Only the lower one-third of the muscle flap, with intact medial attachment, was divided from its insertion laterally to the iliotibial tract and gluteal tuberosity, with a carefully preserved neurovascular pedicle of the inferior gluteal artery and nerve. Type II Taylor's pattern<sup>5</sup> of inferior gluteal innervation facilitated intraneural dissection toward its point of emergence from the greater sciatic foramen, inferior to the piriformis muscle. The pedicle was dissected from its loose attachment to the sciatic nerve to avoid traction during the transposition of the muscle. Care was taken to include the full thickness of the muscle as the neurovascular bundle enters the muscle on its anterior surface. Care was exercised to avoid damage to the posterior cutaneous nerve of thigh and the sciatic nerve. The second incision was made over the contralateral ischial tuberosity. Subcutaneous tunnels were created around the anal canal using blunt and sharp dissections, avoiding perforation. This blind dissection above and below the anal canal, two fingers wide, was performed as closely as possible to the anorectal mucosa to ensure that the muscle would have a lumen-occluding effect. The muscle end was divided into two symmetrical strips along the direction of the muscle fibers (division stopped before the neurovascular hilum). Both the strips were guided into the tunnel, crisscrossed, and stretched around the anal canal. This arrangement produced an S-shaped curvature at the anorectal junction, establishing a reformation of the anorectal angle. The resting tension was achieved intraoperatively with good gripping of the assistant's finger placed in the anal canal or the perineal colostomy opening. On the contralateral side, the muscle ends were sutured over each other and then to the periosteum of the ischial tuberosity with 2–0 polypropylene suture material, just below the Alcock's canal. Hemostasis was secured. A closed suction drain was placed in situ, and closure of both sides was done in layers. In one of the cases, the patient had B/L isolated pudendal neuropathy with atrophy of the ischial pad of fat on both sides. The same procedure was done with transposition of bilateral gluteus muscle, with inset given over contralateral ischial tuberosities.

Postoperatively, the prophylactic antibiotic cover was given for 10 days. Patients were allowed to ambulate postoperatively after 24 hours. Patients were advised to start their gluteus maximus contraction exercises simulating continent control maneuvers from the 10th postoperative day. The training was given using a biofeedback mechanism for those who had difficulty initiating or sustaining contraction. Four to eight weeks later, after objective confirmation of squeeze pressure, the covering colostomy was taken down. Patients were taken up for high-resolution anal manometric assessment 6 months post surgery for the first visit, a year

**Table 1** Patient demographic data

S. No	Age/sex	Etiology	Type of gluteus maximus sphincteroplasty	Complications	Follow-up period (mo)	High-resolution manometry readings at the end of follow-up (mm Hg)		Average continence contraction time at the end of follow-up period (min)	CCFFIS at the end of follow-up
						Basal Pressure	Squeeze Pressure		
1	27/M	Posttraumatic with pull through perineal colostomy	Unilateral	Seroma	20	48	102	4	2
2	40/M	Postanorectal surgery	Unilateral	Wound infection	36	42	100	2	5
3	29/F	Obstetric trauma	Unilateral	Nil	45	50	104	4	2
4	15/M	Postanorectal malformation correction surgery	Unilateral	Nil	35	40	101	3.5	2
5	45/M	Posttraumatic	Unilateral	Nil	26	45	105	4.5	2
6	22/M	Following surgery for recurrent fistula in ano	Unilateral	Nil	16	40	107	2.5	3
7	30/F	Obstetric trauma	Unilateral	Numbness in posterior aspect of thigh	32	48	101	6	2
8	20/M	Isolated Pudendal neuropathy	Bilateral	Nil	28	40	112	2.5	4
9	48/F	Posttraumatic with pull through perineal colostomy	Unilateral	Minimal mucosal collapse through perineal colostomy	20	45	102	4	4
10	26/F	Obstetric trauma	Unilateral	Nil	25	51	105	5	2
11	45/M	Posttraumatic perineal injury	Unilateral	Nil	30	42	100	2	7

Abbreviations: CCFFIS, Cleveland Clinic Florida Faecal Incontinence Score; F, female; M, male.

after surgery for the second visit, and then once every year till the end of the follow-up period. At the end of follow-up transanorectal ultrasound and MRI also assessed the mass of transposed gluteal muscle sling. Patient satisfaction was calculated at the end of the follow-up period by Cleveland Clinic Florida Faecal Incontinence Score (CCFFIS)<sup>6</sup> (► **Table 1**). A score between 0 and 7 was considered a measure of good continence.

### Illustration of Case 1

This is a case of a 15-year-old boy with atrophy of the anal musculature secondary to correction surgeries for his anorectal malformations. He had severe anal incontinence with a patulous anal canal (► **Fig. 1A–C**). However, perianal sensations were intact. He was taught gluteus maximus contraction continence control maneuvers preoperatively. Unilateral unstimulated gluteus maximus sphincteroplasty was performed (► **Figs. 1 and 2**). The follow-up period was for 35 months. There were no complications postoperatively. At the end of the follow-up, the transanorectal ultrasound revealed good transposed gluteal muscle sling (► **Fig. 3**). At the end of the follow-up period, his median resting anal pressure was 40 mm Hg, and median anal squeeze pressure was 101 mm Hg as measured by high-resolution anal manometry (► **Supplementary Video 1**, online only). His CCFFIS at the end of the follow-up period was 2. He had one episode of incontinence for liquid stool in a month. He maintained good, sustained contraction of the anal canal for an average period of 3.5 minutes at the end of the study period (► **Supplementary Video 2**, online only).

#### Supplementary Video 1

High-resolution anal manometric reading with good squeeze pressure in case 1. Online content including video sequences viewable at: <https://www.thieme-connect.com/products/ejournals/html/10.1055/s-0042-1759499>.

#### Supplementary Video 2

Assessment of postoperative sustained muscle contraction around the anal canal in case 1. Online content including video sequences viewable at: <https://www.thieme-connect.com/products/ejournals/html/10.1055/s-0042-1759499>.

### Illustration of Case 2

A 20-year-old male presented with isolated pudendal neuropathy and severe anal incontinence. He had sustained injury over the sacral region in a road traffic accident 5 years before this episode. On examination, he had multiple scars in the sacral region with severe atrophy of the perianal pad of fat (► **Figs. 4 and 5**) but with good perianal sensation. He underwent bilateral unstimulated gluteus maximus sphinc-

teroplasty as there was a less ischioanal pad of fat, and the muscle would provide some bulk to the area (► **Figs. 6 and 7**). There were no postoperative complications observed in the patient (► **Fig. 7**). The follow-up period was for 28 months. At the end of the follow-up period, his median resting pressure was 40 mm Hg, and median squeeze pressure was 112 mm Hg (► **Fig. 7D**) as recorded by high-resolution anal manometric studies. The CCFFIS at the end of the follow-up period was calculated to be 4. He had one episode of incontinence per month for gas and liquid stool. Assessment done at the end of the follow-up period revealed that he could maintain sustained gluteus maximus contraction at the anal canal for an average of 2.5 minutes.

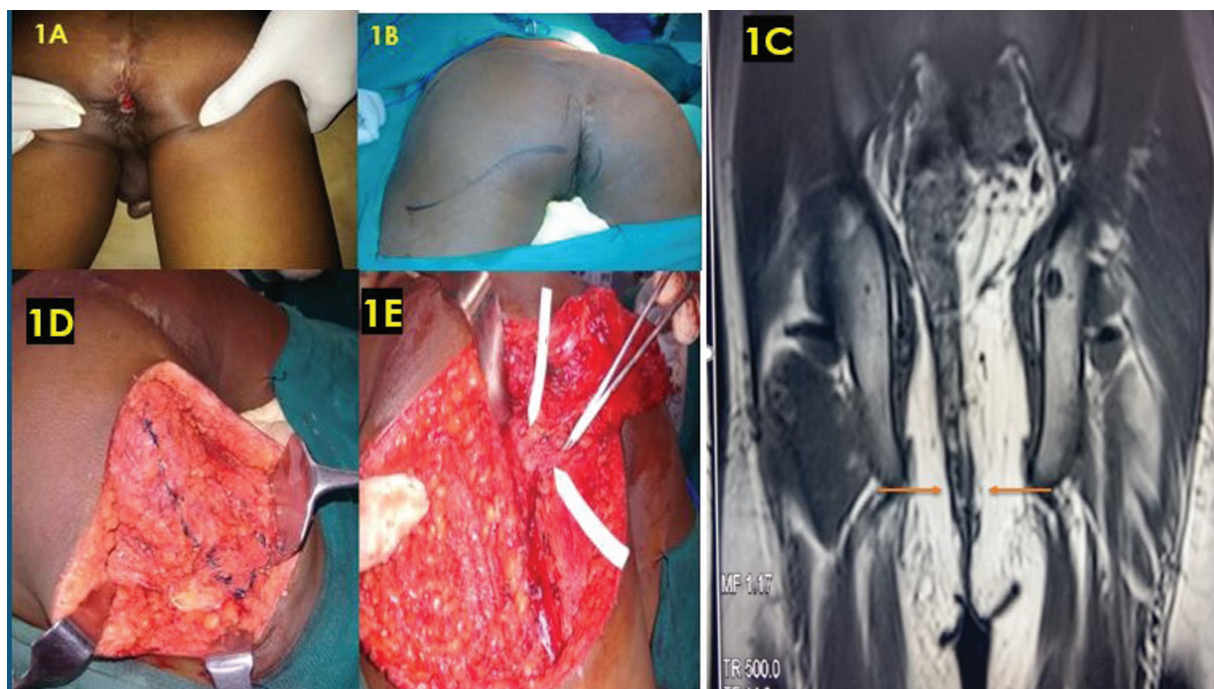
### Illustration of Case 3

A 27-year-old male sustained a fracture of the right femur, with split perineum and bulbar urethral injury in a road traffic accident. The orthopaedics team did skeletal stabilization, pull through perineal colostomy was done for the patient by the surgical gastroenterology team (with covering right transverse diversion colostomy), and the urology team did urethral repair. After 3 months (► **Fig. 8**), he was referred to us for continence surgery, for which he underwent unstimulated unilateral gluteus maximus sphincteroplasty (► **Fig. 9**). Some donor site seroma was noted in the patient on postoperative day 3, which was drained and resolved subsequently (► **Fig. 10**). The diversion colostomy was closed 6 weeks after surgery. The follow-up period was for 20 months. At 18 months, MRI revealed good mass of the transposed gluteal muscle sphincter (► **Fig. 11**). At the end of the follow-up period, his median resting anal pressure was 48 mm Hg, and median squeeze pressure was 102 mm Hg as measured by high-resolution anal manometry (► **Fig. 12**). The CCFFIS was calculated to be 2 as he had a single episode of gaseous incontinence in one month. The patient was able to maintain sustained gluteus maximus muscle contraction for 4 minutes by the end of the follow-up period.

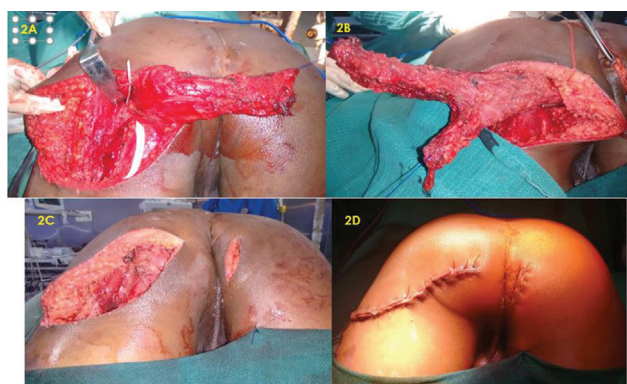
## Results

Over the 5-year study period from 2015 to 2020, a total of 11 patients underwent unstimulated gluteus maximus sphincteroplasty, out of which 10 were unilateral, and 1 was bilateral (► **Table 1**). The mean age was calculated to be 31.55 years and the mean follow-up period was 28.46 months with a range of 16 to 36 months. There were four females and seven males in the study. Etiology of incontinence was obstetric trauma ( $n=3$ ), previous anorectal surgery ( $n=3$ ), isolated pudendal neuropathy ( $n=1$ ), and post trauma ( $n=4$ ). Four patients (overall general complication rate was 36.36%) had complications such as wound site infection ( $n=1$ ), seroma formation ( $n=1$ ), numbness in the distribution of posterior cutaneous nerve of the thigh ( $n=1$ ), and minimal mucosal prolapse through perineal colostomy site ( $n=1$ ) that were all resolved subsequently. Good continence was observed in all patients with an average CCFFIS of 3.18 ( $p=0.0035$ ) (► **Table 1**). At the end of the follow-up period, the average median resting pressure found via

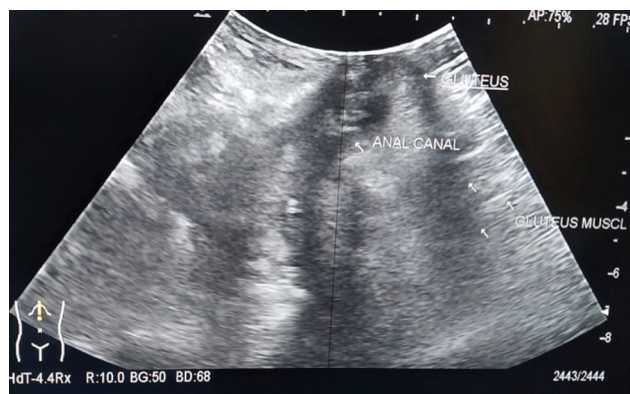



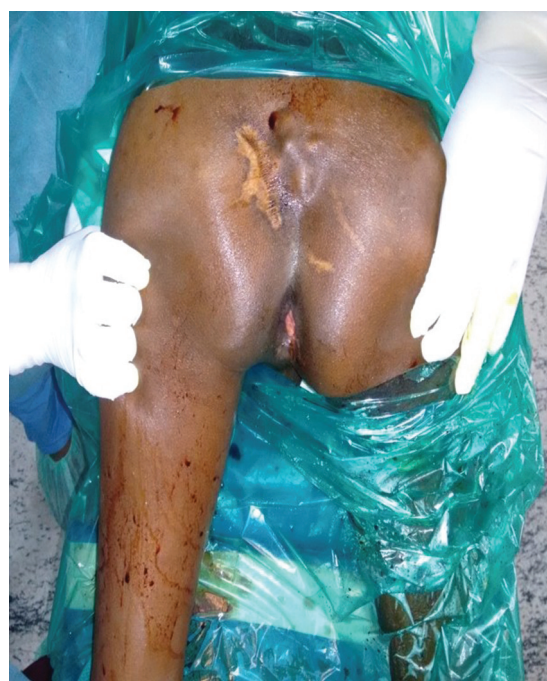**Fig. 1** Illustration of case 1. (A) Anal incontinence with patulous anus. (B) Preoperative markings. (C) Coronal magnetic resonance imaging with an absence of definition of the native anal sphincter (red arrows). (D) Intraoperative marking for lower third gluteus maximus. (E) Skeletonization of neurovascular pedicle.



**Fig. 2** Illustration of case 1. (A) Complete dissection of the lower third of gluteus maximus. (B) Splitting of the lower third of gluteus maximus. (C) Transposition through the perianal tunnel and final inset. (D) Final suture line.



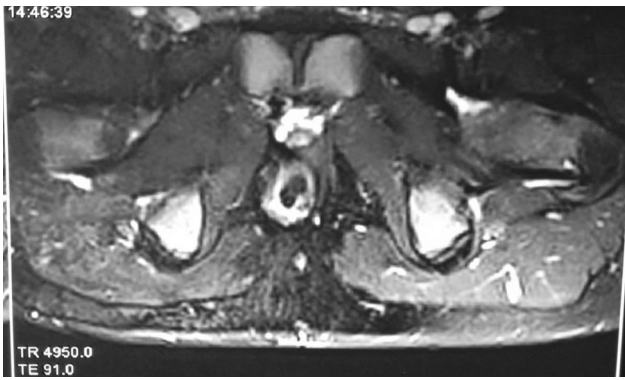
**Fig. 3** High-resolution transanorectal ultrasound showing gluteus maximus sphincter in case 1.



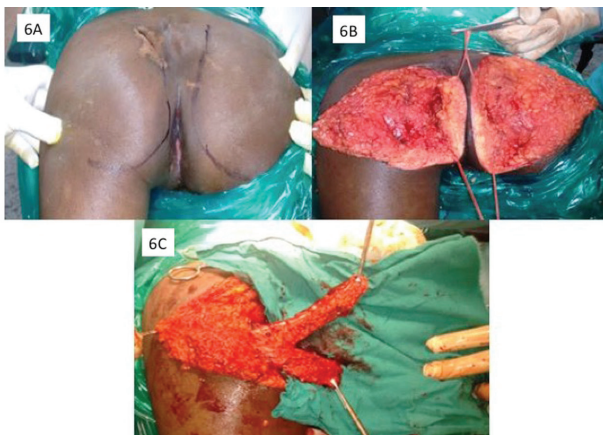
**Fig. 4** Preoperative picture of case 2 showing patulous anal canal.

manometry was 44.64 mm Hg, and the average median squeeze pressure was 103.55 mm Hg. The mean of the average continence contraction time at the end of the follow-up period was found to be 3.64 minutes. None of our patients had complete continence failure (0%). None of our patients used perineal pads or made any lifestyle alterations at the end of the follow-up period. The possible

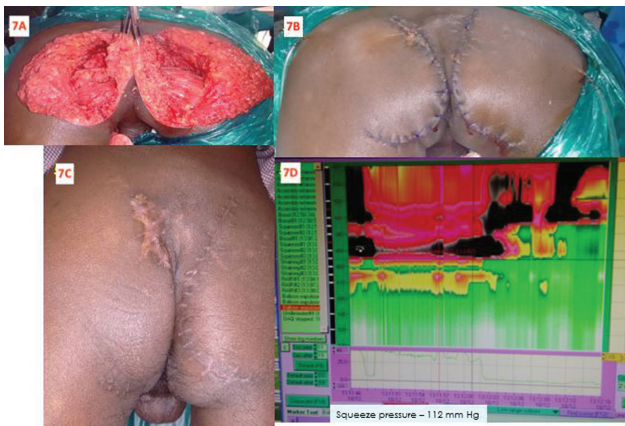



**Fig. 5** Axial magnetic resonance imaging of case 2 (at the level of upper Ischial tuberosity) showing a patulous anal canal with no definition of the native sphincter.

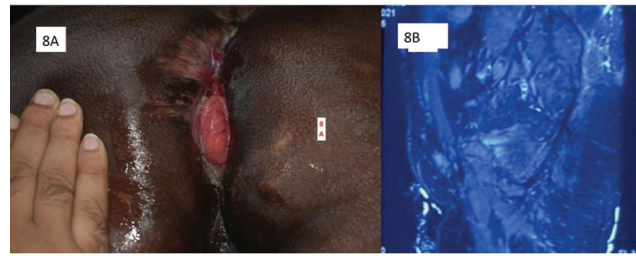


**Fig. 6** Illustration of case 2. (A) Preoperative marking for bilateral lower third gluteus maximus muscle harvest. (B) Harvest in progress. (C) Lower third muscle being split.

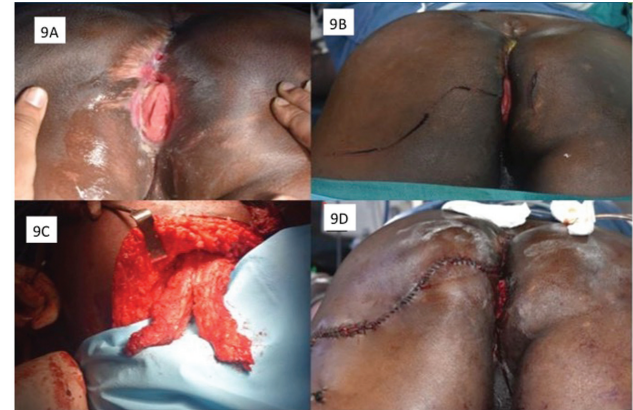


**Fig. 7** Illustration of case 2. (A) Bilateral muscle transposition and inset. (B) Final suture line. (C) 35 months follow-up picture. (D) 35 months follow-up manometric anal squeeze pressure reading of 112 mm Hg.

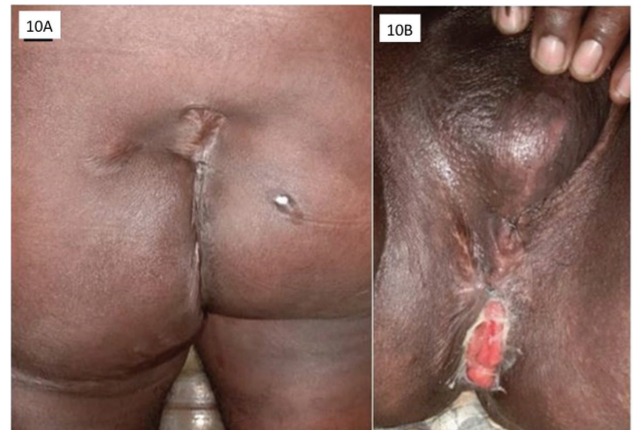complications are related to the inferior gluteal nerve dissection and adhesiolysis of the sciatic nerve. We did not come across any of these complications in our study. Most of the patients expressed satisfactory continence.



**Fig. 8** Illustration of case 3. (A) Scarred perineum, perineal colostomy, and contracting gluteus maximus. (B) Right parasagittal magnetic resonance imaging is showing severely scarred pelvis.



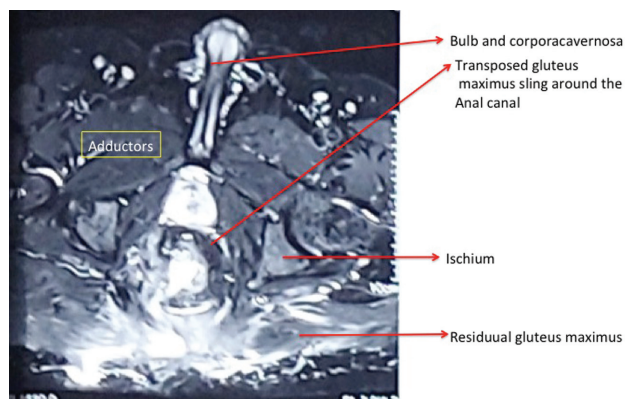
**Fig. 9** Illustration of case 3. (A). Preoperative picture. (B). Preoperative marking. (C) Splitting of lower one-third of muscle. (D) Final suture line after transposition.



**Fig. 10** Illustration of case 3. (A). 20 months later postoperative picture—posterior view. (B) 20 months later postoperative picture—anterior view.

## Discussion

Since the beginning of the 20th century, anal sphincter reconstruction has evolved constantly from fascial sling implantation, muscle slip transposition,<sup>7</sup> gracilis muscle transposition,<sup>8</sup> free muscle graft of striated and smooth muscle,<sup>9</sup> gluteus muscle transposition,<sup>10</sup> and neurovascular intact muscle transposition with implantation of a muscle stimulator.<sup>11-13</sup> Chetwood first introduced gluteus maximus




**Fig. 11** Magnetic resonance imaging axial section at the ischium level reveals good mass of gluteus sphincter in case 3.

muscle sphincteroplasty in 1902.<sup>7</sup> In 1952, gracilis sphincteroplasty was introduced by Pickrell et al,<sup>8</sup> and it became popular because of the accessibility and expendability of the muscle. This was further popularized by Corman,<sup>14</sup> Ben-Hur et al,<sup>15</sup> and Leguit et al<sup>16</sup> However, it was noted that the distal end of the gracilis muscle sustained an ischemic injury, the suspected reason being the segmental blood supply to gracilis muscle. The distal part then became fibrotic, acting

more like a Thiersch sling than a contractile muscle. Attempts were made to modify the procedure.<sup>17</sup> Unfortunately, despite all modifications, continence rates of graciloplasty remained unpredictable and unsatisfactory. Hence, gluteus maximus sphincteroplasty was rediscovered by Bruining et al<sup>10</sup> in 1981. They used a bilateral proximally based flap, split at both distal muscle ends, creating two muscle slings around the anal canal fixed on both sides to the ischial tuberosities. Several modifications of gluteus maximus sphincteroplasty were described by Hentz,<sup>18</sup> Prochiantz and Gross,<sup>19</sup> Devesa et al,<sup>20</sup> and Orgel and Kuncan.<sup>21</sup> The most widely accepted modification was published by Guelinckx et al<sup>11</sup> in 1996, where only lower one-third of the unilateral muscle was harvested, split into two halves, wrapped around the anal canal in a crisscross manner and secured to the periosteum of contralateral Ischial tuberosity. This technique was reinforced by Hultman et al<sup>22</sup> with their study conducted in 25 patients. They reported 56% perirectal complication rates, 64% donor site complication rates, and 40% general complication rates. They reported a complete procedure failure in 8% of the cases and partial failure of procedure in 16% of the cases. Though our study is relatively small, we had a 0% complete continence failure rate and a lower complication rate of 36.36%. Our better results can be attributed to complete neurolysis of inferior gluteal nerve

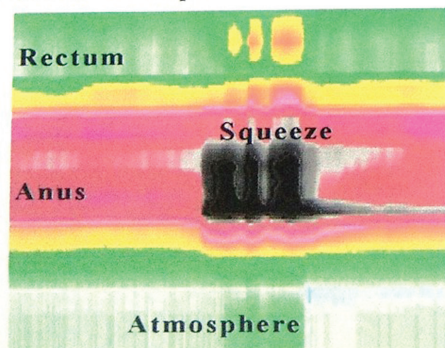
Anal Manometry (mmHg)	
Anal Canal Length 2	
Basal	Squeeze
Median 48	Median 102
Max 51	Max 102
Min 43	Min 73
Rectoanal Inhibitory Reflex	
Present	
Rectal Sensory Function	
Present	
not tested	



**Comments**

Resting anal sphincter pressures were normal. Squeeze pressures were near normal. RAIR and rectal sensation were preserved. Patient was able to expel 40cc balloon with good augmentation of rectal pressures and anal sphincter relaxation.

**Normal Example**



**Diagnosis**

**Normal Anorectal Manometry**

**Fig. 12** Case 3; high-resolution anal manometric report at 20 months after surgery.



and adhesiolysis of pedicle up to the point of emergence from the greater sciatic notch, which has facilitated well-vascularized and innervated lower third gluteus maximus muscle transposition. The patient satisfaction was found to be acceptable as measured by CCFIS with regular readings of resting and squeeze pressure as depicted by high-resolution anal manometry at the end of the follow-up period, reinforced by our muscle re-education and biofeedback exercises.

Gluteus maximus muscle is a type III muscle based on its blood supply.<sup>23</sup> It is a type II muscle based on its nerve supply.<sup>5</sup> The inferior gluteal nerve divides into three branches before entering the muscle anteriorly, supplying the upper, middle, and lower thirds. This arrangement enables us to harvest the lower third of the muscle on a lengthy and intact neurovascular bundle. This ascertained that there was no traction at the neurovascular bundle. Our meticulous dissection with attention to the details at this step of surgery ensured retention of adequate muscle mass even after 1 year. This has contributed to the high squeeze pressure of 100 mm Hg and above in all the cases under voluntary control. This muscle is a proactive and synergistic muscle at the time of contraction of the external anal sphincter. It also pushes the ischioanal pad of fat toward the anal canal, reducing the size of the canal and orifice. These features helped make reeducation of the patient easy, which ultimately contributed to the success of our procedure. Implantable electrical generator for low-frequency stimulation of gluteus maximus muscle was associated with multiple unacceptable complications such as exposure, extrusion, infection, and poor patient compliance. Hence, we stopped using implants that convert type II rapid, fatigue-prone muscle into type I slow, fatigue-resistant muscle. Hitherto, the gluteus maximus muscle has acquired a nonfatigable character during the evolution of human beings on assuming the erect posture. It has many characteristics resembling those of type I striated musculature.<sup>4</sup> Gracilis sphincteroplasty, both dynamic and adynamic, has suffered attenuation of popularity and choice as the avascular tendinous portion commonly ended up being wrapped around the anal canal and invariably suffered traction induced functional neuropathic deterioration. We have also noted several other advantages of gluteus maximus sphincteroplasty over gracilis sphincteroplasty like 1. In gluteus maximus sphincteroplasty, the portion enclosing the anal region is the muscle. 2. Reeducation is easier as it synchronously acts and is synergistic during normal sphincter contraction. 3. Gluteus maximus sphincteroplasty has an added advantage of counteracting levator ani muscle and producing an S-shaped deviation to increase the continence. 4. The squeeze pressure is higher as a lasting muscle cuff is guaranteed around the anal canal. 5. There was no traction of the neurovascular bundle during the transposition of the gluteus maximus muscle, owing to the careful and meticulous dissection done by us in our procedure. 6. Unlike the gracilis muscle, which has a segmental blood supply, gluteus maximus lower third muscle has a homogenized blood supply when harvested with the inferior

gluteal artery. 7. In case of any unfortunate minor iatrogenic injury to the anal mucosa, the presence of sufficient muscle mass helps cover the rents and heal it. 8. Even if needed, the muscle mass is adequate to facilitate the insertion of any electrodes. Chandra et al,<sup>24</sup> in their study, used unstimulated gluteoplasty in postexcisional and perineal injury cases. They have done this as a secondary procedure after vascularized antroploric valve transfer for perineal colostomy reconstruction. They had an 80% success rate and noted excess mucous discharge ( $n = 11$ ) (necessitating continuous pad usage) and dumping syndrome ( $n = 1$ ). But in our study, which has a comparable number of patients, we had good-to-excellent continence in all patients (–Table 1) attributable to the diligent peripedicle dissection around the inferior gluteal neurovascular pedicle, allowing tensionless transposition across the perianal region. Also, dumping syndrome and troublesome excessive mucorrhea were not noted in our patients because we did not use antroploric valve transposition, which in our opinion did not provide any added advantage. The ideal reconstructed anal sphincter must be capable of voluntary contraction and tonic contraction for a prolonged period. The gluteus maximus sphincteroplasty is nearly approximating this goal.

## Conclusion

Despite being untrained with implantable electrodes, the gluteus maximus muscle produced very good continence results with our way of construct. In addition, with its good lumen occluding effect, it achieves good resting and squeeze anal pressure around the anal canal/bowel with trivial reeducation. Hence, it has become our institution's procedure of choice for anal sphincter reconstruction.

## Conflict of Interest

None.

## References

- Merchea A, Larson DW. Anus. In: Townsend CM, Evers BM, Beauchamp RD, Mattox KL, eds. Sabiston Textbook of Surgery. 20th ed. Canada: Elsevier; 2016:1395–1395
- Whitehead WE, Wald A, Norton NJ. Treatment options for fecal incontinence. *Dis Colon Rectum* 2001;44(01):131–142, discussion 142–144
- Madoff RD, Rosen HR, Baeten CG, et al. Safety and efficacy of dynamic muscle plasty for anal incontinence: lessons from a prospective, multicenter trial. *Gastroenterology* 1999;116(03):549–556
- Standring SE. *Gray's Anatomy: The Anatomical Basis of Clinical Practice*. 40th edition Spain: Churchill Livingstone; 2008
- Taylor GI, Gianoutsos MP, Morris SF. The neurovascular territories of the skin and muscles: anatomic study and clinical implications. *Plast Reconstr Surg* 1994;94(01):1–36
- Jorge JM, Wexner SD. Etiology and management of fecal incontinence. *Dis Colon Rectum* 1993;36(01):77–97
- Chetwood CH. Plastic operations for restoration of sphincter ani, with report of a case. *Med Rec* 1902;61(14):529 <https://www.proquest.com/openview/d690fa99f1f772a6c95f7287ded9a09b/1?pq-origsite=gscholar&cbl=40146> Accessed May 18, 2022
- Pickrell KL, Broadbent TR, Masters FW, Metzger JT. Construction of a rectal sphincter and restoration of anal continence by



- transplanting the gracilis muscle; a report of four cases in children. *Ann Surg* 1952;135(06):853–862
- 9 Hofmann-von Kap-herr S, Koltai IL, Tennant LJ. Anal sphincter substitute using autologous smooth muscle in a fold-over, half-cylinder, double plasty (SMFD-plasty): a new method of treatment of anorectal incontinence. *J Pediatr Surg* 1985;20(02):134–137
  - 10 Bruining HA, Bos KE, Colthoff EG, Tolhurst DE. Creation of an anal sphincter mechanism by bilateral proximally based gluteal muscle transposition. *Plast Reconstr Surg* 1981;67(01):70–73
  - 11 Guelinckx PJ, Sinsel NK, Gruwez JA. Anal sphincter reconstruction with the gluteus maximus muscle: anatomic and physiologic considerations concerning conventional and dynamic gluteoplasty. *Plast Reconstr Surg* 1996;98(02):293–302, discussion 303–304
  - 12 Baeten C, Spaans F, Fluks A. An implanted neuromuscular stimulator for fecal continence following previously implanted gracilis muscle. Report of a case. *Dis Colon Rectum* 1988;31(02):134–137
  - 13 Baeten CG, Konsten J, Spaans F, et al. Dynamic graciloplasty for treatment of faecal incontinence. *Lancet* 1991;338(8776):1163–1165
  - 14 Corman ML. Gracilis muscle transposition for anal incontinence: late results. *Br J Surg* 1985;72(Suppl):S21–S22
  - 15 Ben-Hur N, Gilai A, Golan J, Sagher U, Issac M. Reconstruction of the anal sphincter by gracilis muscle transfer: the value of electromyography in the preoperative assessment and postoperative management of the patient. *Br J Plast Surg* 1980;33(02):156–160
  - 16 Leguit P Jr, van Baal JG, Brummelkamp WH. Gracilis muscle transposition in the treatment of fecal incontinence. Long-term follow-up and evaluation of anal pressure recordings. *Dis Colon Rectum* 1985;28(01):1–4
  - 17 Wee JT, Wong CS. Functional anal sphincter reconstruction with the gracilis muscle after abdominoperineal resection. *Lancet* 1983;2(8361):1245–1246
  - 18 Hentz VR. Construction of a rectal sphincter using the origin of the gluteus maximus muscle. *Plast Reconstr Surg* 1982;70(01):82–85
  - 19 Prochiantz A, Gross P. Gluteal myoplasty for sphincter replacement: principles, results and prospects. *J Pediatr Surg* 1982;17(01):25–30
  - 20 Devesa JM, Vicente E, Enríquez JM, et al. Total fecal incontinence—a new method of gluteus maximus transposition: preliminary results and report of previous experience with similar procedures. *Dis Colon Rectum* 1992;35(04):339–349
  - 21 Orgel MG, Kucan JO. A double-split gluteus maximus muscle flap for reconstruction of the rectal sphincter. *Plast Reconstr Surg* 1985;75(01):62–67
  - 22 Hultman CS, Zenn MR, Agarwal T, Baker CC. Restoration of fecal continence after functional gluteoplasty: long-term results, technical refinements, and donor-site morbidity. *Ann Plast Surg* 2006;56(01):65–70, discussion 70–71
  - 23 Mathes SJ, Nahai F. Classification of the vascular anatomy of muscles: experimental and clinical correlation. *Plast Reconstr Surg* 1981;67(02):177–187
  - 24 Chandra A, Mishra B, Kumar S, et al. Composite antropyloric valve and gluteus maximus muscle wrap for neoanal reconstruction: initial results. *Dis Colon Rectum* 2019;62(01):104–111