Article published online: 2022-12-26

Diagnostic Value of Connective Tissue Disease Related CT Signs in Usual Interstitial Pneumonia Pattern of Interstitial Lung Disease

Antony Augustine[1] Leena Robinson Vimala[1] Aparna Irodi[1] John Mathew[2] Mini Pakkal[3]

[1] Department of Radiodiagnosis, Christian Medical College and Hospital, Vellore, Tamil Nadu, India
[2] Department of Clinical Immunology and Rheumatology, Christian Medical College and Hospital, Vellore, Tamil Nadu, India
[3] Joint Department of Medical Imaging, Toronto General Hospital, Toronto, Ontario, Canada

Address for correspondence Leena Robinson Vimala, DMRD, MD, FSCMR, Department of Radiodiagnosis, Christian Medical College and Hospital, Vellore 632004, Tamil Nadu, India (e-mail: leenarv76@gmail.com).

Indian J Radiol Imaging 2023;33:70–75.

Abstract

Purpose Usual interstitial pneumonia (UIP) pattern of interstitial lung disease (ILD) can have varied etiology, with connective tissue disease (CTD) being a common known cause. The anterior upper lobe (AUL) sign, exuberant honeycombing (EHC), and straight edge (SE) sign are recently described computed tomography (CT) signs in CTD-related UIP. We test the diagnostic value of these CT signs for CTD in patients with UIP and compare the incidence of these signs between CTD-related UIP and non–CTD-related UIP. We also evaluated the interobserver agreement in detection of these CT signs.

Methods Retrospective study of all patients who had UIP pattern of ILD on CT thorax done from January 1, 2016 to January 31, 2019, was grouped into two: non–CTD-related UIP or CTD-related UIP. CT thorax was reviewed for the presence of these signs—AUL, SE, and EHC. The diagnostic values of these signs in diagnosing CTD-related UIP was assessed. For assessment of interobserver agreement, another radiologist reviewed a subset of 30 randomly selected cases and looked for the presence of these signs.

Results Of the 156 patients included, 76 had CTD. The incidence of CT signs were significantly higher in CTD-related UIP. The specificities of AUL, EHC, and SE were 82.5, 75, and 85%, respectively. The EHC sign had highest sensitivity of 48.7%. Inclusion of more than one sign increased the specificity of diagnosis of CTD-related UIP; however, the sensitivity decreases. There was excellent interobserver agreement (0.81–0.87) for each of these signs.

Conclusion The presence of SE, AUL, and EHC signs in cases with UIP pattern are specific imaging markers to diagnose underlying CTD; however, due to its low sensitivity, the absence of these signs cannot exclude the same. Because of its excellent interobserver agreement, these signs are reliable in the evaluation of CTD-related ILD.

Keywords
- usual interstitial pneumonia
- connective tissue disease
- computed tomography

article published online
December 26, 2022

DOI https://doi.org/10.1055/s-0042-1758876.
ISSN 0971-3026.

Thieme Medical and Scientific Publishers Pvt. Ltd., A-12, 2nd Floor, Sector 2, Noida-201301 UP, India

Introduction

Usual interstitial pneumonia (UIP) pattern on chest computed tomography (CT) has varied causes, with the common causes being idiopathic pulmonary fibrosis (IPF), connective tissue disease (CTD), chronic hypersensitivity pneumonitis (HP), asbestosis, and drug toxicity.[1] The clinical practice guidelines put forward in 2018 by the American Thoracic Society (ATS), the European Respiratory Society (ERS), the Japanese Respiratory Society (JRS), and the Latin American Thoracic Association (ALAT) are used for the diagnosis of UIP patterns on chest CT.[2] Differentiating IPF from secondary UIP has substantial therapeutic and prognostic implications. A number of radiological and histological clues may help distinguish IPF from other conditions with a UIP pattern of fibrosis, but their appreciation requires extensive expertise in interstitial lung disease (ILD) as well as an integrated multidisciplinary approach involving pulmonologists, rheumatologists, radiologists, and pathologists. Some of the imaging findings which suggest a possible secondary cause for UIP include the presence of pleural plaques, dilated esophagus, distal clavicular erosions, and pleural effusions/thickening.[2]

Majority of patients with CTD-related ILD have a diagnosis of a defined CTD before identifying ILD; however, a small minority may present with ILD first, and CTD is diagnosed later during further evaluation.[3–9] If the reporting radiologist can identify any imaging findings that could suggest a secondary cause, it can go a long way in patient management.

Chung et al[10] in a study done in an ILD clinic in University of Chicago had identified three CT signs which were significantly more common in CTD-related UIP than in IPF-related UIP. The CT signs studied were anterior upper lobe (AUL) sign, straight edge (SE) sign, and exuberant honeycombing (EHC) sign. They concluded that the index of suspicion for CTD-related ILD should be raised in the case of patients with any of the three CT signs.

The primary objective of our study is to evaluate the diagnostic value of these three CT signs (AUL, EHC, and SE) in the diagnosis of CTD-related UIP and compare the incidence of these signs between CTD-related UIP and non–CTD-related UIP. The secondary objective is to evaluate the interobserver agreement in the detection of these CT signs.

Methods

Study flow diagram is given in ►**Fig. 1**.

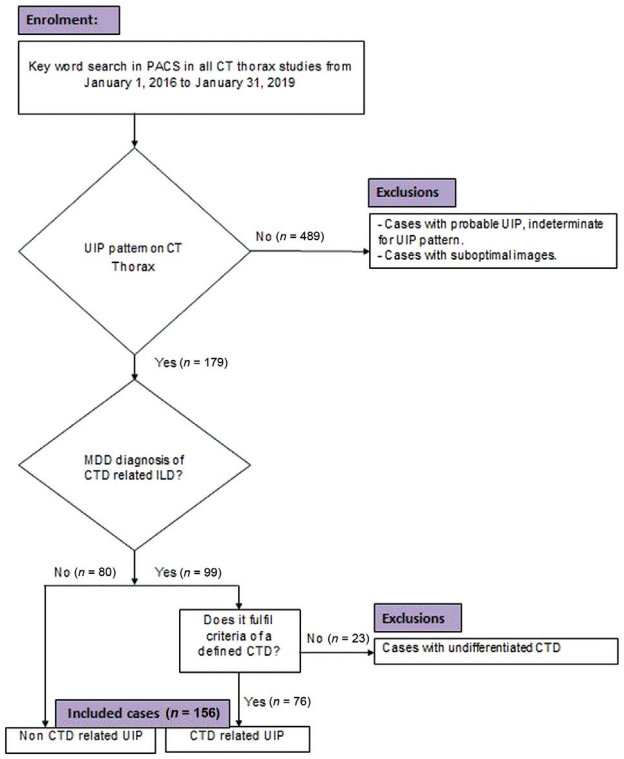

Fig. 1 Study flow diagram. CT, computed tomography; CTD, connective tissue disease; ILD, interstitial lung disease; UIP, usual interstitial pneumonia.

Subjects

After obtaining approval from Institutional Review Board, the study was done in a tertiary care institute with more than 2,500 beds. Retrospective search was done among all CT thorax studies done from January 1, 2016, to January 31, 2019, for cases which fulfilled UIP pattern as per ATS/ERS/JRS/ALAT guidelines. Patients with probable UIP pattern or indeterminate for UIP pattern and other types of ILD were excluded. In our institute, the final diagnosis in each case of ILD is made by multidisciplinary discussion, and cases with clinical and/or serological evidence of autoimmunity will be evaluated by a rheumatologist to diagnose and characterize CTDs using established criteria. Hence, we assessed the clinical records of subjects with UIP pattern through hospital information system, and the study subjects were grouped into CTD-related UIP and non–CTD-related UIP. Any case with clinical and/or serological evidence of autoimmunity but fall short of diagnosis of a specific CTD was classified as undifferentiated CTDs. They were excluded from the study.

CT Assessment

CT scan was performed in one of these three multislice CT scanners available at our institution: Discovery CT750 HD (GE Healthcare, Milwaukee, Wisconsin, United States), SOMATOM Sensation CT Scanner (Siemens AG, Erlangen, Germany), and Phillips Brilliance 16 (Phillips Healthcare, Eindhoven, The Netherlands). Contiguous helical acquisition of CT scans were performed. CT scans were considered diagnostic quality if whole of thorax in full inspiration is covered. All the CT scans were viewed in 1 to 2 mm high spatial algorithm, reconstructed in different planes. A chest radiologist (A.A.) who was blinded to multidisciplinary discussion (MDD) diagnosis and study grouping assessed the CT images for the presence of the three CT signs as described by Chung et al.[10] The AUL sign is concentration of fibrosis in anterior aspect of upper lobes with relative sparing of rest of the upper lobes along with concomitant lower lobe involvement (►**Figs. 2** and **3**). EHC sign is extensive honeycomb-like cyst formation in more than 70% of fibrotic portion of lungs

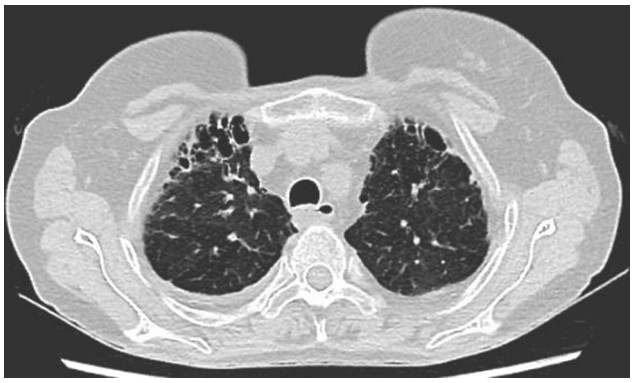

Fig. 2 A 58-year-old woman with systemic sclerosis. Axial chest computed tomography image through upper lung shows concentration of fibrosis in anterior aspect of bilateral upper lobes consistent with anterior upper lobe sign.

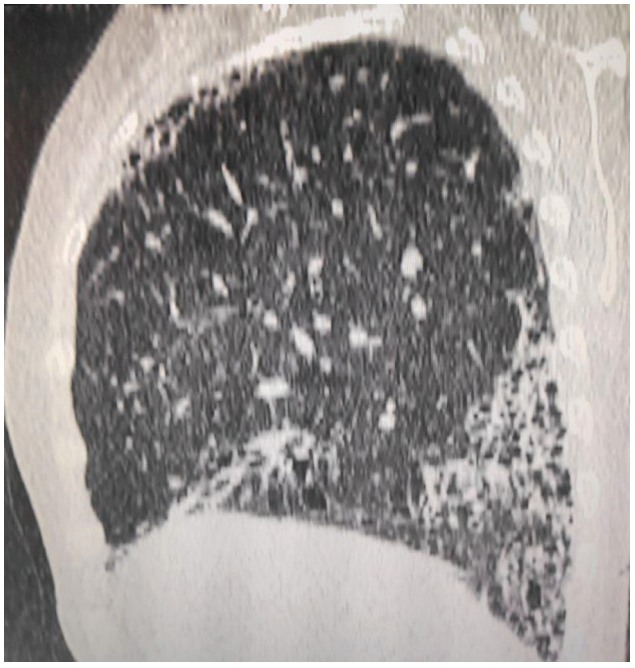

Fig. 3 A 49-year-old woman with rheumatoid arthritis. Sagittal reconstructed chest computed tomography image shows fibrosis in upper lobe concentrated in the anterior aspect, consistent with anterior upper lobe sign. There is concomitant fibrosis in basal lung posteriorly.

(►**Fig. 4A**). SE sign is fairly straight and abrupt interphase between fibrotic lung bases and normal lung without extension along the lateral margins of lung on coronal images (►**Fig. 4B**). A randomly selected subset of 30 patients were chosen to assess interobserver agreement in detecting the CT signs. The CT of these patients were reviewed independently by another chest radiologist (L.R.V.) who was blinded to MDD diagnosis or study grouping, to look for the presence of the three CT signs.

Statistical Analysis

Categorical variables were presented as frequency and percentage, and continuous variables as mean and standard deviation. Continuous variables were compared among CTD-related ILD and non-CTD-related ILD using independent *t*-test. Categorical variables were compared using chi-square test. The sensitivity, specificity, positive likelihood ratio, and negative likelihood ratio for each of the signs in diagnosing CTD-related ILD were calculated. Interobserver agreement was estimated by calculating intraclass correlation coefficient (ICC).

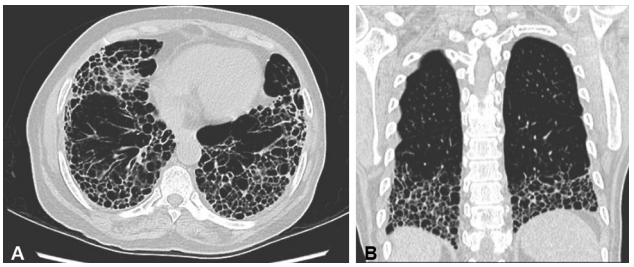

Fig. 4 A 63-year-old woman with rheumatoid arthritis. (**A**) Axial chest computed tomography (CT) image through lung base shows extensive honeycombing, consistent with exuberant honeycombing sign. (**B**) Coronal chest CT image shows basal fibrosis as extensive honey combing with an abrupt transition from the uninvolved lung forming a straight interface between them, consistent with straight edge sign.

Results

A total of 156 patients were included in the study, 76 (48.6%) had CTD. Majority of the study subjects were females (53.2%). The mean age for the cohort was 55.8 ± 13 years. Comparison of demographic characteristics and CT sign distribution between CTD-related UIP and non-CTD-related UIP is given in ►**Table 1**. There was significant difference in gender distribution, females being more common in CTD-related UIP. Patients with CTD-related UIP were significantly younger than those without CTD in our study. Thirty-eight cases (24.4%) in our cohort had smoking history, more common in the non–CTD-related UIP group. The subtypes of CTD in our cohort are given in ►**Table 2**. Rheumatoid arthritis (RA) (60.5%) was the most common subtype of CTD.

Among the three signs studied, EHC sign was the most common sign and was present in 57 patients (36.5%). SE sign and AUL sign were present in 41 patients (26.2%) each. There were 83 patients (53%) with at least one sign being positive on CT, 42 patients (26.9%) with more than one sign being positive, and 14 patients (8.9%) with all signs being positive. All the three signs were significantly more common in CTD-related UIP than in non–CTD-related UIP.

The performance of these signs in CTD-related UIP and non–CTD-related UIP is demonstrated in ►**Table 3**. The most sensitive sign was EHC sign (48.7%) followed by SE sign (38.2%) and AUL sign (35.5%). The most specific sign was SE sign (85%) followed by AUL sign (82.5%) and EHC sign (75%). The highest positive likelihood ratio was for SE sign (2.54), and the lowest negative likelihood ratio was for EHC sign (0.68). The highest positive predictive value was for SE sign (70.7%) and negative predictive value was for EHC sign (60.6%).

When any one of the three signs being positive is considered for diagnosis, the sensitivity was higher (69.7%) and the

Table 1 Demographic characteristics and CT sign distribution between CTD-related UIP and non-CTD-related UIP

	Non-CTD UIP ($n = 80$)	CTD UIP ($n = 76$)	Total	*p*-Value
Mean age (y)	61.35 ± 11	50.0 ± 13	55.82 ± 13	<0.001
Sex				
Male	53 (72.6%)	20 (27.4%)	73	<0.001
Female	27 (32.5%)	56 (67.5%)	83	
Smoking history				
Present	30 (78.9%)	8 (21.1%)	38	<0.001
Absent	50 (42.4%)	68 (57.6%)	118	
Anterior upper lobe sign				
Present	14 (34.1%)	27 (65.9%)	41	0.011
Absent	66 (57.4%)	49 (42.6%)	115	
Exuberant honeycombing sign				
Present	20 (35.1%)	37 (64.9%)	57	0.002
Absent	60 (60.6%)	39 (39.4%)	99	
Straight edge sign				
Present	12 (29.3%)	29 (70.7%)	41	0.001
Absent	68 (59.1%)	47 (40.9%)	115	
Any sign positive (one or more)				
Present	30 (36.1%)	53 (63.9%)	83	<0.001
Absent	50 (68.5%)	23 (31.5%)	73	
More than one sign positive (two or more)				
Present	13 (31%)	29 (69%)	42	0.002
Absent	67 (58.8%)	47 (41.2%)	114	
All signs positive				
Present	3 (21.4%)	11 (78.6%)	14	0.019
Absent	77 (54.2%)	65 (45.8%)	142	

Abbreviations: CT, computed tomography; CTD, connective tissue disease; UIP, usual interstitial pneumonia.

Table 2 Subtypes of CTD in cohort

Subtype of CTD–ILD	Count (%)
Rheumatoid arthritis	46 (60.5)
Systemic sclerosis	14 (18.4)
Mixed connective tissue disease	10 (13.2)
Systemic lupus erythematosus	5 (6.6)
Sjogren's syndrome	1(1.3)
Total	76 (100)

Abbreviations: CTD, connective tissue disease; ILD, interstitial lung disease.

specificity is lower than that for any individual signs (62.5%). When more than one sign being positive are considered, the sensitivity and specificity were 38.2 and 83.8%, respectively. Sensitivity further decreased to 14.5% and specificity increased to 96.2% when all the three positivity signs were considered for diagnosis (►**Table 3**).

In the subset of 30 cases whose CT was read independently by two radiologists, the ICCs for AUL, EHC, and SE were 0.81 (95% confidence interval [CI]: 0.63–0.90), 0.86 (95% CI: 0.74–0.93), and 0.87 (95% CI: 0.75–0.93), respectively, suggestive of excellent interobserver agreement for all the three CT signs.

Table 3 Performance of CT signs in the diagnosis of CTD-related UIP

	AUL	EHC	SE	Any positive	> 1 positive	All positives
Sensitivity	35.5	48.7	38.2	69.7	38.2	14.5
Specificity	82.5	75.0	85.0	62.5	83.8	96.2
LR+	2.02	1.95	2.54	1.85	2.36	3.82
LR−	0.78	0.68	0.73	0.48	0.74	0.89

Abbreviations: AUL, anterior upper lobe; CT, computed tomography; CTD, connective tissue disease; EHC, exuberant honeycombing; LR, likelihood ratio; SE, straight edge; UIP, usual interstitial pneumonia.

Discussion

We aimed to evaluate the diagnostic performance of CT signs, namely, the AUL sign, SE sign, and EHC sign, in the diagnosis of CTD-related UIP and the interobserver variability in detecting these among two radiologists. We have demonstrated that these signs are more common in CTD-related UIP with at least one sign being present in nearly 64% of CTD-related ILD with UIP pattern, and these signs are relatively specific as well. All the three signs showed excellent interobserver agreement suggesting that these signs are reliable in the evaluation of CTD-related ILD.

Some of the previous studies which included all types of ILD have found conflicting results with IPF as the most common ILD in some of the studies, whereas CTD-related ILD was the most common in a few others.[11–16] One of the largest prospective registries for ILD performed in a similar population as the present study has found HP to be the most common cause of ILD, followed by CTD-related ILD and then IPF.[17] In the same registry, among cases with UIP pattern on CT, majority of cases (51.6%) were IPF, and only 18.75% were CTD related. In the study by Chung et al,[10] which studied CT features of UIP, 32% of cases were CTD related and the rest IPF. The incidence of CTD-related UIP is higher in our sample as the study was done in a multispecialty institute with a larger proportion of patients being referred from Clinical Immunology and Rheumatology Department. Hence, our results may not represent the proportion of such diagnosis in other hospital settings or general population.

RA is the most common CTD to cause ILD, and the most common pattern of ILD in RA is UIP followed by nonspecific interstitial pneumonia.[7,10,17–20] Our cohort of CTD-related UIP cases also showed similar trend with RA being the most common (60.5%) followed by systemic sclerosis (18.4%), mixed CTD (13.2%), systemic lupus erythematosus (6.6%), and Sjogren's syndrome (1.3%).

All the three CT signs described in CTD-related UIP had lower sensitivity individually (35.5–48.7%) but good specificity (75–85%) in diagnosing CTD-related UIP. With increasing number of signs being considered for diagnosis, the sensitivity for the detection of CTD decreased, whereas the specificity increased. Our results showed a similar trend as the previous study by Chung et al[10] which compared the performance of these CT signs in patients with IPF and CTD-related UIP. The sensitivity was slightly lower and specificity was slightly higher in the study by Chung et al.[10] In their study, the highest sensitivity was for AUL sign and SE sign (both had sensitivity of 25.4%), and the highest specificity was for EHC sign and SE sign (both had 94% specificity), whereas in our study, the highest sensitivity was for EHC sign and highest specificity was for SE sign. These difference may be partly due to the difference in the study group selection, as our comparison group had all cases with UIP pattern which are non–CTD related (includes IPF as well as other secondary causes of UIP other than CTD). We believe such comparison may be more appropriate as these imaging signs are primarily for helping a radiologist who may not have availability or access to the clinical and serological evaluation at the time of reporting, and the presence of these signs suggests that an underlying CTD is likely and needs further evaluation of the same. Because of good specificity of these signs, they can be considered as pointers which suggest the presence of underlying CTD in patients with UIP pattern of ILD on CT; however, the absence of these signs should not be taken as non–CTD-related UIP.

The limitation of our study was its retrospective design and the limited number of subjects. Also, as the study is done in a single tertiary referral center with an established rheumatology department, the proportion of each diagnosis may not be a representative sample in the general population. Undifferentiated CTD cases were not addressed in our study and were excluded from our cohort as they may represent an overlap between the groups. The number of such cases was also small for deriving any conclusion. Further multicentric, prospective studies on larger sample will be helpful.

Conclusion

Radiologists should actively look for AUL sign, EHC sign, and SE sign when evaluating UIP pattern on CT as these are significantly common in CTD-related ILD with UIP pattern. EHC sign was the most sensitive sign and SE sign was the most specific sign. Inclusion of more than one sign increases the specificity of diagnosis of CTD-related UIP; however, the sensitivity decreases. These signs can be used as specific imaging markers to diagnose underlying CTD; however, due to its low sensitivity, the absence of these signs cannot exclude the same. Because of its excellent interobserver agreement, these signs are reliable in the evaluation of CTD-related ILD.

Note

A part of this study was presented in competitive oral paper presentation during Third Annual National Conference of Society of Chest Imaging and Intervention (SCII CON 2021) and won second prize.

Author Contributions

All the authors contributed to the study conception and design. Material preparation, data collection and analysis were performed by A.A. and L.R.V. The first draft of the manuscript was written by A.A. and L.R.V., and all the authors commented on previous versions of the manuscript. All the authors read and approved the final manuscript.

Ethical Approval

This study was performed in line with the principles of the Declaration of Helsinki. Approval was granted by the Ethics Committee or Institutional Review Board of Christian Medical College, Vellore (September 15, 2020, No. 13306).

Informed Consent

Written informed consent was waived by the Institutional Review Board.

Study Design
This is a retrospective, cross-sectional study performed at one institution.

Funding
None.

Conflict of Interest
None declared.

References
1 Wuyts WA, Cavazza A, Rossi G, Bonella F, Sverzellati N, Spagnolo P. Differential diagnosis of usual interstitial pneumonia: when is it truly idiopathic? Eur Respir Rev 2014;23(133):308–319
2 Raghu G, Remy-Jardin M, Myers JL, et al; American Thoracic Society, European Respiratory Society, Japanese Respiratory Society, and Latin American Thoracic Society. Diagnosis of idiopathic pulmonary fibrosis. an official ATS/ERS/JRS/ALAT clinical practice guideline. Am J Respir Crit Care Med 2018;198(05):e44–e68
3 Lynch DA. Lung disease related to collagen vascular disease. J Thorac Imaging 2009;24(04):299–309
4 Kono M, Nakamura Y, Enomoto N, et al. Usual interstitial pneumonia preceding collagen vascular disease: a retrospective case control study of patients initially diagnosed with idiopathic pulmonary fibrosis. PLoS One 2014;9(04):e94775
5 Romagnoli M, Nannini C, Piciucchi S, et al. Idiopathic nonspecific interstitial pneumonia: an interstitial lung disease associated with autoimmune disorders? Eur Respir J 2011;38(02): 384–391
6 Sato T, Fujita J, Yamadori I, et al. Non-specific interstitial pneumonia; as the first clinical presentation of various collagen vascular disorders. Rheumatol Int 2006;26(06):551–555
7 Hu Y, Wang LS, Wei YR, et al. Clinical characteristics of connective tissue disease-associated interstitial lung disease in 1,044 Chinese patients. Chest 2016;149(01):201–208
8 Cottin V. Significance of connective tissue diseases features in pulmonary fibrosis. Eur Respir Rev 2013;22(129):273–280
9 Cottin V. Interstitial lung disease: are we missing formes frustes of connective tissue disease? Eur Respir J 2006;28(05):893–896
10 Chung JH, Cox CW, Montner SM, et al. CT features of the usual interstitial pneumonia pattern: differentiating connective tissue disease-associated interstitial lung disease from idiopathic pulmonary fibrosis. AJR Am J Roentgenol 2018;210(02):307–313
11 Subhash HS, Ashwin I, Solomon SK, David T, Cherian AM, Thomas K. A comparative study on idiopathic pulmonary fibrosis and secondary diffuse parenchymal lung disease. Indian J Med Sci 2004;58(05):185–190
12 Jindal SK, Malik SK, Deodhar SD, Sharma BK. Fibrosing alveolitis: a report of 61 cases seen over the past five years. Indian J Chest Dis Allied Sci 1979;21(04):174–179
13 Sen T, Udwadia ZF. Retrospective study of interstitial lung disease in a tertiary care centre in India. Indian J Chest Dis Allied Sci 2010; 52(04):207–211
14 Kundu S, Mitra S, Ganguly J, Mukherjee S, Ray S, Mitra R. Spectrum of diffuse parenchymal lung diseases with special reference to idiopathic pulmonary fibrosis and connective tissue disease: an eastern India experience. Lung India 2014;31(04):354–360
15 Maheshwari U, Gupta D, Aggarwal AN, Jindal SK. Spectrum and diagnosis of idiopathic pulmonary fibrosis. Indian J Chest Dis Allied Sci 2004;46(01):23–26
16 Sharma SK, Pande JN, Verma K, Guleria JS. Bronchoalveolar lavage fluid (BALF) analysis in interstitial lung diseases–a 7-year experience. Indian J Chest Dis Allied Sci 1989;31(03):187–196
17 Singh S, Collins BF, Sharma BB, et al. Interstitial lung disease in India. Results of a prospective registry. Am J Respir Crit Care Med 2017;195(06):801–813
18 Kim EA, Lee KS, Johkoh T, et al. Interstitial lung diseases associated with collagen vascular diseases: radiologic and histopathologic findings. Radiographics 2002;22(Spec No):S151–S165 Erratum in: Radiographics 2003;23(5):1340
19 Corte TJ, Copley SJ, Desai SR, et al. Significance of connective tissue disease features in idiopathic interstitial pneumonia. Eur Respir J 2012;39(03):661–668
20 Kligerman SJ, Groshong S, Brown KK, Lynch DA. Nonspecific interstitial pneumonia: radiologic, clinical, and pathologic considerations. Radiographics 2009;29(01):73–87

