Article published online: 2023-03-20

Additive Manufacturing of Titanium Implants for Skull Reconstruction in 2 Dogs after Bone Tumour Excision

Eline J.C. van den Brink[1] Guy C.M. Grinwis[2] Koen Willemsen[3,4] Floor Driessen[1] Susanne A.E.B. Boroffka[5] Björn P. Meij[1]

[1] Department of Clinical Sciences, Faculty of Veterinary Medicine, Utrecht University, Utrecht, the Netherlands
[2] Department of Biomolecular Health Sciences, Faculty of Veterinary Medicine, Utrecht University, Utrecht, the Netherlands
[3] Department of Orthopedics, University Medical Center Utrecht, Utrecht, the Netherlands
[4] Division of Surgical Specialties, University Medical Center Utrecht, Utrecht, the Netherlands
[5] Boroffka Diagnostic Imaging, Utrecht, the Netherlands

Address for correspondence Björn P. Meij, DVM, PhD, ECVS, Department of Clinical Sciences, Faculty of Veterinary Medicine, Utrecht University, Utrecht 3584 CM, the Netherlands (e-mail: b.p.meij@uu.nl; E.J.C.vandenBrink@uu.nl).

VCOT Open 2023;6:e61–e66.

Abstract

In two dogs, skull defects were closed with a patient-specific implant created by additive manufacturing after excision of tumours of the skull. Both dogs presented with a space-occupying mass in which excisional surgery without the use of implants would have resulted in incomplete closure due to extensive bone defects of the skull. The aim of the present case report is to describe the use of individualized three-dimensional-printed titanium implants for skull reconstruction following oncological surgery. The reconstructive implant-based surgeries performed in these patients were feasible without complications.

Keywords
- osteosarcoma
- osteoma
- 3D printing
- skull reconstruction
- tumour

Introduction

Additive manufacturing (AM) has been introduced in the medical field in the last decade, gaining popularity specifically in the field of maxillofacial, orthopaedic, oncological and spine surgery.[1–10] The availability of materials and printers has led to lower costs of patient-specific three-dimensional (3D) implants in human medicine bringing them also within the scope of the veterinary field.[11]

The use of individualized implants is the latest development in implant technology and offers a wide variety of opportunities and applications. To date, only few studies in veterinary medicine have used 3D individualized implants. Case reports have described 3D-printed implants for dogs with atlantoaxial subluxation, angular limb deformity, in limb-sparing surgery and in mandibular and maxillary surgery.[1–7] Three-dimensional-printed customized cages have also been used for tibial tuberosity advancement and for the treatment of cervical spondylomyelopathy.[8,9]

In contrast to fractures and defects in the appendicular skeleton, reconstruction of the skull and spine is often complicated due to the individual variety in anatomy or the lack of veterinary implants. The development of patient-specific 3D printing will improve surgical planning and enable successful surgical results in veterinary patients with extensive tumours of the skull.[12] The use of AM offers new surgical possibilities for patients who cannot benefit from existing surgical treatments. Practical experience from cases treated using this technique is valuable to accelerate the development of patient-specific 3D implants in the future.[13] The aim of the present case report is to describe

received
November 30, 2021
accepted after revision
September 2, 2022

DOI https://doi.org/10.1055/s-0042-1758679.
ISSN 2625-2325.

the use of individualized 3D-printed titanium implants for skull reconstruction following oncologic surgery.

Case Description

Case 1

A 2-year-old female neutered Siberian Husky was presented for depression and a mass on the right rostral calvarium. For further evaluation of the extension of the mass and metastasis control, a pre- and postcontrast computed tomography (CT) of the head and thorax was performed. Computed tomography showed an ossifying mass originating from the right frontal sinus and adjacent frontal bone (►**Fig. 1**). The mass measured approximately $4.2 \times 4.4 \times 5.1$ cm and had infiltrated the entire right frontal sinus and frontal neurocranium compressing the brain on the right side (►**Fig. 1**). Suspected CT diagnosis was a multilobular osteochondrosarcoma, osteosarcoma or osteoma. There was no evidence of metastases in the regional lymph nodes or the lungs.

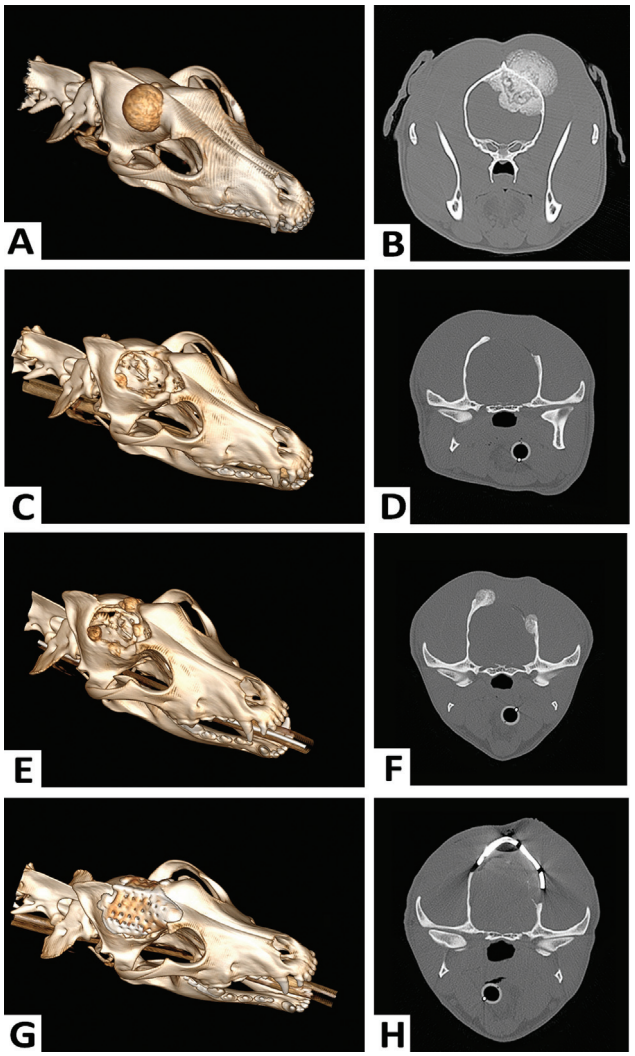

Fig. 1 Case 1: Three-dimensional (3D) computed tomography (CT) reconstruction (**A, C, E, G**) and transverse CT image (**B, D, F, H**) of a 2-year-old Siberian Husky with a calvarian osteoma. Before surgery (**A, B**), at 3 months (**C, D**), and 6 months (**E, F**) after surgical resection, and after revision surgical resection followed by reconstruction with a 3D-printed titanium implant (**G, H**).

The dog was anaesthetized using a protocol for intracranial surgery, a right trans sinus frontalis craniectomy was performed with 5 mm bone margins and the tumour was removed as one solid bony mass. Recovery was uneventful and the patient was discharged 2 days after surgery with antibiotic medications and analgesics. The solid bony mass needed extensive decalcification and histopathological examination showed proliferation of well-defined bony tissue, consistent with an osteoma (►**Fig. 2**). A follow-up CT scan at 3 months after surgery showed possible regrowth of the tumour which was confirmed 6 months post-surgery at four locations around the original craniectomy (►**Fig. 1**) without evidence of metastasis to the regional lymph nodes and lungs. Because total excision of the tumour recurrences with 10 mm margins would lead to removal of more than half of the calvarium, the option of AM to close the defect with an individualized implant was explored.

To design an AM individualized implant, first the digital imaging and communications in medicine files of the most recent CT scan (250 mAs, 120 kV, 0.6 mm slice thickness) were exported from the imaging archive system to Mimics v21 (Materialise, Leuven, Belgium) for anatomical segmentation. Standard bone threshold values (226 HU – upper threshold) were taken to outline the bone. Furthermore, the tumour recurrences were manually outlined together with a digitally drawn resection margin that was used to simulate the minimal needed resection area.

Thereafter, the anatomical models were transferred using stereolithography files to 3-matic software (v.13, Medical, NV, Leuven, Belgium) in which the design took place. The resection guide was designed around the tumour recurrences, including the digitally simulated 10 mm resection margin, and reviewed by a board-certified veterinary surgeon. Then the remaining skull was digitally reconstructed. The cranioplasty implant was designed as press fit and contained five extensions overlaying intact bone with screw holes for fixation to the skull and a porous mesh border (70% porous, 500–600 µm pore size, Diamond unit cell) to allow bony ingrowth at the implant bone interface (►**Fig. 2**).[14,15] Additionally, the midline ridge of the implant contained designated holes for suture attachment of the temporal muscle fascia and suture anchors through which muscles could be reattached. The surgical saw guide was 3D-printed in Nylon (PA12) on an EOS P110 printer (EOS, Krailling, Germany) and the implant was 3D-printed in medical grade titanium alloy Ti-6Al-4V ELI grade 23 using direct metal printing on a ProX DMP320 printer (3D Systems, Leuven, Belgium). Post-processing included polishing, cleaning and sterilization.Two months after the last CT scan, the dog underwent a second extended craniectomy with resection of the tumour recurrences and the 10 mm margin using the saw guide (►**Fig. 2**). The implant was fitted and secured into place using six 2.0 mm self-tapping titanium cortical screws (Unilock, DePuy Synthes, Johnson-Johnson, Oberdorf, Switzerland) ranging from 6 to 8 mm in length. The fascia of the temporal muscle was sutured through the 4 holes on

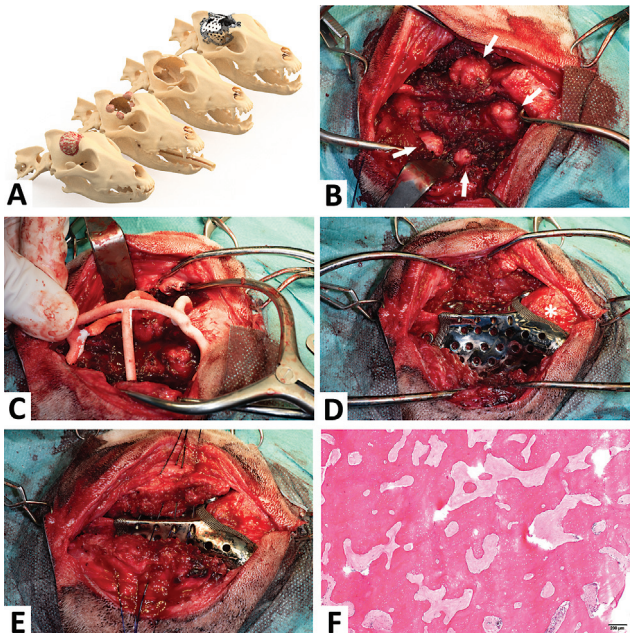

Fig. 2 Case 1: Sequential steps in surgical treatment of a 2-year-old Siberian Husky with a calvarian osteoma (**A**). Intraoperative views at moment of revision surgery, quadruple recurrences (*arrows*) are present at the first surgical rim (**B**). Placement of the saw guide (**C**) for the three-dimensional-printed titanium implant (**D**) extending over the right frontal sinus (*) and application of stay sutures for the attachment of the temporal muscle to the dorsal implant ridge (**E**). Histology of the mass showed well-differentiated, mainly immature (woven) bone and a cell-poor fibrous component most consistent with an osteoma. Haematoxylin and eosin stain, size bar = 200 µm (**F**).

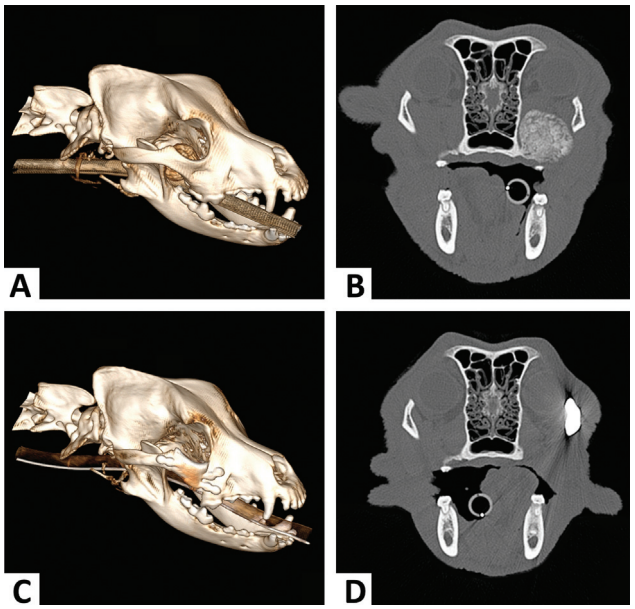

Fig. 3 Case 2: Three-dimensional computed tomography (3D CT) skull reconstruction (**A, C**) and transverse CT image (**B, D**) of a 11-year-old Labrador Retriever with a right zygomatic arch parosteal osteosarcoma involving the maxillary and orbital bones. Before surgery (**A, B**) and after surgical resection of the mass and reconstruction with a 3D-printed titanium implant (**C, D**).

the sagittal ridge of the implant. The subcutis and cutis were routinely closed. A postoperative CT was performed to assess the position of the implant. The dog received postoperative analgesia, was monitored and was discharged 2 days after surgery with antibiotic medications and routine analgesics. A follow-up CT was performed 4 months postoperatively and showed no signs of tumour regrowth and intact implant positioning identical to the immediate postoperative CT (►**Fig. 1**). The dog showed no clinical signs and the survival time at time of writing was 943 days.

Case 2

A 11-year-old female neutered Labrador Retriever was presented for the removal of a mass of the zygomatic bone causing problems with mastication. Computed tomography was performed for surgical planning and the mass measured 3 cm in diameter (►**Fig. 3**). Suspected CT diagnosis was a multilobular osteochondrosarcoma, osteoma or osteosarcoma. There was no evidence of metastases to the regional lymph nodes or the lungs. Using the same AM workflow as in case 1, a patient-specific 3D implant was designed based on the mirrored contralateral skull after complete tumour removal with 10 mm bone margins on the zygomatic, palatine and adjacent orbital bones. Because of clear bony landmarks, there was no need for a saw guide in this patient. The implant consisted of polished titanium with an unpolished titanium mesh around the edges to facilitate bone ingrowth and was manufactured using the same parameters as in case 1. Six weeks after the most recent CT scan, the dog was anaesthetized and the tumour was removed by approaching the zygomatic bone and cutting the bone with an oscillating saw at the predetermined land marks (►**Fig. 4**). The mass was resected completely including the zygomatic bone, maxilla including molars 109 and 110, palatine and adjacent orbital bones (►**Fig. 4**). The implant was secured using six 2.0 mm self-tapping titanium cortical screws (Unilock, DePuy Synthes, Johnson-Johnson, Oberdorf, Switzerland) ranging from 7 to 10 mm in length. The subcutis and cutis were routinely closed. A postoperative CT scan showed anatomical placement of the 3D-printed titanium implant (►**Fig. 3**). The patient was discharged 1 day after surgery with antibiotic medications and routine analgesics. The dog was offered soft food and was not allowed to chew on toys. One month after surgery, the patient showed no clinical signs and normal pellet food was reintroduced. Histopathological diagnosis of the tumour was consistent with a parosteal osteosarcoma. A follow-up CT scan 4 months after surgery showed no signs of recurrence or implant failure and some activity of bony ingrowth on the porous implant borders. The dog died 670 days after surgery of age-related problems, until the day of death the dog showed no clinical signs associated with the tumour or implant.

Discussion

These two cases describe the feasibility and the use of patient-specific customized implants in extensive reconstructive surgery of the skull. Both implants were designed

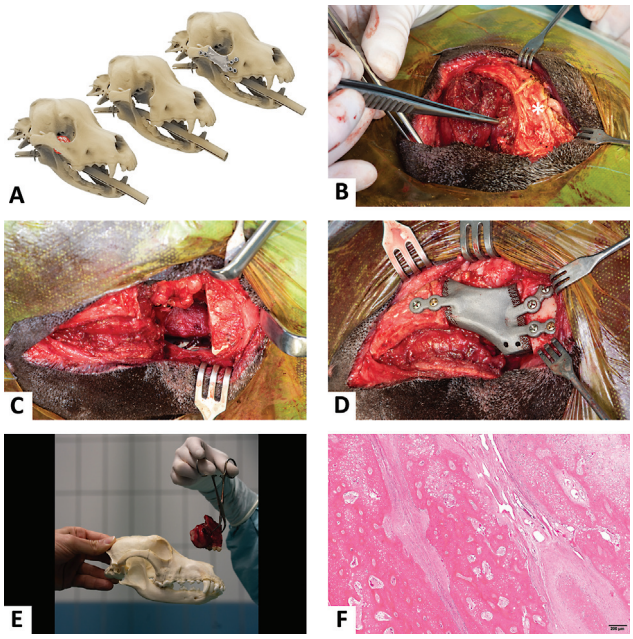

Fig. 4 Case 2: Sequential skull views during surgical treatment of an 11-year-old Labrador Retriever with a right zygomatic bone parosteal osteosarcoma (**A**). Intra-operative view showing the right zygomatic bone (*) with the forceps indicating the neoplasm (**B**), followed by surgical resection of part of the zygomatic bone and maxilla together with the neoplasm (**C**) and placement of the three-dimensional-printed titanium implant (**D**). Tumour after excision next to canine skull (**E**). Histology of the mass showed a moderately cellular spindle cell proliferation with formation of woven bone and a cartilaginous component most consistent with a parosteal osteosarcoma. Haematoxylin and eosin stain, size bar = 200 µm (**F**).

to precisely press fit into the craniectomy or ostectomy defect. This differs from the implant described by Oblak and Hayes who created a titanium implant that overlaid the frontal and temporal bones in a dog with reconstruction of the neurocranium after removal of a frontal bone tumor.[16] The press fit nature of the design of the implants created the need for a perfect osteotomy. Because clear anatomical margins were lacking for the location of the tumour in case 1, a saw guide was designed. The design needed to align with the skull perfectly to create the perfect osteotomy in this patient. To diminish costs, the saw guide was printed in Nylon (PA12). Previous work has shown that CT images provide accurate models of the skull.[17] The accuracy of the designing process, the quality of the program, the collaboration with the manufacturer and surgeon are all important to achieve a high-quality end result.[13]

The borders of both implants were made of a porous titanium mesh allowing bone ingrowth and therefore permanently embedding the implant into the skull, adding to the long-term durability. Although we have no histological prove that bone ingrowth occurred in our cases, both in vivo and in vitro push-out tests, micro-CT and histopathology have proven that bone ingrowth occurred in Ti6-Al4-V scaffolds in dogs and that the strength in implant embedding was increased.[18–21]

The solid part of the implant was polished, the mesh surface was unpolished. Polishing has proven to be beneficial in the reduction in the risk of biofilm formation compared with unpolished implants.[22] To obtain a smooth surface, implants can also be coated. Calcium-phosphate-coated porous titanium implants enhanced tissue ingrowth compared with porous implants without coating.[23] Preliminary results of an in vitro study showed promising results on the prevention of growth of tumour cells on the margins of selenium-coated implants.[24] For future cases, this could be of added benefit in bone reconstruction after tumour removal.

When using metal implants in orthopaedic surgery under strict asepsis, there is always a risk for implant-related infections. In an in vivo study, significantly more bacteria were cultured from implants with rough surfaces than from those with a smooth surface.[22] However, in non-coated implants with a porous mesh border that stimulated ingrowth of bone, an in vitro study showed that mesh also increased the risk of bacterial adhesion.[25] In the present case series, there were no clinical or radiological signs of implant-related infections, despite the use of a porous mesh at the borders of the implants.

Histologic examination of the tumour in case 1 showed well-differentiated, mainly immature bone and a cell-poor fibrous component most consistent with osteoma. Osteomas are usually locally invasive benign bone tumours where complete surgical excision is curative in most cases.[26] In this case, the histological diagnosis was not consistent with the clinical behaviour of the tumour which showed regrowth of the mass several months after removal and required extensive second-step excision surgery. This is suggestive of a more malignant tumour like multilobular osteochondrosarcoma. This tumour may show varying levels of malignancy in different histological sections.[26,27] Nevertheless, the final histopathological diagnosis confirmed an osteoma. The recurrence of the osteoma can be explained by insufficient margins during the initial resection. In case 1 metastasis was not identified until the day of writing. The appearance of the tumour on CT and consistency of the tumour after removal (solid bone) were in agreement with the histological diagnosis of osteoma. The reason for the recurrences was most likely due to the limited surgical margins (5 mm) during the first surgery and histopathologic examination was not able to differentiate between clear or dirty margins. The typical recurrence of the tumour in four small bone proliferations on the surgical margin of the first craniectomy is more consistent with an osteoma that was not completely resected.

As these were the first patients that received patient-specific 3D-printed implants in our hospital, the manufacturing and printing of the implants took more than 1 month.[1] The commercial company that printed the implants usually does not have a priority lane for veterinary implants which resulted in a long lead time between CT and the surgery date. This similar problem has been experienced by other surgeons and presents a problem in oncological

patients in which the tumour continues to grow after CT imaging.[24] Further developments in AM for veterinary use and start-up companies with a veterinary focus on patient-specific 3D printing should result in future decreased lead times for 3D-printed implants.

Little is known about the long-term effects and durability of 3D-printed implants. Although titanium has been used safely in osteosynthesis with long-term follow-up times, there is currently no long-term data on patient-specific implants in veterinary medicine. More research is needed to provide information on long-term results and possible side effects of the implants and the specific designs. It may be expected that intensified collaboration between human medicine and veterinary medicine accelerates development and broadens the knowledge on AM in veterinary surgery, thereby adding more applications for patient-specific implants in dogs and cats.

This case report describes two cases of extensive reconstructions after tumour excision of the skull with patient-specific customized titanium implants with porous edges. Three months postoperatively, both dogs were free of clinical signs and CT showed correct placement of implants without signs of tumour regrowth, implant loosening or infection. The use of partly porous titanium implants in craniomaxillary surgery in two dogs resulted in excellent clinical outcome with long-term survival and therefore may be considered as a treatment option in similar cases.

References

1 Kamishina H, Sugawara T, Nakata K, et al. Clinical application of 3D printing technology to the surgical treatment of atlantoaxial subluxation in small breed dogs. PLoS One 2019;14(05): e0216445

2 Carwardine DR, Gosling MJ, Burton NJ, O'Malley FL, Parsons KJ. Three-dimensional-printed patient-specific osteotomy guides, repositioning guides and titanium plates for acute correction of antebrachial limb deformities in dogs. Vet Comp Orthop Traumatol 2021;34(01):43–52

3 Choi S, Oh YI, Park KH, Lee JS, Shim JH, Kang BJ. New clinical application of three-dimensional-printed polycaprolactone/β-tricalcium phosphate scaffold as an alternative to allograft bone for limb-sparing surgery in a dog with distal radial osteosarcoma. J Vet Med Sci 2019;81(03):434–439

4 Séguin B, Pinard C, Lussier B, et al. Limb-sparing in dogs using patient-specific, three-dimensional-printed endoprosthesis for distal radial osteosarcoma: a pilot study. Vet Comp Oncol 2020; 18(01):92–104

5 Arzi B, Cissell DD, Pollard RE, Verstraete FJ. Regenerative approach to bilateral rostral mandibular reconstruction in a case series of dogs. Front Vet Sci 2015;2:4

6 Kim S, Mi Shim K, Jang K, Shim J, Kang S. Three-dimensional printing-based reconstruction of a maxillary bone defect in a dog following tumor removal. In Vivo 2018;32(01):63–70

7 Liptak JM, Thatcher GP, Bray JP. Reconstruction of a mandibular segmental defect with a customized 3-dimensional-printed titanium prosthesis in a cat with a mandibular osteosarcoma. J Am Vet Med Assoc 2017;250(08):900–908

8 Castilho M, Dias M, Vorndran E, et al. Application of a 3D printed customized implant for canine cruciate ligament treatment by tibial tuberosity advancement. Biofabrication 2014;6(02): 025005

9 Joffe MR, Parr WCH, Tan C, Walsh WR, Brunel L. Development of a customized interbody fusion device for treatment of canine disc-associated cervical spondylomyelopathy. Vet Comp Orthop Traumatol 2019;32(01):79–86

10 Willemsen K, Tryfonidou MA, Sakkers RJB, et al. Patient-specific 3D-printed shelf implant for the treatment of hip dysplasia tested in an experimental animal pilot in canines. Sci Rep 2022;12(01): 3032

11 Willemsen K, Tryfonidou M, Sakkers R, et al. Patient-specific 3D-printed shelf implant for the treatment of hip dysplasia: anatomical and biomechanical outcomes in a canine model. J Orthop Res 2022;40(05):1154–1162

12 Rotaru H, Schumacher R, Kim SG, Dinu C. Selective laser melted titanium implants: a new technique for the reconstruction of extensive zygomatic complex defects. Maxillofac Plast Reconstr Surg 2015;37(01):1–6

13 Willemsen K, Nizak R, Noordmans HJ, Castelein RM, Weinans H, Kruyt MC. Challenges in the design and regulatory approval of 3D-printed surgical implants: a two-case series. Lancet Digit Health 2019;1(04):e163–e171

14 Taniguchi N, Fujibayashi S, Takemoto M, et al. Effect of pore size on bone ingrowth into porous titanium implants fabricated by additive manufacturing: an in vivo experiment. Mater Sci Eng C 2016;59:690–701

15 Van der Stok J, Van der Jagt OP, Amin Yavari S, et al. Selective laser melting-produced porous titanium scaffolds regenerate bone in critical size cortical bone defects. J Orthop Res 2013;31(05): 792–799

16 Oblak M, Hayes G. Use of a custom additive manufactured titanium plate for cranioplasty in a dog with multilobular osteochondrosarcoma. Abstract. European College Veterinary Surgeons 28th Annual Scientific Meeting, July 2–4, 2019, Budapest, Hungary

17 Comrie ML, Monteith G, Zur Linden A, Oblak M, Phillips J, James FMKOntario Veterinary College Rapid Prototyping of Patient-specific Implants for Dogs (RaPPID) group. The accuracy of computed tomography scans for rapid prototyping of canine skulls. PLoS One 2019;14(03):e0214123

18 Wang H, Su K, Su L, Liang P, Ji P, Wang C. The effect of 3D-printed Ti_6Al_4V scaffolds with various macropore structures on osteointegration and osteogenesis: a biomechanical evaluation. J Mech Behav Biomed Mater 2018;88:488–496

19 Wang H, Su K, Su L, Liang P, Ji P, Wang C. Comparison of 3D-printed porous tantalum and titanium scaffolds on osteointegration and osteogenesis. Mater Sci Eng C 2019;104:109908

20 Tanzer M, Chuang PJ, Ngo CG, Song L, TenHuisen KS. Characterization of bone ingrowth and interface mechanics of a new porous 3D printed biomaterial: an animal study. Bone Joint J 2019;101-B (6_Supple_B, Supple_B):62–67

21 Reints Bok TE, Willemsen K, van Rijen MHP, Grinwis GCM, Tryfonidou MA, Meij BP. Instrumented cervical fusion in nine dogs with caudal cervical spondylomyelopathy. Vet Surg 2019;48 (07):1287–1298

22 McGaffey M, Zur Linden A, Bachynski N, Oblak M, James F, Weese JS. Manual polishing of 3D printed metals produced by laser powder bed fusion reduces biofilm formation. PLoS One 2019; 14(02):e0212995

23 Bose S, Banerjee D, Shivaram A, Tarafder S, Bandyopadhyay A. Calcium phosphate coated 3D printed porous titanium with nanoscale surface modification for orthopedic and dental applications. Mater Des 2018;151:102–112

24 Nimwegen B. Head & Neck tumors: diagnosis, staging, surgery, and multimodal treatment. Abstract. Voorjaarsdagen European

Veterinary Conference, April 10–12, 2019, The Hague, The Netherlands
25 Xie K, Guo Y, Zhao S, et al. Partially melted Ti6Al4V particles increase bacterial adhesion and inhibit osteogenic activity on 3D-printed implants: an in vitro study. Clin Orthop Relat Res 2019; 477(12):2772–2782
26 Erhart N, Christensen N, Fan T. Tumors of the skeletal system. In: Vail D, Thamm D, Liptak L, eds. Withrow and MacEwan's Small animal Oncology. 6th ed. St. Louis: Elsevier; 2020:551–2
27 Dernell WS, Straw RC, Cooper MF, Powers BE, LaRue SM, Withrow SJ. Multilobular osteochondrosarcoma in 39 dogs: 1979-1993. J Am Anim Hosp Assoc 1998;34(01):11–18