





Gestational Choriocarcinoma Manifesting as Spontaneous Hemothorax in Third Trimester of Pregnancy: A Case Report

Suma Devaraj¹ Soumya Surath Panda¹ Debasish Sahu² Debahuti Mohapatra³
Beena Devi Agarwal⁴ Ghanashyam Biswas¹ Lalatendu Moharana¹ Sindhu Kilaru¹ Spoorthy Kolluri¹

¹ Department of Medical Oncology, Institute of Medical Sciences & SUM Hospital, Bhubaneswar, Odisha, India

² Department of Cardiothoracic Vascular Surgery, Institute of Medical Sciences & SUM Hospital, Bhubaneswar, Odisha, India

³ Department of Pathology, Institute of Medical Sciences & SUM Hospital, Bhubaneswar, Odisha, India

⁴ Department of Radiodiagnosis, Institute of Medical Sciences & SUM Hospital, Bhubaneswar, Odisha, India

Address for correspondence Suma Devaraj, MD, Department of Medical Oncology, Institute of Medical Sciences & SUM Hospital, Bhubaneswar 751003, Odisha, India (e-mail: sumadevaraj26@gmail.com).

Ind J Med Paediatr Oncol 2022;43:513–517.

Abstract

Gestational trophoblastic neoplasia (GTN) is an aggressive malignancy arising from the trophoblastic tissue. It is rarely seen in association with advanced intrauterine pregnancy. Most common manifestations are due to bleeding caused by the rich vascularity of trophoblastic tissue. We describe here a case of a 28-year-old female patient who presented to us at 32 weeks of pregnancy with sudden onset dyspnea and hemodynamic instability. On evaluation, imaging techniques revealed a gross left hemothorax requiring intercostal tube insertion for stabilization. Emergency thoracotomy and hemothorax drainage were performed wherein a tumor mass in the lower lobe of left lung was identified and resected. Histopathological examination confirmed the diagnosis of choriocarcinoma. Beta HCG levels were found to be elevated. Final diagnosis of a FIGO stage IV high-risk gestational choriocarcinoma was made. Following this, six cycles of multi-agent EMA-CO chemotherapy was administered to the patient. Patient had an excellent response to treatment with documented serial fall in β HCG levels and she continues to be in remission after 6 months of follow-up. In conclusion, in the circumstance of any pregnant women presenting with abnormal bleeding symptoms such as hemothorax, choriocarcinoma as a cause should be considered for early diagnosis and effective management.

Keywords

- ▶ gestational choriocarcinoma
- ▶ hemothorax
- ▶ pregnancy

Introduction

Gestational trophoblastic neoplasia (GTN) represents a spectrum of proliferative abnormalities of trophoblasts associated with pregnancy.¹ Choriocarcinoma is a highly aggressive form of gestational trophoblastic disease presenting with early distant metastasis due to high metastatic potential.² Although molar pregnancies are most commonly associated

with choriocarcinoma, 25% of cases follow previous abortions, while 22.5% arise in normal pregnancy, and 2.5% are subsequent to ectopic pregnancy. All cases are associated with elevated β human chorionic gonadotrophin (HCG) levels.³

While choriocarcinoma generally presents with gynecological manifestations such as vaginal bleeding, as many as

DOI <https://doi.org/10.1055/s-0042-1758525>.
ISSN 0971-5851.

© 2022. The Author(s).

This is an open access article published by Thieme under the terms of the Creative Commons Attribution License, permitting unrestricted use, distribution, and reproduction so long as the original work is properly cited. (<https://creativecommons.org/licenses/by/4.0/>)

Thieme Medical and Scientific Publishers Pvt. Ltd., A-12, 2nd Floor, Sector 2, Noida-201301 UP, India

one-third of the patients can manifest with only non-gynecological symptoms due to metastases to various sites.⁴ Favored sites of metastases are lungs (80%), followed by vagina (30%), brain (10%), and liver (10%).² Abnormal bleeding at these locations could be the primary presentation due to the rich vascularity of lesions at these sites.⁵ Pulmonary metastatic choriocarcinoma mainly presents with hemoptysis, dyspnea, pleuritic pain, and cough⁶; pleural effusion or non-traumatic hemothorax being rare manifestations.⁷ Metastatic gestational choriocarcinoma presenting in a normal intrauterine pregnancy is exceptionally rare and is assigned a higher World Health Organization (WHO) score with historically high maternal and fetal mortality.⁸ Herein, we report a rare case of spontaneous hemothorax in the third trimester of pregnancy leading to a diagnosis of choriocarcinoma.

Case Presentation

A 28-year-old housewife presented at 32 weeks of gestation to the institution with 2-day history of progressive dyspnea and reduced fetal movements. She was triaged as G2P1L1 with a 3-year-old female child and present spontaneous conception. Her first and second trimesters were uneventful. She developed mild breathlessness and discomfort 2 days ago, which subsided on their own, however, were aggravated on the morning of day of admission. She had no significant medical or family history.

Patient was irritable and tachypneic with signs of tachycardia and hypoxia. Clinical examination was significant for reduced breath sounds in the left hemithorax. A chest X-ray showed a massive pleural effusion in the left lung. A subsequent CT scan of the thorax revealed gross left hemothorax with internal organized hyperdense content causing a contralateral shift of mediastinum and compression of the left lung. A few focal small hyperdense organized hematomas were also observed along the left diaphragmatic pleura. Another small hypodense lesion with peripheral eccentric nodular enhancement in collapsed left lower lobe was suspected of being a capillary hemangioma (→Fig. 1A). An intercostal drainage tube was placed to decompress the left hemithorax. She had severe anemia requiring multiple blood transfusions. The obstetric ultrasonogram showed a single intrauterine fetal demise (IUD) of 33 weeks 4 days gestation with a normal placenta.

An emergency thoracotomy and hemothorax drainage with clot removal were performed. A mass in the lower lobe of the left lung (→Fig. 1B) and another vascular mass in the apex of chest wall were identified. Wedge resection of the former site and sclerotherapy of the latter site were performed. The patient also underwent a lower segment cesarean section and a 2.2 kg preterm IUD fetus was delivered. The placental examination did not reveal any abnormality. The histopathological examination of the lung mass was suggestive of a poorly differentiated malignant tumor compatible with choriocarcinoma (→Fig. 1C). These tumor cells showed positive immunohistochemical (IHC) staining for PANCK (pan cytokeratin) and β HCG suggestive of choriocarcinoma (→Fig. 1D). Serum β HCG level was reported to

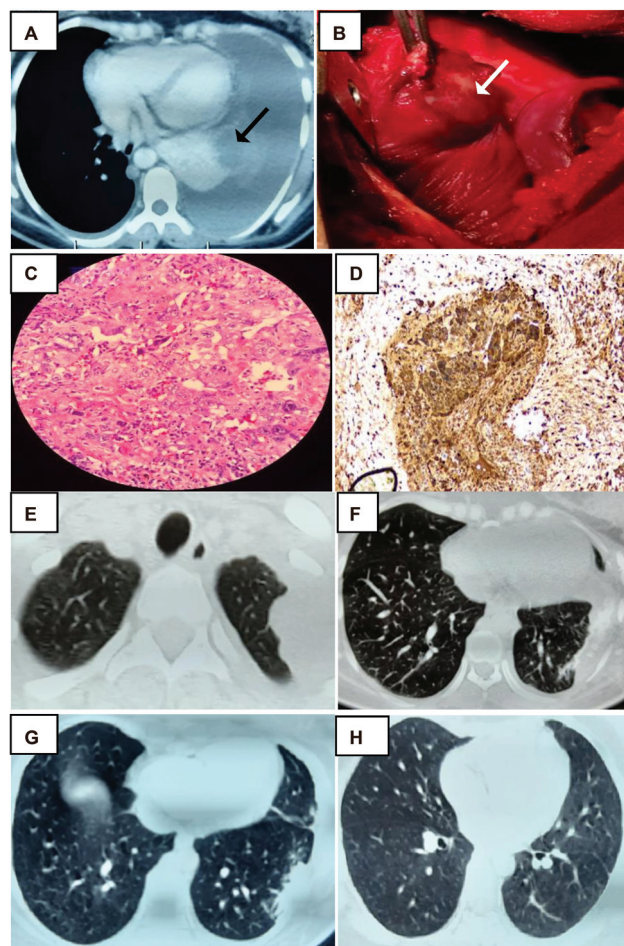


Fig. 1 CT thorax showing hemothorax, lesion in left lower lobe (black arrow). (A). Intraoperative lung mass (white arrow). (B) Syncytiotrophoblast surrounded by cytotrophoblast in biopsy and IHC positive for β HCG. (C and D) Post-surgery CT thorax - residual lesions in the left upper and lower lobe. (E and F) CT thorax post treatment with soft calcified nodule over left upper lobe and normal lower lobe (G and H).

be 25,600 mIU/mL and α fetoprotein level was found to be 5.3 ng/mL clinching the diagnosis of metastatic gestational choriocarcinoma.

Follow-up CT imaging of the thorax showed residual pleural-based lesions in apical segment of the left upper and lower lobes of the lungs (→Figs. 1E and 1F). An observation of left pleural minimal-organized hemothorax was also noted. CT scans of the abdomen and pelvis confirmed a bulky uterus with enhancing submucosal vasculature suggestive of post cesarean changes. MRI scan of the brain did not reveal any metastases.

A diagnosis of stage IV high-risk choriocarcinoma based on the International Federation of Gynecology and Obstetrics (FIGO) system was made. The WHO score was declared as 10 [antecedent pregnancy (2), HCG (2), site (4), number of metastases (1), size (1)]. The patient was started on chemotherapy that consisted of six cycles of intravenous EMA-CO protocol (etoposide 100 mg/m², methotrexate 100 mg/m² bolus, and 200 mg/m² infusion over 12 hours and actinomycin D 0.5 mg on first day; etoposide 100 mg/m², actinomycin D 0.5 mg on the second day with four doses of 15 mg folinic

Table 1 Chronological trend of β HCG levels (mIU/mL)

Date	Beta HCG (mIU/mL)
17/03/2021	25,600
31/03/2021	91,900
29/04/2021	1335
21/05/2021	23.66
25/06/2021	0.730
21/09/2021	0.187
19/10/2021	< 0.100
09/11/2021	< 0.100
16/02/2022	< 0.100

acid rescue every 12 hours from 24 hours after beginning of methotrexate; cyclophosphamide 600 mg/m² and vincristine 1 mg/m² on the eighth day and intrathecal methotrexate (12.5 mg) delivered every three weekly for all cycles.

There was remarkable response to chemotherapy in the form of shrinkage of metastatic foci and dramatic decline of serum β HCG to below-detectable levels. Post-therapy CT scan revealed a small nodule over the upper lobe of left lung with soft calcification (**Fig. 1G** and **1H**). The patient is currently on follow-up after 6 months and doing well with normal serum β HCG values (**Table 1**).

Discussion

In the developed world, the incidence of gestational choriocarcinoma is estimated to be ~1 in 40,000 pregnancies; being much lower (1 in 160,000 pregnancies) in the setting of a viable gestation.⁹ In Asia, Africa, and Latin America, this ratio is reported to be 1 per 500 to 1,000 pregnancies.¹⁰ Malignant potential of the disease is also reported to be higher in Southeast Asia, which is 10 to 15% compared with 2 to 4% in the West.¹¹

In our patient, spontaneous hemothorax occurred simultaneously with a third trimester intrauterine pregnancy presenting a diagnostic dilemma. This diagnosis is exceptionally rare and has a poor maternal and fetal prognosis. Worldwide literature review of cases by Steigrad et al could identify a total of 36 cases of gestational choriocarcinoma coexisting with a normal intrauterine pregnancy in the 20th century. Both mother and fetus survived in only 25% of the cases.⁸ Our patient was initially suspected to have a vascular cause for the hemothorax such as capillary hemangioma and underwent thoracotomy. Hemothorax may be a result of vascular invasion by trophoblastic emboli causing pulmonary infarction or due to direct involvement of pleura.⁷ In this case, hemothorax may be attributed to the rupture of the metastatic lung nodule as well as bleeding from the pleural-based lesion.

Trophoblastic tumors are usually perfused by fragile vessels. Trophoblastic cells have the innate capacity to invade and erode the capillary vessel wall leading to hemorrhage.¹²

Conversion of normal trophoblast cells in the current gestation, transformation of residual trophoblast tissue from a previous pregnancy or conversion of one of the products of conception in a multiple fetal pregnancy are some of the theories postulated to explain choriocarcinoma in an ongoing viable pregnancy.⁴ Also, the placental examination and pelvic imaging in our patient did not reveal any primary focus of choriocarcinoma. The lack of primary focus may be explained by persistence of metastatic foci despite spontaneous regression of the primary tumor; resurrection and malignant change of trophoblastic cells present in the extra-uterine vessels under stimulation of endocrine factors during the current pregnancy; and intra-placental choriocarcinomas having more minute microscopic foci without overt macroscopic presentation that are not picked up on pathological examination.⁴ Regrettably, the diagnosis of choriocarcinoma as the cause of hemothorax was established only after thoracotomy and histopathological examination of the metastatic tissue, which prompted the measurement of serum β HCG levels leading to a considerable delay in initiation of chemotherapy from the presentation.

Successful outcome of a pregnancy in gestational choriocarcinoma presenting after 24 weeks of pregnancy have been documented in a few case reports.^{4,5,13,14} While most cases of hemothorax associated with choriocarcinoma have been in the setting of prior history of abortion or amenorrhea^{15–20}; very few instances of spontaneous hemothorax with advanced intrauterine pregnancy have been reported. Sudduth described an occurrence of bilateral hemothoraces due to choriocarcinoma in a woman presenting at 32 weeks of amenorrhea wherein a healthy male infant was delivered.¹⁴ Our patient unfortunately had an intrauterine fetal demise at presentation. Massive bleeding within the pleural cavity and delayed presentation could be one of the reasons for fetal demise. This emphasizes the importance of considering choriocarcinoma as a possibility in any pregnant woman presenting with the rare scenario of spontaneous hemothorax for establishing early diagnosis and initiation of appropriate therapy for a better maternal and fetal outcome.

Despite presenting with metastasis, choriocarcinoma is a highly chemotherapy sensitive tumor. The stage and risk score of the disease at the time of diagnosis determine the chemotherapy regimen used. The FIGO staging system identifies four stages based on the extent of the disease, whereas the WHO prognostic scoring system gives a numerical score on the basis of the patient and tumor characteristics.²¹ Our patient was high risk in view of antecedent pregnancy and pleural metastasis.

Low-risk groups with FIGO stage I or stage II and III with a WHO risk score below 7 are treated with single-agent chemotherapy regimen (methotrexate or actinomycin D) to obtain maximum remission rates with less toxicity.²² However, high-risk patients (FIGO stage IV or stage II and III with a WHO risk score over 6) require first-line multi-agent chemotherapy regime in view of risk of resistance to single-agent chemotherapy. The combination of the drugs etoposide, methotrexate, actinomycin D, cyclophosphamide, and vincristine (EMA-CO) is the regimen of choice.²³

Complete remission rate in low-risk groups is nearly 80% after single-agent chemotherapy with an overall survival rate of almost 100% with multi-agent therapy and recurrence rates are less than 5%. While 85% of stage II and 75% of stage III patients attain full remission after front-line multi-agent chemotherapy, overall cure rates reach 95 to 100% after secondary therapy. In stage IV groups, up to 80% of patients are ultimately cured with intensive multi-agent therapy and radiation or surgical adjuvant therapy when needed. Depending on the initial stage, recurrence rates vary between 8 and 10%.²⁴ Chemotherapy is continued until HCG values have normalized followed by at least two to three courses of consolidation chemotherapy for the purpose of eradicating all viable tumors.²¹

Patients failing the EMA-CO regimen are mostly salvaged with paclitaxel and etoposide alternating with paclitaxel and cisplatin (TE/TP) or with EP/EMA (etoposide, cisplatin, etoposide, methotrexate and actinomycin-D). For women failing EP/EMA or TE/TP, options include high-dose chemotherapy (HDC) regimens with autologous peripheral stem cell support and immunotherapy.²¹ A recent retrospective analysis reported remission rates of 41% with HDC and peripheral stem cell support. An HCG level > 12 IU/L before or after HDC, stages II–IV, and presence of metastases were all associated with adverse survival outcomes. However, HDC was associated with significant toxicity with a procedure mortality in 3 out of 32 patients.²⁵

GTN tissue constitutively and strongly expresses programmed cell death ligand 1 (PD-L1).²⁶ The significant advances in immunotherapy in recent years has led to the use of immune checkpoint inhibitors in GTN. The PD-1 (programmed cell death 1) inhibitor drug pembrolizumab has demonstrated efficacy in a few cases of unresectable, chemo-resistant GTN.^{27,28} The PD-L1 inhibitor avelumab has also shown efficacy in GTN, inducing complete serological response in ~53% of patients who had previously received single-agent methotrexate or actinomycin-D. One patient subsequently had a normal pregnancy as well.²⁹ Anti-PD-1/anti-PD-L1 treatment is generally tolerated well with minimal toxicity as reported in majority of patients. It presents a much less toxic alternative to HDC with autologous stem cell transplantation.²⁸

All patients require post-treatment surveillance through checking for β HCG levels for detection of recurrences. After HCG value is normalized, serial determinations of HCG levels are continued at 2-week intervals during the first 3 months of remission and then at monthly intervals for at least 12 months.³⁰

Conclusion

Spontaneous hemothorax is a life-threatening emergency. It can be one of the rare presentations of metastatic gestational choriocarcinoma in the setting of a current pregnancy. Our case emphasizes the need for a strong clinical suspicion in any pregnant woman presenting with abnormal bleeding symptoms such as hemothorax despite the absence of a detectable primary focus of choriocarcinoma. This is to

ensure early diagnosis and management of this chemosensitive tumor.

Declaration of Patient Consent

Informed consent of the patient was acquired.

Funding

None.

Conflict of Interest

None declared.

References

- Berkowitz RS, Goldstein DP. Chorionic tumors. *N Engl J Med* 1996; 335(23):1740–1748. Doi: 10.1056/NEJM199612053352306
- Wreczycka-Cegielyny P, Cegielyny T, Oplawski M, Sawicki W, Kojs Z. Current treatment options for advanced choriocarcinoma on the basis of own case and review of the literature. *Ginekol Pol* 2018;89 (12):711–715. Doi: 10.5603/GPa.2018.0120
- Braun-Parvez L, Charlin E, Caillard S, et al. Gestational choriocarcinoma transmission following multiorgan donation. *Am J Transplant* 2010;10(11):2541–2546. Doi: 10.1111/j.1600-6143.2010.03275.x
- Yu P, Diao W, Jiang X. A successfully treated metastatic choriocarcinoma coexistent with pregnancy: a case report of a 4-year follow-up. *Medicine (Baltimore)* 2016;95(21):e3505. Doi: 10.1097/MD.00000000000003505
- Álvarez-Sarrado L, González-Ballano I, Herrero-Serrano R, Giménez-Molina C, Rodríguez-Solanilla B, Campillos-Maza JM. Hemoptysis as the first symptom in the diagnosis of metastatic choriocarcinoma in the third trimester of pregnancy: a case report. *Case Rep Womens Health* 2020;27:e00211
- Mangla M, Singla D, Kaur H, Sharma S. Unusual clinical presentations of choriocarcinoma: a systematic review of case reports. *Taiwan J Obstet Gynecol* 2017;56(01):1–8. Doi: 10.1016/j.tjog.2015.05.011
- Saha K, Basuthakur S, Jash D, Bandyopadhyay A. Gestational choriocarcinoma presenting as hemothorax. *Indian J Med Sci* 2010;64(05):237–240
- Steigrad SJ, Cheung AP, Osborn RA. Choriocarcinoma co-existent with an intact pregnancy: case report and review of the literature. *J Obstet Gynaecol Res* 1999;25(03):197–203. Doi: 10.1111/j.1447-0756.1999.tb01147.x
- Soper JT, Mutch DG, Schink JCAmerican College of Obstetricians and Gynecologists. Diagnosis and treatment of gestational trophoblastic disease: ACOG Practice Bulletin No. 53. *Gynecol Oncol* 2004;93(03):575–585. Doi: 10.1016/j.ygyno.2004.05.013
- Buckley JD. The epidemiology of molar pregnancy and choriocarcinoma. *Clin Obstet Gynecol* 1984;27(01):153–159. Doi: 10.1097/00003081-198403000-00022
- Balogopal P, Pandey M, Chandramohan K, Somanathan T, Kumar A. Unusual presentation of choriocarcinoma. *World J Surg Oncol* 2003;1(01):4
- Huang CY, Chen CA, Hsieh CY, Cheng WF. Intracerebral hemorrhage as initial presentation of gestational choriocarcinoma: a case report and literature review. *Int J Gynecol Cancer* 2007;17 (05):1166–1171. Doi: 10.1111/j.1525-1438.2007.00934.x
- Kulkarni R, Lister UG. Metastatic choriocarcinoma coexisting with full term viable pregnancy. *Postgrad Med J* 1985;61(721):1013–1014. Doi: 10.1136/pgmj.61.721.1013
- Sudduth CD, Strange C, Campbell BA, Sahn SA. Metastatic choriocarcinoma of the lung presenting as hemothorax. *Chest* 1991;99 (02):527–528. Doi: 10.1378/chest.99.2.527b
- DeFrance JH, Blewett JH Jr, Ricci JA, Patterson LT. Massive hemothorax: two unusual cases. *Chest* 1974;66(01):82–84. Doi: 10.1378/chest.66.1.82

- 16 Wolkove N, Gervais A, Kreisman H, Frank H, Lachance RC. Choriocarcinoma presenting as hemothorax. *Can Med Assoc J* 1981; 124(12):1599–1600
- 17 Lazovic B, Milenkovic V. Gestational choriocarcinoma with hemorrhagic pleural effusion. *Arch Oncol* 2010;18(03):86–87. Doi: 10.2298/aoo1003086l
- 18 Yangki S. Pulmonary metastatic choriocarcinoma presenting as hemodynamically unstable patient with hemothorax. *The Turkish Journal of Thoracic and Cardiovascular Surgery*. 2016;24(03): 582–584. Doi: 10.5606/tgkdc.dergisi.2016.11699
- 19 Seetharaman ML, Arora R, Arora VK. Gestational choriocarcinoma with haemorrhagic pleural effusion. *Indian J Chest Dis Allied Sci* 1991;33(01):39–42
- 20 Buza N, Baine I, Hui P. Precision genotyping diagnosis of lung tumors with trophoblastic morphology in young women. *Mod Pathol* 2019; 32(09):1271–1280. Doi: 10.1038/s41379-019-0275-z
- 21 Ngan HYS, Seckl MJ, Berkowitz RS, et al. Update on the diagnosis and management of gestational trophoblastic disease. *Int J Gynaecol Obstet* 2018;143(Suppl 2):79–85. Doi: 10.1002/ijgo.12615
- 22 Dhanda S, Ramani S, Thakur M. Gestational trophoblastic disease: a multimodality imaging approach with impact on diagnosis and management. *Radiol Res Pract* 2014;2014:842751. Doi: 10.1155/2014/842751
- 23 Cagayan MS. High-risk metastatic gestational trophoblastic neoplasia. Primary management with EMA-CO (etoposide, methotrexate, actinomycin D, cyclophosphamide and vincristine) chemotherapy. *J Reprod Med* 2012;57(5-6):231–236
- 24 May T, Goldstein DP, Berkowitz RS. Current chemotherapeutic management of patients with gestational trophoblastic neoplasia. *Chemother Res Pract* 2011;2011:806256. Doi: 10.1155/2011/806256
- 25 Frijstein MM, Lok CAR, Short D, et al. The results of treatment with high-dose chemotherapy and peripheral blood stem cell support for gestational trophoblastic neoplasia. *Eur J Cancer* 2019; 109:162–171. Doi: 10.1016/j.ejca.2018.12.033
- 26 Veras E, Kurman RJ, Wang TL, Shih IM. PD-L1 expression in human placentas and gestational trophoblastic diseases. *Int J Gynecol Pathol* 2017;36(02):146–153. Doi: 10.1097/PGP.0000000000000305
- 27 Ghorani E, Kaur B, Fisher RA, et al. Pembrolizumab is effective for drug-resistant gestational trophoblastic neoplasia. *Lancet* 2017;390(10110):2343–2345. Doi: 10.1016/S0140-6736(17)32894-5
- 28 Clark JJ, Slater S, Seckl MJ. Treatment of gestational trophoblastic disease in the 2020s. *Curr Opin Obstet Gynecol* 2021;33(01): 7–12. Doi: 10.1097/GCO.0000000000000674
- 29 You B, Bolze PA, Lotz JP, et al. Avelumab in patients with gestational trophoblastic tumors with resistance to single-agent chemotherapy: cohort A of the TROPHIMMUN phase II trial. *J Clin Oncol* 2020;38(27):3129–3137. Doi: 10.1200/JCO.20.00803
- 30 Soper JT. Gestational trophoblastic disease: current evaluation and management. [published correction appears in *Obstet Gynecol*. 2022 Jan 1;139(1):149] *Obstet Gynecol* 2021;137(02): 355–370 Doi: 10.1097/AOG.00000000000004240