



Evidences in Uterine Artery Embolization: A Radiologist's Primer

Pavankumar Bellala¹ Jineesh Valakkada¹ Anoop Ayyappan¹ Santhosh Kumar¹

¹Department of Imaging Sciences and Interventional Radiology, Sreechitra Institute of Medical Sciences and Technology, Trivandrum, Kerala, India

Address for correspondence Jineesh Valakkada, MD, Department of Imaging Sciences and Interventional Radiology, Sreechitra Institute of Medical Sciences and Technology, Trivandrum 695011, Kerala, India (e-mail: jineesh174@gmail.com).

J Clin Interv Radiol ISVIR 2023;7:87–96.

Abstract

Uterine artery embolization is an established minimally invasive therapy for symptomatic fibroids. It has also been used for other diseases of the uterus, including adenomyosis, uterine arteriovenous malformation, ectopic pregnancy, abnormal invasive placenta, and postpartum hemorrhage. In this review, we provide an updated and comprehensive review of uterine artery embolization based on the evidence published. We review the indications, the role of MRI, technical aspects, and complications of the procedure. The issues with a future pregnancy, risk of infertility, and fetal radiation are discussed as well.

Keywords

- ▶ uterine artery embolization
- ▶ fibroids
- ▶ arteriovenous malformation
- ▶ pseudoaneurysm
- ▶ perinatal period
- ▶ ectopic pregnancy

Introduction

Diseases related to the uterus, such as uterine fibroids, adenomyosis, and pregnancy-related uterine and placental diseases constitute a major part of morbidity in women. Many of these patients eventually undergo invasive surgical therapy when medical management fails. Minimally invasive therapies such as uterine artery embolization (UAE) are safe and effective for many of these conditions. However, there are concerns regarding appropriate indications, future infertility risk, and radiation injury with UAE. The published literature is heterogenous and often confusing. We attempt to provide an updated and comprehensive evidence-based review regarding indications, the role of imaging, technical aspects, complications, radiation and infertility concerns of uterine artery embolization in various uterine pathologies.

UAE for Fibroids

Uterine fibroids are the most common benign pelvic tumors in women with a prevalence ranging from 4.5 to 68% depending on study population.¹ Around 25 to 50% of these patients are symptomatic with bleeding or pelvic pain. Around 30% of these patients resort to invasive surgical therapies including myomectomy or hysterectomy.¹ The number of UAE procedures for fibroids is increasing and various societies have suggested guidelines with subtle differences (▶ **Table 1**). While the Society of Interventional Radiology (SIR) guidelines of 2014 recommended UAE for all symptomatic fibroids, the Royal College of Gynecology (RCOG) endorses primary myomectomy as the first line option in patients who wish for future pregnancy, with UAE reserved for surgically unfit patients.² The Cardiovascular Interventional Radiology Society of Europe (CIRSE) standards of practice

article published online
October 23, 2022

DOI <https://doi.org/10.1055/s-0042-1758050>.
ISSN 2457-0214.

© 2022. Indian Society of Vascular and Interventional Radiology. All rights reserved.

This is an open access article published by Thieme under the terms of the Creative Commons Attribution-NonDerivative-NonCommercial-License, permitting copying and reproduction so long as the original work is given appropriate credit. Contents may not be used for commercial purposes, or adapted, remixed, transformed or built upon. (<https://creativecommons.org/licenses/by-nc-nd/4.0/>)

Thieme Medical and Scientific Publishers Pvt. Ltd., A-12, 2nd Floor, Sector 2, Noida-201301 UP, India

Table 1 Comparison of indications and contraindications for UAE by different societies

	Indications	Contraindications
ACR appropriateness criteria 2017	<ul style="list-style-type: none"> • Symptomatic fibroids in middle-aged and childbearing women with multiple fibroids do not wish to become pregnant in future but want to conserve the uterus • Single fibroid of less than 3 cm with adenomyosis or pedunculated sub-serosal fibroid in middle age women 	<ul style="list-style-type: none"> • Viable pregnancy • Active pelvic infection
CIRSIE standards of practice guidelines-2015	<ul style="list-style-type: none"> • Symptomatic fibroids • As a part of palliation/adjunct to surgery in case of uterine/ovarian malignancy • Can be considered in woman who wants to become pregnant and myomectomy is contraindicated but not as the first choice 	<ul style="list-style-type: none"> • Viable pregnancy • Active infection of the uterus • Malignancy of uterus/ovaries • Relative contraindications • Who wants to become pregnant. • Pedunculated subserosal fibroid with stalk diameter less than 50% of tumor diameter • Presence of common arterial supply for both uterus and ovaries. • Presence of intrauterine contraceptive device
SIR 2014	<ul style="list-style-type: none"> • Symptomatic fibroid 	<ul style="list-style-type: none"> • Viable pregnancy • Active infection of the uterus • Malignancy of uterus/ovaries
RCOG 2013	<ul style="list-style-type: none"> • Symptomatic fibroids • Fibroids and adenomyosis coexistence • Contraindication/ unwillingness/unsuccessful surgery 	<ul style="list-style-type: none"> • Active genital tract infection • Viable pregnancy • Asymptomatic fibroid • Relative contraindications • Pedunculated submucosal fibroid with a narrow stalk • Pedunculated subserosal fibroid. • Large fibroid causing bulk symptoms (volume reduction is not sufficient) • Women who wish to preserve fertility

guidelines of 2015 concur with RCOG guidelines and do not support UAE in subserosal fibroids with a stalk diameter less than 50% of the tumor diameter and when there is a common arterial supply to both uterus and ovaries.³ All these guidelines emphasize the beneficial role of UAE in patients with symptomatic fibroids who have heavy menstrual bleeding and pain and who wish to preserve the uterus. UAE is relatively contraindicated in patients with symptoms due to pressure on pelvic structures such as the rectum and bladder, as the volume reduction may be insufficient to eliminate pressure effects. According to the fifth radiological gynecological expert meet consensus, absolute contraindications for UAE include viable pregnancy, active pelvic infection, and malignancy of uterus/ovaries. The relative contraindications include GnRH analog treatment in previous 3 months, isolated submucosal fibroid (type 0 and 1-European society for Gynecological endoscopy classification), isolated pedunculated subserosal fibroids, and fibroids supplied by the ovarian artery.⁴

Surgery versus UAE for Fibroids

The FUME trial, an RCT comparing UAE with myomectomy, found significant and equal improvement in quality of life (QoL) in both arms at 2 years with shorter length of hospital stay (2.0 vs. 6.0 days, $p < 0.0001$) as well as fewer complica-

tions (2% in UAE and 8% in myomectomy) with the UAE.⁵ The EMMY trial, which compared 10-year outcomes of UAE and myomectomy, showed that UAE was an acceptable alternative to surgical treatment in women who wish to preserve the uterus.⁶ However, reintervention rates due to residual lesion within 2 years were high in UAE compared with myomectomy (14% vs. 4% in myomectomy). Sandberg et al found that reintervention after 5 years was 14.4% in UAE, whereas after myomectomy, it was 12.2%.⁷ Meta-analysis of surgical methods versus UAE showed UAE having fewer major complications (RR, 1.65 [95% CI, 1.32–2.06]; $p < 0.00001$) compared with surgery but higher reintervention rates after 5 years (RR of 5.01).⁸

The recent FEMME trial that evaluated the cost utility of myomectomy versus UAE showed UAE to be associated with higher costs (difference of 645 pounds) in 4 year horizon⁹ These results point out that the short-term results of UAE are good, while the long-term results of myomectomy are better, as UAE may require frequent reinterventions.

Investigations

A trans-abdominal ultrasound is recommended for preoperative workup. However, pre-procedure MRI can help in predicting the treatment response of UAE. Fibroids are usually hypointense on T2-weighted images. However,

moderate degrees of T2 hyperintensity can be seen in hypercellular fibroids, whereas marked hyperintensity suggests degeneration¹⁰. Duvnjak et al had shown that higher ratio (>2.6) of T2 hyperintensity of fibroids compared with adjacent myometrium was associated with increased volume reduction of more than 50% of the fibroid.¹¹ Fibroids with T1 hyperintensity respond poorly due to hemorrhagic necrosis or fat within.¹⁰ The fibroid location can also affect the response, with submucosal fibroids having higher volume reduction compared with intramural or subserosal fibroids due to predominant supply from the uterine radial arteries.¹² Kalina et al showed that fibroids with enhancement which is more than the myometrium on gadolinium-enhanced MRI show more significant volume reduction (61.3% vs. 47.6%) than hypo-enhancing fibroids.¹² MRI also helps predict ovarian artery supply to fibroids. Normally, the ovarian arteries are very small and the visualization of ovarian arteries on pelvic MRA indicates substantial contribution from them resulting in incomplete embolization if overlooked.¹⁰ MRI is superior to ultrasound as it allows tissue characterization of uterine fibroids and helps distinguish them from malignant tumors such as low-grade leiomyosarcoma. Diffusion-weighted MRI and T1 perfusion techniques help differentiate malignant tumors with a sensitivity of 94%, and this distinction is vital as these tumors are treated by definitive surgery.¹³

Pre-procedure Antibiotics

The possible source of infection after UAE is either from the arterial access site or ascending infection from the vagina by staphylococcus aureus, *Staphylococcus epidermis*, *Streptococcus*, and *Escherichia coli*¹⁴. SIR recommends prophylactic intravenous cephazolin (1–2 g) 1 hour before procedure with the addition of 100 mg of doxycycline, twice daily for 1 week in cases of associated hydrosalpinx.¹⁴ Though Assaf et al found no change in the rate of infectious complications between individuals with and without post-procedure antibiotics (1.8% vs. 1.3%), RCOG endorses a combination of cephalosporin and metronidazole, quinolones or amoxicillin post-procedure. However, the choice of antibiotic depends on local hospital guidelines.¹⁵

Vascular Access

The access artery can be unilateral common femoral artery (CFA), bilateral CFA, or radial artery (► Fig. 1). Compared with unilateral approach, bilateral femoral access is associated with shorter procedure times (54.9 vs. 62.9 minutes, $p=0.026$), shorter fluoroscopic times (12.8 vs. 16.6 minutes, $p=0.046$) and reduced radiation to ovaries (25% less in bilateral access group).¹⁶ Except for minor groin pain at the puncture site, there was no significant increase in access site complications in the bilateral access group.¹⁷ Radial access is also used, as it has fewer complications rate compared with femoral access.¹⁸ Left radial artery is usually preferred due to fewer manipulations needed in the arch of aorta, thus minimizing the risk of cerebral embolism and reducing the distance from the access site to the uterine artery (5–10 cm less compared with right side). Longer

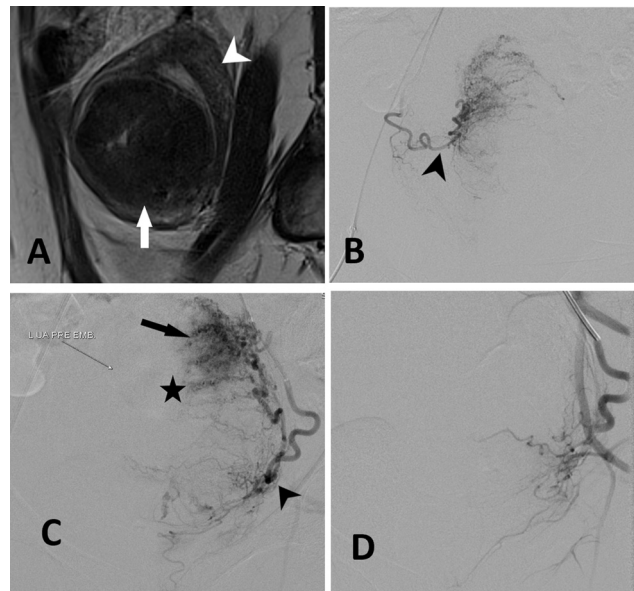


Fig. 1 A 31-year-old female patient presented with menorrhagia and dysmenorrhea due to uterine fibroid. She underwent bilateral UAE with 500 to 700 micron-sized PVA particles. Preprocedure sagittal T2 imaging (image A) shows hypointensity of mass (white arrow) as compared with adjacent myometrium (white arrow head). The presence of T2 hypointense is associated with poor response. Images B and C show dilated bilateral uterine artery (arrowheads in image B and C) with multiple corkscrew type of branches (arrow in image C) supplying fibroid (star in image C). Image D shows no filling of vessels after uterine artery embolization.

length (125 cm) catheters are preferred in the radial route.¹⁹ An RCT by Evgeny et al comparing trans-radial vs. trans-femoral access for UAE in 153 patients showed that trans-radial access was associated with shorter procedure times (32.2 ± 7.9 vs. 39.2 ± 9.7 minutes, $p < 0.001$), uterine artery catheterization time (12.3 ± 5.7 vs. 19.0 ± 6.0 minutes, $p < 0.001$) and radiation dose (0.28 ± 0.14 mSv vs. 0.5 ± 0.2 , $p < 0.001$) compared with transfemoral access.¹⁹

Embolization Materials for Fibroid Embolization

Particulate materials are preferred for fibroid embolization. Various embolic materials include nonspherical polyvinyl alcohol particles (PVA, Cook Medical, Bloomington, IL and Contour, Boston Scientific, Natick, MA), spherical tris-acrylic gelatin microspheres (Embospheres, Merit Medical inc., USA), and Polyzene F-coated hydrogel microspheres (Embozene, Varian Medical Systems, Palo Alto, CA, USA). Nonspherical PVA particles have an irregular shape and tend to occlude in the peri-fibroid vascular plexus leading to moderate perivascular inflammatory change and partial recanalization (90% at 6 months).^{20,21} Spherical PVA particles are associated with less tumor infarction compared with nonspherical PVA particles.²² Embospheres are compressible, allow easy passage through the microcatheter and cause less aggregate formation within the catheter or in this vasculature. This property enables deeper penetration into the distal vasculature, resulting in occlusion of more distal arteries.²⁰ Inflammation with embosphere is less intense compared with nonspherical PVA.²³ A meta-analysis by Das et al showed no superiority of the available embolic materials for UAE.²⁰

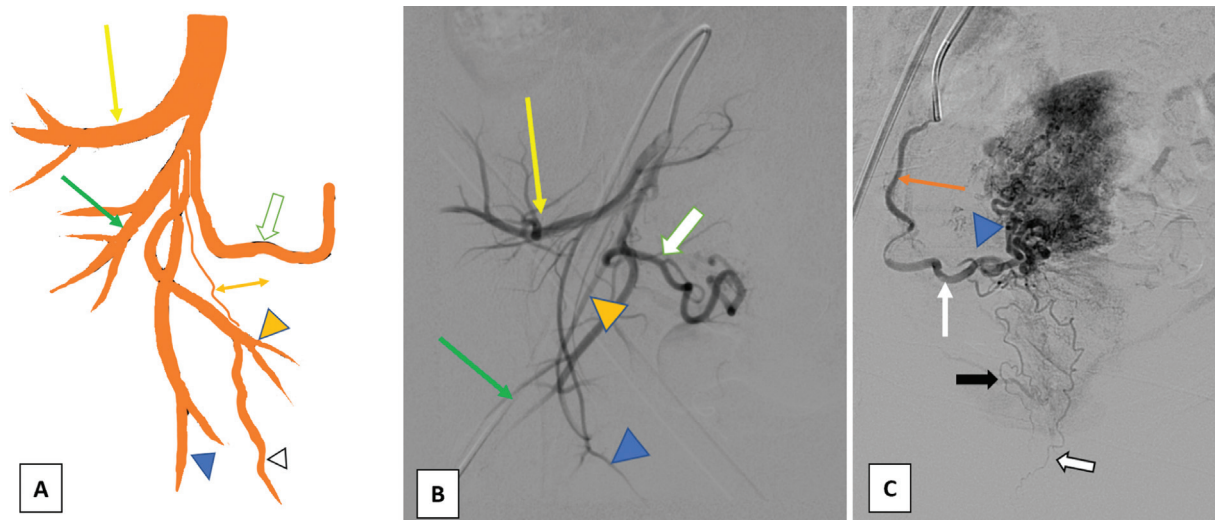


Fig. 2 Anatomy of uterine artery. (A), (B) diagrammatic and angiographic image of internal iliac artery which divides into anterior and posterior branch. From the posterior division (yellow arrow) superior gluteal artery. Iliolumbar and lateral sacral arises caliber. From the anterior division, inferior gluteal artery (green arrow) is a large branch coursing outside the pelvis. Other branches from anterior division include obturator artery which passes through obturator foramen and have a distal fork like configuration (blue arrowhead), Internal pudendal artery (yellow arrowhead) which passes through greater sciatic foramen reentering the pelvis through lesser sciatic foramen providing vascular supply to pelvic organs. Uterine artery (white arrow) arising from inferior gluteal artery has a 'U' shaped course with descending (orange arrow), transverse (white arrow) and ascending course (blue arrowhead) as shown in image (C). Cervicovaginal arteries (black arrow) arise from the transverse part of uterine artery and need to be spared while embolization to prevent vaginal ischemia.

The choice of the size of particles is also important due to the presence of utero-ovarian anastomosis that measures ~350µm in size. Small PVA particles with a size less than 350µm though have better penetration into distal vessels, causing more intense ischemic necrosis of fibroids and therapeutic response but have a higher chance of non-target embolization through utero-ovarian anastomosis (→Fig. 2).

PVA particles of 500 to 750 microns result in more proximal occlusion, but with less non-targeted embolization.²⁴ In a study comparing 350 to 500 micron and 500 to 700 micron, there was no difference in outcomes at 6 months though smaller PVA was associated with higher post-procedure pain.²⁴ A detailed description of various embolization materials used in UAE is given in →Table 2.

Table 2 Embolization agents in UAE, advantages and disadvantages and specific use

Agent	Property	Advantage	Disadvantages	Specific use
PVA particle Non-spherical (500–700)	<ul style="list-style-type: none"> Irregular particles Causes arteriolar occlusion 	<ul style="list-style-type: none"> Permanent agent Less ovarian failure due to larger size 	<ul style="list-style-type: none"> Proximal occlusion Catheter clumping 	Fibroids
PVA particle. Non-spherical (350–500)	<ul style="list-style-type: none"> Irregular particles Causes arteriolar occlusion 	<ul style="list-style-type: none"> Better distal embolization in 	<ul style="list-style-type: none"> More chances of passing through utero-ovarian anastomosis More pain 	Less preferred compared with 500–700 particles
Embospheres	<ul style="list-style-type: none"> Spherical particles Uniform size 	<ul style="list-style-type: none"> Less catheter block Better and uniform penetration Lesser pain 	<ul style="list-style-type: none"> Higher cost 	Fibroids
NBCA	<ul style="list-style-type: none"> Liquid permanent embolic 	<ul style="list-style-type: none"> Can permeate distally in case difficult emergency cannulation 	<ul style="list-style-type: none"> Uterine ischemia 	Refractory PPH, distal pseudoaneurysm
Gelfoam	<ul style="list-style-type: none"> Temporary agent 	<ul style="list-style-type: none"> Concentration can be adjusted for proximal or distal embolization No risk for permanent ischemia 	<ul style="list-style-type: none"> Temporary agent 	Post-partum hemorrhage
Vascular Coils	<ul style="list-style-type: none"> Permanent agents, proximal artery occlusion 		<ul style="list-style-type: none"> Inability to prevent flow through collaterals 	

Pain Management

Significant pain after fibroid embolization is due to ischemia of the uterus releasing lactate and adenosine that stimulate chemosensitive receptors. The pain is usually severe and cramping in nature and is most severe in the initial 2 to 3 hours, and stabilizes by 8 to 12 hours. It can also be seen as part of post embolization syndrome, which may present with fever and fatigue, commonly on the third post-procedure day. Various pain management strategies are described, including NSAIDs and opioids, patient-controlled analgesia, nerve block, and intrauterine artery injection of analgesics. A systematic review showed that the combination of NSAIDs, acetaminophen and intrauterine injection of lignocaine had better control of pain compared with NSAIDs only.²⁵ Intraarterial use of lignocaine (20–200 mg) into uterine arteries after embolization helps in the reduction of post-procedure pain for 7 hours (half-life of lignocaine 90–120 minutes) with reduced requirement of narcotic dose.²⁶ Superior hypogastric nerve block (SNBH) effectively reduces procedural pain and decreases the need for opioid analgesic. It is done by instilling 3 mL of 0.5% ropivacaine (75–100 mg) or 15–20 mL of 0.5% bupivacaine at the level below the abdominal aortic bifurcation (L5 level) and the anesthetic effect usually lasts for 8 to 12 hours.^{27,28} The injection can be done fluoroscopically after locating the aortic bifurcation by a catheter or angiogram.²⁸ Post-procedure, patient-controlled analgesia (PCA) for 24 hours followed by naproxen 500 mg BD or ibuprofen 800 mg three times a day next seven days is effective in reducing post embolization syndrome.²⁸ Opioids including fentanyl, morphine, hydromorphone, hydrocodone, and oxycodone can also be considered in cases of severe pain.

Fertility and Ovarian Reserve Function Post-uterine Fibroid Embolization

A significant concern related to uterine fibroid embolization is future fertility. The cause of infertility includes (1) reduced blood supply to uterine endometrium, (2) residual distortion of uterine cavity by any embolized involuting fibroid having a submucosal extension, thereby resulting in abnormal placentation and miscarriage, and (3) a decrease in ovarian function due to nontarget ovarian embolization through utero-ovarian anastomosis.²⁹ The risk of ovarian failure after the UAE is high in women more than 45 years of age. A

systematic review by Karsen et al showed that the pregnancy rate was lesser in patients undergoing UAE (50% vs. 78%) with a higher miscarriage rate compared with myomectomy (60% vs. 20%).³⁰ A RCT by Mara et al showed that myomectomy had a superior reproductive outcome than UAE within 2 years of treatment with higher pregnancy rate (78% vs. 50% $p < 0.05$) and lower abortion rate (23% vs. 64%, $p < 0.05$).³¹ A systematic review by Sandberg et al suggested that if a patient is a surgical candidate and concerned about future pregnancy, myomectomy should be the first choice.^{7,32} UAE may be considered in fibroids, that are surgically challenging to treat in sub-fertility patients.³² The diminution of ovarian reserve leading to infertility after UAE is controversial. Razavi et al classified the utero-ovarian anastomosis (UOA) into three types (– **Table 3**) and described a high change ovarian failure after UAE in type Ib, and type III UOA and in patients with age more than 45 years.³³ Sheikh et al described the use of coils and 700 to 900 µm PVA particles to occlude the UAO in type 1b and type III to reduce ovarian failure.³⁴ However, a systematic review by Tare et al that compared case–control and three cohort studies, showed that ovarian reserve as measured by the level of anti-mullerian hormone (AMH) and follicular stimulating hormone (FSH) was not affected by UAE. However, majority of the population included in their study were less than 40 years. In the EMMY study, which analyzed a homogenous population, the level of FSH used as a measure of the ovarian reserve was seen to increase after embolization more in women over 45 years of age.³⁵ In summary, the ovaries of younger age exhibit greater recovery after ischemic damage suggesting that the infertility is more likely to be due to uterine and endometrial causes than ovarian in younger age, compared with those of age > 45 years.

UAE in Adenomyosis

Adenomyosis (– **Fig. 3**) is commonly seen in the fourth to fifth decade presenting as dysmenorrhea, menorrhagia, or abdominal pain.³⁶ The management is by medical therapy with hysterectomy reserved for refractory cases. UAE is emerging as a potential alternative. Liang et al showed a success rate of 88% in controlling bleeding with a pain score reduction from 7.45 to 1.32 ($p < 0.001$).³⁷ The short term (6-month) success rate described by Kim et al amounts to 82 to 83%, while Popovic et al showed a long-term (5-year) success

Table 3 Utero-ovarian anastomosis and significance

Type	Morphology	Significance
Ia	Ovarian artery connects to uterine mural artery and then supplies fibroid. Flow in tubal arteries is toward the uterus on selective uterine angiogram	Chances of failure of UAE high
Ib	Same as type Ia. Reflux of contrast into an ovarian artery is seen during pre-embolization angiogram followed by washout of contrast toward the uterus	Ovarian failure risk
II	The ovarian artery directly supplies fibroid apart from uterine artery	Chances of residual fibroid
III	Ovary is supplied by uterine artery with flow in the tuboovarian segment is toward the ovary	Ovarian failure risk

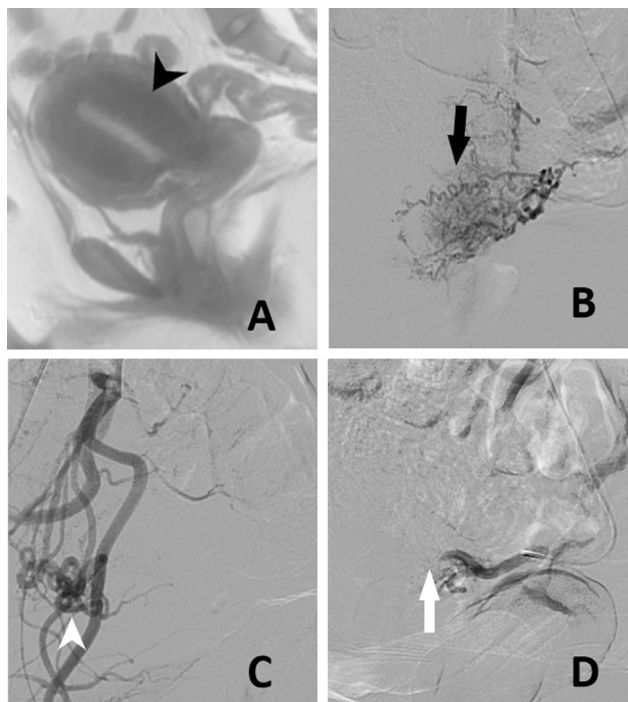


Fig. 3 A 37-year-old female patient is a known case of adenomyosis. She underwent bilateral UAE with 300 to 50 micron-sized PVA particles. Image A-Sagittal MRI shows increased junctional zone thickness of more than 12 mm (arrowhead). Angiogram shows dilated tortuous bilateral uterine arteries with multiple feeders supplying the uterus (arrow in image B and arrowhead in image C). Post embolization angiogram shows occlusion of the uterine artery.

rate of 64.5%.^{38,39} The ongoing QUESTA trial that compares UAE with hysterectomy in premenopausal women may provide insights regarding the future role of the UAE in adenomyosis.⁴⁰ MRI can help in predicting the response: lesions with low T2 (higher smooth muscle quantity with less extracellular matrix) intensity compared with rectus muscle has been shown to have better therapeutic response.^{38,41} A ratio of rectus to adenomyosis T2 signal intensity of more than 0.475 was associated with complete necrosis in such lesions.⁴¹ Lesions with higher vascularity also show better response than lesions without significant

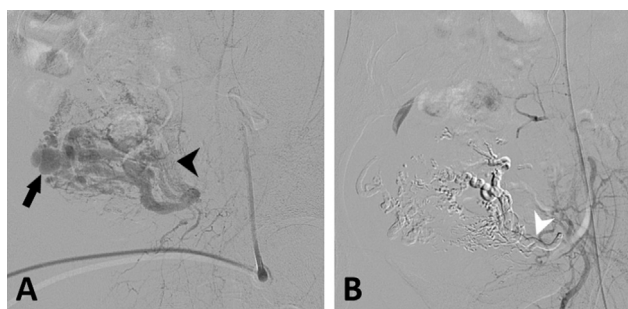

Fig. 4 Uterine AVM in a 26-year-old female patient post gestational trophoblastic disease underwent bilateral UAE with glue embolization. Image A shows an abnormal dilated uterine artery with small communications (arrowhead), there is an additional pseudoaneurysm (arrow). Image B-post glue embolization shows occlusion of the fistula, pseudoaneurysm, and uterine artery.

vascularity.⁴² Post-procedure MR can predict the midterm (2 years) clinical recurrence, with necrosis of less than 34.3% of volume associated with seven-fold risk of recurrence.⁴² Kim et al using 150 to 250 micron-sized nonspherical PVA particles, followed by 250 to 355 micron and 355 to 500 micron-sized particles achieved a success rate of 90%. However, as discussed, smaller particles (< 350 μm) should not be considered in young patients who want to become pregnant.³⁸

UAE in Arteriovenous Uterine Malformations

Uterine AVMs (► Fig. 4) are of two types: congenital or acquired. Congenital AVM occurs due to a defect in embryological differentiation leading to abnormal arteriovenous communications.⁴³ Even though these are present since childhood, they are commonly noticed during the reproductive period and are frequently associated with multiple feeders from other pelvic arteries in addition to uterine artery.⁴⁴ Acquired AVMs involve fistulous communication between uterine artery branches and venous plexuses in the myometrium.⁴³ These are more common and seen in conditions with prior uterine interventions, uterine surgery, and in gestational trophoblastic disease and infection.⁴⁴ Ultrasound is the initial imaging test and shows multiple cystic structures in uterine myometrium on grayscale, and high turbulent flow on color flow imaging.⁴⁴ Doppler parameters can help in guiding treatment. Timmerman et al and Lee et al in their studies showed AVMs with high PSV (≥ 83 cm/s) required embolization whereas lesions with a PSV of less than 39 cm/s required only conservative medical management.^{45,46} For women who wish to conserve uterus, expectant management and UAE are the main methods of treatment.⁴⁷ Hysterectomy is considered in individuals who do not wish to have future pregnancies or in whom UAE has failed.⁴⁴ A systematic review by Yoon et al reported that the primary success rate of UAE in acquired AVM was 61%, whereas, in cases of repeated embolization, it was 91%.⁴³ Recent studies by Delplanque and Zhu et al showed that the success rate of UAE was 71% to 87% in acquired AVMs.^{47,48} Sophie et al, in 22 patients, showed reasonable fertility rates post UAE (6/7, 85.7%) compared with expectant management (2/5, 33.3%), with no miscarriages and ectopic pregnancy.⁴⁷ Pei et al showed similar results in 62 acquired AVMs treated with UAE where 10 patients became pregnant and resulted in the delivery of a healthy live baby.⁴⁸ Young age and lack of uterine distortion by fibroid are the probable reasons for successful pregnancy.⁴⁷ The choice of embolizing material is variable and in cases of ovarian artery supply, temporary occlusion by gelfoam is sufficient as the main goal is to prevent bleeding.⁴³

UAE in Antenatal Bleeding

There is increasing use of UAE in controlling antepartum bleed in ectopic pregnancy and invasive placenta. Scar ectopics (► Fig. 5) require early termination in the first trimester.⁴⁹ Various treatment options include systemic methotrexate, hysteroscopic resection, dilatation and curettage. Timor et al showed bleeding rate (due to the slow action of the drug, which results in growth of embryo and placental

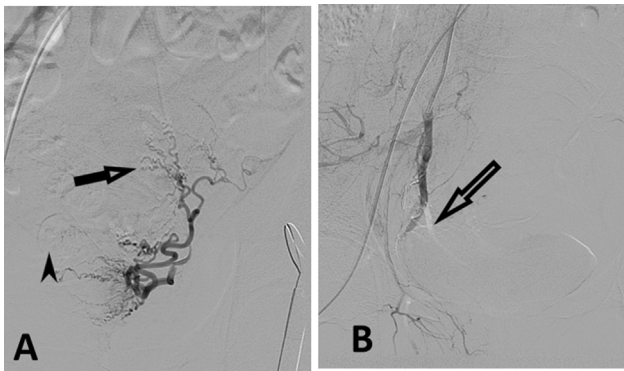


Fig. 5 Case of scar ectopic in a 34-year-old female patient awaiting curettage-prophylactic bilateral uterine artery embolization is done using gelfoam. In image A, abnormal feeders to the uterus (arrow) and fetal head can also be noted (arrowhead). Image B-Post gel foam embolization of uterine artery shows stoppage of flow.

tissue) with methotrexate was 62%, thus requiring further treatment.⁵⁰ Hysteroscopic removal or dilation and curettage (D & C) in cervical scar ectopic results in profuse life-threatening bleeding due to lack of normal myometrium in cervix. UAE has shown to reduce preoperative bleeding in cases of surgical evacuation.⁵⁰ Systematic review by Pektaş et al showed 82% of cases treated initially with UAE alone require further treatment by curettage or methotrexate⁴⁹. Though the exact time interval between the UAE and evacuation of products is not clearly defined, it is better to do the evacuation as early as possible after UAE, because delaying evacuation results in recruitment and development of uterine collaterals.

Abnormal invasive placenta (►Fig. 6) includes placenta accreta, increta, and percreta. Planned delivery by cesarean section is performed at 34 to 36 weeks of gestation. Endo-

vascular interventions help in preserving the uterus and decreasing intraoperative bleeding.⁵¹ Endovascular interventions include prophylactic balloon occlusion (PBO) and uterine artery embolization. In PBO compliant balloons are placed under fluoroscopy guidance and are inflated after the delivery of the baby and clamping of the umbilical cord. Balloon occlusion can be performed either proximally at the infrarenal abdominal aorta, bilateral common iliac arteries, or distally at the internal iliac or uterine arteries. Proximal occlusion in the aorta is quick to perform with less radiation exposure to the fetus and it also reduces bleeding from collaterals compared with distal occlusion. Uterine artery embolization can be considered after balloon occlusion if there is persistent bleeding. In a systematic review, Shahin et al compared proximal versus distal balloon occlusion and reported that proximal balloon occlusion of the abdominal aorta resulted in better control of blood loss (mean difference-1.391 mL, $p < 0.001$), lower hysterectomy rates, and less fetal radiation dose.⁵² Wu et al showed average fetal radiation dose in aortic balloon occlusion was 5.1 ± 3 mGy in 230 patients, whereas the radiation dose with internal iliac balloon occlusion was 21 to 61 mGy.⁵³ The average radiation dose absorbed by the skin for 10 to 35 minutes of fluoroscopy was ~450 to 1600 mGy, and the dose absorbed by ovaries was 7 to 378 mGy, which is far less compared with the recommended dose limits.⁵⁴

UAE in Postpartum Bleed

Postpartum hemorrhage (PPH) is an important cause of morbidity and mortality worldwide with more than 1 lakh death per annum.⁵⁵ It is defined as blood loss of more than 1000 mL of blood associated with features of volume loss such as hypotension and tachycardia. It can be primary, which occurs within the first 24 hours due to uterine atony,

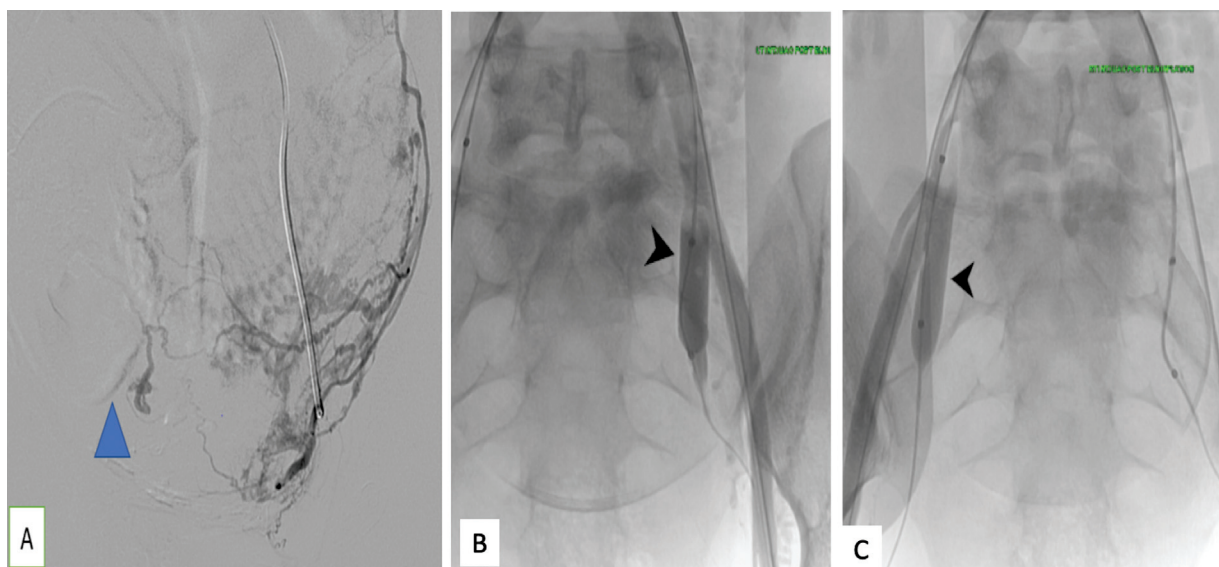


Fig. 6 A 33-year-female patient with placenta percreta invading bladder at 35 weeks of gestation underwent bilateral internal iliac arteries balloon placement before delivery. Image (A) showing the fetus (blue arrowhead) with vascular placental blush. Bilateral femoral artery access was done and 10 mm x 2 cm balloon was placed in the both internal iliac artery (arrowheads in image B and image C). The patient was then taken for cesarean section and the balloons were inflated after the delivery of fetus, followed by hysterectomy. The perioperative blood loss was 350 mL, which was significantly low compared with a surgery for placenta percreta.

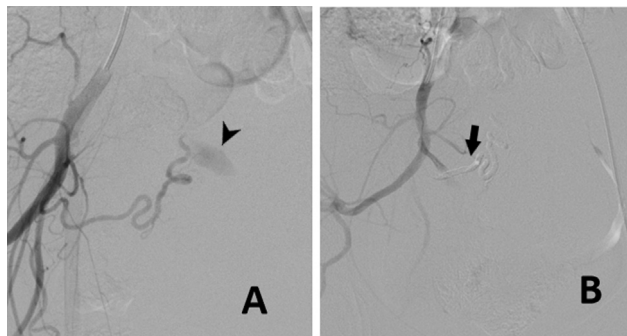


Fig. 7 A 35-year-female patient presented with bleeding per vagina after a recent D&C. Image A shows a large pseudoaneurysm seen arising from right uterine artery (arrowhead). After selectively cannulating the right uterine artery, it was embolized with 20% glue. Image B-Post embolization shows occlusion of uterine artery as well as pseudoaneurysm.

trauma to the genital tract, retained placental tissues or coagulopathic disorders or secondary (occurring 24 hours to 12 weeks) due to retained placental tissue, infection, coagulopathy, uterine artery pseudoaneurysm (→ Fig. 7) or AVM⁵⁶. The latest FIGO guidelines recommend UAE for refractory PPH uncontrolled by medical and nonsurgical methods, provided there is availability of skilled personnel.⁵⁷ UAE can be considered when conservative management fails. It is preferable to perform angiography after 30 minutes of administration of uterotonics, as these drugs cause vasospasm, obscuring the total extent of the problem. During angiography, contrast extravasation is seen in 21 to 52% of cases, and the most common source of bleeding is from distal branches of the uterine artery, or vaginal arteries. Absorbable gel foam as embolizing material is preferred as it stops bleeding and allows recanalization within 2 to 4 weeks, thereby preventing ischemia.⁵⁵ Liquid embolics such as N-butyl cyanoacrylate are used only when the total permanent occlusion of the vessel is required in recurrent or refractory PPH or in large pseudoaneurysms.⁵⁸ In cases where the bleeding site is not identified, empirical embolization of bilateral uterine arteries or anterior division of the internal iliac artery can be attempted.⁵⁸ Systematic review by Zhang et al showed that UAE was successful in controlling bleeding in 90.5% of cases with 91 to 100% of these cases resuming their normal menstruation during follow-up.⁵⁴ Study by Lee et al in 251 patients with primary PPH showed successful rate of UAE in 88% of patients with disseminated intravascular coagulation and massive transfusion as independent predictors for clinical failure.⁵⁹

Conclusion

In conclusion, uterine artery embolization is a safe, effective, and minimally invasive technique in treating various uterine pathologies such as fibroids, adenomyosis, and uterine vascular malformations. It can help reduce bleeding and preserve the uterus in abnormal invasive placenta and scar ectopic pregnancy. Proper patient selection and consideration of appropriate technical aspects can achieve better success rate.

Funding

None.

Conflict of Interest

None declared.

References

- Marsh EE, Al-Hendy A, Kappus D, Galitsky A, Stewart EA, Kerulous M. Burden, prevalence, and treatment of uterine fibroids: a survey of U.S. women. *J Womens Health (Larchmt)* 2018;27(11):1359–1367
- Dariushnia SR, Nikolic B, Stokes LS, Spies JBSociety of Interventional Radiology Standards of Practice Committee. Quality improvement guidelines for uterine artery embolization for symptomatic leiomyomata. *J Vasc Interv Radiol* 2014;25(11):1737–1747
- Rand T, Patel R, Magerle W, Uberoi R. CIRSE standards of practice on gynaecological and obstetric haemorrhage. *CVIR Endovasc* 2020;3(01):85https://www.ncbi.nlm.nih.gov/pmc/articles/PMC7695782/ cited 2021Jun1 [Internet]
- Kröncke T, David Mparticipants of the Consensus Meeting. Uterine artery embolization (UAE) for fibroid treatment - results of the 5th radiological gynecological expert meeting. *Geburtshilfe Frauenheilkd* 2015;75(05):439–441
- Manyonda IT, Bratby M, Horst JS, Banu N, Gorti M, Belli AM. Uterine artery embolization versus myomectomy: impact on quality of life—results of the FUME (Fibroids of the Uterus: Myomectomy versus Embolization) Trial. *Cardiovasc Intervent Radiol* 2012;35(03):530–536
- van der Kooij SM, Hehenkamp WJK, Volkers NA, Birnie E, Ankum WM, Reekers JA. Uterine artery embolization vs hysterectomy in the treatment of symptomatic uterine fibroids: 5-year outcome from the randomized EMMY trial. *Am J Obstet Gynecol* 2010;203(02):105.e1–105.e13
- Sandberg EM, Tummers FHMP, Cohen SL, van den Haak L, Dekkers OM, Jansen FW. Reintervention risk and quality of life outcomes after uterine-sparing interventions for fibroids: a systematic review and meta-analysis. *Fertil Steril* 2018;109(04):698–707.e1
- Fonseca MCM, Castro R, Machado M, Conte T, Girao MJBC. Uterine artery embolization and surgical methods for the treatment of symptomatic uterine leiomyomas: a systemic review and meta-analysis followed by indirect treatment comparison. *Clin Ther* 2017;39(07):1438–1455.e2
- Rana D, Wu O, Cheed V, et al; FEMME Trial Collaborative Group. Uterine artery embolisation or myomectomy for women with uterine fibroids wishing to avoid hysterectomy: a cost-utility analysis of the FEMME trial. *BJOG* 2021;128(11):1793–1802
- Kirby JM, Burrows D, Haider E, Maizlin Z, Midia M. Utility of MRI before and after uterine fibroid embolization: why to do it and what to look for. *Cardiovasc Intervent Radiol* 2011;34(04):705–716
- Duvnjak S, Ravn P, Green A, Andersen PE. Magnetic resonance signal intensity ratio measurement before uterine artery embolization: ability to predict fibroid size reduction. *Cardiovasc Intervent Radiol* 2017;40(12):1839–1844
- Kalina I, Tóth A, Valcseva É, et al. Prognostic value of pre-embolisation MRI features of uterine fibroids in uterine artery embolisation. *Clin Radiol* 2018;73(12):1060.e1–1060.e7
- Thomassin-Naggara I, Dechoux S, Bonneau C, et al. How to differentiate benign from malignant myometrial tumours using MR imaging. *Eur Radiol* 2013;23(08):2306–2314
- Chehab MA, Thakor AS, Tulin-Silver S, et al. Adult and pediatric antibiotic prophylaxis during vascular and IR procedures: a Society of Interventional Radiology Practice Parameter Update Endorsed by the Cardiovascular and Interventional Radiological Society of Europe and the Canadian Association for Interventional Radiology. *J Vasc Interv Radiol* 2018;29(11):1483–1501.e2

- 15 Graif A, Leung DA, McKenna G, Patel KD, Holmes LE, Grilli CJ. Evaluation of the effect of routine antibiotic administration after uterine artery embolization on infection rates. *J Vasc Interv Radiol* 2020;31(08):1263–1269
- 16 Bratby MJ, Ramachandran N, Sheppard N, Kyriou J, Munneke GM, Belli AM. Prospective study of elective bilateral versus unilateral femoral arterial puncture for uterine artery embolization. *Cardiovasc Intervent Radiol* 2007;30(06):1139–1143
- 17 Costantino M, Lee J, McCullough M, Nsouli-Maktabi H, Spies JB. Bilateral versus unilateral femoral access for uterine artery embolization: results of a randomized comparative trial. *J Vasc Interv Radiol* 2010;21(06):829–835, quiz 835
- 18 Resnick NJ, Kim E, Patel RS, Lookstein RA, Nowakowski FS, Fischman AM. Uterine artery embolization using a transradial approach: initial experience and technique. *J Vasc Interv Radiol* 2014;25(03):443–447
- 19 Khayrutdinov E, Vorontsov I, Arablinskiy A, Shcherbakov D, Gromov D. A randomized comparison of transradial and transfemoral access in uterine artery embolization. *Diagn Interv Radiol* 2021;27(01):59–64
- 20 Das R, Champaneria R, Daniels JP, Belli AM. Comparison of embolic agents used in uterine artery embolisation: a systematic review and meta-analysis. *Cardiovasc Intervent Radiol* 2014;37(05):1179–1190
- 21 Das R, Gonsalves M, Vlahos I, Manyonda I, Belli AM. MRI assessment of uterine artery patency and fibroid infarction rates 6 months after uterine artery embolization with nonspherical polyvinyl alcohol. *Cardiovasc Intervent Radiol* 2013;36(05):1280–1287
- 22 Rasuli P, Hammond I, Al-Mutairi B, et al. Spherical versus conventional polyvinyl alcohol particles for uterine artery embolization. *J Vasc Interv Radiol* 2008;19(01):42–46
- 23 Laurent A, Wassef M, Namur J, Martal J, Labarre D, Pelage JP. Recanalization and particle exclusion after embolization of uterine arteries in sheep: a long-term study. *Fertil Steril* 2009;91(03):884–892
- 24 Bilhim T, Pisco JM, Duarte M, Oliveira AG. Polyvinyl alcohol particle size for uterine artery embolization: a prospective randomized study of initial use of 350–500 μm particles versus initial use of 500–700 μm particles. *J Vasc Interv Radiol* 2011;22(01):21–27
- 25 Saibudeen A, Makris GC, Elzein A, et al. Pain management protocols during uterine fibroid embolisation: a systematic review of the evidence. *Cardiovasc Intervent Radiol* 2019;42(12):1663–1677
- 26 Shiwani TH, Shiwani H. Intra-arterial anaesthetics for pain control in arterial embolisation procedures: a systematic review and meta-analysis. *CVIR Endovasc* 2021;4(01):6
- 27 Pereira K, Morel-Ovalle LM, Wiemken TL, et al. Intraprocedural superior hypogastric nerve block allows same-day discharge following uterine artery embolization. *J Vasc Interv Radiol* 2020;31(03):388–392
- 28 Spencer EB, Stratil P, Mizones H. Clinical and periprocedural pain management for uterine artery embolization. *Semin Intervent Radiol* 2013;30(04):354–363
- 29 Czuczwar P, Stępnik A, Wrona W, Woźniak S, Milart P, Paszkowski T. The influence of uterine artery embolisation on ovarian reserve, fertility, and pregnancy outcomes - a review of literature. *Przegl Menopauz* 2016;15(04):205–209
- 30 Karlson K, Hrobjartsson A, Korsholm M, Mogensen O, Humaidan P, Ravn P. Fertility after uterine artery embolization of fibroids: a systematic review. *Arch Gynecol Obstet* 2018;297(01):13–25
- 31 Mara M, Maskova J, Fucikova Z, Kuzel D, Belsan T, Sosna O. Midterm clinical and first reproductive results of a randomized controlled trial comparing uterine fibroid embolization and myomectomy. *Cardiovasc Intervent Radiol* 2008;31(01):73–85
- 32 Spies JB. Current role of uterine artery embolization in the management of uterine fibroids. *Clin Obstet Gynecol* 2016;59(01):93–102
- 33 Razavi MK, Wolanske KA, Hwang GL, Sze DY, Kee ST, Dake MD. Angiographic classification of ovarian artery-to-uterine artery anastomoses: initial observations in uterine fibroid embolization. *Radiology* 2002;224(03):707–712
- 34 Sheikh GT, Najafi A, Cunier M, Hess TH, Binkert CA. Angiographic detection of utero-ovarian anastomosis and influence on ovarian function after uterine artery embolization. *Cardiovasc Intervent Radiol* 2020;43(02):231–237
- 35 de Bruijn AM, Ankum WM, Reekers JA, et al. Uterine artery embolization vs hysterectomy in the treatment of symptomatic uterine fibroids: 10-year outcomes from the randomized EMMY trial. *Am J Obstet Gynecol* 2016;215(06):745.e1–745.e12
- 36 Kulshrestha V, Yadav R, Malla S, Gamanagatti S, Bhatla N. Successful pregnancy outcome in refractory adenomyosis treated with two sessions of uterine artery embolization: a case report and brief review. *J Gynecol Obstet Hum Reprod* 2021;50(07):102132
- 37 Liang E, Brown B, Rachinsky M. A clinical audit on the efficacy and safety of uterine artery embolisation for symptomatic adenomyosis: results in 117 women. *Aust N Z J Obstet Gynaecol* 2018;58(04):454–459
- 38 Kim MD, Kim YM, Kim HC, et al. Uterine artery embolization for symptomatic adenomyosis: a new technical development of the 1–2–3 protocol and predictive factors of MR imaging affecting outcomes. *J Vasc Interv Radiol* 2011;22(04):497–502
- 39 Popovic M, Puchner S, Berzaczy D, Lammer J, Bucek RA. Uterine artery embolization for the treatment of adenomyosis: a review. *J Vasc Interv Radiol* 2011;22(07):901–909, quiz 909
- 40 de Bruijn AM, Lohle PN, Huirne JA, de Vries J, Twisk M, Hehenkamp WJQUESTA-Trial Group. Uterine artery embolization versus hysterectomy in the treatment of symptomatic adenomyosis: protocol for the randomized QUESTA trial. *JMIR Res Protoc* 2018;7(03):e47
- 41 Jung DC, Kim MD, Oh YT, Won JY, Lee DY. Prediction of early response to uterine arterial embolisation of adenomyosis: value of T2 signal intensity ratio of adenomyosis. *Eur Radiol* 2012;22(09):2044–2049
- 42 Bae SH, Kim MD, Kim GM, et al. Uterine artery embolization for adenomyosis: percentage of necrosis predicts midterm clinical recurrence. *J Vasc Interv Radiol* 2015;26(09):1290–6.e2
- 43 Yoon DJ, Jones M, Taani JA, Buhimschi C, Dowell JD. A systematic review of acquired uterine arteriovenous malformations: pathophysiology, diagnosis, and transcatheter treatment. *AJP Rep* 2016;6(01):e6–e14
- 44 Szpera-Goździewicz A, Gruca-Stryjak K, Bręborowicz GH, Ropacka-Lesiak M. Uterine arteriovenous malformation - diagnosis and management. *Ginekol Pol* 2018;89(05):276–279
- 45 Timmerman D, Wauters J, Van Calenbergh S, et al. Color Doppler imaging is a valuable tool for the diagnosis and management of uterine vascular malformations. *Ultrasound Obstet Gynecol* 2003;21(06):570–577
- 46 Lee TY, Kim SH, Lee HJ, et al. Ultrasonographic indications for conservative treatment in pregnancy-related uterine arteriovenous malformations. *Acta Radiol* 2014;55(09):1145–1152
- 47 Delplanque S, Le Lous M, Proisy M, et al. Fertility, pregnancy, and clinical outcomes after uterine arteriovenous malformation management. *J Minim Invasive Gynecol* 2019;26(01):153–161
- 48 Zhu YP, Sun ZJ, Lang JH, Pan J. Clinical characteristic and management of acquired uterine arteriovenous malformation. *Chin Med J (Engl)* 2018;131(20):2489–2491
- 49 Kanat-Pektas M, Bodur S, Dundar O, Bakır VL. Systematic review: what is the best first-line approach for cesarean section ectopic pregnancy? *Taiwan J Obstet Gynecol* 2016;55(02):263–269
- 50 Timor-Tritsch IE, Monteagudo A. Unforeseen consequences of the increasing rate of cesarean deliveries: early placenta accreta and

- cesarean scar pregnancy. A review. *Am J Obstet Gynecol* 2012;207(01):14–29
- 51 Huang KL, Tsai CC, Fu HC, et al. Prophylactic transcatheter arterial embolization helps intraoperative hemorrhagic control for REMOVING Invasive Placenta. *J Clin Med* 2018;7(11):460
- 52 Shahin Y, Pang CL. Endovascular interventional modalities for haemorrhage control in abnormal placental implantation deliveries: a systematic review and meta-analysis. *Eur Radiol* 2018;28(07):2713–2726
- 53 Wu Q, Liu Z, Zhao X, et al. Outcome of pregnancies after balloon occlusion of the infrarenal abdominal aorta during caesarean in 230 patients with placenta praevia accreta. *Cardiovasc Intervent Radiol* 2016;39(11):1573–1579
- 54 Zhang XQ, Chen XT, Zhang YT, Mai CX. The emergent pelvic artery embolization in the management of postpartum hemorrhage: a systematic review and meta-analysis. *Obstet Gynecol Surv* 2021;76(04):234–244
- 55 Brown M, Hong M Jr, Lindquist J. Uterine artery embolization for primary postpartum hemorrhage. *Tech Vasc Interv Radiol* 2021;24(01):100727
- 56 Committee on Practice Bulletins–Obstetrics. Practice bulletin no. 183: postpartum hemorrhage. *Obstet Gynecol* 2017;130(04):e168–e186
- 57 Escobar MF, Nassar AH, Theron G, et al; FIGO Safe Motherhood and Newborn Health Committee. FIGO recommendations on the management of postpartum hemorrhage 2022. *Int J Gynaecol Obstet* 2022;157(Suppl 1):3–50
- 58 Loya MF, Garcia-Reyes K, Gichoya J, Newsome J. Uterine artery embolization for secondary postpartum hemorrhage. *Tech Vasc Interv Radiol* 2021;24(01):100728 [https://www.techvir.com/article/S1089-2516\(21\)00006-8/fulltext](https://www.techvir.com/article/S1089-2516(21)00006-8/fulltext) cited 2022Aug15 [Internet]
- 59 Lee HY, Shin JH, Kim J, et al. Primary postpartum hemorrhage: outcome of pelvic arterial embolization in 251 patients at a single institution. *Radiology* 2012;264(03):903–909