



# Aortic Root Surgery in Adults: An Unsolved Problem

Carlotta Brega, MD<sup>1</sup>  Alberto Albertini, MD<sup>1</sup>

<sup>1</sup>Department of Cardiovascular Surgery, GVM Care and Research, Cotignola, RA, Italy

Address for correspondence Carlotta Brega, MD, Maria Cecilia Hospital, GVM Care and Research, Via Corriera 1, 48033 Cotignola, RA, Italy (e-mail: carlottabrega@icloud.com).

Aorta (Stamford) 2023;11:29–35.

## Abstract

Nowadays, despite the rapid advancements in interventional cardiology, open surgery still deals with aortic root diseases, to assure the best “ad hoc” treatment. In case of middle-aged adult patients, the optimal operation still represents a matter of debate. A review of the last 10-year literature was conducted, focusing on patients below 65 to 70 years of age. Because of the small sample and the heterogeneity of the papers, no meta-analysis was possible. Bentall–de Bono procedure, valve sparing, and Ross operations are the surgical options currently available. The main issues in the Bentall – de Bono operation are lifelong anticoagulation therapy and cavitation in case of mechanical prosthesis implantation and structural valve degeneration in case of biological Bentall. As transcatheter procedures are currently performed as valve in valve, biological prosthesis may be preferable, if the diameter may prevent postoperative high gradients. Conservative techniques, such as remodeling and reimplantation, preferred in the young, guarantee physiologic aortic root dynamics and impose surgical analysis of the aortic root structures to get a durable result. The Ross operation, which shows excellent performance, involves autologous pulmonary valve implantation and is performed only in experienced and high-volume centers. Due to its technical difficulty, it requires a steep learning curve and presents some limitations in specific aortic valve diseases. All three have advantages and downsides, and no ideal solution has still been reported.

## Keywords

- ▶ aortic root
- ▶ aortic root surgery
- ▶ Bentall’s procedure
- ▶ valve-sparing operations
- ▶ Ross’ operation

## Introduction

Cardiac surgery has broadened its horizons, to assure the best “ad hoc” treatment. On the one hand, aortic root surgery remains in the surgical domain, but on the other hand, transcatheter techniques have dramatically altered the approach to aortic valve diseases. In case of young-adult patients (below the age of 65–70 years), the optimal choice of aortic root procedures still represents a matter of debate. Established treatment options include aortic valve replacement (AVR) using a mechanical or biological prosthesis. In young patients, however, both valve prostheses are associated with well-

known drawbacks: limited durability for bioprostheses and anticoagulation-related morbidity for mechanical valves. A reconstructive technique using autologous pericardium (Ozaki’s procedure) showed excellent follow-up results but is still not worldwide performed.<sup>1,2</sup> Aortic root surgery has been evolving, from the traditional replacement by a mechanical conduit to the use of biological grafts. Valve sparing operations are routinely performed in some centers, but they are not applicable in case of aortic valve stenosis and calcification. The Ross operation assures an excellent hemodynamic profile and avoids lifelong anticoagulation therapy but is still performed almost exclusively in selected, high-volume centers.

received  
November 15, 2021  
accepted after revision  
August 8, 2022

DOI <https://doi.org/10.1055/s-0042-1757949>.  
ISSN 2325-4637.

© 2023. The Author(s).

This is an open access article published by Thieme under the terms of the Creative Commons Attribution-NonDerivative-NonCommercial-License, permitting copying and reproduction so long as the original work is given appropriate credit. Contents may not be used for commercial purposes, or adapted, remixed, transformed or built upon. (<https://creativecommons.org/licenses/by-nc-nd/4.0/>)

Thieme Medical Publishers, Inc., 333 Seventh Avenue, 18th Floor, New York, NY 10001, USA

**Table 1** Selection of the papers

	Author	Year	Number of patients	Patient
1	Pantaleo et al <sup>9</sup>	2017	1,112	BB vs. MB
2	Di Marco et al <sup>10</sup>	2016	1,045	BB vs. MB
3	Desai et al <sup>8</sup>	2011	986	BB
4	Lansac et al <sup>22</sup>	2017	177	Remodeling + annuloplasty
5	Badiu et al <sup>26</sup>	2014	370	BB vs. MB vs. reimplantation
6	Lee et al <sup>24</sup>	2018	216	BB vs. reimplantation
7	Ouzounian et al <sup>25</sup>	2016	616	BB vs. MB vs. reimplantation/remodeling
8	Gaudino et al <sup>27</sup>	2015	890	BB vs. MB vs. reimplantation/remodeling
9	Dinato et al <sup>28</sup>	2020	448	BB vs. MB vs. reimplantation/remodeling
10	Patel et al <sup>31</sup>	2021	1,241	Reimplantation/remodeling
11	Romeo et al <sup>43</sup>	2021	1,431	Ross
12	Pergola et al <sup>44</sup>	2020	600	Ross
13	Aboud et al <sup>42</sup>	2021	2,444	Ross

Abbreviations: BB, biological Bentall; MB, mechanical Bentall.

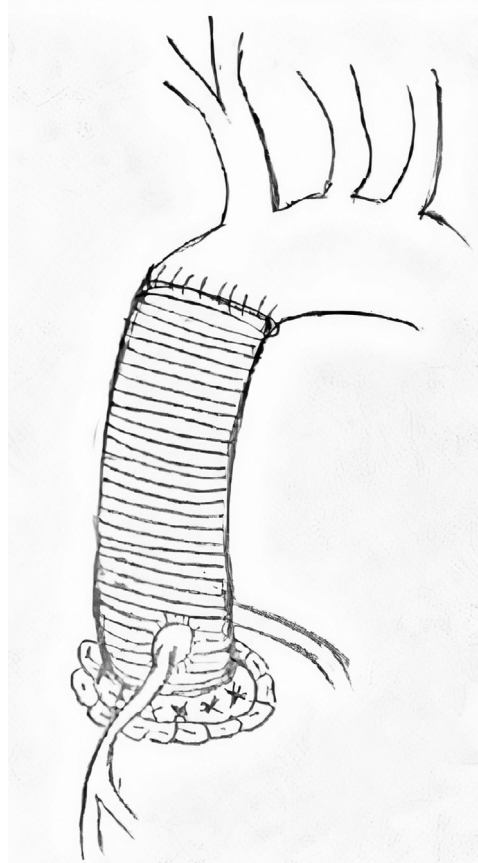
## Background

A literature review was conducted regarding outcomes of aortic root surgery in patients below 70 years of age. In March and April 2021, PubMed, Web of Science, Scopus, and Google Scholar were searched using key terms “aortic root surgery,” “biological Bentall,” “mechanical Bentall,” “Ross operation,” “valve sparing,” “remodeling,” reimplantation,” and “young patients.” The research was limited to the past 10 years. The full texts of the articles were then screened for study type, age of population, type of intervention, and outcome (early and late mortality rates, reoperations, and complications). Pediatric series were excluded and connective tissue diseases were not considered, as well. To avoid potential biases, Type A aortic dissections were not included in our analysis. We aimed to focus on the young adults (age < 70 years), but most of the papers reported mean age of the patients and no age range, so the sample size was small and the papers were extremely heterogeneous. Hence, formal meta-analysis was not possible and we conducted a traditional literature review on the largest series (► **Table 1**). Our review focused on patients < 70 years old, and we aimed to evaluate the suitability of the Bentall-de Bono procedure, valve-sparing operations, and Ross operation (► **Table 1**).

### Bentall-de Bono Operation: Mechanical or Biological Bentall, That Is the Question

The Bentall-de Bono operation represents the gold standard for aortic aneurysms associated with aortic valve disease, when valve-sparing operations cannot be performed (► **Fig. 1**). The Bentall-de Bono procedure is usually performed using a mechanical valved conduit, to guarantee the most radical treatment of the aortic disease and to avoid eventual redo procedures. The implantation of a biological prosthesis in young patients has always been argued, because of the limited durability of biological valves.

Overall, whether to implant a biological or a mechanical valve prosthesis to replace the diseased native aortic valve depends, among other factors, on the patient's age at the time of surgery. The European Society of Cardiology (ESC)



**Fig. 1** Bentall-de Bono operation: valved straight graft replacing the aortic root. Both biological and mechanical prosthesis can be used, even if our drawings does not show the valve.

guidelines<sup>3</sup> indicate acceptability of both prostheses in patients aged 60 to 65 years. Both options have disadvantages: for mechanical valves, this is lifetime anticoagulation, with increased risk of spontaneous bleeding especially in the elderly<sup>4</sup> and cavitation issues with microembolic cerebral lesions<sup>5</sup>; also, the downside of a biological prosthesis is the risk of structural valve degeneration (SVD).<sup>6</sup> Technology has developed new designs for better hemodynamic performance in biological prosthesis, newer anticalcification treatments to reduce early SVD, and new frames designed to facilitate the implantation of valve-in-valve transcatheter aortic valve implantation and increase the overall durability. However, new generation mechanical valves require lower anticoagulation levels.

Accounting for all these factors makes the choice of prosthesis difficult.<sup>7</sup> Young patients with an active lifestyle may not be ideal candidates for long-term anticoagulant therapy, because of the potential thromboembolic and hemorrhagic complications. Desai et al<sup>8</sup> compared mid- and long-term results of porcine bioprosthesis and mechanical conduits, including young adult patients. No statistically significant differences were found in terms of follow-up mortality, aortic root reoperation, thromboembolic events, endocarditis, or major bleeding events. The overall bleeding rate was higher in the mechanical group, but these were minor bleeding episodes. A propensity score analysis of 1,112 patients by Pantaleo et al<sup>9</sup> reported 6.5% as early mortality: 7.2% for the mechanical Bentall and 5.8% for the biological, with no significant statistical difference and no differences in terms of major postoperative complications being found between the two groups. The early mortality rate was similar to the 5% reported by Di Marco,<sup>10</sup> but was higher than the data reported in other large series<sup>11,12</sup>: the rate of associated procedures was 39 and 36%, respectively, in mechanical and biological Bentall and it may impact the early mortality.

The mid- and long-term results for patients <65 years old who underwent biological AVR are of major interest. Ongoing development of new composite grafts has allowed the implantation of biological conduits with excellent results at 10-year follow-up. Galiñanes et al<sup>13</sup> report excellent long-term clinical results after the implantation of the No-React Bioconduit, even in patients <65 years old. This study includes combined procedures, as well, so data are difficult to sort out. The overall 10-year survival following Biobentall using the No-React Bioconduit was 51%, and 88% of the patients were free from valve-conduit-related complications leading to death. Postoperative echocardiography did not show stenosis, calcification, or structural change of the conduit itself. Certainly, SVD represents a relevant issue especially in young patients, creating a need for eventual redo-Bentall, which will be challenging and complex.

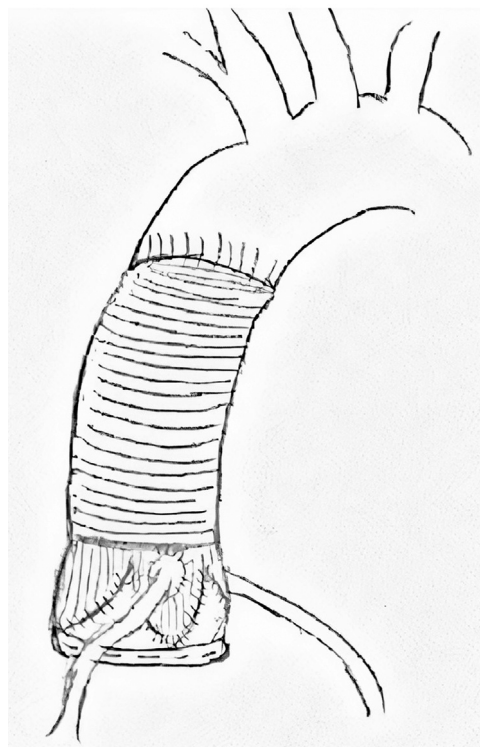
The reapproach to the aortic root requires its mobilization, with the risk of distortion of the structures and high operative risk. In fact, early mortality reported in the literature for re-Bentall is approximately 8.6 to 7.1%.<sup>14,15</sup> We have previously described the “double sewing ring technique,”<sup>16</sup> which also allows upsizing of the prosthesis, which may represent an advantage, especially in a small aortic annulus.

In case of a redo procedure, the double sewing ring technique simplifies surgery. The valve, fixed with a running suture, can be easily removed, leaving in place the vascular graft; furthermore, the rim of the graft which was everted during the initial surgery is available for suturing a new prosthesis.

As well, nowadays, nonsurgical options such as valve-in-valve transcatheter procedures are appealing.<sup>17-19</sup> To guarantee acceptable results in terms of patient-prosthesis mismatch after valve in valve, bioprosthesis diameter should be assessed.<sup>20,21</sup> To make simpler the choice of prosthesis, a preoperative accurate analysis of the aortic ring diameter, through CT-scan imaging or echo may be helpful: if the measurement of the annulus is at least 23 mm, a biological valve may be suitable, in the perspective of an eventual transcatheter procedure; if it is a smaller one, the mechanical Bentall is probably the most definitive solution.

### Valve Sparing Operations: Pathophysiology and Durability

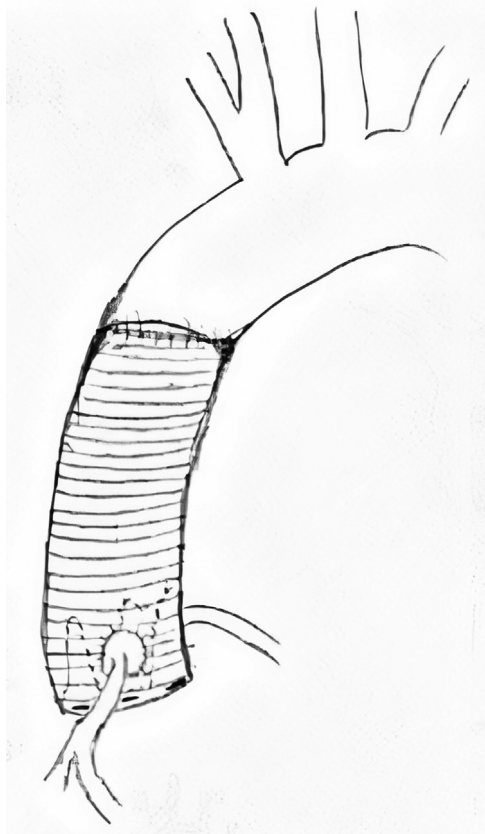
A current goal of the surgical management of aortic root pathology and aortic valve insufficiency is aortic valve preservation, with or without repair. The two most widely used techniques are the remodeling (Yacoub's model) and the reimplantation (David's model) techniques. In the Yacoub procedure, neo-sinuses of Valsalva are designed and created with synthetic tube graft, thereby producing a nearly physiologic reconstruction of the aortic root (→Fig. 2). This technique allows independence of every interleaflet triangle, creating the most physiologic solution to aortic root replacement. This procedure should be accompanied by external



**Fig. 2** Remodeling operation: three “petals” of a bulged vascular graft sutured to the native aortic valve and ring annuloplasty.

annuloplasty, to guarantee the most freedom from late aortic insufficiency.<sup>22</sup>

The reimplantation procedure is the most widely used technique; this involves reimplantation of the aortic valve within a straight or bulged graft, whereby the sinotubular junction (STJ) and the annulus are reduced and the inter-leaflet triangles are included, thus impairing root expansibility and possibly valve dynamics<sup>23</sup> (–Fig. 3). The rate of aortic valve-sparing operations has been increasing since 2000, as reported by Lee et al<sup>24</sup>: a more and more standardized approach has been developed and prevailed over the initial uncertainty about the durability of this surgery. Ouzounian et al<sup>25</sup> compared from 1999 to 2010 patients under 70 years of age who underwent David, mechanical, and biological Bentall and found similar hospital mortality and postoperative complications. At follow-up, all-cause mortality, major aortic valve-related events, and cardiac-related mortality were lower in aortic valve-sparing patients. Long-term rates of endocarditis and thromboembolic events were comparable among the three groups. The reoperation rate was higher in biological Bentall, and hemorrhagic events were more common in mechanical Bentall. Badiu et al<sup>26</sup> found similar results, but the three groups compared differed in age range, as the biological Bentall were older than the others and 27.5% of patients had emergency operation. One hundred and seventy eight patients of this series had valve-sparing operation, either Yacoub or David, and eight of them were early reoperated because of severe aortic valve insuffi-



**Fig. 3** Reimplantation operation: native aortic valve sutured inside a straight vascular graft.

ciency; despite the higher rate of reintervention, valve-sparing operations allow the longest survival curve and freedom from major bleeding events.

Gaudino et al<sup>27</sup> showed excellent results, with 0% in early mortality, in postoperative stroke and myocardial infarction, in comparison with the Bentall technique. Dinato et al<sup>28</sup> showed better cardiac output when the aortic valve was spared, as well.

In valve-sparing surgery, the point is that the continuous research and update, to understand the mechanisms and the pathophysiology of aortic root disease allowed the extension of this surgery to a younger and potentially healthier category of patients. On the one hand, a more prophylactic surgery was performed; on the other hand, “expanded indications”<sup>29</sup> were described. In some marginal operative indications, such as age >65 years, aortitis, Type A aortic dissection, and redo valve-sparing surgery showed satisfactory results; cusp prolapse and diameter of the aortic ring larger than 28 mm were considered predictors of more than mild aortic regurgitation at follow-up.

Feasibility of valve-sparing procedures for bicuspid valves in patients under 65 years was confirmed by Kari et al<sup>30</sup> and by Patel et al<sup>31</sup> as well: early mortality of 2.5%, 10-year survival of 94%, and freedom from redo at 10 years of 96% were observed. Bicuspid repair involves cusp repair and, in most of the cases, remodeling<sup>32</sup> or reimplantation<sup>33</sup> that allow freedom from eventual reoperation at 10 year from 83 to 89%.

The opportunity to spare a patient’s own aortic valve is interesting and surely underestimated, as an excess of mortality is documented in several studies, both involving biological or mechanical prosthesis<sup>34–36</sup>: AVR at 40 years old reduces life expectancy by 20 years. In case of aortic valve insufficiency and aortic root aneurysm, remodeling with annuloplasty and/or reimplantation is feasible and safe.

One key factor needs to be discussed: the challenging aspect in case of valve-sparing operations is the evaluation of the native aortic valve, whose mobility and dynamics need to be efficiently restored. This is not always possible, in case of diffuse fibrosis or calcification, as the shaving of the free edge and of the cusps themselves is not sufficient to restore mobility. Except in such cases, conservative aortic valve surgery is nowadays preferred and often realized. Another point is the durability of aortic valve repair: according to the most recent guidelines,<sup>3</sup> aortic valve repair is legitimated in experienced centers and when durable results are expected. It should be reserved for young patients, but homogeneous data reporting the clinical results are scarce. Multiple techniques are used, often in association with root replacement, so mixed groups of patients with short follow-up are included.<sup>37</sup>

### The Ross Operation: Two-Valve Disease?

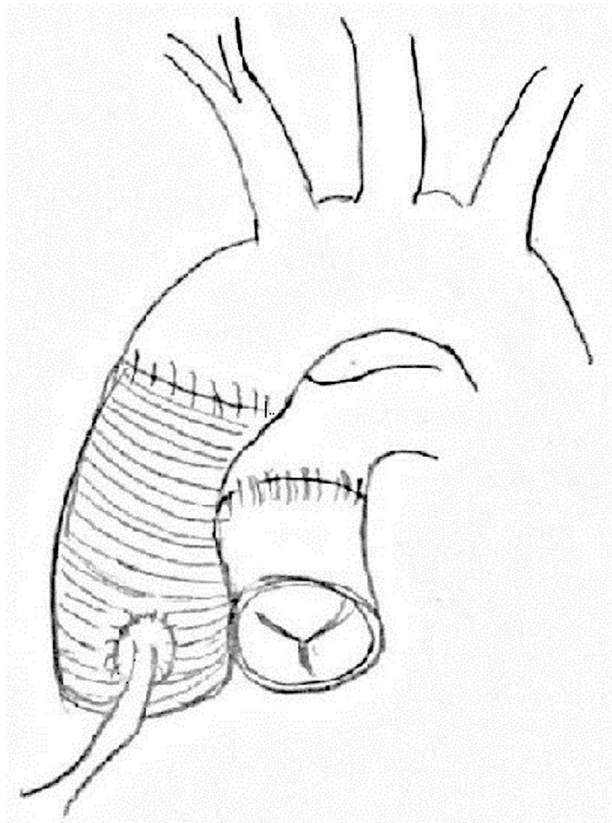
In case of aortic valve degeneration in a young adult, AVR is mandatory, but surgery remains challenging. Despite the development of longer-lasting bioprostheses, which fit active lifestyles as well, no optimal solutions are currently available. The durability of bioprostheses is getting longer



but remains uncertain, as long-term follow-up data are still not available for the newer valves. In the presence of mechanical prostheses, anticoagulant therapy is needed lifelong, with subsequent thromboembolic risk. In addition to the already mentioned disadvantages, prostheses lack physiologic biology and hemodynamics.<sup>38</sup> These features may be not so relevant in case of limited life expectancy, but to guarantee the best solution for young patients, the Ross operation needs to be considered. ESC Guidelines consider Ross operation for patients <50 years old to whom anticoagulation would not be possible, in specialized centers.<sup>3</sup>

The Ross concept was developed in 1962, when Donald Ross proposed the most physiologic replacement of degenerated aortic valves with a pulmonary autograft. The first operations were performed in 1967, with the concomitant implantation of a pulmonary homograft (►Fig. 4). The technique gained popularity and enthusiasm, especially in the United States, where the first specialized centers developed. The studies supporting the Ross technique consider the aortic valve as belonging to a vital structure, the aortic root, which plays a bridge role between the left ventricle, and the vascular system. Physiologic interactions and cross talk are advisable and are indeed realized by autografts. So minimization of the transaortic gradients is accomplished, especially in young patients.

Moreover, different modifications of the Ross technique have been introduced, to improve operative results and long-



**Fig. 4** The Ross operation: pulmonary autograft in aortic position and pulmonary homograft.

term performance. Three different main pulmonary autograft implantation techniques have been described: the original subcoronary implantation, the entire root replacement, and the inclusion technique.<sup>39–41</sup> Of these, the root replacement technique has received the greatest acceptance because of its easier implantation, wider indication field (including root aneurysms), and better early and midterm results.<sup>31</sup>

However, longer follow-up showed a progressive dilation of the pulmonary autograft, so the inclusion technique was developed. The full autograft root is included as a cylinder inside the native aortic root, which seems efficient in preventing autograft dilatation.

However, controversies about the safety of Ross operations have persisted. The Ross procedure is thought to be technically complex. It converts a single-valve disease into a double-valve disease. Another limitation to this technique has to do with the availability of pulmonary allografts, as in many countries homograft banks are not present or the use of cadaver tissue is forbidden for ethical or religious reasons. So, the benefits of replacing the aortic valve with an autograft, despite mimicking the normal physiology, have not been widely praised. A recent paper by Aboud et al<sup>42</sup> conducted on 2,444 patients who underwent the Ross procedure showed patient survival equivalent to an age and sex-matched population at 15 years after surgery. This aspect was confirmed even by Romeo et al.<sup>43</sup> Early mortality ranges between 0.4 and 2.3% in experienced centers, and it is comparable with many routine surgeries. After propensity score matching, freedom from both death and reintervention was in favor of the Ross procedure, in comparison with mechanical AVR. Freedom from redo for the homograft is reported at 97.2 and 92% for the autograft: transcatheter techniques may anyway be helpful and reduce the pulmonary redo rate. Moreover, freedom from reintervention after mechanical prosthesis implantation at 10 years is not negligible, approximately 82%, because of valve thrombosis, leakage, pannus, or endocarditis.<sup>43</sup> The rates of bleeding, endocarditis, and thromboembolic events were very low (maximum 0.15% per patient year). The rate of reoperation was approximately 1% and reoperation was more common if aortic regurgitation was severe accompanied by annular/STJ dilation.<sup>42,43</sup>

As suitable to young patients, Ross is performed even in case of bicuspid aortic valve diseases: as reported by Pergola et al,<sup>44</sup> the congenital etiology did not impact mortality and rate of reoperations. As the bicuspid aortic valve is associated with aortic disease, whether to use an autograft is still arguable and a matter of debate.

Some points need discussion: the Ross procedure requires an adequate learning curve. It needs to be performed in a specialized high-volume center, to achieve safety and durability. In the Ross operation, the surgeon faces potential failure of two instead of one valve, with a chance of redo surgery of 15% at 15-year follow-up. Redo surgery after a Ross procedure, because of its complexity and challenging features, needs to be realized in specialized high-volume centers, with a Ross program, as well.

## Conclusion

Despite the heterogeneity of the papers focusing on adults, in patients below the age of 65 to 70 years, Bentall and valve-sparing surgery are viable options. BioBentall does not impose lifelong anticoagulation therapy and should provide optimal aortic orifice area. Different bioconduits for biological Bentall have been tested, with partial focus on the young and middle-aged adults. SVD and eventual re-Bentall remain the most argued issue. If the bioprosthesis diameter is adequate, a valve-in-valve procedure can be performed. When possible, restoring-reconstructive surgery is preferable to replacement techniques: accurate examination of the root structures is mandatory to guarantee the durability of surgery. Accurate study and examination of the native aortic valve geometry and performance allow even complex aortic valve repair, in concomitance with aortic root replacement. The main advantage of the Ross operation is the opportunity to gain the best hemodynamic condition, which is the ultimate ambitious aim of AVR. Complexity makes the Ross procedure a niche operation, performable only after accurate specialized training to assure procedural safety and long-term survival.

### Funding

None.

### Conflict of Interest

A.A. is consultant for Livanova, for NeoChord Inc., and Proctor for JOMDD Inc.

### Acknowledgments

None.

## References

- Ozaki S, Kawase I, Yamashita H, Uchida S, Takatoh M, Kiyohara N. Midterm outcomes after aortic valve neocuspidization with glutaraldehyde-treated autologous pericardium. *J Thorac Cardiovasc Surg* 2018;155(06):2379–2387
- Seese L, Yoon P, Morell VO, Chu D. Aortic root replacement with autologous pericardium valved conduit. *Ann Thorac Surg* 2022; 113(03):e227–e229
- Otto CM, Nishimura RA, Bonow RO, et al; Writing Committee Members. 2020 ACC/AHA Guideline for the Management of Patients With Valvular Heart Disease: a report of the American College of Cardiology/American Heart Association Joint Committee on Clinical Practice Guidelines. *J Am Coll Cardiol* 2021;77(04): e25–e197
- Loewen P, Dahri K. Risk of bleeding with oral anticoagulants: an updated systematic review and performance analysis of clinical prediction rules. *Ann Hematol* 2011;90(10):1191–1200
- Vriz O, Arshi F, Ahmed M, et al. Cavitation phenomenon in mechanical prosthetic valves: not only microbubbles. *Echocardiography* 2020;37(06):876–882
- Rahimtoola SH. Choice of prosthetic heart valve in adults an update. *J Am Coll Cardiol* 2010;55(22):2413–2426
- Puskas JD, Gerdisch M, Nichols D, et al; PROACT Investigators. Anticoagulation and antiplatelet strategies after On-X mechanical aortic valve replacement. *J Am Coll Cardiol* 2018;71(24): 2717–2726
- Desai ND, McCarthy F, Moser W, et al. Durability of porcine bioprosthesis in younger patients with aortic root pathology: a propensity-matched comparison with composite mechanical roots. *Ann Thorac Surg* 2011;92(06):2054–2060, discussion 2060–2061
- Pantaleo A, Murana G, Di Marco L, et al. Biological versus mechanical Bentall procedure for aortic root replacement: a propensity score analysis of a consecutive series of 1112 patients. *Eur J Cardiothorac Surg* 2017;52(01):143–149
- Di Marco L, Pacini D, Pantaleo A, et al. Composite valve graft implantation for the treatment of aortic valve and root disease: results in 1045 patients. *J Thorac Cardiovasc Surg* 2016;152(04): 1041–1048.e1
- Castrovinci S, Tian DH, Murana G, et al. Aortic root replacement with biological valved conduits. *Ann Thorac Surg* 2015;100(01): 337–353
- De Paulis R, Scaffa R, Salica A, Weltert L, Chirichilli I. Biological solutions to aortic root replacement: valve-sparing versus bio-prosthetic conduit. *J Vis Surg* 2018;4:94
- Galiñanes M, Meduoye A, Ferreira I, Sosnowski A. Totally biological composite aortic stentless valved conduit for aortic root replacement: 10-year experience. *J Cardiothorac Surg* 2011;6:86
- Dougenis D, Daily BB, Kouchoukos NT. Reoperations on the aortic root and ascending aorta. *Ann Thorac Surg* 1997;64(04):986–992
- Fukunaga N, Koyama T, Konishi Y, Murashita T, Okada Y. Clinical outcome of redo operation on aortic root. *Gen Thorac Cardiovasc Surg* 2014;62pages215–220
- Albertini A, Dell'Amore A, Zussa C, Lamarra M. Modified Bentall operation: the double sewing ring technique. *Eur J Cardiothorac Surg* 2007;32(05):804–806
- Rodés-Cabau J, Dumont E, Doyle D, Lemieux J. Transcatheter valve-in-valve implantation for the treatment of stentless aortic valve dysfunction. *J Thorac Cardiovasc Surg* 2010;140(01): 246–248
- Ferrari E, Marcucci C, Sulzer C, von Segesser LK. Which available transapical transcatheter valve fits into degenerated aortic bioprosthesis? *Interact Cardiovasc Thorac Surg* 2010;11(01):83–85
- Ye J, Webb JG, Cheung A, et al. Transapical transcatheter aortic valve-in-valve implantation: clinical and hemodynamic outcomes beyond 2 years. *Thorac Cardiovasc Surg* 2013;145(06): 1554–1562
- Durko AP, Head SJ, Pibarot P, et al. Characteristics of surgical prosthetic heart valves and problems around labelling: a document from the European Association for Cardio-Thoracic Surgery (EACTS)-The Society of Thoracic Surgeons (STS)-American Association for Thoracic Surgery (AATS) Valve Labelling Task Force. *Eur J Cardiothorac Surg* 2019;55(06):1025–1036
- Lopez S, Meyer P, Teboul J, et al. Transcatheter valve-in-valve implantation in a degenerated very small Mitroflow prosthesis. *Interact Cardiovasc Thorac Surg* 2018;27(06):850–855
- Lansac E, Di Cetta I, Sleilat G, et al. Remodeling root repair with an external aortic ring annuloplasty. *J Thorac Cardiovasc Surg* 2017;153(05):1033–1042
- David TE, Feindel CM. An aortic valve-sparing operation for patients with aortic incompetence and aneurysm of the ascending aorta. *J Thorac Cardiovasc Surg* 1992;103(04):617–621, discussion 622
- Lee H, Cho YH, Sung K, et al. Clinical outcomes of root reimplantation and Bentall procedure: propensity score matching analysis. *Ann Thorac Surg* 2018;106(02):539–547
- Ouzounian M, Rao V, Manlhiot C, et al. Valve-sparing root replacement compared with composite valve graft procedures in patients with aortic root dilation. *J Am Coll Cardiol* 2016;68(17): 1838–1847
- Badiu CC, Deutsch MA, Sideris C, et al. Aortic root replacement: comparison of clinical outcome between different surgical techniques. *Eur J Cardiothorac Surg* 2014;46(04):685–692, discussion 692
- Gaudino M, Lau C, Munjal M, Avgerinos D, Girardi LN. Contemporary outcomes of surgery for aortic root aneurysms: a propensity-

- matched comparison of valve-sparing and composite valve graft replacement. *J Thorac Cardiovasc Surg* 2015;150(05):1120–9.e1
- 28 Dinato FJ, Dias RR, Duncan JA, et al. Brazilian single-center experience with aortic root replacement in 448 patients: what is the best technique? *Rev Bras Cir Cardiovasc* 2020;35(06):869–877
- 29 Miyahara S, Matsueda T, Izawa N, et al. Mid-term results of valve-sparing aortic root replacement in patients with expanded indications. *Ann Thorac Surg* 2015;100(03):845–851, discussion 852
- 30 Kari FA, Liang DH, Kvitting JP, et al. Tirone David valve-sparing aortic root replacement and cusp repair for bicuspid aortic valve disease. *J Thorac Cardiovasc Surg* 2013;145(3, suppl):S35–40.e1, 2
- 31 Patel PM, Wei JW, McPherson L, Binongo J, Leshnower BG, Chen EP. Bicuspid aortic valve sparing root replacement. *J Card Surg* 2021;36(01):118–123
- 32 Kari FA, Doll KN, Hemmer W, et al. Survival and freedom from aortic valve-related reoperation after valve-sparing aortic root replacement in 1015 patients. *Interact Cardiovasc Thorac Surg* 2016;22(04):431–438
- 33 Mastrobuoni S, de Kerchove L, Navarra E, et al. Long-term experience with valve-sparing reimplantation technique for the treatment of aortic aneurysm and aortic regurgitation. *J Thorac Cardiovasc Surg* 2019;158(01):14–23
- 34 Kvidal P, Bergström R, Hörte LG, Ståhle E. Observed and relative survival after aortic valve replacement. *J Am Coll Cardiol* 2000;35(03):747–756
- 35 Bouhout I, Stevens LM, Mazine A, et al. Long-term outcomes after elective isolated mechanical aortic valve replacement in young adults. *J Thorac Cardiovasc Surg* 2014;148(04):1341–1346.e1
- 36 Mihaljevic T, Nowicki ER, Rajeswaran J, et al. Survival after valve replacement for aortic stenosis: implications for decision making. *J Thorac Cardiovasc Surg* 2008;135(06):1270–1278, discussion 1278–1279
- 37 Fok M, Shaw M, Sancho E, Abello D, Bashir M. Aortic valve repair: a systematic review and meta-analysis of published literature. *Aorta (Stamford)* 2014;2(01):10–21
- 38 El-Hamamsy I, Warnes C, Nishimura RA. The Ross procedure in adults: the ideal aortic valve substitute? *JACC* 2021;77(11):1423–1425
- 39 Ross DN. Replacement of aortic and mitral valves with a pulmonary autograft. *Lancet* 1967;2(7523):956–958
- 40 Kouchoukos NT, Dávila-Román VG, Spray TL, Murphy SF, Perrillo JB. Replacement of the aortic root with a pulmonary autograft in children and young adults with aortic-valve disease. *N Engl J Med* 1994;330(01):1–6
- 41 Elkins RC, Lane MM, McCue C. Pulmonary autograft reoperation: incidence and management. *Ann Thorac Surg* 1996;62(02):450–455
- 42 Aboud A, Charitos EI, Fujita B, et al. Long-term outcomes of patients undergoing the Ross procedure. *J Am Coll Cardiol* 2021;77(11):1412–1422
- 43 Romeo JLR, Papageorgiou G, da Costa FFD, et al. Long-term clinical and echocardiographic outcomes in young and middle-aged adults undergoing the Ross procedure. *JAMA Cardiol* 2021;6(05):539–548
- 44 Pergola V, Di Salvo G, Fadel B, et al. The long term results of the Ross procedure: the importance of candidate selection. *Int J Cardiol* 2020;320:35–41