Article published online: 2022-10-28

Type III Sturge Weber Syndrome, An Uncommon Cause of Status Epilepticus

Juan Pablo Coronado-Lopez[1] Juan Felipe Coronado[2] Jose Fernando Gomez-Urrego[3] Richard Londono-Chavez[4]

[1] Faculty of Medicine, Pediatrics Department, Pontificia Universidad Javeriana, Cali, Colombia
[2] Faculty of Medicine, Genetics Group, Universidad de La Sabana, Chia, Colombia
[3] Pediatrics Department, Universidad de Caldas 2, Pontificia Universidad Javeriana, Cali, Colombia
[4] Pediatrics Neurosurgery Department, Universidad Militar Nueva Granada, Bogota, Colombia

Address for correspondence Juan Felipe Coronado, MD, Faculty of Medicine, Universidad de la Sabana, Campus del Puente del Común, Km. 7, Autopista Norte de Bogota, Chia, Cundinamarca, Bogota 53753, Colombia (e-mail: juanfcs13@gmail.com).

J Pediatr Epilepsy 2023;12:103–108.

Abstract

Introduction Sturge Weber syndrome (SWS) is a rare neurocutaneous condition due to the mutation of the GNAQ gen. This condition is characterized by skin, eye, and brain compromise, but the type III only affects the brain, making it a challenging condition to diagnose.

Clinical Case A Hispanic 4 year-old female, with a history of complex febrile seizure in her medical records, presented to the emergency room in status epilepticus after 24 hours of upper respiratory symptoms. After a neurological and radiologic evaluation, SWS III was diagnosed, which led to a pharmacological adjustment for achieving control of the seizures, with a great clinical evolution.

Discussion The pathophysiology, diagnostics, and proper management of this disease are discussed.

Conclusion SWS is a rare neurocutaneous disease, usually diagnosed in patients with pathognomonic features, however it is important to know that type III SWS exists and represents a challenging diagnosis, leading to a time-race for starting proper management, considering that the outcome includes a better life-quality, a higher cognitive result, and reduced morbimortality.

Keywords
- Sturge-Weber syndrome
- febrile seizure
- neurosurgery

Introduction

Sturge-Weber syndrome (SWS) is a neurovascular condition with a very low incidence, affecting one of 20,000 to 23,000 live-births.[1] This condition derives from a post-zygotic somatic mutation of GNAQ gene,[1,2] located in chromosome 9,[3] responsible for cellular proliferation and inhibition of apoptosis. This gene is mostly expressed in the brain and lung; when is altered, it leads to an uncontrolled tissue proliferation, particularly of the endothelial cells.[4] Clinical features of this syndrome include postcapillary and venous malformation which might affect different tissues including brain, skin, and eye,[3] producing a classic cutaneous lesion described as *Port wine birthmark*, usually located in the territory of either the frontonasal prominence with or without compromising the optic vesicle area,[5] seizures, usually focal seizures with or without secondary generalization, moderate to severe headache, and glaucoma.[1,2] Based on the features, Roach classified SWS into three types[6]: type I, which is the most common (classic) presentation including

received
June 9, 2022
accepted
September 6, 2022
article published online
October 28, 2022

© 2022. Thieme. All rights reserved.
Georg Thieme Verlag KG,
Rüdigerstraße 14,
70469 Stuttgart, Germany

DOI https://doi.org/10.1055/s-0042-1757917.
ISSN 2146-457X.

This document was downloaded for personal use only. Unauthorized distribution is strictly prohibited.

both cutaneous and leptomeningeal capillary malformation (LCM), with or without glaucoma, type II includes the presence of a port-wine stain with glaucoma but without leptomeningeal involvement, and type III, the least common presentation, characterized by LCM without cutaneous or ocular affection. Currently, this type of SWS is considered an incidental diagnosis, and mostly done during adulthood. The purpose of this article is to present a case report of a type III SWS and review the clinical features of this rare entity.

Clinical Case

A Hispanic 4-years and 1-month old female was brought by her mother to the emergency room because she presented a generalized tonic-clonic seizure, staring spell along with urinary incontinence, apparently lasting 30 minutes. In the emergency room, the patient received midazolam (0.1 mg/kg) followed by a phenytoin load (15 mg/kg) which successfully stopped the seizures. By the history, in the preceding 24 hours, the patient had had upper respiratory symptoms including clear rhinorrhea, cough, and intermittent fever, with quantified temperature of 38.4°C (101.2°F), managed with acetaminophen.

Based on the information provided by the mother and the clinical findings, a parainfectious status epilepticus was considered, and the patient was admitted to the pediatric unit. At admission, she was confused, on supplementary oxygen, with normal vital signs. Cardiopulmonary auscultation showed no pathological findings. Neurological examination showed a somnolent but arousable patient, oriented in person, and responsive to her mother's voice. Pupils were 4 mm and briskly reactive to light. Muscle bulk and tone were normal. Strength was full bilaterally. Reflexes were 2+ and symmetric at the biceps, triceps, knees, and ankles. Plantar responses were flexor. The patient did not have any relevant perinatal or birth condition in her medical records. After she was 6-months old, she had two febrile seizures and after studies, including an electroencephalogram (EEG) whose result was normal, she was diagnosed with a complex febrile seizure managed with valproic acid 15 mg/kg/d.

In her blood work-up (►**Table 1**), lymphocytosis was observed, a respiratory viral panel was negative and her valproic acid values were in subtherapeutic range. A head computed tomography (CT) (►**Fig. 1**, top line) showed atrophic changes in the right hemisphere and subcortical irregular calcifications of the same side, suggesting a structural etiology of the seizures, compatible with SWS.

She was evaluated by pediatric neurology, who noted the absence of any port wine stain on physical examination. The valproic acid dose was increased to 30 mg/kg/d and levetiracetam added with a target dose of 20 mg/kg, and acetyl salicylic acid with dose of 5 mg/kg/d. Additionally, a contrast-enhanced head magnetic resonance (►**Fig. 1**, bottom line) was obtained. An EEG was performed whose did not show any abnormalities, and antibody testing for cytomegalovirus and toxoplasma was negative (►**Table 2**). Pediatric ophthalmology considered she had a low risk for developing glaucoma, considering the SWS type (III).

Finally, the patient was evaluated by the pediatric neurosurgery department, who felt that based on the extent and location of the LCM, she was not a good surgical candidate. She was discharged home after 2 weeks with occupational therapy and pediatric neurology follow-up. At follow-up appointments the second and fourth week after being discharged, she had no additional convulsive episodes.

Discussion

This case shows a patient with a convulsive syndrome hard to characterize, with normal neurodevelopment, an EEG without alterations, with a final diagnosis of a SWS III after blood work-up and imaging studies.

The prevalence of this SWS type is very low in the pediatric population, in fact, based on the available reports in the main databases, it cannot be established. Literature search was performed in Medline, SCOPUS, and PubMed searching for SWS type III in population under 18 years old, finding only five publications, reported in ►**Table 2**.

Initially, the Port wine birthmark was considered the pathognomonic sign of the SWS, given the fact that in different case series up to 8% of the patients with that cutaneous lesion presented a SWS.[12] However, in the type III SWS, the absence of typical clinical features or complications like cosmetic[3] or visual,[13] creates a diagnostic challenge, explaining the uncertain prevalence of this subtype. Furthermore, the clinical presentation of this SWS subtype is in the context of seizures or headache, most of them presenting as complex febrile seizures or migraine headaches, that only after imaging and electroencephalographic studies the diagnosis of this condition could be made.[11]

Seizures are common in SWS, considering that LCM acts like a structural epileptogenic focus, however, the detection in the EEG may only be made when it affects a large brain area.[14] EEG findings correlate with the LCM size, because at the beginning there is a slight vascular dilation and later dysgenesis of the superficial venous system with no changes in the EEG, but later there will be shunts with the deep system, leading to venous dilation, flow stasis, and chronic ischemia, presented in the imaging as linear cortical calcificacitions, known as tram-track sign, with features in the EEG including from focal asymmetry to epileptiform pattern.[15]

Imaging for characterization of SWS often starts with tomography, useful in this case because it helps to show calcifications. However, based on the ionizing radiation and limitation in the evaluation of brain parenchyma, the preferred method to evaluate this condition is contrast-enhanced magnetic resonance imaging,[4,16,17] finding in the early phases of the SWS a transitory abnormal white matter signal, moreover, leptomeningeal enhancement is found because it is the most affected region, and limited diffusion can be found if there have been ischemic episodes. Late disease shows an increased signal in the T2 sequence related with gliosis and low enhancing of the pia mater and secondary brain parenchyma atrophy.[17]

 © 2022. Thieme. All rights reserved.

This document was downloaded for personal use only. Unauthorized distribution is strictly prohibited.

Table 1 Patient́s work-up

Parameter	Obtained value	Reference value	Reference unit
Creatinine	0.3	0.5–1.5	mg/dL
Ureic nitrogen	10	8–20	mg/dL
Na^+	140	135–150	mEq/L
K^+	4,2	3.5–5	mEq/L
Cl^-	105	96–106	mEq/L
Mg^{2+}	2	1.6–2.3	mEq/L
CPR	<0,5	1	mg/dL
Hemogram			
Leucocytes	12.2	5.5–15.5	$\times 10^3$ cell $\times$ L
Neutrophils	2.56	1.5–8.5	$\times 10^3$ cell $\times$ L
Lymphocytes	8.54	2.0–8.0	$\times 10^3$ cell $\times$ L
Hemoglobin	12.5 g	12–16	g/dL
Hematocrit	38	36–8	%
Platelets	340	150–450	$\times 10^3$ cell $\times$ L
Urinalysis			
pH	6.0	5–7	–
Density	1.007	1.005–1.030	–
Proteins	0	0–14	mg/dL
Leukocyte esterase	Negative	Negative	–
Nitrites	Negative	Negative	–
Epithelial cells	1	1–2	Por campo
Red blood cells	0	0–1	Por campo
Respiratory panel virus Adenovirus, Influenza A y B, VSR, human metapneumovirus y parainfluenza 1, 2 years 3	Negative	–	–
Valproic acid	37.3	50–100	µg/mL
PCR* SARS CoV2	Negative	–	–
TORCH work-up	Negative	–	–

Abbreviations: Na^+, sodium, K^+, potassium; Cl^-, chloride, Mg^{2+}, magnesium; CPR, C-reactive protein; RSV, respiratory syncytial virus; PCR*, protein chain reaction; TORCH, Toxoplasmosis (VDRL), Rubella, Cytomegalovirus, Herpes (IgM and IgG) and Human Immunodeficiency Virus (HIV) (Third generation ELISA).

Due to the unpredictability of the clinical course of the SWS type III, it is both challenging to diagnose and treat, based on the wide clinical spectrum, because it can start from being asymptomatic or a migraine-like headache,[1] to medically intractable seizures,[18] along with hemiparesis,[5] and cognitive impairment.[19]

Epilepsy in patients with SWS is usually focal but may secondarily generalize,[18] with an incidence up to 90% in patients in SWS type I; however, in a great proportion of patients the debut could be as status epilepticus, with a long remission time between seizures.[12,18] In the current management, prophylaxis should be included because several studies have shown its importance to reducing the risk of cognitive impairment.[18,19] The m-Tor inhibitor agent sirolimus in combination with low-dose aspirin or phenobarbital has been successfully used. Medical management of seizures often has to be aggressive, and has included oxcarbazepine, because of a favorable rate of adverse effects reported,[4] in combination with carbamazepine or levetiracetam, particularly useful in patients with bilateral brain involvement; in cases when the patients have migraine-like headaches management could be complemented with valproic acid or topiramate.[1,4] Regarding surgical management, it is considered to have prophylactic potential,[16,17] and in up to 50% of the patients, hemispherectomy or a functional hemispherectomy can be performed with great outcomes regarding epilepsy control.[12,16,20] It was not considered in this patient because she had control of her epilepsy episodes. Management should also include anti-aggregation, usually with acetyl salicylic acid in dose between 3 and 5 mg/kg/d, because it helps to control seizures by diminishing the blood stasis[12] and may help to avoid hemiparesis and stroke-like episodes.[16,20]

 © 2022. Thieme. All rights reserved.

This document was downloaded for personal use only. Unauthorized distribution is strictly prohibited.

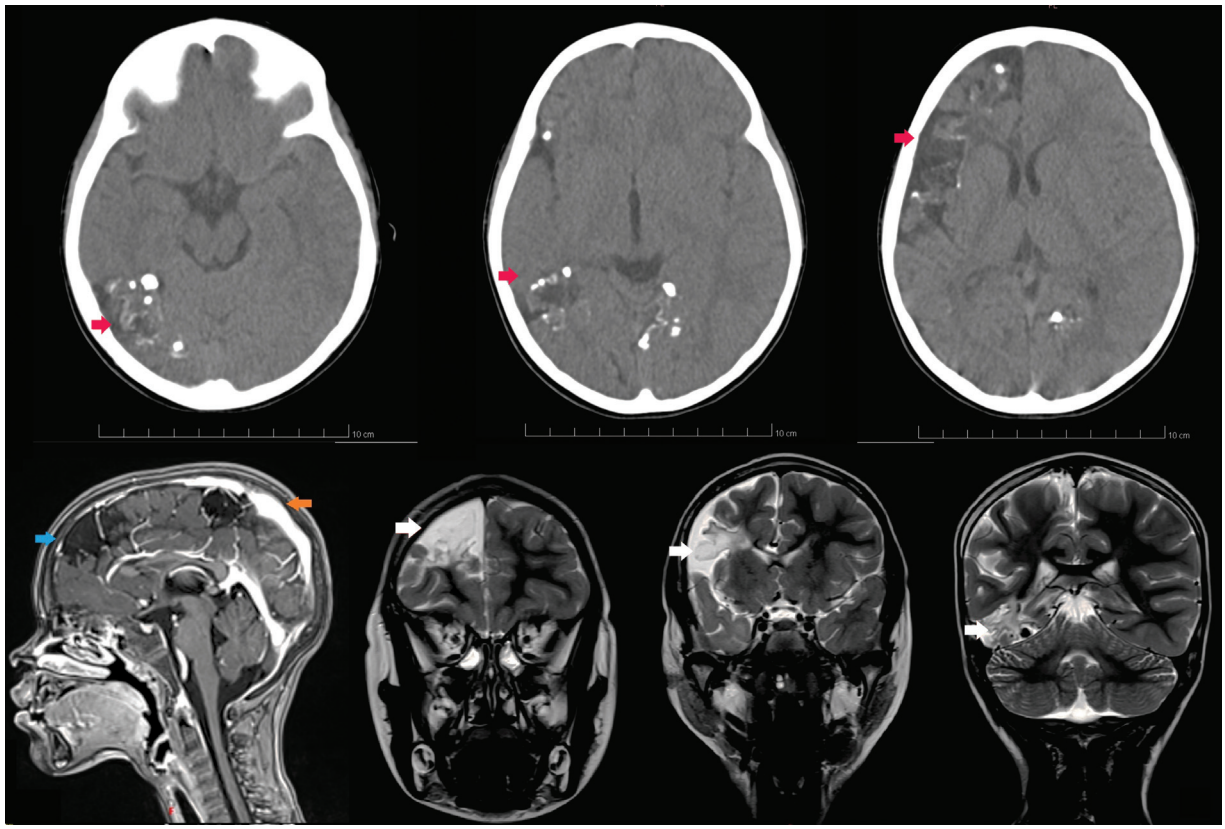

Fig. 1 *Top line:* head CT sequence in axial cuts, showing multiple subcortical and irregular calcifications dispersed in the right brain hemisphere and the calcarine gyrus, along with the *tram-track sign (red arrow). Bottom line*: head magnetic resonance (MRI), contrast enhancing images showing leptomeningeal malformations with brain parenchymal loss (*blue arrow*), and leptomeningeal thickening (*orange arrow*). Head MRI, T2 sequence in coronal cuts, showing leptomeningeal capillary malformations (*white arrows arrows*) along the right hemisphere.

Table 2 Publications presenting a SWS type III in the pediatric population

Authors	Sex	Age[a]	Main findings
Zanzmera et al[7]	M	9	Patient with normal birth and development, who presented complex focal seizures since he was 9 mo. Those seizures were managed and controlled with valproic acid and clobazam during his initial 3 y. But later, despite he was on medication, he started with partial complex seizures along with central vertigo and throbbing headache. Neurological, ophthalmological, and general physical exam did not show any pathological findings. EEG revealed right posterior head region spike and wave discharges and hCT scan showed focal cortical atrophy over the right parietal region and gadolinium contrast revealed LMC over the same region. Management with clobazam and oxcarbazepine was administered, with great medical response and the patient was seizure-free in his 6-mo follow-up.
Mukherjee et al[8]	F	3	Patient with normal birth and development, presented in the ER with afebrile right-sided complex partial seizures since he was 1 year old, without improvement after management with phenytoin. During her hospitalization, EEG showed epileptiform paroxysmal burst of discharges with hypsarrhythmia with significant cortical dysfunction, predominantly involving left hemisphere, and her hCT showed gyral thickening, gyriform enhancement, and focal calcification at left frontoparietal region with diffuse edema and mass effect and her bMRI showed left frontal, parietal, and occipital LMC with calcifications. She was discharged with valproate acid with no episodes of seizures.
Jordan et al[9]	M	9	Patient presented to the ER with severe throbbing left temporal headache and vomiting. His medical records showed a similar episode when he was 6 years old. In that episode, he had the same characteristics of the headache, along with vomiting but with a prolonged generalized seizure, requiring orotracheal intubation. The working diagnosis at that time was encephalitis, however, spine fluid and hCT were

 © 2022. Thieme. All rights reserved.

This document was downloaded for personal use only. Unauthorized distribution is strictly prohibited.

Table 2 (*Continued*)

Authors	Sex	Age[a]	Main findings
			within normal values, and he was discharged without further complication 1 wk later. On assessment in the current episode, he scored 15/15 on the GCS and had an unremarkable systemic examination. hCT contrast showed focal areas of cortical/subcortical calcification in the left occipital lobe, initially considered as postencephalitic laminar calcification, but radiology described as pial capillary malformation. The patient persisted with the headache despite the analgesic management and after serial evaluations made by neurology, a right-sided homonymous hemianopia was found; based on the clinical features he received the diagnosis of SWS type III. Eight days later after being discharged he was brought to the ER with recurrence of the headache along with sudden acute confusion and decreasing conscious level; the diagnosis at that time was a complex partial seizure, managed with phenytoin. He was discharged managed with levetiracetam. Headache improved but the visual defect remained.
Gururaj et al[10]	F	12	Patients were born to consanguineous parents, with normal birth and development. When she was 2 years old, she began with brief, generalized tonic clinic seizures with fever, and was started on phenobarbital as prophylaxis. These episodes last until she was 5 years old. When she was 7 years old, she experienced afebrile seizures, the EEG showed spike-wave activities over the left occipital area with secondary generalization, and the hCT showed a cortical curvilinear calcification in the left parieto-occipital area associated with surrounding leptomeningeal hypervascularity. At that time, she was managed with carbamazepine with poor adherence. When she was 12 years old, she was admitted in status epilepticus, controlled with diazepam, bMRI showed an obvious leptomeningeal blush in the polar area of the occipital lobe, with deep veins draining posteriorly into the left lateral ventricle. She was restarted on carbamazepine with proper dose, with no further seizure episodes.
Martínez-Bermejo et al[11]	M	12	Patient without intellectual deterioration, with a previous diagnose of epilepsy. After a hard-managing crisis, hCT showed right temporal and occipital atrophy along with calcifications at the same level. bMRI showed LCM and calcification in the same level described in the CT. The EEG showed spike focal activity in the right parieto-occipital region.
	F	8	Patient without intellectual deterioration, with a precedent of epilepsy managed with valproic acid. A new work-up set requested by pediatric neurology included an EEG, showing interhemispheric asymmetry and low electric potential in the left hemisphere. hCT showed a left occipital paramedian calcification, and the bMRI showed LCM in the left occipital region.
	M	11	Patient evaluated due to difficulties for learning. EEG showed a slight decrease in the amplitude of the potentials registered in the right hemisphere. hCT showed a cortical/subcortical calcification in the right occipital region, and the bMRI showed hypertrophic veins in the right parietal and occipital region.

Abbreviations: bMRI, brain magnetic resonance; EEG, electroencephalogram; ER, emergency room; M, masculine; F, feminine; GCS, Glasgow Coma Score; hCT, head tomography; LCM, leptomeningeal capillary malformations; *Age in years, yo, years old.

Considering the complexity of the SWS, management should be addressed by a multidisciplinary team,[16,19,20] where a proper clinical approach by the emergency and general pediatric services may lead to a better outcome, based on the early start of proper management. Quality of life should be continuously assessed because main goals include involvement with family and peers, reducing adverse effects of the anticonvulsants, and emotional support. Interestingly, patients who started antidepressants had worst cognitive development.[1,6,17]

Conclusion

SWS is a rare neurocutaneous disease, usually diagnosed in patients with pathognomonic features, however, it is important to know that type III SWS exists and represents a challenging diagnosis, leading to a time-race for starting proper management, considering that the outcome includes a better quality of life, a higher cognitive result, and reduced morbimortality.

Ethical Approval

Informed consent was obtained from the patient's parents for publication of the case report and accompanying images. The present publication was also approved by the local ethics committee.

Conflict of Interest

None declared.

 © 2022. Thieme. All rights reserved.

This document was downloaded for personal use only. Unauthorized distribution is strictly prohibited.

References

1 Arkush L, Prabhakar P, Scott RC, Aylett SE. Headache in children with Sturge-Weber syndrome – prevalence, associations and impact. Eur J Paediatr Neurol 2020;27:43–48
2 Shirley MD, Tang H, Gallione CJ, et al. Sturge-Weber syndrome and port-wine stains caused by somatic mutation in GNAQ. N Engl J Med 2013;368(21):1971–1979
3 Higueros E, Roe E, Granell E, Baselga E. Síndrome de Sturge-Weber: revisión. Actas Dermosifiliogr 2017;108(05):407–417
4 Luat AF, Juhász C, Loeb JA, et al. Neurological complications of Sturge-Weber syndrome: current status and unmet needs. Pediatr Neurol 2019;98:31–38
5 Waelchli R, Aylett SE, Robinson K, Chong WK, Martinez AE, Kinsler VA. New vascular classification of port-wine stains: improving prediction of Sturge-Weber risk. Br J Dermatol 2014;171(04): 861–867
6 Roach ES. Neurocutaneous syndromes. Pediatr Clin North Am 1992;39(04):591–620
7 Zanzmera P, Patel T, Shah V. Diagnostic dilemma: Sturge-Weber syndrome, without facial nevus. J Neurosci Rural Pract 2015;6 (01):105–107
8 Mukherjee D, Kundu R, Niyogi PC. Sturge-Weber syndrome type III. Indian J Pediatr 2015;82(01):97–98
9 Jordan PR, Iqbal M, Prasad M. Sturge-Weber syndrome type 3 manifesting as 'Status migrainosus'. BMJ Case Rep 2016;2016: bcr2016216842
10 Gururaj AK, Sztriha L, Johansen J, Nork M, Aithala G. Sturge-Weber syndrome without facial nevus: a case report and review of the literature. Acta Paediatr 2000;89(06):740–743
11 Martínez-Bermejo A, Tendero A, López-Martín V, et al. Angiomatosis leptomeníngea occipital sin angioma facial. Debe considerarse como variante del síndrome de Sturge-Weber? Rev Neurol 2000;30(09):837–841
12 Comi AM. Sturge-Weber syndrome. Handb Clin Neurol 2015; 132:157–168
13 Ha A, Kim JS, Baek SU, et al. Facial Port-Wine Stain phenotypes associated with glaucoma risk in neonates. Am J Ophthalmol 2020;220:183–190
14 Lagarde S, Bartolomei F. Focal Epilepsies and Focal Disorders. 2019:17–43
15 Goyal P, Mangla R, Gupta S, et al. Pediatric congenital cerebrovascular anomalies. J Neuroimaging 2019;29(02):165–181
16 Iyer RR, Strahle JM, Groves ML. Neurosurgical considerations of neurocutaneous syndromes. Neurosurg Clin N Am 2022;33(01): 81–89
17 Bianchi F, Auricchio AM, Battaglia DI, Chieffo DRP, Massimi L. Sturge-Weber syndrome: an update on the relevant issues for neurosurgeons. Childs Nerv Syst 2020;36(10):2553–2570
18 Stafstrom CE, Staedtke V, Comi AM. Epilepsy mechanisms in neurocutaneous disorders: tuberous sclerosis complex, neurofibromatosis type 1, and Sturge-Weber syndrome. Front Neurol 2017;8:87
19 Powell S, Fosi T, Sloneem J, Hawkins C, Richardson H, Aylett S. Neurological presentations and cognitive outcome in Sturge-Weber syndrome. Eur J Paediatr Neurol 2021;34:21–32
20 Bourgeois M, Crimmins DW, de Oliveira RS, et al. Surgical treatment of epilepsy in Sturge-Weber syndrome in children. J Neurosurg 2007;106(Suppl 1):20–28

This document was downloaded for personal use only. Unauthorized distribution is strictly prohibited.

 © 2022. Thieme. All rights reserved.