



Fulminant Herpes Pneumonia Post-aortic Surgery with Known Ankylosing Spondylitis

Nicole Asemota, MBBS, BMedSci (Hons)¹ Ikenna David Ike, MBBS (Hons)¹
Aung Ye Oo, MD, FRCS-CTh¹ Ana Lopez-Marco, PhD, FRCS-CTh¹

¹Department of Cardiothoracic Surgery, St Bartholomew's Hospital, London, United Kingdom

Aorta (Stamford) 2022;10:256–258.

Address for correspondence Ana Lopez-Marco, PhD, FRCS-CTh, Department of Cardiothoracic Surgery, St Bartholomew's Hospital, West Smithfield, London EC1A 7BE, United Kingdom (e-mail: ana.lopez-marco@nhs.net).

Abstract

Herpes simplex virus (HSV) pneumonitis is rare after cardiac surgery. A 36-year-old gentleman with ankylosing spondylitis underwent emergency surgery for a complex aortic aneurysmal disease. Preoperative treatment of aortitis with antitumor necrosis factor and steroid medication and surgical stress including cardiopulmonary bypass potentially created an immunosuppressive state and reactivation of undiagnosed HSV. Rapid HSV pneumonia ensued, culminating in fulminant organ failure and mortality. HSV pneumonia should be considered postoperatively in patients with severe respiratory distress, especially if immunocompromised.

Keywords

- ▶ pneumonia
- ▶ herpes simplex
- ▶ postoperative
- ▶ immunosuppression

Introduction

Although herpes simplex virus (HSV) reactivation is not uncommon in immunosuppressed states,¹ HSV pneumonitis after cardiac surgery is rare and only sporadically reported.^{1–3} We present a fulminant HSV pneumonitis in a young, immunosuppressed patient after surgery for a rapidly expanding aortic arch aneurysm secondary to ankylosing spondylitis.

Case Presentation

A 36-year-old gentleman with a background of ankylosing spondylitis (AS) was incidentally diagnosed with a 51-mm aortic arch aneurysm, involving the innominate artery (IA) and left subclavian artery (LSA), as well as a 25-mm aneurysm of the left common carotid artery (LCCA; ▶ **Fig. 1**). Surgical indication was made based on the aortic diameters, but persistently elevated inflammatory markers at the time of diagnosis compatible with acute vasculitis delayed the surgery until optimization of the inflammatory status to reduce postoperative complications.

He received a course of antitumor necrosis factor (TNF) therapy (adalimumab) and intravenous methylprednisolone

over 2 months until the inflammatory markers normalized. A new pulsatile mass became evident in the neck due to the rapid expansion of the LCCA aneurysm (70 mm × 25 mm × 26 mm; ▶ **Fig. 2**).

Urgent surgery was then performed and consisted of aortic arch replacement with a 30 mm × 100 mm Thoraflex frozen elephant trunk anastomosed to zone 1 of the aortic arch, with reimplantation of the IA and LCCA onto the corresponding branches of the arch graft and extra-anatomical bypass of the LSA. Surgery was performed via a ministernotomy (J-shaped toward the fourth right intercostal space), and cardiopulmonary bypass (CPB) was established by cannulation of the LSA with an 8-mm Dacron graft anastomosed end to side, and the right atrium with a double stage venous cannula. Hypothermic circulatory arrest (28 °C), antegrade cerebral perfusion (via selective cannulation of IA, LCCA, and LSA), and myocardial protection with repeated administration of antegrade cold blood cardioplegia were used.

The procedure was uneventful, and he was transferred to intensive care in a stable condition. He was extubated in the early postoperative hours but developed worsening metabolic acidosis with discrete response to fluid resuscitation and bicarbonate administration. A transesophageal echocardiogram

received
September 13, 2021
accepted after revision
April 13, 2022

DOI <https://doi.org/10.1055/s-0042-1757791>.
ISSN 2325-4637.

© 2022. The Author(s).

This is an open access article published by Thieme under the terms of the Creative Commons Attribution License, permitting unrestricted use, distribution, and reproduction so long as the original work is properly cited. (<https://creativecommons.org/licenses/by/4.0/>)

Thieme Medical Publishers, Inc., 333 Seventh Avenue, 18th Floor, New York, NY 10001, USA

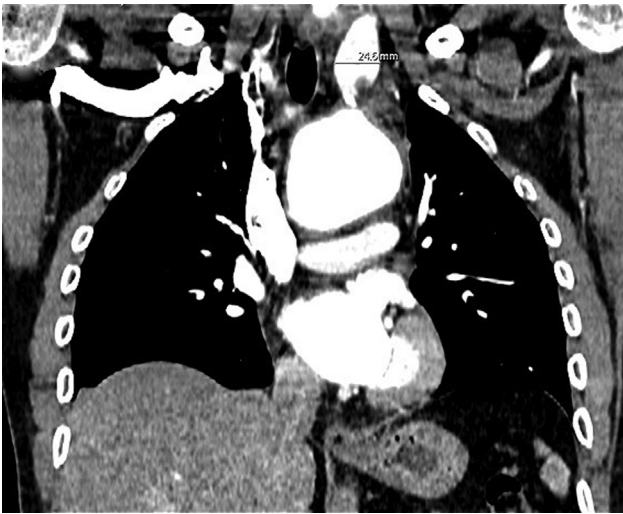

Fig. 1 Coronal view of preoperative computed tomography scan demonstrating a 55-mm aortic arch aneurysm involving the origin of the supra-aortic trunks, with a separate aneurysm of the left common carotid (25 mm).

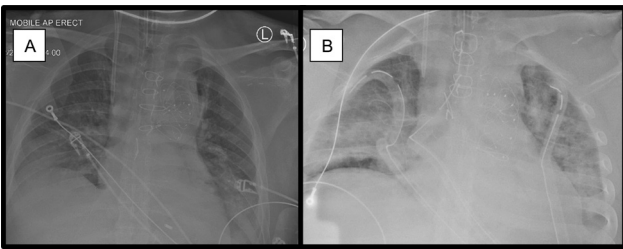


Fig. 3 Anteroposterior erect chest X-rays: serial postoperative anteroposterior chest-X-rays taken on postoperative day 2 in the interval of 6 hours. Note the rapid progression of widespread bilateral ground-glass opacification, consisting bilateral pneumonitis.

demonstrated no evidence of tamponade or cardiac impairment.

The following day, he developed fast atrial fibrillation with hemodynamic compromise, requiring both electric and pharmacological cardioversions that were ineffective.

Due to worsening metabolic acidosis and hypoxia, he was reintubated and started on continuous veno-venous hemofiltration.

Serial chest X-rays demonstrated progressive bilateral widespread infiltrates (► **Fig. 3**). A computed tomography scan of the chest, abdomen, and pelvis was performed, ruling out bowel ischemia.

He was taken back to the theater for reexploration with no abnormal findings.

He continued to decline with evidence of refractory ischemic hepatic failure. He was declined for extracorporeal membrane oxygenation due to worsening multiorgan failure and died shortly after.

Postmortem examination surprisingly revealed extensive bilateral bronchopneumonia due to HSV infection that had caused the progressive and refractory multiorgan failure. Histopathology analysis of the aortic tissues confirmed aortitis secondary to autoimmune disease.

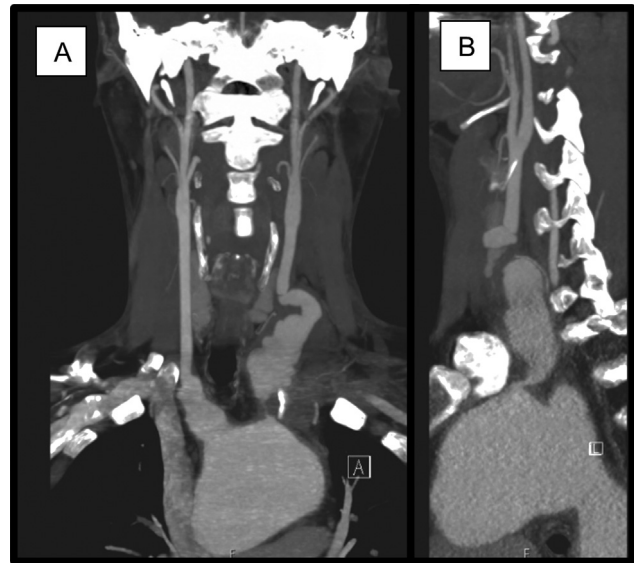


Fig. 2 (A) Coronal view and (B) sagittal view of interval preoperative computed tomography scan demonstrating expansion of left common carotid aneurysm (70 mm x 25 mm x 26 mm).

Discussion

The association between AS and cardiac disease has been widely demonstrated. The common manifestations include aortic valve regurgitation and arrhythmias, although aortitis and aneurysmal disease have also been described, rarely requiring surgical intervention.⁴

Common side effects of anti-TNF therapy (used commonly in AS) include respiratory tract infections and hepatitis,⁵ which are never evident preoperatively. Despite aortic aneurysm being listed as an uncommon side effect of adalimumab,⁵ it is difficult to ascertain if this contributed to the rapid expansion of the aneurysm in our patient.

The relationship between immunosuppression and HSV pneumonia has been widely demonstrated.¹ HSV pneumonia is rare after cardiac surgery.^{1,2} Sporadic cases are reported in both immunocompetent and immunocompromised patients, presenting with acute hypoxic deterioration (often requiring invasive ventilation), ground-glass opacification on chest radiography (► **Fig. 3**), no organisms on bacterial sputum cultures, and failure to respond to antibiotics.¹⁻³ Polymerase chain reaction analysis for HSV from bronchial aspirates is the best diagnostic investigation.¹ Many reported cases responded well to acyclovir treatment, although none of them described such fulminant multiorgan failure as in our patient.^{1,2}

It is unclear whether prior knowledge of latent disease would have aided in diagnosis and treatment. Viral screening and infection history are routinely conducted in heart transplant patients due to the risk of reactivations once immunosuppressed⁶; however, due to the wide prevalence of HSV in the general population,¹ the benefit of routine preoperative screening may be minimal. Furthermore, CPB has a weakening effect on cell-mediated immunity ranging from transient to sustained suppression months after

surgery.^{1,2} Therefore, it can be argued that all patients should be treated as temporarily immunocompromised after bypass surgery.¹

In conclusion, we report a case with a rapidly expanding aneurysm of the aortic arch and supra-aortic trunks in the context of rheumatological disease treated with anti-TNF and steroids preoperatively. This led to an immunosuppressive state that contributed to the reactivation of unknown previous HSV infection in the immediate postoperative period causing fulminant pneumonia. HSV pneumonitis, although rare, should be considered in patients presenting with severe respiratory complications, particularly if immunocompromised. The addition of a viral screening panel should be considered for immunosuppressed patients undergoing cardiac surgery when time permits. Rapid developing and refractory hypoxia in a young, immunosuppressed patient should trigger the suspicion of fulminant viral pneumonia and consideration for early veno-venous extracorporeal membrane oxygenation.

Funding

None.

Conflict of Interest

The authors declare no conflict of interest related to this article.

Acknowledgments

None.

References

- 1 Arata K, Sakata R, Iguro Y, Toda R, Watanabe S, Eitsuru Y. Herpes simplex viral pneumonia after coronary artery bypass grafting. *Jpn J Thorac Cardiovasc Surg* 2003;51(04):158–159
- 2 Shimokawa S, Watanabe S, Taira A, Eizuru Y. Herpes simplex virus pneumonia after cardiac surgery: report of a case. *Surg Today* 2001;31(09):814–816
- 3 Breyer RH, Andrews RI, Mills SA, Cordell AR, Ahl ET. Probable herpes simplex pneumonia after aortic valve replacement. *JAMA* 1983;249(10):1319–1322
- 4 Yuan SM. Cardiovascular involvement of ankylosing spondylitis: report of three cases. *Vascular* 2009;17(06):342–354
- 5 NICE. ADALIMUMAB. Drug. British National Formulary. London, U.K.: National Institute for Health and Care Excellence; 2020
- 6 Banner NR, Bonser RS, Clark AL, et al. UK guidelines for referral and assessment of adults for heart transplantation. *Heart* 2011;97(18):1520–1527