

Endovascular Infusion of Amphotericin B for the Treatment of Rhino-Orbito-Cerebral Mucormycosis: A Pilot Study Assessing Technical Feasibility and Safety

Subhash Kumar¹ Kranti Bhavana² Vijay Kumar³  Amarjeet Kumar⁴ Mala Mahto⁵

¹Department of Radiodiagnosis, All India Institute of Medical Sciences, Patna, Bihar, India

²Department of ENT, All India Institute of Medical Sciences, Patna, Bihar, India

³Department of General Medicine, All India Institute of Medical Sciences, Patna, Bihar, India

⁴Department of Anaesthesiology, All India Institute of Medical Sciences, Patna, Bihar, India

⁵Department of Biochemistry, All India Institute of Medical Sciences, Patna, Bihar, India

Address for correspondence Subhash Kumar, MBBS, MD, DM, Department of Radiodiagnosis, All India Institute of Medical Sciences, Patna, Phulwarisharif, Patna, Bihar 801507, India (e-mail: drsubhash.dm@gmail.com).

Arab J Intervent Radiol 2022;6:92–98.

Abstract

Objectives The aim of this study was to assess the technical feasibility and safety of intra-arterial infusion of amphotericin B for the management of rhino-orbito-cerebral mucormycosis in patients unable to receive full dose and schedule of intravenous amphotericin B and/or unsuitable for surgery.

Materials and Methods Five consecutive patients underwent five sessions of intra-arterial infusion each via both external carotid arteries on alternate days. Liposomal amphotericin B (50 mg) was infused at each session. The baseline and follow-up investigations as well as local and systemic complications were charted.

Results Procedure could be completed for all participants without any local complications. One patient had transient and another had progressive deterioration in renal parameters during the follow-up period of 30 days.

Conclusions Authors conducted successfully a pilot study of multisession intra-arterial infusion of amphotericin B, with the premise that it can provide high concentration of drug at the desired site with reduced systemic complications. They recommend further larger randomized studies to evaluate its efficacy for the management of advanced rhino-oculo-cerebral mucormycosis.

Keywords

- ▶ mucormycosis
- ▶ rhino-orbito-cerebral
- ▶ COVID-19
- ▶ amphotericin B
- ▶ endovascular

Introduction

Rhino-orbito-cerebral mucormycosis (ROCM), a rare but highly aggressive disease, has been increasingly reported

during the novel coronavirus disease 2019 (COVID-19) pandemic from various parts of the world.^{1–6} Its recommended therapy includes extensive surgery and intravenous amphotericin B (amB) injections (5–10 mg/kg/per day for ~4 weeks,

published online
November 1, 2022

DOI <https://doi.org/10.1055/s-0042-1757783>.
ISSN 2542-7075.

© 2022. The Pan Arab Interventional Radiology Society. All rights reserved.

This is an open access article published by Thieme under the terms of the Creative Commons Attribution-NonDerivative-NonCommercial-License, permitting copying and reproduction so long as the original work is given appropriate credit. Contents may not be used for commercial purposes, or adapted, remixed, transformed or built upon. (<https://creativecommons.org/licenses/by-nc-nd/4.0/>)

Thieme Medical and Scientific Publishers Pvt. Ltd., A-12, 2nd Floor, Sector 2, Noida-201301 UP, India

preferably of the liposomal form), followed by a long course of oral posaconazole or isavuconazole.⁷⁻¹⁰ Medical comorbidities or poor general condition, especially in the setting of COVID-19 related lung disease, mean that patients can neither have surgery nor be given full dose of amB, the latter being a highly toxic drug.

Endovascular drug infusion has been increasingly utilized for many indications including chemotherapy and thrombolysis, with the premise of achieving a higher local concentration of the drug, while minimizing systemic side effects. Intra-arterial antibiotic infusion has also been reported in literature, including those for pyogenic and fungal liver and splenic abscesses, infected pancreatic necrosis, mandibular osteomyelitis, as well as for septic and fungal limb infections.¹¹⁻¹⁸ Thus, the precedence, technical expertise, and tools are available to evaluate intra-arterial chemotherapy for ROCM.

Objectives

The aim of this study was to evaluate safety and technical feasibility of intra-arterial infusion of liposomal amB in ROCM patients unfit for surgery and/or full dose of intravenous amB.

Materials and Methods

After due approval of the Institute Ethics Committee (IEC), consecutive cases of microbiologically proven ROCM deemed unfit for surgery within 5 days of diagnosis and/or full dose of intravenous amB were included in a prospective pilot study during the period of June and July 2021. Patients with extensive and multifocal intracranial disease, pulmonary fungal disease, and those already received antifungal therapy were not included.

Digital subtraction angiography (DSA) and endovascular amB infusion technique were used in this study.

The study participants underwent a six-vessel cerebral DSA on a Philips Allura Clarity biplane DSA machine by a single operator with 14 years' experience, to study the arterial anatomy and evaluate stenosis and occlusions, if any. Subsequently, five sessions of intra-arterial infusions of amB were performed on alternate day. Liposomal amB (50 mg) was reconstituted in 25 mL of 5% dextrose and the reconstituted drug was passed through a 5 micron filter provided with the injection vial package to obtain a clear yellowish fluid. Three different Indian brands of the drug were used, made by Cipla, Celon Labs, and Lyka laboratories, depending upon availability of the drug, as amB was in short supply and heavy demand during this period.

The reconstituted fluid was infused either in the external carotid artery (ECA) trunk via a 5 French size diagnostic catheter or in case of unstable catheter position, via a 2.7 French size microcatheter (Progreat, Terumo Corporation, Tokyo, 151-0072, Japan) placed in the internal maxillary and facial arteries. The fluid was injected at the rate of 1 mL/min, for a total injection time of 24 minutes (1 mL fluid was accounted for by wastages during syringe filling and exchanges). The total dose of 50 mg was divided equally

for diffuse bilateral disease (12 mL reconstituted fluid for each side) or two-third and one-third for asymmetrical involvement (16 mL on the side with larger extent of disease and 8 mL on the side with lesser disease).

The intra-arterial infusions were given on alternate days, and investigations including blood urea, serum creatinine, serum electrolytes, and complete blood counts were checked every day till 2 weeks. The patients were kept in a dedicated mucormycosis intensive care unit or ward and monitored.

The two femoral arteries and the right radial artery were punctured on different days, so as to prevent local site complications. For femoral artery punctures, clean dressing was applied and the punctured site limb was not allowed to be flexed for 6 hours. For radial artery punctures, air-filled compression bands were used for 2 hours. No additional measures were used for local puncture site infection control, as per our routine practice for vascular interventions.

During the angiography procedure, an iso-osmolar iodinated contrast medium iodixanol 270 mg/mL (Wipro GE Healthcare Pvt. Ltd., Bengaluru, 560067, Karnataka, India) was used at 1:3 dilution, using hand injections, with maximum volume restricted to 15 mL for each session.

Other standard care of comorbidities and COVID-19 continued as per institutional and national guidelines. The study participants were prescribed oral posaconazole 100 mg thrice a day during the 10 days duration of the endovascular therapy and advised to continue for a further minimum period of 6 months. Local site and systemic complications were charted and repeat magnetic resonance imaging (MRI) study performed at 1 month, which was also the study endpoint.

Results

The IEC had granted approval for 10 participants; however, the study was stopped after 5, as the number of new ROCM admissions reduced drastically in late July 2021. A total of 9 patients were counselled, of which 5 had provided consent. Another participant provided consent for only one session and was not included in the study. The baseline data are provided in ► **Table 1**. All patients had diabetes mellitus, uncontrolled, or newly detected during COVID-19 management and were treated with insulin. All had received steroids earlier.

The infusion could be performed in all cases for five sessions, without any direct procedure related complications. Case 3 had transient increase in serum creatinine after the third session, which resolved at 2 weeks; case 5 had progressively deteriorating renal functions. Two participants (case 4 and 5) required sedation with intravenous midazolam during the procedure.

MRI of all five cases were performed at 1 month (+ 5 days deviation), and showed extension of disease in three participants (case 1, 3, 5), with maximum changes noted in case 3.

Five out of ten eyes had complete vision loss at presentation, and none had any improvement, nor did any worsening

Table 1 Characteristics of ROCM patients undergoing endovascular amphotericin B infusion

	Case 1 (– Fig. 1)	Case 2 (– Fig. 2)	Case 3 (– Fig. 3)	Case 4	Case 5
Age, sex	55 years, F	58 years, F	35 years, M	60 years, M	70 years, M
Onset of ROCM-related symptom(s) during active COVID-19 disease	Yes	Yes	Yes	5 days after testing negative for COVID-19	Yes
Gap between symptom onset and imaging	17 days	25 days	20 days	14 days	5 days
Diabetes mellitus	> 10 years	7 years	Detected during COVID-19 management; on insulin	Detected during COVID-19 management; on insulin	5 years
Hypertension	> 10 years	7 years	No	No	Newly detected
Renal profile derangement	Yes	No	Raised blood urea	Yes, US showing renal parenchymal disease	Yes, progressively deteriorating
Lungs	Minimal changes of COVID-19 pneumonia	Moderate changes of COVID-19 pneumonia, CT severity score 9/25	Severe COVID-19 pneumonia, CT severity score 19/25	Minimal changes of COVID-19 pneumonia	Mild changes of COVID-19 pneumonia
Oxygen supplementation during hospitalization	No	Yes	Yes	Yes	Yes
Others	Coronary artery disease	Hemorrhoids	–	Past history of pulmonary tuberculosis, left orbital injury a year back with vision loss	On treatment with multiple antipsychotic drugs
ICU care required during hospitalization	Yes, 7 days	Yes, 9 days	Yes, 18 days	Yes, 35 days	Yes, 19 days
Chief presenting complaint	Right facial swelling and skin necrosis, nasal bleeding	Left eye swelling, rapidly progressing to whole face, with bilateral vision loss	Periorbital and facial swelling, right eye vision loss	Bilateral periorbital swelling, decrease vision, patient drowsy, cerebritis, brain edema	Visual disturbance, periorbital and facial swelling
Disease symmetry	Right > left	Bilateral	Right > left	Right > left	Left > right
^a Clinicoradiological stage	4c	4c	4c	4c	4c
Reason for not performing surgery	1. Intracranial disease with vascular involvement 2. Coronary artery disease 3. Deranged renal profile with hyperkalemia	1. Bilateral central artery occlusion with complete vision loss 2. Intracranial disease 3. Bleeding hemorrhoids 4. Required prone positioning and high flow oxygen for maintenance of saturation	1. Poor pulmonary status precluding general anesthesia 2. Refusal by patient and family 3. Intracranial disease	1. Renal parenchymal disease 2. Intracranial infarcts 3. Poor sensorium (Glasgow coma scale 8/15) 4. Electrolyte imbalance (hyperkalemia) 5. NSTEMI 6. Patient on antiplatelet drugs	1. Refusal by family 2. Poor general health 3. Uncontrolled electrolyte levels, progressive renal disease 4. Intracranial disease
Salient DSA findings	Right cavernous ICA stenosis, bilateral terminal internal maxillary artery occlusion	Left ophthalmic artery stenosis, right ophthalmic artery occlusion	Right ophthalmic artery occlusion	Right ophthalmic artery occlusion	Left ophthalmic artery occlusion

Abbreviations: COVID-19, coronavirus disease 2019; CT, computed tomography; DSA, digital subtraction angiography; ICA, internal carotid artery; ICU, intensive care unit; NSTEMI, non-ST-elevation myocardial infarction; ROCM, rhino-oculo-cerebral-mucormycosis; US, ultrasound.
^aClinicoradiological staging performed as per Honavar.⁷

in the other eyes; however, three patients also received intraorbital amB injections.

No patient died during therapy, and none had puncture site or neurological complications.

Although the study end-point was 1 month, the participants were followed up every month, and 3 out of 5 have died by 6 months (at 1.5, 3.5, and 4.5 months approximately).

Discussion

ROCM is a very aggressive, rapidly progressing, angioinvasive disease, usually associated with uncontrolled diabetes mellitus, especially ketoacidosis, immunosuppression, malignancies, or chemotherapy¹⁹ (►Fig. 1). While COVID-19 has not yet been proven to have a direct association or causality, there have been increased number of ROCM cases in patients who have active COVID-19 or more commonly who have recovered recently.¹ It can be hypothesized that steroid intake in the background of uncontrolled diabetes leads to these cases¹⁹ however, these two have not been found in all such cases.

Nevertheless, the authors work in a 960-bed tertiary care institute, which was designated a dedicated COVID-19 care center and later a center of excellence for mucormycosis care by the government. Most cases reporting to the authors did have the combination of COVID-19, diabetes and steroid intake, including all the participants of this study.

Some of the patients had very extensive disease, and not suitable for surgery, which is the standard of care. Further, amB can be very toxic; thus, any mode of delivery, which can reduce its toxicity, is highly desirable. Further, it was in short supply due to the epidemic, and well as costly, and as the dose required per patient is very high,²⁰ search for alternative modes of delivery is highly desirable.

Local drug delivery offers a possibly higher concentration of drugs, thus forming the basis of intraorbital and intrathecal antifungal injections. However, intra-arterial infusion of antibiotics, as opposed to chemotherapeutic agents, is not

common. The authors could find limited literature of intra-arterial amB injections, and none for ROCM.^{11–18}

That endovascular infusion is technically feasible is proven from our study, and in experienced hands, complications will be as for diagnostic angiograms, which is less than 0.5%. Such complications can be related to the contrast medium, amB-related toxicity, or the procedure itself, and include puncture site hematoma, thromboembolism, stroke.

Thus, this mode of therapy can be explored further in prospective randomized trials.

However, the authors also realize that multiple sessions of procedures may be required per patients, and due to scarce facility of advanced catheterization laboratories in most places, it may be difficult to accommodate larger group of patients in real life.

We had opted for repeated vascular access and infusions rather than placing an indwelling catheter for prolonged endovascular infusion for several reasons, including:

1. The catheter needed to be placed in the ECA trunk, so that the drug reaches into all its branches. However, the ECA trunk is rather a short artery and catheter would inevitably get dislodged and fall back proximally into the common carotid artery
2. As infusion had to be given on both sides, two vascular access sites would have been required, thus making the patient relatively bed-bound, keeping the legs straight and immobilized for the entire duration of the therapy.
3. Continuous heparinization would have been required to prevent thrombotic and embolic complications
4. It is practically unknown to keep intra-arterial infusion catheters in situ for 10 days.

This study has some limitations. There are frequent chances of arterial stenosis and occlusions in ROCM, as seen in our study group, and also reported in literature, which may lead to failure of drug to reach the desired site. Also, as we infused amB only in the ECA, there would be

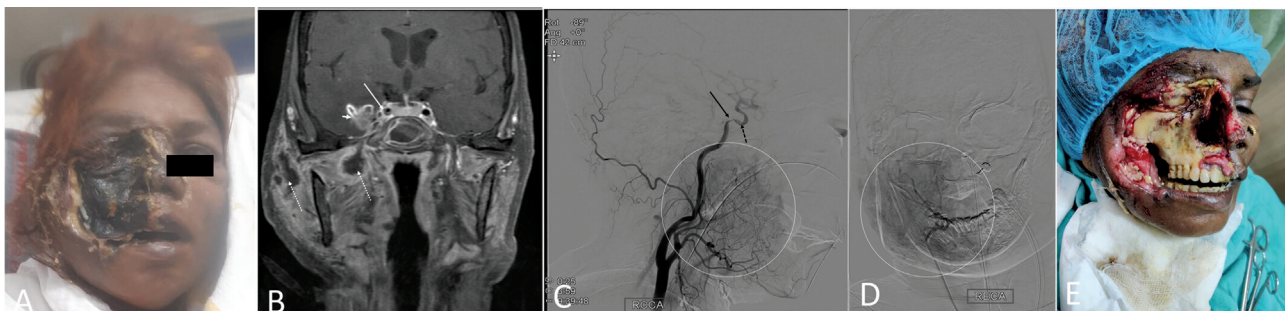


Fig. 1 Imaging of case number 1: a 55-year-old female. (A) Clinical image at admission showing extensive necrosis of the right faciomaxillary region. (B) Coronal fat-suppressed postcontrast T1-weighted image showing extensive soft tissue swelling and enhancement in infratemporal, temporal, masticator spaces with necrotic collections (dashed white arrows) within. There is intracranial extension and abscess formation in the right temporal lobe (short thick arrow). The right cavernous sinus is involved and the right internal carotid wall appears thickened (thin solid white arrow). (C) Cerebral digital subtraction angiography image, right common carotid artery injection, lateral view, showing severe stenosis of the posterior bend of the cavernous sinus segment of the internal carotid artery (long black arrow) and filling defect suggestive of thrombus in the horizontal portion of the cavernous internal carotid artery. (D) White oval indicates diffuse blush in the faciomaxillary region in the external carotid artery territory, the internal maxillary artery is not seen, likely to be thrombosed. (E) Post-debridement clinical picture; this patient died suddenly after 6 weeks while being planned for discharge from the hospital.

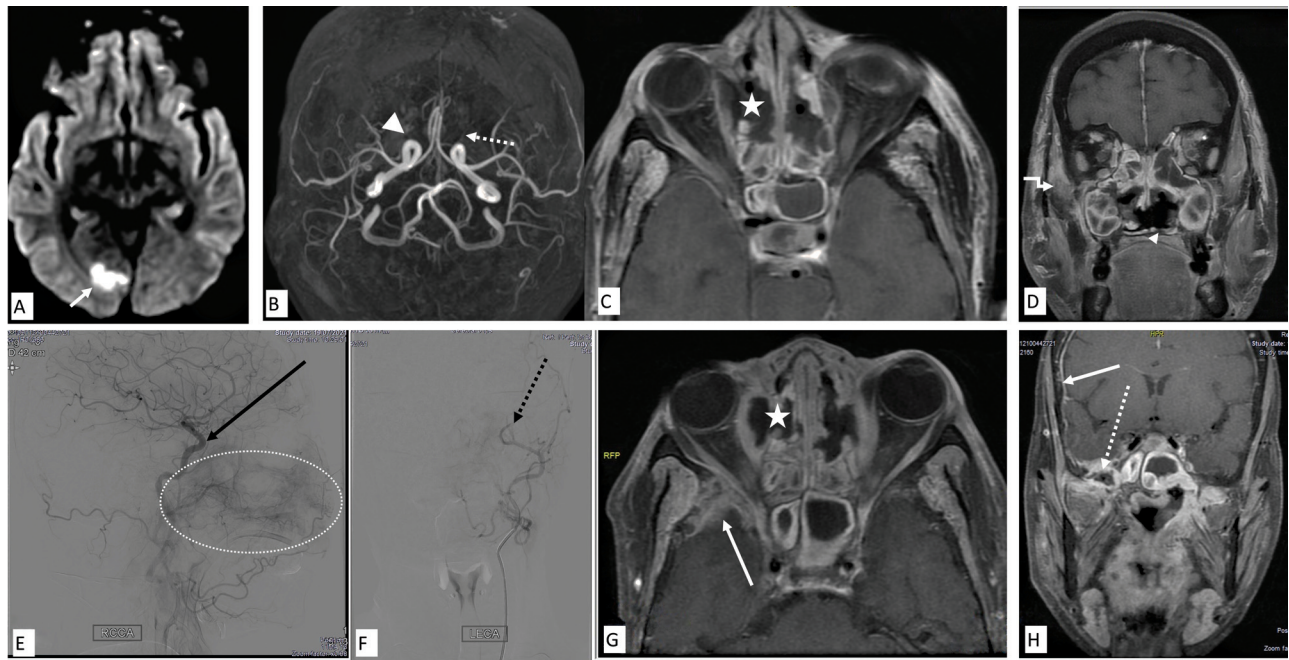


Fig. 2 Imaging of case number 2: a 58-year-old female with rhino-oculo-cerebral mucormycosis. (A) Axial diffusion-weighted imaging showing infarct in right occipital region (white arrow). (B) Axial maximum intensity projection image of time of flight magnetic resonance angiography showing occluded right ophthalmic artery (white arrowhead at the expected location of ophthalmic artery) and stenotic left ophthalmic artery with poor visualization distally (dashed white arrow). (C) Axial postcontrast T1-weighted (T1W) fat-suppressed image showing necrotic turbinates (white star) with extension of disease in orbits. (D) Coronal postcontrast T1-weighted (T1W) fat-suppressed image showing diffuse enhancement and swelling of facial soft tissue, as well as masticator muscles (zig-zag white arrow points to swollen and enhancing right temporalis muscle), note the pansinusitis, and necrotic turbinates; there is necrosis of the hard palate also (white arrowhead). (E) Digital subtraction angiography, right common carotid injection, lateral view, late arterial phase, demonstrating occluded right ophthalmic artery (black arrow at expected site of normal ophthalmic artery), and diffuse blush in the faciomaxillary region (white dashed oval) in the external carotid artery territory. (F) Anteroposterior view of left external carotid artery injection showing occlusion of distal left internal maxillary artery (dashed black arrow). (G) One-month follow-up magnetic resonance imaging, axial postcontrast T1W fat-suppressed image, showing increase in the tissue reaction visualized as thickened enhancing periphery around the necrotic areas, but with stable disease and no significant increase in necrosis (white star); however, there is dural thickening and enhancement in the middle cranial fossa (white arrow). (H) Postcontrast T1W coronal image showing skull base osteomyelitis (white dashed arrow) and dural thickening and enhancement extending along the convexity (white solid arrow).

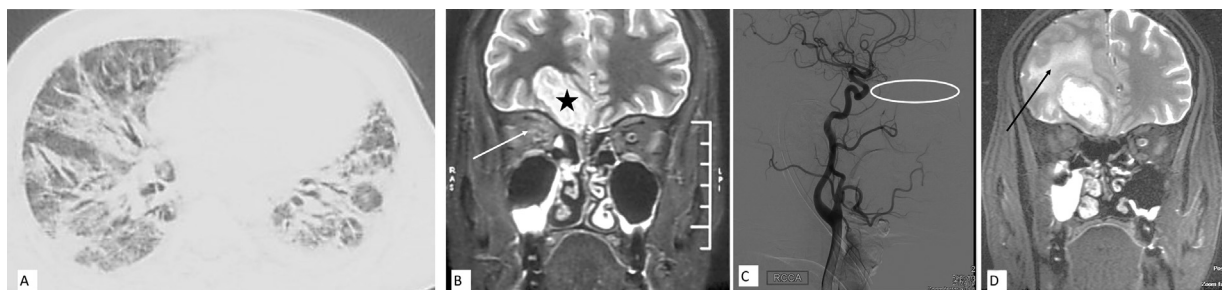


Fig. 3 Imaging of case number 3: a 35-year-old male with rhino-oculo-cerebral mucormycosis, newly detected type 2 diabetes mellitus, altered renal profile, and severe coronavirus disease 2019-related pneumonia. (A) Axial high-resolution computed tomography (CT) scan image of chest showing extensive consolidation and ground glass opacification of both lungs. (B) Coronal T2-weighted (T2W) fat-suppressed magnetic resonance (MR) image, performed 12 days after the chest CT, showing rhinosinusitis, edema, and soft tissue swelling in the right orbit (white arrow) and a right basifrontal abscess (black star). (C) Right carotid angiogram, lateral view, prior to the first session of endovascular amphotericin B infusion, 20 days after the MR scan, demonstrating nonvisualization of the right ophthalmic artery (the white oval indicates the normal location of the ophthalmic artery), suggesting thrombosis. (D) Coronal T2W fat-suppressed image, after 1 month of last session of endovascular infusion, showing edema around the abscess (black arrow), minimal increase in abscess size, and no change in the orbital involvement.

intracranial drug supply. In addition, the participants received oral posaconazole, and it is difficult to assign the degree of disease response to amB or posaconazole. However, addition of an azole (posaconazole or isavuconazole) is highly recommended for invasive mucormycosis

treatment, in addition to amB, as there is very high mortality in spite of high dosage and added surgery.²¹

Another limitation of the study is that four out of five participants did not undergo salvage surgery subsequent to amB infusion, for decreasing the fungal load. Surgery is

especially pertinent in the cases with radiological disease progression. Probably, after improvement in the general physical conditions, pulmonary and renal functions, surgery could have been performed, so as to speed up the recovery process.

The authors recognize that the amB dose and schedule in the study are somewhat arbitrary; however, it is to re-emphasize that amB stays in local tissues for up to 72 hours, and novel ways of drug administration are active areas of research; for example, aerosolized amB produces high local levels of drug in lungs even after 24 hours, and persist even after 336 hours.²¹ Intermittent or single dosing of the drug is also being researched for both therapy and prophylaxis.^{21,22} The authors did not measure the serum levels of amB for the reason that local concentration of drug would be high, and the serum levels would be naturally be low, considering that we infused 50 mg drug intra-arterially, instead of 5mg/kg (~350mg for a 70 kg person) given intravenously.

That ROCM by itself is highly fatal in spite of all currently known therapeutic options, is well known, and the endovascular therapy being an unknown entity for this indication, also has potential chances for clinical failure. The reasons may be due to the highly invasive nature of the disease, but also due to failure of successful drug delivery. There has to be a consistent technique of drug delivery with constant speed and good reach of the drug to the target areas. Further, infusion of the drug intracranially does not occur, if infusion is given in the ECA territory only; thus, potentially this therapy may be applicable only to extracranial disease. Further, the iodinated contrast used for angiography can add up to the nephrotoxic effect, and the dose has to be minimized as far as possible.

Conclusion

Authors describe a relatively safe novel way of amB therapy in COVID-19-associated ROCM, in patients unfit for surgery at presentation and/or full dose of intravenous amB, and recommend further research to establish its efficacy.

Ethical Statement

The study was conducted after approval of the Institute Ethics Committee, and has therefore been performed in accordance with the ethical standards laid down in the 1964 Helsinki Declaration and its later amendments.

Conflict of Interest

None declared.

References

- Sen M, Honavar SG, Bansal R, et al; members of the Collaborative OPAI-IJO Study on Mucormycosis in COVID-19 (COSMIC) Study Group. Epidemiology, clinical profile, management, and outcome of COVID-19-associated rhino-orbital-cerebral mucormycosis in 2826 patients in India - Collaborative OPAI-IJO Study on Mucormycosis in COVID-19 (COSMIC), Report 1. *Indian J Ophthalmol* 2021;69(07):1670-1692
- Sarkar S, Gokhale T, Choudhury SS, Deb AK. COVID-19 and orbital mucormycosis. *Indian J Ophthalmol* 2021;69(04):1002-1004
- Singh AK, Singh R, Joshi SR, Misra A. Mucormycosis in COVID-19: A systematic review of cases reported worldwide and in India. *Diabetes Metab Syndr* 2021;15(04):102146
- Garg D, Muthu V, Sehgal IS, et al. Coronavirus disease (Covid-19) associated mucormycosis (CAM): case report and systematic review of literature. *Mycopathologia* 2021;186(02):289-298
- Arora R, Goel R, Khanam S, et al. Rhino-orbital-cerebral-mucormycosis during the COVID-19 second wave in 2021 - a preliminary report from a single hospital. *Clin Ophthalmol* 2021;15:3505-3514
- Gelston CD, Durairaj VD, Simoes EA. Rhino-orbital mucormycosis causing cavernous sinus and internal carotid thrombosis treated with posaconazole. *Arch Ophthalmol* 2007;125(06):848-849
- Honavar SG. Code Mucor: guidelines for the diagnosis, staging and management of rhino-orbital-cerebral mucormycosis in the setting of COVID-19. *Indian J Ophthalmol* 2021;69(06):1361-1365
- Cornely OA, Alastruey-Izquierdo A, Arenz D, et al; Mucormycosis ECMM MSG Global Guideline Writing Group. Global guideline for the diagnosis and management of mucormycosis: an initiative of the European Confederation of Medical Mycology in cooperation with the Mycoses Study Group Education and Research Consortium. *Lancet Infect Dis* 2019;19(12):e405-e421
- Sipsas NV, Gamaletsou MN, Anastasopoulou A, Kontoyiannis DP. Therapy of mucormycosis. *J Fungi (Basel)* 2018;4(03):90. Doi: 10.3390/jof4030090
- De Pauw B, Walsh TJ, Donnelly JP, et al; European Organization for Research and Treatment of Cancer/Invasive Fungal Infections Cooperative Group National Institute of Allergy and Infectious Diseases Mycoses Study Group (EORTC/MSG) Consensus Group. Revised definitions of invasive fungal disease from the European Organization for Research and Treatment of Cancer/Invasive Fungal Infections Cooperative Group and the National Institute of Allergy and Infectious Diseases Mycoses Study Group (-EORTC/MSG) Consensus Group. *Clin Infect Dis* 2008;46(12):1813-1821
- Matoba M, Tonami H, Kuginuki M, Yamamoto I, Takashima S. Intermittent hepatic artery antibiotic infusion therapy for pyogenic hepatic abscess. *Acta Radiol* 2004;45(01):13-17
- Chujo T, Kuratsune H, Nishimori Y, et al. [Mycotic liver and spleen abscesses successfully treated by intraportal and intrahepato-splenic arterial administration of antimycotic drugs in two cases with acute leukemia]. *Rinsho Ketsueki* 1989;30(05):736-745 Japanese.
- Miyata A, Honda K, Fujita M, Kikuchi T. [Multiple candida liver abscesses successfully treated by continuous intrahepatic arterial infusion of amphotericin B using a reservoir in a case with acute myelocytic leukemia (M2)]. *Rinsho Ketsueki* 1995;36(10):1217-1222
- Chooklin S, Hranat O, Usach O. Prophylactic of infected pancreatic necrosis by intra-arterial infusion. *HPB (Oxford)* 2016;18(02):e817
- Suzuki A, Ohtani T, Otani E. [Two cases of intra-arterial infusion of antibiotics in intractable chronic osteomyelitis of the mandible]. *Aichi Gakuin Daigaku Shigakkaishi* 1989;27(04):1071-1079
- Hugeneck J, Gottlob R. [The intra-arterial infusion. II. Its use in the treatment of septic gangrene]. *Wien Med Wochenschr* 1982;132(21):523-526

- 17 Mansueto P, Rizzo M, Affronti M, et al. Safe and successful endoarterial infusion of liposomal amphotericin B in treatment of mucormycosis. *New Microbiol* 2003;26(04): 395–398
- 18 Lentino JR, Pachucki CT, Ramamurthy S, Turner J. Local Arterial Infusion of Amphotericin B for Refractory Aspergillosis. 2002. Accessed September 21, 2022, at: https://www.medscape.com/viewarticle/439192_2
- 19 Yadav S, Rawal G. Mucormycosis in COVID-19- a burgeoning epidemic in the ongoing pandemic. *IP Ind J Immunol Respir Med* 2021;6(02):67–70
- 20 Handzel O, Landau Z, Halperin D. Liposomal amphotericin B treatment for rhinocerebral mucormycosis: how much is enough? *Rhinology* 2003;41(03):184–186
- 21 Stone NR, Bicanic T, Salim R, Hope W. Liposomal amphotericin B (AmBisome®): a review of the pharmacokinetics, pharmacodynamics, clinical experience and future directions. *Drugs* 2016;76(04):485–500
- 22 Sundar S, Jha TK, Thakur CP, Mishra M, Singh VP, Buffels R. Single-dose liposomal amphotericin B in the treatment of visceral leishmaniasis in India: a multicenter study. *Clin Infect Dis* 2003;37(06):800–804