



# Histoplasmosis of Adrenal Gland: A 5 Years' Review from a Multispecialty Diagnostic Centre

Kumkum Bhattacharyya<sup>1,2</sup> Suranjan Pal<sup>3</sup> Ashis Dutta<sup>4</sup> Pinak Pani Bhattachryya<sup>5</sup> Saurabh Laskar<sup>1</sup>

<sup>1</sup>Department of Microbiology, Quadra Medical Services, Kolkata, West Bengal, India

<sup>2</sup>Department of Microbiology, Institute of Post Graduate Medical Education & Research, Kolkata, West Bengal, India

<sup>3</sup>Department of Microbiology, Raiganj Government Medical College, Raiganj, Uttar Dinajpur, West Bengal, India

<sup>4</sup>Department of Pathology, Quadra Medical Services, Kolkata, West Bengal, India

Address for correspondence Suranjan Pal, MD, DNB, Department of Microbiology, Raiganj Government Medical College, 31/F Chowdhury Para Bye Lane, P. O. Chatra, Serampore, Hooghly, 712204, West Bengal, India (e-mail: suranjanbabla@gmail.com).

<sup>5</sup>Department of Radiology, Quadra Medical Services, Kolkata, West Bengal, India

J Lab Physicians 2023;15:243–252.

## Abstract

**Objective** Histoplasmosis is an infectious disease caused by the dimorphic fungus *Histoplasma capsulatum*. Histoplasmosis is considered to be endemic to India, especially the Gangetic belt. Disseminated histoplasmosis may affect almost all systems. Disseminated histoplasmosis with asymptomatic adrenal involvement has been described in immunocompromised patients, whereas isolated adrenal involvement as the presenting manifestation in immunocompetent is uncommon. We aimed to determine the clinicopathological and radiological findings of adrenal histoplasmosis in immunocompetent patients attending a multispecialty diagnostic center referred from different clinics and hospitals.

**Materials and Methods** All tissue samples were initially examined microscopically by performing potassium hydroxide (KOH) wet mounts, followed by culture on two tubes of Sabouraud dextrose agar and phase conversion. Histopathological correlation was done using tissue stains, hematoxylin and eosin, periodic acid–Schiff, and Gomori methenamine silver.

**Results** We evaluated 84 clinically suspected cases radiologically for adrenal mass. The pathological and microbiological work-up was done from these suspected cases. A total of 19 cases were evident from the tissue stain and fungal culture methods. The affected population were mostly above 45 years and male. Seven patients had bilateral adrenal involvement. All these patients received amphotericin B and/or itraconazole treatment, which led to symptomatic improvement in most cases.

**Conclusion** Diagnosis of invasive fungal infection requires a high index of suspicion, especially in immunocompetent patients presenting with nonspecific symptoms, clinical signs, and laboratory and radiological features that often resemble adrenal neoplasms. Clinical specimens, together with fungal culture, must be sent for cytopathology/histopathology for a definite diagnosis and appropriate management.

## Keywords

- ▶ histoplasmosis
- ▶ mycosis
- ▶ adrenal gland

article published online  
October 20, 2022

DOI <https://doi.org/10.1055/s-0042-1757587>.  
ISSN 0974-2727.

© 2022. The Indian Association of Laboratory Physicians. All rights reserved.

This is an open access article published by Thieme under the terms of the Creative Commons Attribution-NonDerivative-NonCommercial-License, permitting copying and reproduction so long as the original work is given appropriate credit. Contents may not be used for commercial purposes, or adapted, remixed, transformed or built upon. (<https://creativecommons.org/licenses/by-nc-nd/4.0/>)

Thieme Medical and Scientific Publishers Pvt. Ltd., A-12, 2nd Floor, Sector 2, Noida-201301 UP, India

## Introduction

Histoplasmosis is a fatal granulomatous disease affecting people worldwide caused by a thermally dimorphic fungus *Histoplasma capsulatum*. Samuel Darling in 1905–1906 first reported histoplasmosis in a patient from Martinique.<sup>1</sup> Histoplasmosis poses a difficult diagnostic challenge because of its highly variable clinical manifestations. *Histoplasma* is primarily a pulmonary pathogen; infections are often asymptomatic or present as a self-limiting influenza-like illness. In some instances, especially in immunosuppressed patients, the fungi multiply intracellularly and disseminates via lymphatic and hematogenous routes, resulting in disseminated histoplasmosis, which mimics metastasis.<sup>2,3</sup> Disseminated histoplasmosis occurs largely in immunocompromised patients, but there have been cases reported in the literature in immunocompetent individuals as well.<sup>3–5</sup> Disseminated form affect almost all systems, including the bone marrow, lungs, reticuloendothelial system, central nervous system, gastrointestinal tract, renal tract, and adrenal glands.<sup>6</sup> Adrenal gland involvement by *Histoplasma* may occur during the active dissemination or may evolve years after the disease become inactive. The adrenal gland is one of the most commonly involved sites in disseminated histoplasmosis.<sup>5,7</sup> The trend of reporting histoplasmosis cases has notably increased in the past 2 years, which might be caused by increased awareness among clinicians to diagnose histoplasmosis.<sup>8</sup> The increase in Indian diabetic population might be a contributory factor in the increased fatality of adrenal histoplasmosis. However, whether this increase is caused by a real increased in the number of patients infected by *Histoplasma* in India is a matter of thorough research.<sup>9</sup> Therefore, we undertook this study to establish tissue diagnosis in clinico-radiologically suspected adrenal histoplasmosis patients attending a multispecialty diagnostic facility referred from different clinics and hospitals.

## Materials and Methods

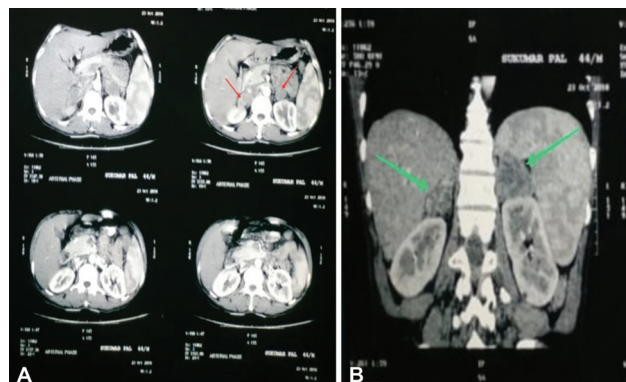
In this retrospective, diagnostic facility-based study, we analyzed the clinical presentations and prognosis of 84 consecutive patients with clinico-radiological suspicion of adrenal histoplasmosis who were referred to our facility in Kolkata, India, over a period of 5 years (November 2015 to November 2020). The cases from different facility were referred to us, and most of them had low-grade fever, night sweats, weight loss, and heaviness in the abdomen. The study was approved by the Institutional Ethics Committee. Waiver of patient consent was granted by the Institutional Ethics Committee because of the fully retrospective nature of the study.<sup>10</sup> Information was entered using a pro forma being routinely followed in the facility. Data were retrieved from case records as well as the laboratory electronic database. The occupation, residence, clinical features suggesting infection (weight loss, fever), treatment details, and the response to antifungal therapy were noted. Patients having human immunodeficiency virus/acquired immunodeficiency syndrome (HIV/AIDS) or malignancy were excluded from this study. The patients underwent detailed investigations in-

cluding a complete hemogram and biochemical evaluation, chest radiology, abdominal ultrasonography, and blood and urine cultures for aerobic and anaerobic organisms. An abdominal computed tomography (CT) scan with contrast was performed in each case. All clinically suspected patients were evaluated radiologically by abdominal CT scan and/or ultrasonography, and 23 cases of bilateral and/or unilateral adrenal mass were found. These 23 patients with radiologically detected unilateral or bilateral adrenal mass underwent a CT- or ultrasonography-guided fine needle aspiration ( $n=8$ ) or biopsy ( $n=15$ ) of the enlarged adrenal glands. From all these 23 cases, tissue samples/fine needle aspiration samples were taken and samples were initially examined microscopically by performing 20% potassium hydroxide (KOH) wet mounts, followed by putting culture on two tubes of Sabouraud dextrose agar (HiMedia Laboratories, India) kept at 25 °C and 37 °C for 4 to 6 weeks and transfer into phase conversion medium (brain–heart infusion, glutamine, and sheep blood agar; HiMedia Laboratories, India).<sup>2</sup> Histopathological correlation were done using tissue stains such as hematoxylin and eosin, Gomori methenamine silver (GMS) (PathnSitu Biotechnologies, United States), and periodic acid–Schiff (PAS) stain (ScyTek Laboratories, United States). Adrenal specimens were also stained using the Ziehl–Neelsen method of acid-fast stain. Other tests such as urinary metanephrine, normetanephrine, adrenocorticotrophic hormone, paired cortisol, sputum cartridge-based nucleic acid amplification test (CBNAAT), high-resolution computed tomography scans of the thorax were done to exclude the differential diagnosis of adrenal incidentaloma.

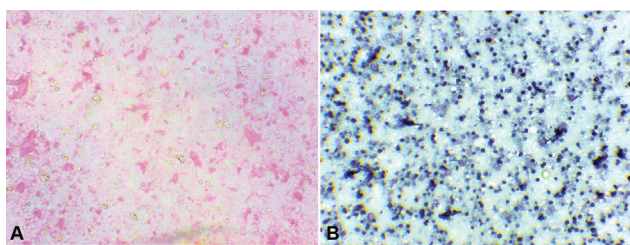
## Results

We describe the clinically suspected and radiologically detected cases of adrenal histoplasmosis from our diagnostic facility from November 2015 to November 2020 (–Fig. 1A, B).

The total number of clinically suspected cases was 84, of which there were 23 clinico-radiologically suspected cases of adrenal histoplasmosis. Of these, only 19 cases could be confirmed by histopathology and culture. The study population were adult, and 17 patients (73.9%) were male with the



**Fig. 1** (A, B) CT scan of the abdomen showed bilateral adrenal enlargement.

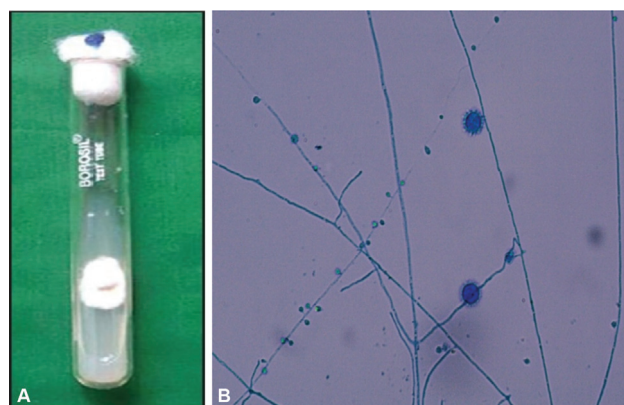


**Fig. 2** Cytology smears. (A) Multiple capsulated *Histoplasma* in histiocytic cells (periodic acid–Schiff;  $\times 100$ ). (B) *Histoplasma* yeasts with Gomori methenamine silver (GMS) positivity (GMS;  $\times 400$ ).

mean age of presentation of 54.25 years (range, 36–74 years). All patients were HIV nonreactive and had no history of other congenital syndromes or AIDS. Important suggestive occupational exposures in these patients were taken; notably, none of them had a history of agriculture-related work or exposure to birds. Nine patients had type 2 diabetes mellitus and were on oral hypoglycemic agents. Seven patients had bilateral adrenal involvement. None of the patients on biochemical evaluation showed adrenal insufficiency. No hepatosplenomegaly or lymphadenopathy was noted in any of the patients. On further cytopathology/histopathology and microbiological work-up, different stains and culture confirmed 19 cases of histoplasmosis out of 23 clinico-radiologically suspected case. Three patients had been diagnosed with tuberculosis by CBNAAT, one patient were diagnosed to have rhodotorulosis in culture. Eight cases were diagnosed using CT-guided fine needle aspiration cytology (FNAC) and the rest using histopathological examination of adrenals. FNAC smears showed scattered adrenal epithelial elements and a dense amorphous background with scattered lipid globules, debris, areas of dense necrosis, and mixed population of numerous inflammatory cells with round-to-oval yeast-like organisms, few of which show budding. The Ziehl–Neelsen stain showed no acid-fast bacilli. On PAS and GMS, numerous yeasts-like fungal organism with uneven budding were evident morphologically resembling *Histoplasma* species ( $\rightarrow$ Fig. 2A, B). Histopathology of adrenal gland revealed mostly necrotic, degenerated cells, polymorphonuclear cells (PMN), and nuclear fragments. Large aggregates of epithelioid histiocytes admixed with endothelial cells, epithelioid cell granulomas, and occasional multinucleate giant cells are present. Many of the histiocytes showed yeast form of 2 to 4  $\mu\text{m}$  in size with a perinuclear halo resembling *Histoplasma* spp. The fungal cultures were put and all of them showed growth of mold form of *H. capsulatum* with successful yeast conversion in vitro ( $\rightarrow$ Fig. 3). Fungal agents itraconazole and/or amphotericin B were administered in 18 of 19 cases and led to clinical improvement. The cases are summarized in  $\rightarrow$ Table 1.

## Discussion

In India, histoplasmosis seems to be prevalent in the soil of the Gangetic delta.<sup>11</sup> Panja and Sen reported the first case of disseminated histoplasmosis from Calcutta in 1954.<sup>12</sup> Since then, individual cases have been reported from various



**Fig. 3** (A) Mycelial colonies of *H. capsulatum* showing white aerial hyphae at 25°C. (B) Macroconidia (tuberculate) and microconidia from mycelial growth of *H. capsulatum* (lactophenol cotton blue [LCB];  $\times 400$ ).

states, mostly from West Bengal.<sup>13</sup> Adrenal infections are commonly caused by hematological dissemination. The adrenals are also a frequent site of metastasis. The differential diagnoses of bilateral adrenal enlargement are metastasis, lymphoma, adrenal hemorrhage, sarcoidosis, and infections, which include tuberculosis, histoplasmosis, cryptococcosis, blastomycosis, and coccidioidomycosis.<sup>14,15</sup> However, central hypodensity and peripheral rim enhancement of the adrenals are common only to tuberculosis and histoplasmosis.<sup>6,16</sup> *Mycobacterium tuberculosis* is the most common pathogen causing adrenal infection. *Histoplasma* spp. are the commonest fungi involving the adrenals. Other fungi that can affect the adrenals are *Blastomyces*, *Coccidioides*, *Paracoccidioides*, *Cryptococcus*, and *Candida*. The range of adrenal involvement by histoplasmosis is varied as follows: (1) mildest form characterized by isolated cortical foci of parasitized macrophages, (2) extensive caseous necrosis with enlargement of bilateral adrenals, (3) extensive infarction, (4) granulomatous replacement of adrenals, and (5) calcified mass lesion that may mimic tubercular or metastatic lesions.<sup>3,4,6</sup> Asymptomatic adrenal involvement has been described in 30 to 50% of patients with disseminated histoplasmosis and henceforth a meticulous work-up with close follow-up is necessary as there is no clinical diagnostic hallmark of the disease; often, they mimic visceral leishmaniasis, which is prevalent in this part of India, and the diagnosis is often missed.<sup>17–19</sup> Increased steroid concentration within the adrenal glands may promote the growth of *H. capsulatum*, as suggested by some researchers.<sup>20</sup>

The histoplasmosis cases from India are based on the study by Randhawa and Gugnani who found a total of 426 cases (1954–2018) and 207 cases from the literature search (2018–2020; excluding studies cited in Randhawa and Gugnani).<sup>6,8</sup> The progressive disseminated form of the disease is rare and occurs mainly in immunocompromised patients. Being a primary pathogen, the etiologic agent, *H. capsulatum* var. *capsulatum* also infects immunocompetent patients in the Indian subcontinent. The histoplasmosis cases during the past 3 years in India were dominated by

**Table 1** Profile of cases of adrenal histoplasmosis

No.	Age/sex	Predisposing condition(s)	Clinical presentation	Imaging results abdominal CT	HPE and culture	Outcome and sequel
1	55/M	DM	FUO/4 mo	Homogeneous, hypodense, right adrenal enlarged in size. Right adrenal SOL: ?fungal infection	H&E: extensive necrosis and degenerated material GMS: numerous spherical and noncapsulated budding fungal spores Fungal culture: showed growth of mycelial colonies of <i>H. capsulatum</i> at 25°C	Clinical improvement following oral itraconazole
2	49/M	DM	Anorexia + generalized weakness + splenomegaly/6 mo	Right adrenal is enlarged in size and mass-like appearance, heterogeneous enhancement, and nonenhancing necrotic areas	H&E: discrete single minute rounded yeast-like organism in a necrotic background PAS: plenty of yeast-like cells morphologically resembling yeast of <i>Histoplasma</i> spp. Fungal culture: showed growth of mycelial colonies of <i>H. capsulatum</i> at 25°C	Adrenal mass decreased with IV amphotericin B; now on oral itraconazole
3	66/M	DM	FUO + progressive weight loss + anorexia/4 mo	Approximately 43 × 28 × 38 mm sized well-defined, smooth margined, heterogeneously hypodense, mildly enhancing lesion in left adrenal gland	H&E: predominantly hemorrhagic comprising histiocytes containing yeast-like organism showing budding at times PAS and GMS: yeast-like organism without any capsules	Patient discharged on oral itraconazole after initial IV amphotericin B
4	37/M	NIL	Fatigue and hyperpigmentation/4 mo	Left adrenal is enlarged in size and mass-like appearance, heterogeneous enhancement, and nonenhancing necrotic areas	Minute rounded single budding organisms revealed by GMS in a necrotic background	Symptoms resolved and discharged with oral itraconazole
5	60/F	Pulmonary tuberculosis	Chronic lung disease/1 y	Homogeneous, hypodense, left adrenal enlarged in size. Left adrenal SOL: ?fungal infection	Predominantly necro-inflammatory comprising many discrete minute rounded organisms, some of which have single budding, revealed by PAS and GMS Fungal culture: showed growth of mycelial colonies of <i>H. capsulatum</i> at 25°C	IV amphotericin B, oral itraconazole, patient recovered
6	66/M	CRF	Fever + skinpigmentation + weightloss/1 mo	Homogeneous, hypodense, right adrenal enlarged in size. Right adrenal SOL	Predominantly necrotic comprising minute, rounded single organism strongly stained by GMS Fungal culture: showed growth of mycelial colonies of <i>H. capsulatum</i> at 25°C	Symptoms resolved and discharged with oral itraconazole

Table 1 (Continued)

No.	Age/sex	Predisposing condition(s)	Clinical presentation	Imaging results abdominal CT	HPE and culture	Outcome and sequel
7	57/M	DM	Pain in abdomen/3 mo	Left suprarenal heterogeneous enhancing mass	Mostly necrosis, degenerated cells, PMN, and nuclear fragments. Large aggregates of epithelioid histiocytes admixed with endothelial cells, epithelioid cell granulomas, occasional giant cells Fungal culture: showed growth of mycelial colonies of <i>H. capsulatum</i> at 25°C	Symptoms resolved and discharged with oral itraconazole
8	70/M	COPD	Fever, progressive weight loss, anorexia/1 mo	Homogeneous, hypodense, both adrenals enlarged in size	Predominantly necro-inflammatory PAS and GMS: round-to-oval yeast-like organisms, few of which show budding Fungal culture: showed growth of mycelial colonies of <i>H. capsulatum</i> at 25°C	Symptoms resolved and discharged with oral itraconazole
9	45/M	Nil	FUO + chest discomfort + fatigue/3 mo	Homogeneous, hypodense, both adrenals enlarged in size	Paucicellular smear show few clusters of adrenal cortical cells with mild anisonucleosis and numerous yeast forms of fungus morphologically resembling <i>Histoplasma</i> , few of them show budding Yeast cells: suggestive of histoplasmosis Fungal culture: showed growth of mycelial colonies of <i>H. capsulatum</i> at 25°C	Symptoms resolved and discharged with oral itraconazole
10	67/M	DM	Pain and heaviness in lower abdomen with anorexia/4 mo	Homogeneous, hypodense, both adrenals enlarged in size	Extensive areas of necrosis surrounded by palisades of histiocytic cells with focal areas showing epithelioid morphology with giant cell granuloma, plenty of yeasts of <i>Histoplasma</i> Fungal culture: showed growth of mycelial colonies of <i>H. capsulatum</i> at 25°C	Adrenal mass decreased with IV amphotericin B, now on oral itraconazole
11	74/M	DM	Pain in abdomen, weight loss/3 mo	Enlarged bilateral adrenals with heterogeneous enhancement and central attenuation with septations	Extensive areas of necrosis surrounded by histiocytic cells with focal areas showing epithelioid morphology with giant cell granuloma. Many of the histiocytic cells showed yeast forms	Symptoms resolved and discharged with oral itraconazole

(Continued)

Table 1 (Continued)

No.	Age/sex	Predisposing condition(s)	Clinical presentation	Imaging results abdominal CT	HPE and culture	Outcome and sequel
12	57/M	DM	Anorexia, weight loss/6 mo	Enlarged bilateral adrenals with heterogeneous enhancement and central attenuation with septations	conforming closely to the morphology of <i>Histoplasma</i> Fungal culture: showed growth of mycelial colonies of <i>H. capsulatum</i> at 25°C  Extensive areas of necrosis surrounded by histiocytic cells with focal areas showing epithelioid morphology with giant cell granuloma. Many of the histiocytic cells showed yeast forms conforming closely to <i>Histoplasma</i> . Fungal culture: showed growth of mycelial colonies of <i>H. capsulatum</i> at 25°C	Symptoms resolved and discharged with oral itraconazole
13	55/F	DM	Intermittent fever, weight loss, pain in abdomen, hyperpigmentation/2 mo	Homogeneous, hypodense, both adrenals enlarged in size	Extensive areas of necrosis surrounded by histiocytic cells with focal areas showing epithelioid morphology with giant cell granuloma. Many of the histiocytic cells showed yeast forms similar to the morphology of <i>Histoplasma</i> . Fungal culture: showed growth of mycelial colonies of <i>H. capsulatum</i> at 25°C	Symptoms resolved and discharged with oral itraconazole
14	63/M	DM	Intermittent fever, pain in abdomen, anorexia, hyperpigmentation/1 mo	Enlarged bilateral adrenals with heterogeneous enhancement and central attenuation with septations	Extensive areas of necrosis surrounded by layer of histiocytic cells with focal areas showing epithelioid morphology with giant cell granuloma. Many of the histiocytic cells showed yeast forms conforming closely to <i>Histoplasma</i> . Fungal culture: showed growth of mycelial colonies of <i>H. capsulatum</i> at 25°C	Symptoms resolved and discharged with oral itraconazole
15	50/F	NIL	Skin hyperpigmentation/1 mo	Homogeneous, hypodense, both adrenals enlarged in size	Extensive areas of necrosis surrounded by palisades of histiocytic cells with focal areas showing epithelioid morphology with giant cell granuloma. Many of the histiocytic cells showed yeast	Symptoms resolved and f/u adrenal mass decreased

Table 1 (Continued)

No.	Age/sex	Predisposing condition(s)	Clinical presentation	Imaging results abdominal CT	HPE and culture	Outcome and sequel
16	44/M	NIL	Weight loss, pain in abdomen, intermittent cough/1 y	Enlarged bilateral adrenals with heterogeneous enhancement and central attenuation with septations	forms of <i>Histoplasma</i> Fungal culture: showed growth of mycelial colonies of <i>H. capsulatum</i> at 25°C  Extensive areas of necrosis surrounded by palisades of histiocytic cells with focal areas showing epithelioid morphology with giant cell granuloma. Many of the histiocytic cells showed yeast forms conforming closely to the morphology of <i>Histoplasma</i> Fungal culture: showed growth of mycelial colonies of <i>H. capsulatum</i> at 25°C	Symptoms resolved and f/u adrenal mass decreased
17	72/M	NIL	Pain in abdomen, weight loss/3 mo	Enlarged bilateral adrenals with heterogeneous enhancement and central attenuation	Extensive necrosis surrounded by palisades of histiocytic cells with focal areas showing epithelioid morphology with giant cell granuloma. Many of the histiocytic cells showed yeast forms conforming closely to the morphology of <i>Histoplasma</i> Fungal culture: showed growth of mycelial colonies of <i>H. capsulatum</i> at 25°C	Symptoms resolved and f/u adrenal mass decreased
18	51/M	NIL	Intermittent fever, pain in abdomen, anorexia, hyperpigmentation/8 mo	Enlarged bilateral adrenals with heterogeneous enhancement and central attenuation	Necrosis surrounded by palisades of histiocytic cells with focal areas showing epithelioid morphology with giant cell granuloma. Many of the histiocytic cells showed yeast forms conforming closely to the morphology of <i>Histoplasma</i> Fungal culture: showed growth of mycelial colonies of <i>H. capsulatum</i> at 25°C	Symptoms resolved and f/u adrenal mass decreased
19	40/F	NIL	Pain in abdomen, fever, weight loss, anemia/1 mo	Bilateral thickening of adrenal glands, hypodense centrally with peripherally enhancing margins	Adrenal histopathology revealed extensive necrosis surrounded by palisades of histiocytic cells with focal areas showing epithelioid morphology with giant cell	Patient died before diagnosis

(Continued)

Table 1 (Continued)

No.	Age/sex	Predisposing condition(s)	Clinical presentation	Imaging results abdominal CT	HPE and culture	Outcome and sequel
					granuloma. Many of the histiocytic cells showed yeast forms con-forming closely to the morphology of <i>Histoplasma</i> Fungal culture: Showed growth of <i>H. capsulatum</i> at 25°C	

Abbreviations: COPD, chronic obstructive pulmonary disease; CRF, chronic renal failure; CT, computed tomography; DM, diabetes mellitus; f/u, follow-up; F.UO, fever of unknown origin; GMS, Gomori methenamine silver; H&E, hematoxylin and eosin; IV, intravenous; PMN, polymorphonuclear cells; PAS, periodic acid-Schiff; SOL, space occupying lesion.

HIV-negative patients based on a literature search. This is in contrast with the period before 2018 that indicated HIV as the common comorbidity among histoplasmosis in India.<sup>21-23</sup> We excluded HIV-reactive case from this study to estimate clinic-based case burden in otherwise immunocompetent patients, reflecting a snapshot of histoplasmosis case burden in an otherwise immunocompetent population of the community.

Diabetes mellitus is emerging as a major risk factor associated with histoplasmosis. Immunologic studies have demonstrated phagocytic capabilities of polymorphonuclear leukocytes (PMN) in diabetics are affected by the hyperglycemic state as demonstrated in rat models. The defects include impaired migration, intracellular cellular killing, and chemotaxis, which are thought to be due to decreased membrane fluidity, which predisposes the patients to the risk of intracellular pathogens such as *Histoplasma*.<sup>24,25</sup> Diabetic population in India increased from 40.9 million people in 2007 to 77 million people in 2019.<sup>6,25</sup> The growing population of diabetes might contribute to the findings of diabetes as a risk factor as well as a common predisposing factor in the mortality of adrenal histoplasmosis. We found adrenal histoplasmosis in the adult population and most of them were male. We also found that among the predisposing conditions, type 2 diabetes mellitus was the commonest (39.13%), unlike case reports from the Americas where type 1 diabetes mellitus was associated with disseminated histoplasmosis.<sup>26</sup> In India, there are only a few case reports of adrenal histoplasmosis in diabetic patients; sometimes, they directly present with the fatal complications of diabetes mellitus such as diabetic ketoacidosis.<sup>27,28</sup> There are isolated case reports of type 1 diabetes mellitus and disseminated histoplasmosis.<sup>2,4-7</sup> Symmers described a distinct clinical syndrome "Asian histoplasmosis" with two salient features, namely mucosal ulceration at mucocutaneous junctions or body orifices and a propensity to acute adrenocortical insufficiency.<sup>29</sup> The average duration of symptoms to diagnosis was around 4 months (range, 1 month to 1 year). The diagnoses are often delayed as the presenting symptoms were mostly nonspecific such as pain and heaviness in the abdomen with weight loss and low-grade fever. Unlike other Indian studies, we could not find hepatosplenomegaly associated with the cases; it might be due to a selection bias as it is a diagnostic clinic-based study. Also, most of our cases of adrenal histoplasmosis started with incidental diagnostic clue from radiological tests. Normally, adrenal histoplasmosis subsides with antifungal therapy not demanding surgical excision. Following radiological and microbiological diagnoses, all 18 cases recovered; only 1 patient died before diagnosis as the presentation was almost 1 year after the symptom onset. Interestingly, however, the adrenals are not part of the reticuloendothelial system but their predilection for histoplasmosis is getting common in India.<sup>18,30</sup> We would like to suggest that there might be some new intermediate steroid-synthesis ingredient serving as a better nutrient for these fungi or this adrenal favoring *Histoplasma* might be of different genetic composition.<sup>31</sup> As we found in our small study and also supported by other studies, there may be the



least association of soil as the patients had no exposure to soil or excavation. As proposed by Gupta et al, it is likely that the soil in India is not supportive of its growth and the fungus may be present only in the low inoculum. The environmental niche of the fungus and the burden of infection in the community need to be further explored as most of the cases are reported from the Gangetic basins.<sup>32</sup> A further detailed study would be apt to find the answers. A limitation of this study was that, as the setting was a private diagnostic facility, the multiple diagnostic modalities and treatment follow-up were very difficult. Accurate diagnosis is still challenging and limited in many countries where this disease is highly endemic like ours. The caseload presented was only the tip of the iceberg with the new geographical location being reported.<sup>6,33</sup> In this regard, *Histoplasma* antigen testing is now included in the WHO essential diagnostics list.<sup>34</sup> As proposed by Banerjee et al, a program for establishing the rates of histoplasmin skin sensitivity in India should be undertaken to understand the exposure rate of the population wherever cases have been documented and prioritize local diagnostic testing.<sup>35</sup>

We can conclude that histoplasmosis of the adrenal gland is not uncommon even in immunocompetent patients and has to be considered in the differential diagnosis of unilateral/bilateral adrenal enlargement. The diagnosis of invasive fungal infection is critical and requires a high index of suspicion, especially in immunocompetent patients who have presented with nonspecific symptoms, clinical signs, and laboratory and radiological features resembling adrenal mass. Clinical specimens should always be sent for mycological evaluation for a definite diagnosis and appropriate management. Also, a highly sensitive and specific diagnostic test is the need of the hour.

#### Authors' Contributions

P.P.B. contributed to the concept and design; A.D., K.B., S.L., and P.P.B. contributed to data collection and processing; A.D., K.B., S.L., and S.P. contributed to analysis and interpretation; S.P. and K.B. contributed to drafting the manuscript; K.B. and S.P. contributed to the manuscript's critical review.

#### Funding

None.

#### Conflict of Interest

None declared.

#### Acknowledgments

We thank the Department of Endocrinology, IPGME&R, Kolkata.

#### References

- Darling ST. The morphology of the parasite (*Histoplasma capsulatum*) and the lesions of histoplasmosis, a fatal disease of tropical America. *J Exp Med* 1909;11(04):515–531
- Chander J. *Textbook of Medical Mycology*. 4th ed. New Delhi: JP Medical Ltd; 2018
- Gajendra S, Sharma R, Goel S, et al. Adrenal histoplasmosis in immunocompetent patients presenting as adrenal insufficiency. *Turk Patoloji Derg* 2016;32(02):105–111
- Kathuria S, Capoor MR, Yadav S, Singh A, Ramesh V. Disseminated histoplasmosis in an apparently immunocompetent individual from north India: a case report and review. *Med Mycol* 2013;51(07):774–778
- Sharma N, Adhikari RC. Adrenal involvement in histoplasmosis. *J Pathol Nepal* 2019;9:1502–1504
- Rozaliyani A, Setianingrum F. The review of histoplasmosis endemicity and current status in Asia. In: Bongomin F, ed. *Histoplasma and Histoplasmosis*. IntechOpen; 2020 Available at: <https://www.intechopen.com/chapters/7218992448>
- Goswami RP, Pramanik N, Banerjee D, Raza MM, Guha SK, Maiti PK. Histoplasmosis in eastern India: the tip of the iceberg? *Trans R Soc Trop Med Hyg* 1999;93(05):540–542
- Randhawa HS, Gugnani HC. Occurrence of histoplasmosis in the Indian subcontinent: an overview and update. *J Med Res Pract* 2018;7(03):71–83
- Gopalakrishnan R, Nambi PS, Ramasubramanian V, Abdul Ghafur K, Parameswaran A. Histoplasmosis in India: truly uncommon or uncommonly recognised? *J Assoc Physicians India* 2012; 60:25–28
- Singh M, Chandy DD, Bharani T, et al. Clinical outcomes and cortical reserve in adrenal histoplasmosis—a retrospective follow-up study of 40 patients. *Clin Endocrinol (Oxf)* 2019;90(04): 534–541
- Sanyal M, Thammayya A. *Histoplasma capsulatum* in the soil of Gangetic plain in India. *Indian J Med Res* 1975;63(07):1020–1028
- Panja G, Sen S. A unique case of histoplasmosis. *J Indian Med Assoc* 1954;23(06):257–258
- Dhar S, Roy RK, Todi SK, Roy S, Dhar S. Seven cases of histoplasmosis: cutaneous and extracutaneous involvements. *Indian J Dermatol* 2006;51(02):137–139
- Deepe JS Jr. *Histoplasma capsulatum*. In: Bennet JE, Dolin R, Blaser MJ, eds. *Principles and Practice of Infectious Diseases*. 8th ed. Philadelphia, PA: Elsevier/Saunders; 2015:2949–2962
- Schonfeld AD, Jackson JA, Smith DJ, Hurley DL. Disseminated histoplasmosis with bilateral adrenal enlargement: diagnosis by computed tomography-directed needle biopsy. *Tex Med* 1991;87(04):88–90
- Mehra R, Singh GN, Agrawal P. Adrenal histoplasmosis: clinical, imaging and correlation. *Indian J Res* 2017;6:48–49
- Kumar N, Singh S, Govil S. Adrenal histoplasmosis: clinical presentation and imaging features in nine cases. *Abdom Imaging* 2003;28(05):703–708
- Mandal SK, Mani S, Sau D, Bhattacharjee K, Mandal SS, Bhattachary S. Bilateral adrenal histoplasmosis in an immunocompetent patient. *J Assoc Physicians India* 2012;60:47
- Bhari N, Pahadiya P, Arava S, Gupta S. Histoplasmosis mimicking non-Hodgkin lymphoma in a 40-year-old man with AIDS. *Int J STD AIDS* 2017;28(03):312–314
- Angeli A, Masera RG, Gatti G. Mycoses and adrenocortical function. New pathogenetic aspects of adrenal hypofunction [in Italian]. *Recenti Prog Med* 1991;82(12):652–660
- Randhawa HS, Chowdhary A. Medical mycology in India (1957–2007): contributions by the VPCI Mycoses Group. *Indian J Chest Dis Allied Sci* 2008;50(01):19–32
- Samaddar A, Sharma A, Kumar Ph A, et al. Disseminated histoplasmosis in immunocompetent patients from an arid zone in Western India: a case series. *Med Mycol Case Rep* 2019; 25:49–52
- Subramanian S, Abraham OC, Rupali P, Zachariah A, Mathews MS, Mathai D. Disseminated histoplasmosis. *J Assoc Physicians India* 2005;53:185–189
- Diabetes in America. 2nd ed. Washington, DC: National Diabetes Data Group, National Institute of Diabetes and Digestive and Kidney Diseases, National Institute of Health; 1995

- 25 Williams R, Colagiuri S, Chan J, et al. IDF Diabetes Atlas. 9th ed. Brussels, Belgium: International Diabetes Federation; 2019
- 26 Butta H, Chatterjee S, Mendiratta L, et al. Bilateral adrenal histoplasmosis in a diabetic patient: a case report and review of cases in India. *Apollo Med* 2019;16:109–113. Accessed on September 23, 2022, at: <https://apollomedicine.org/text.asp?2019/16/2/109/260691>
- 27 Rana C, Krishnani N, Kumari N. Bilateral adrenal histoplasmosis in immunocompetent patients. *Diagn Cytopathol* 2011;39(04):294–296
- 28 Niknam N, Malhotra P, Kim A, Koenig S. Disseminated histoplasmosis presenting as diabetic keto-acidosis in an immunocompetent patient. *BMJ Case Rep* 2017;2017:bcr2016217915
- 29 Symmers WS. Histoplasmosis in southern and south-eastern Asia. A syndrome associated with a peculiar tissue form of histoplasma: a study of 48 cases. *Ann Soc Belg Med Trop* 1972;52(04):435–452
- 30 Larbcharoensub N, Boonsakan P, Aroonroch R, et al. Adrenal histoplasmosis: a case series and review of the literature. *South-east Asian J Trop Med Public Health* 2011;42(04):920–925
- 31 Teixeira MdeM, Patané JS, Taylor ML, et al. Worldwide phylogenetic distributions and population dynamics of the genus *Histoplasma*. *PLoS Negl Trop Dis* 2016;10(06):e0004732
- 32 Gupta A, Ghosh A, Singh G, Xess I. A twenty-first-century perspective of disseminated histoplasmosis in India: literature review and retrospective analysis of published and unpublished cases at a tertiary care hospital in north India. *Mycopathologia* 2017;182(11–12):1077–1093
- 33 Sharma B, Nehara HR, Bhavi VK, Maan P, Saran S. Adrenal histoplasmosis in immunocompetent individuals a case series from the north-western part of India, Rajasthan province: an emerging endemic focus. *Indian J Med Microbiol* 2020;38(3–4):485–488
- 34 Toscanini MA, Nusblat AD, Cuestas ML. Diagnosis of histoplasmosis: current status and perspectives. *Appl Microbiol Biotechnol* 2021;105(05):1837–1859
- 35 Banerjee S, Denning DW, Chakrabarti A. One health aspects & priority roadmap for fungal diseases : a mini-review. *Indian J Med Res* 2021;153(03):311–319