Article published online: 2022-12-15

A Case of Pseudoaneurysm of the Superficial Temporal Artery Causing a Massive Subcutaneous Hematoma after Craniotomy

Masaki Tatano[1] Seiya Hayashi[1] Masatoshi Yunoki[1] Michiari Umakoshi[1] Koji Hirashita[1] Kimihiro Yoshino[1]

[1] Department of Neurosurgery, Kagawa Rosai Hospital, Marugame, Kagaw, Japan

AJNS 2022;17:672–675.

Address for correspondence Masatoshi Yunoki, MD, PhD, Department of Neurosurgery, Kagawa Rosai Hospital, 3-3-1 Joto-cho, Marugame, Kagaw, 763-8502, Japan (e-mail: yunomasato@yahoo.co.jp).

Abstract

We present a case of a ruptured pseudoaneurysm of the superficial temporal artery (STA) after surgery for intracranial hemorrhage. To our knowledge, only three similar cases have been reported. A 47-year-old man underwent left frontal craniotomy for a left frontal subcortical hematoma. The left STA was not identified during the surgery, and no STA bleeding was observed. The postoperative course was uneventful for 20 days, until the patient experienced a left-side headache and noticed a subcutaneous mass. The mass increase in size within 1 hour and arterial hemorrhage was observed through a tear in the wound. Findings on subsequent contrast computed tomography were consistent with a ruptured pseudoaneurysm arising from the left STA. Emergency evacuation of the hematoma and STA ligation were performed. Pathological findings were consistent with a pseudoaneurysm. STA pseudoaneurysms occasionally grow rapidly and can cause massive hematoma. Surgeons should carefully monitor for evidence of a pseudoaneurysm after craniotomy, even in the absence of intraoperative bleeding from the STA.

Keywords
- craniotomy
- hematoma
- pseudoaneurysm
- superficial temporal artery

Introduction

A superficial temporal artery (STA) pseudoaneurysm after a craniotomy is rare, with only 16 cases reported in the literature—the majority of these were found in subcutaneous pulsatile and painless masses.[1–16] Herein, we report a case of an STA pseudoaneurysm with severe subcutaneous bleeding after craniotomy, and provide a review of the literature. To our knowledge, only three similar cases have been reported.[6,9,10]

Case History

A 47-year-old man with a history of hypertension was brought to the emergency department of our hospital due to sudden onset of headache, right hemiparesis, and consciousness disturbance (20 JCS: Japan Coma Scale).

On arrival, the head computed tomography (CT) scan showed a left subcortical hemorrhage (►**Fig. 1A**). Craniotomy was performed on the same day.

For the first surgery, a coronal skin incision was made, and a right frontal craniotomy was performed. A microscope was introduced to aid removal of the hematoma located directly below the craniotomy. For skin closure, a 3–0 absorbent thread (Vicryl plus 3.0; Ethicon Co., Somerville, New Jersey, USA) was used subcutaneously, while a stapler was used superficially. During the period from skin incision to closure, the left STA was preserved posterior to the skin incision, and the surgery was completed without damage to the STA.

article published online
December 15, 2022

DOI https://doi.org/10.1055/s-0042-1757222.
ISSN 2248-9614.

Thieme Medical and Scientific Publishers Pvt. Ltd., A-12, 2nd Floor, Sector 2, Noida-201301 UP, India

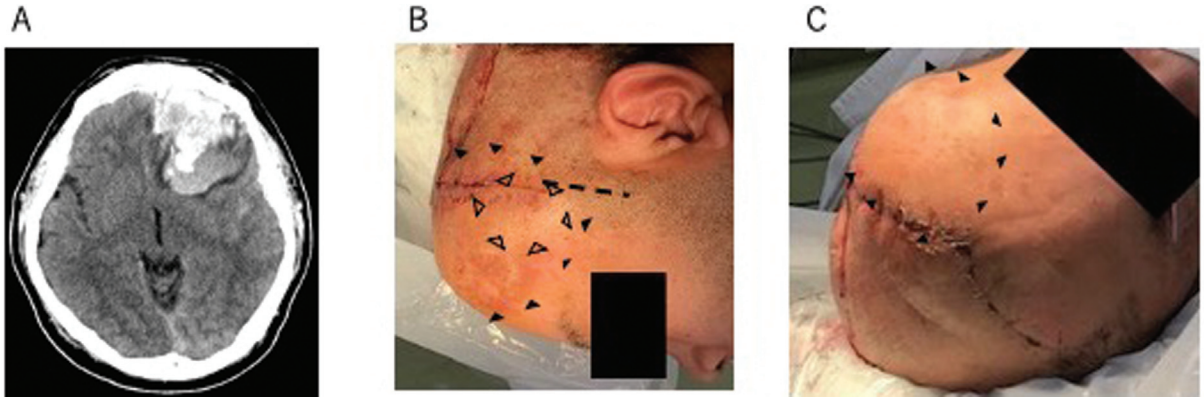

Fig. 1 (**A**) Axial image of head computed tomography on admission. Intracranial hematoma was detected in the left frontal lobe. (**B**, **C**) Photographs before the second surgery. Severe subcutaneous swelling was identified in the left frontal region (▲). The superficial temporal artery (STA) was palpable on the occipital side of the skin incision (—). A pulsative portion of the subcutaneous mass was identified on the frontal side of the STA (△). A pulsatile portion of the mass was identified on the frontal side of the STA.

The postoperative course was good, with mild paralysis of the right upper and lower limbs and clear consciousness. Normal blood pressure was maintained by oral administration of a calcium channel blocker. The surgical wound was in good condition, and the hooks were removed on the 7th postoperative day. On the 20th day after surgery, the patient noted pain and swelling of the wound, despite no prior reports of wound swelling. The swelling gradually worsened within 1 hour, the sutures tore, and bleeding was observed. An emergency head CT scan (plain and contrast) revealed a $13 \times 21 \times 22$ mm aneurysm in the parietal branch of the left STA with a marked subcutaneous hematoma (►**Fig. 1B,C**). Because the patient experienced a severe headache, emergency surgery was performed. There were no abnormal findings on preoperative blood tests, including blood coagulation and fibrinolysis function.

At surgery, the STA was palpable caudal to the prior skin incision (►**Fig. 2A**). Additionally, a pulsating spot was observed on the frontal side of the STA within the area of severe head swelling (►**Fig. 2A,B**). This area was considered to be a pseudoaneurysm (►**Fig. 2A**). The skin incision was extended caudally, and the STA was identified. During removal of as much of the hematoma as possible, arterial bleeding was observed from the hematoma area. Thus, the secured STA was temporarily blocked and the prior skin incision was fully opened to sufficiently remove the hematoma. The STA was then traced distally, and was found to be disrupted within the hematoma, with the distal end identified nearby. Both ends were collected for pathology and ligated with silk thread.

Pathology showed true blood vessels with elastic fibers (►**Fig. 3A,B**). Membranous tissue with calcification consisting of some fibrous tissue was also observed (►**Fig. 3A,B**). The area was diagnosed as a pseudoaneurysm because elastic fibers were not identified.

After the second surgery, the patient's headache improved, and the hooks were removed on the 7th day. There was no recurrence of subcutaneous swelling. The patient was transferred to a rehabilitation hospital at 14 days after the second surgery.

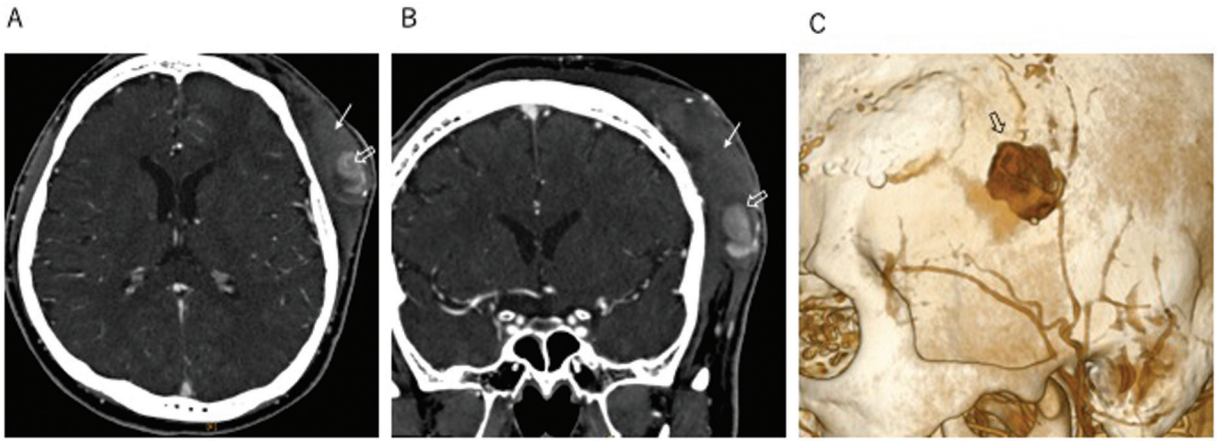

Fig. 2 An axial (**A**) and coronal (**B**) view of gadolinium-enhanced computed tomography (CT) before the second surgery showing a left subcutaneous hematoma (↓). A pool of contrast medium (⇩) was identified in the hematoma, which was consistent with a pseudoaneurysm. (**C**) Three-dimensional CT angiography revealed a pool of contrast medium arising from the left superficial temporal artery.

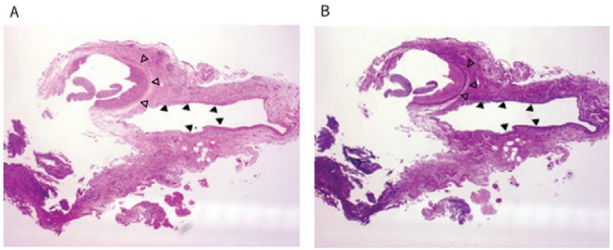

Fig. 3 Histopathological examination of the surgical specimen. (**A**) Hematoxylin and eosin staining (×40 magnification). (**B**) Elastica van Gieson staining (×40 magnification). In the true vessel wall, internal elastic fibers were identified by Elastica van Gieson staining (▲). The area of the membranous tissue was diagnosed as a pseudoaneurysm because no elastic fibers were identified (△).

Discussion

In head and neck aneurysms, the frequency of STA pseudoaneurysms was reported as 0.5 to 2.5%,[17] of which approximately 75% were caused by blunt head trauma.[18] This is because the STA runs just below the scalp, on top of the hard skull, making it vulnerable to trauma.[17,18] Damage to the arterial wall can result in hematoma formation beneath the scalp, while in some cases blood flow may remain between the hematoma cavity and the vessel lumen. In this condition, the hematoma is absorbed and a fibrous coating develops around it, forming a pseudoaneurysm.[17,18] Histological findings in our case showed evidence of true blood vessels and fibrous tissue, without elastic fibers, in the excised area, which was consistent with a pseudoaneurysm.

Table 1 Reported cases of pseudoaneurysm of the STA after craniotomy

Author	Sex	Age	Cause of craniotomy	Cause of STA injury	Duration (days)[a]	Rupture of pseudoaneurysm	Treatment
Shimoda et al (1988)[11]	Male	17 yo	Removal of intracranial hematoma	Unknown	40	No	Embolization
Fernández-Portales et al (1999)[4]	Male	51 yo	Clipping for ruptured aneurysm	Pin head holder	35	+	Extirpation
Tsutsumi et al (2000)[13]	Male	48 yo	Clipping for ruptured aneurysm	Possibly suture needle	40	No	Extirpation
Lee et al (2002)[8]	Male	52 yo	Clipping for ruptured aneurysm	Possibly suture needle	110	No	Extirpation
Hakan et al (2011)[5]	Female	58 yo	Clipping for ruptured aneurysm	Unknown	4 d	No	Extirpation
Bobinski et al (2004)[2]	Male	74 yo	Clipping for ruptured aneurysm	Unknown	17	No	Injection of thrombin glue
Wang et al (2011)[14]	Male	28 yo	Clipping for ruptured aneurysm	Possibly suture needle	25	No	Extirpation
Terterov et al (2012)[12]	Male	31 yo	Clipping for ruptured aneurysm	Possibly suture needle (triple H)	22	No	Coil embolization andsealed with liquid Onyx
Kobayashi et al (2013)[7]	Female	41 yo	Microvascular decompression	Pin head holder	71	No	Extirpation
Honda et al (2013)[6]	Male	57 yo	Clipping for ruptured aneurysm	Possibly suture needle (triple H)	1	+	Emergency surgery
Wright et al (2015)[15]	Male	78 yo	Removal of meningioma	Unknown	21	No	Coiling
Madhusudan et al (2015)[9]	Male	57 yo	Removal of high-grade glioma	Possibly suture needle (vasculitis)	8	+	Emergency surgery
Anania et al (2018)[1]	Unknown	3 wo	Surgery for craniosynostosis	Unknown	17	No	Extirpation
Entezami et al (2019)[3]	Male	83 yo	Removal of high-grade glioma	Unknown	Na	+	Embolized and surgery
Zheng et al (2021)[16]	Male	36 yo	Removal of epidural hematoma	Fish hook retractor	1	No	Extirpation
Shields et al (2021)[10]	Male	38 yo	Surgery for cerebrospinal fluid leak repair	Unknown	14	+	Emergency surgery
Present case	Male	47 yo	Removal of intracranial hematoma	Unknown	20	+	Emergency surgery

Abbreviations: STA, superficial temporal artery; wo, weeks old; yo, years old.
[a]The duration until the subcutaneous mass was identified after surgery.

Reports of pseudoaneurysms after craniotomy are rare, with only 16 cases in the literature (►**Table 1**).[1–16] Reported causes of STA damage include subcutaneous suture needles, hook retractor, or three-point pin fixators.[6–8,13,16] Systemic diseases including hemophilia or vasculitis, and background such as triple H therapy after subarachnoid hemorrhage, are also risk factors for pseudoaneurysms.[6,9,11,12] Furthermore, even if there is only endothelial damage without bleeding, surgical manipulation or electrocoagulation may lead to formation of fusiform dilatation and subsequent minor bleeding, resulting in pseudoaneurysm formation.[1,5,8,13] In our case, the STA was not injured during surgery and was clearly distant from the site of the Mayfield 3-point pin fixator. Thus, the pseudoaneurysm in present case may have resulted from microtrauma to the intima caused by surgical manipulation or electrocautery.[1,3] Alternatively, the STA may have been injured during subcutaneous closure, resulting in a small unnoticed bleed that caused the pseudoaneurysm.[1,5,8,13]

The risk factors and probability of pseudoaneurysm rupture are unknown. Nevertheless, massive bleeding was reported in 4 of 16 cases of pseudoaneurysm after craniotomy (25%),[6,9,10] which is not uncommon. In these four cases of massive hemorrhage, including the present case, no obvious pulsatile mass was observed prior to the pseudoaneurysm rupture. However, this may be because careful monitoring for pseudoaneurysm formation was not performed after the first surgery. Thus, careful monitoring of the wound after craniotomy may allow for earlier and less invasive treatment.

Conclusion

Pseudoaneurysms of the STA after craniotomy may result in a severe subcutaneous hematoma that requires surgical removal. After craniotomy, the patient should be carefully monitored for the appearance of pseudoaneurysms in the surgical wound, even if there is no intraoperative bleeding from the STA.

Conflicts of Interest

None declared.

Ethical Approval

The report was approved by the institutional review board of Kagawa Rosai Hospital (R2–9). The patient provided written informed consent for this case report.

References

1 Anania P, Pacetti M, Ravegnani M, Pavanello M, Piatelli G, Consales A. Iatrogenic pseudoaneurysm of superficial temporal artery after surgery for scaphocephaly: case report and review of literature. World Neurosurg 2018;111:60–62

2 Bobinski L, Boström S, Hillman J, Theodorsson A. Postoperative pseudoaneurysm of the superficial temporal artery (S.T.A.) treated with Thrombostat (thrombin glue) injection. Acta Neurochir (Wien) 2004;146(09):1039–1041, discussion 1041

3 Entezami P, Dalfino J, O'Brien MW, Paul A. Endovascular embolisation of an iatrogenic superficial temporal artery pseudoaneurysm using liquid embolic. BMJ Case Rep 2019;12(01):e227742

4 Fernández-Portales I, Cabezudo JM, Lorenzana L, Gómez L, Porras L, Rodríguez JA. Traumatic aneurysm of the superficial temporal artery as a complication of pin-type head-holder device. Case report. Surg Neurol 1999;52(04):400–403

5 Hakan T, Ersahin M, Somay H, Aker F. Pseudoaneurysm of the superficial temporal artery following revision of a middle cerebral artery aneurysm clipping: case report and review of the literature. Turk Neurosurg 2011;21(03):430–434

6 Honda M, Anda T, Ishihara T. Ruptured pseudoaneurysm of the superficial temporal artery after craniotomy. Neurol India 2013; 61(06):698–699

7 Kobayashi H, Abe H, Shigemori Y, et al. A case of pseudoaneurysm of superficial temporal artery after craniotomy. Current Pract Neurosurg 2013;23:908–912

8 Lee GY, Daniel RT, Halcrow S. Postoperative pseudoaneurysm of the superficial temporal artery. J Neurol Neurosurg Psychiatry 2002;72(04):553–554

9 Madhusudan HV, Krishnamoorthy N, Suresh PK, Subramaniam V. Superficial temporal artery pseudoaneurysm presenting as extradural hematoma: a case report and review of literature. Asian J Neurosurg 2015;10(02):63–65

10 Shields J, Robichaux J, Morrow K, Crutcher C, Tender G. Rupture of a superficial temporal artery pseudoaneurysm following craniotomy. J Surg Case Rep 2021;2021(09):b379

11 Shimoda M, Ikeda A, Sato O, Watabe T. [A case of multiple superficial temporal artery pseudoaneurysms following craniotomy]. No Shinkei Geka 1988;16(06):797–800

12 Terterov S, McLaughlin N, Martin NA. Postcraniotomy superficial temporal artery pseudoaneurysm in the setting of triple H therapy: a case report and literature review. Surg Neurol Int 2012;3:139

13 Tsutsumi M, Kawano T, Kawaguchi T, Kaneko Y, Ooigawa H. Pseudoaneurysm of the superficial temporal artery following craniotomy–case report. Neurol Med Chir (Tokyo) 2000;40(05): 261–263

14 Wang X, Chen JX, You C. Iatrogenic false aneurysm caused by surgery of a traumatic intracranial false aneurysm. Neurol India 2011;59(05):753–755

15 Wright CH, Wright J, Badjatiya A, Manjila S, Reed S, Geertman R. Ultrasound guided local endovascular coiling of an iatrogenic superficial temporal artery pseudoaneurysm. J Cerebrovasc Endovasc Neurosurg 2015;17(04):313–317

16 Zheng HX, Lee YL, Chen GY, Hung YC. Iatrogenic pseudoaneurysm of the superficial temporal artery following craniectomy from a scalp hook retractor penetrating injury: case report and literature review. Int J Surg Case Rep 2021;84:106076

17 Fujii S, Kajikawa H, Yamamura K, Wada M, Shimamoto F. [Spontaneous dissecting aneurysm of the superficial temporal artery: a case report]. No Shinkei Geka 1995;23(09):797–800

18 Khandelwal P, Akkara F, Dhupar V, Louis A. Traumatic pseudoaneurysm of the superficial temporal artery. Natl J Maxillofac Surg 2018;9(01):74–77

