



Congenital Analbuminemia Associated with Hypothyroidism in a Preterm Neonate: The First Case from a Highly Consanguineous Community

Manar Al-lawama¹  Jumana Albaramki¹ Arwa Kiswani¹ Sara Kussad¹ Rasha Odeh¹ Eyad Altamimi²

¹The Pediatric Department, The University of Jordan, Amman, Jordan

²The Pediatric and Neonatal Department, Jordan University for Science and Technology, Irbid, Jordan

Address for correspondence Manar Al-lawama, MD, The Pediatric Department, The University of Jordan, Amman, Jordan (e-mail: manar-76@hotmail.com).

J Child Sci 2022;12:e196–e199.

Abstract

Analbuminemia is a rare autosomal recessive disease characterized by extremely low or zero levels of circulating serum albumin. The diagnosis is made by ruling out other causes of hypoalbuminemia and should be confirmed by gene mutation analysis. In this article, we describe the clinical findings of a preterm neonate born to a consanguineous family who presented with progressive lower limb edema at the age of 7 days and who was confirmed as having congenital analbuminemia by genetic testing (homozygous mutation ALB NP_000468.1: p. Val78CysfsTer2) and hypothyroidism. This is the first case of congenital analbuminemia to be reported from Jordan.

Keywords

- ▶ analbuminemia
- ▶ albumin
- ▶ rare disease
- ▶ neonatal edema

Introduction

Albumin is produced by the liver and released into the blood stream; it constitutes two-thirds of total plasma proteins (35–45 g/L) and is responsible for 85% of plasma oncotic pressure.¹ In plasma, albumin carries nutrients, waste, drugs, and hormones.² Its other important functions include buffering capacity, action as an amino acid source, neutralization of free radicals, and anti-inflammatory effects.³

ALB is the gene responsible for albumin production and is located on chromosome 4 at the position 4q13.⁴ To date, 73 nucleotide substitutions (mainly missense) have been reported to cause circulating variants of ALB or its propeptides,⁵ and 27 different defects in either the 14 exons of ALB or in the intron/exon junctions have been identified as causes of congenital analbuminemia (CAA).⁶

CAA is a rare autosomal recessive disease with an incidence of one in 1,000,000 live births (Online Mendelian Inheritance in Man entry number 616000),⁷ and approximately 90 cases have been reported since 1954.^{6,8} CAA is characterized by extremely low or zero levels of circulating

serum albumin. Edema is the most common finding in young children, while hypercholesterolemia is typical in older individuals. The diagnosis is made by ruling out other causes of hypoalbuminemia and should be confirmed by gene mutation analysis. CAA carries high rate of mortality,⁹ and only a few individuals with CAA survive the neonatal period.^{10,11}

In this article, we describe the clinical findings of a neonate with CAA and hypothyroidism, confirmed by molecular analysis of the ALB gene. The present case of CAA is the first to be reported in Jordan.

Case Presentation

The patient is a male baby, part of a dichorionic diamniotic twin pregnancy. He was conceived by in vitro fertilization and was born at 33 weeks and 3 days of gestation to a primigravida mother. He was delivered by cesarean section due to prematurity and twin pregnancy and had Apgar scores of 8 and 9 at 1 and 5 minutes, respectively, after birth. He had symmetrical intrauterine growth restriction, but his length

received
February 9, 2022
accepted after revision
July 11, 2022

DOI <https://doi.org/10.1055/s-0042-1757149>.
ISSN 2474-5871.

© 2022. The Author(s).

This is an open access article published by Thieme under the terms of the Creative Commons Attribution License, permitting unrestricted use, distribution, and reproduction so long as the original work is properly cited. (<https://creativecommons.org/licenses/by/4.0/>)
Georg Thieme Verlag KG, Rüdigerstraße 14, 70469 Stuttgart, Germany

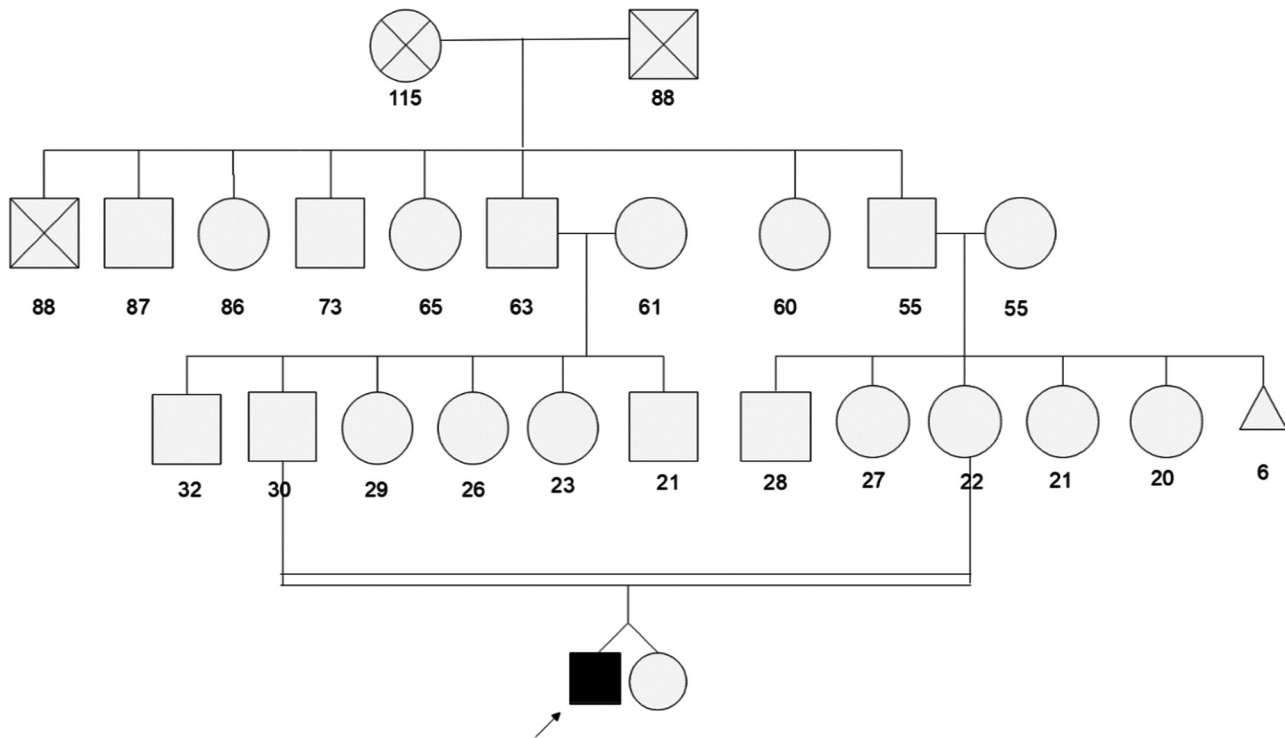


Fig. 1 Family pedigree of the neonate with analbuminemia.

and head circumference were most affected. His birth weight was 1,440 g (below the 10th centile), length was 40 cm (below the 3rd centile), and head circumference was 26 cm (below the 3rd centile). His twin was a girl with appropriate weight for her age. Antenatally, he had poor growth but no other documented complications. The parents are first degree cousins, and the maternal grandmother had a history of six first-trimester miscarriages (→Fig. 1).

He was initially admitted due to prematurity and respiratory distress, which was managed by nasal continuous positive airway pressure. According to our protocol, he was on total parenteral nutrition started at birth at a rate of 80 mL/kg with increments of 20 mL/kg/day, reaching 150 mL/kg/day on day 5. He was started on an initial protein dose of 2.4 g/kg, increased gradually to 4 g/kg. The patient was started on breast milk feeding as per the unit protocol; he tolerated his feeds with normal bowel motions and no vomiting, but his weight gain was unsatisfactory.

At the age of 7 days, the baby developed lower limb edema and was found to have low albumin of 0.65 g/dL. Urine was negative for protein, and the spot protein to creatinine ratio was normal. The baby received human albumin 1 g/kg and was retested for proteinuria, which was also negative. The edema progressed into penile and scrotal edema, but there were no signs of liver dysfunction, and his basic laboratory investigations showed normal complete blood counts, serum electrolytes, prothrombin time, international normalized ratio, and liver enzymes. Abdominal and liver ultrasounds were reported as normal, apart from a minimal amount of free intraperitoneal fluid. Thyroid function screening was reported as abnormal, with elevated thyroid-stimulating

hormone (TSH) of 30.6 mIU/L and normal free T4 of 14.5 pmol/L. He was started on L-thyroxine at the age of 8 days.

On an assumption of protein-losing enteropathy secondary to cow's milk protein allergy, a trial of extensively hydrolyzed infant formula was used, but there was no improvement in serum albumin or clinical sign. Stool for α 1-antitrypsin was not available. Upon considering cystic fibrosis as a cause of the patient's symptoms, pancreatic replacement therapy (CREON) was also tried, but with no response. During hospitalization, the patient required repeated human albumin transfusions.

The selectivity of albumin involvement in the absence of any protein loss, consanguinity of parents, and maternal grandmother's history of multiple miscarriages (→Fig. 1) raised the suspicion of congenital impaired albumin production. Whole exome sequencing was ordered for the patient, and the results confirmed a diagnosis of CAA with homozygous mutation (ALB NP_000468.1: p. Val78CysfsTer2). Known as the Kayseri variant, this has been reported multiple times as pathogenic (ClinVar ID: VCV000156319) and is expected to cause a loss of normal protein function via nonsense-mediated messenger ribonucleic acid decay.

Once the diagnosis was made, the patient's sister's condition was reevaluated. She had normal growth and her serum albumin was normal. The patient was discharged home but still required recurrent admissions for albumin transfusion and recurring infections, mainly gastroenteritis. The parents have recently reported the development of hypercholesterolemia, which is being managed at another medical center. At the time of submitting this article, the patient was 6 months old. Consent was received from the parents for this report.

Discussion

Albumin is a major body protein with multiple essential functions. Congenital absence of albumin is extremely rare; according to estimates, less than one in a million people have analbuminemia, regardless of gender or ethnic predilection.¹¹ To date, fewer than a hundred cases of CAA have been registered worldwide, with our case being the first from Jordan.

Despite being termed “congenital,” fewer than 20% of CAA cases are identified during infancy and only approximately 9% during the neonatal period. Many families with analbuminemic children have reported fetal or neonatal death of their siblings, suggesting that albumin might play a fundamental role in fetal development^{2,6} or that this might be secondary to commonly encountered oligohydramnios/placental pathologies (e.g., edema, large calcifications).⁹ Unfortunately, in the current case, no postpartum placental examination was performed.

Although this was the first pregnancy for the mother, the unexplained recurrent abortions in the grandmother might be related to CAA. Neonates with CAA tend to be both born prematurely and small for their gestational age. Toye et al⁹ described 11 cases of CAA in the Canadian First Nations communities of Saskatchewan, Canada, of whom 63.7% (seven patients) were premature infants and three (23.7%) were small for their age. Our patient is consistent with those reports, having been born prematurely at 33 weeks and 3 days. His growth parameters were below the 10th centile, and it was noticeable that his length and head circumference were below the 3rd centile while his weight was only just below the 10th centile. This could be attributed to fluid retention that falsely magnified his weight, but the edema was not clinically evident until his seventh day of life. Indeed, postnatal presentations vary, with most neonates being asymptomatic and few showing symptoms of fluid retention, edema, or recurrent infections, similar to our patient.⁹

Albumin transports heavy metals, fatty acids, metabolites, bilirubin, enzymes, hormones, and drugs, and it is rather peculiar that a protein with so many functions can be virtually absent and yet cause only minimal clinical and biochemical abnormalities.¹² A key compensatory mechanism involves the production of nonalbumin proteins, resulting in a slight decrease in total serum protein levels, and these other proteins are believed to take over many of the functions that albumin usually performs.^{13,14} In the literature, significant hypocalcemia and hypomagnesemia have been reported in four children,² but our patient did not develop any electrolyte imbalances during admission.

The patient’s diagnosis with congenital hypothyroidism was based on significantly raised TSH, which was associated with normal-range free T4. The finding of a normal level of free T4 might be attributable to the absence of albumin, with the higher thyroid binding globulin capacity that has been reported in patients with CAA¹⁵ possibly being insufficient to compensate for the lack of albumin. Hypothyroidism has previously been reported in two patients,^{16,17} but whether

hypothyroidism is actually related to CAA or not cannot be determined at this stage.

Patients with congenital CAA show significant derangement in lipid metabolism. The compensatory mechanism for low albumin leads to severe hypercholesterolemia and high low-density lipoprotein levels, while high-density lipoprotein and triglyceride levels usually remain normal.¹⁸ Such changes may be responsible for the premature ischemic heart disease found in adult patients.^{19,20} Although actual levels of lipids are not available for our patient, high levels of cholesterol were reported at his last follow-up at another center.

The data reported to date has identified 28 distinct variations of the albumin gene (ALB), most of which are unique to a single individual or family.⁵ Most defects have been splicing, nonsense variants, or frameshift/deletions. The Kayseri variant (c.228_229 del) identified in our patient is the most common cause of CAA⁶ and causes an AT deletion at positions c.228–229, which are the 91st and 92nd bases of exon 3, producing a frameshift leading to a premature stop two codons downstream. The translated product would thus consist of only 54 amino acids.²¹

This mutation appears to be distributed worldwide—at least four Arab children have already been reported.²² It has previously been noted that these patients might have mild developmental delay,⁹ but due to the short duration of follow-up, such findings cannot be confirmed in this case.

Conclusion

CAA is an extremely rare condition. It should be suspected in prematurely born babies with intrauterine growth restriction if they develop edema with extremely low albumin, especially in the presence of consanguinity, as in our case. Genetic analysis should be performed after exclusion of the more likely diagnoses.

Conflict of Interest

None declared.

Acknowledgments

The authors would like to thank 3billion corporation in Seoul, Republic of Korea for producing and analyzing the results of the whole exome sequencing (rare disease genetic testing).

References

- Peters T Jr. All about Albumin: Biochemistry, Genetics, and Medical Applications. Academic Press; 1995
- Koot BG, Houwen R, Pot DJ, Nauta J. Congenital analbuminaemia: biochemical and clinical implications. A case report and literature review. *Eur J Pediatr* 2004;163(11):664–670
- Kragh-Hansen U. Human Serum Albumin: A Multifunctional Protein. In: Otagiri M, Chuang V, eds. *Albumin in Medicine*. Singapore: Springer; 2016
- Minghetti PP, Ruffner DE, Kuang WJ, et al. Molecular structure of the human albumin gene is revealed by nucleotide sequence within q11-22 of chromosome 4. *J Biol Chem* 1986;261(15):6747–6757

- 5 Minchiotti L, Campagnoli M. Genetic variants of human serum albumin. *Albumin*. January 2021. Accessed July 27, 2022 at: <https://www.albumin.org>
- 6 Minchiotti L, Caridi G, Campagnoli M, Lugani F, Galliano M, Kragh-Hansen U. Diagnosis, phenotype, and molecular genetics of congenital Analbuminemia. *Front Genet* 2019;10:336
- 7 Online Mendelian Inheritance in Man. OMIM®. Baltimore, MD: Johns Hopkins University MIM Number: {616000}: {06/03/2021}. Accessed July 27, 2022 at: <https://omim.org/>
- 8 Dammacco F, Miglietta A, D'Addabbo A, Fratello A, Moschetta R, Bonomo L. Analbuminemia: report of a case and review of the literature. *Vox Sang* 1980;39(03):153–161
- 9 Toye JM, Lemire EG, Baerg KL. Perinatal and childhood morbidity and mortality in congenital analbuminemia. *Paediatr Child Health* 2012;17(06):e20–e23
- 10 Ruffner DE, Dugaiczky A. Splicing mutation in human hereditary analbuminemia. *Proc Natl Acad Sci U S A* 1988;85(07):2125–2129
- 11 Watkins S, Madison J, Galliano M, Minchiotti L, Putnam FW. A nucleotide insertion and frameshift cause analbuminemia in an Italian family. *Proc Natl Acad Sci U S A* 1994;91(06):2275–2279
- 12 Cormode EJ, Lyster DM, Israels S. Analbuminemia in a neonate. *J Pediatr* 1975;86(06):862–867
- 13 Kallee E. Bennhold's analbuminemia: a follow-up study of the first two cases (1953–1992). *J Lab Clin Med* 1996;127(05):470–480
- 14 Kang J, Holland M, Jones H, Kaysen GA. Coordinate augmentation in expression of genes encoding transcription factors and liver secretory proteins in hypo-oncotic states. *Kidney Int* 1999;56(02):452–460
- 15 Hollander CS, Bernstein G, Oppenheimer JH. Abnormalities of thyroxine binding in analbuminemia. *J Clin Endocrinol Metab* 1968;28(07):1064–1066
- 16 Platt HS, Barron N, Giles AF, Midgley JE, Wilkins TA. Thyroid-function indices in an analbuminemic subject being treated with thyroxin for hypothyroidism. *Clin Chem* 1985;31(02):341–342
- 17 Suppressa P, Carbonara C, Lugani F, et al. Congenital analbuminemia in a patient affected by hypercholesterolemia: a case report. *World J Clin Cases* 2019;7(04):466–472
- 18 Crook MA. *Annals of Clinical Biochemistry*. Analbuminaemia: clinical features and associated hypercholesterolaemia. *Ann Clin Biochem* 2016;53(Pt 5):525–526
- 19 Caridi G, de Abreu IBR, Alves JA, et al. A novel splicing mutation in the ALB gene causing analbuminaemia in a Portuguese woman. *Pathology* 2018;50(06):679–682
- 20 Burgess LJ, Marais AD. The use of simvastatin in analbuminaemia. *Cardiovasc Drugs Ther* 2001;15(06):555–558
- 21 Galliano M, Campagnoli M, Rossi A, et al. Molecular diagnosis of analbuminemia: a novel mutation identified in two Amerindian and two Turkish families. *Clin Chem* 2002;48(6 Pt 1):844–849
- 22 Minchiotti L, Galliano M, Caridi G, Kragh-Hansen U, Peters T Jr. Congenital analbuminaemia: molecular defects and biochemical and clinical aspects. *Biochim Biophys Acta* 2013;1830(12):5494–5502