



Diffuse Leptomeningeal Glioneuronal Tumor: A Rare Case Report with Review of Literature

Amey P. Patankar¹ Palak Vaghela² Jitendra Nasit³ Rajvee Gohil⁴

¹Department of Neurosurgery, Baroda Medical College and SSG Hospital, Vadodara, Gujarat, India

²Department of Radiology, Sahyog Imaging Centre, Vadodara, Gujarat, India

³Department of Pathology, Baroda Medical College and SSG Hospital, Vadodara, Gujarat, India

⁴Department of Surgery, Baroda Medical College and SSG Hospital, Vadodara, Gujarat, India

Address for correspondence Amey P. Patankar, MBBS, MS, MCh, 703, Rajarshi Darshan Tower, Near Jalaram Mandir, Karelilbag, Vadodara 390018, Gujarat, India (e-mail: docapp@icloud.com).

AJNS 2022;17:532–535.

Abstract

Keywords

- ▶ glioneuronal tumor
- ▶ diffuse glioneuronal leptomeningeal tumor
- ▶ pediatric brain tumor
- ▶ WHO classification of brain tumor
- ▶ glial tumor

Diffuse leptomeningeal glioneuronal tumor (DLGNT) is a rare tumor that was defined as a separate entity in the 2016 World Health Organization classification of brain tumors. It is most common in the pediatric age group. The diagnosis of this tumor can be made preoperatively by its characteristic imaging findings of diffuse intracranial and intraspinal nodular leptomeningeal thickening and enhancement associated with small cyst-like nonenhancing lesions in the brain and spinal cord. We report a case of DLGNT in a 7-year-old male presenting with hydrocephalus. The patient was treated successfully by cerebrospinal fluid (CSF) diversion followed by biopsy of the lesion from the cerebellum. Histopathology and immunohistochemistry confirmed the diagnosis of DLGNT. Our case would hopefully increase the awareness regarding this rare tumor and facilitate an early diagnosis and management of the affected patients with atypical radiological features.

Introduction

Diffuse leptomeningeal glioneuronal tumor (DLGNT) was first described as a new entity in 2010,¹ and has been included in the 2016 World Health Organization (WHO) classification of central nervous system (CNS) tumors.² It is classified in the category of neuronal and neuronal–glial tumors.

It has been further classified into subtypes based on their molecular basis in the 2021 WHO update on CNS tumors.³

It is seen most commonly seen in the pediatric age group with a strong male preponderance.

A preoperative diagnosis of this condition can be made on imaging studies that commonly show diffuse intracranial and intraspinal leptomeningeal nodular thickening. However, because of the rarity of this tumor, the diagnosis may be overlooked or can be mistaken as meningitis.

Case Presentation

A 7-year-old male child presented with complains of headache and vomiting for the last 2 months and dimness of vision for the last 15 to 20 days. The patient had imbalance

DOI <https://doi.org/10.1055/s-0042-1756637>.
ISSN 2248-9614.

© 2022. Asian Congress of Neurological Surgeons. All rights reserved.

This is an open access article published by Thieme under the terms of the Creative Commons Attribution-NonDerivative-NonCommercial-License, permitting copying and reproduction so long as the original work is given appropriate credit. Contents may not be used for commercial purposes, or adapted, remixed, transformed or built upon. (<https://creativecommons.org/licenses/by-nc-nd/4.0/>)

Thieme Medical and Scientific Publishers Pvt. Ltd., A-12, 2nd Floor, Sector 2, Noida-201301 UP, India

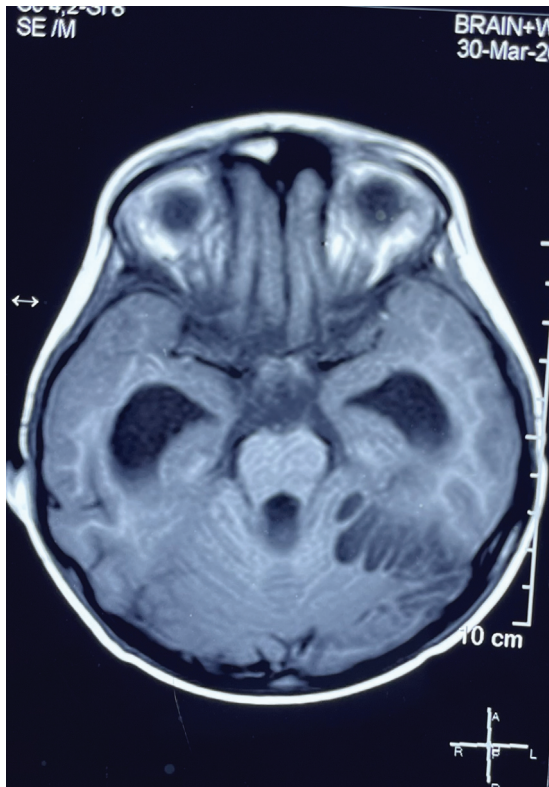


Fig. 1 T1 axial image showing cystic thin-walled cystic lesions in the left cerebellar hemisphere.

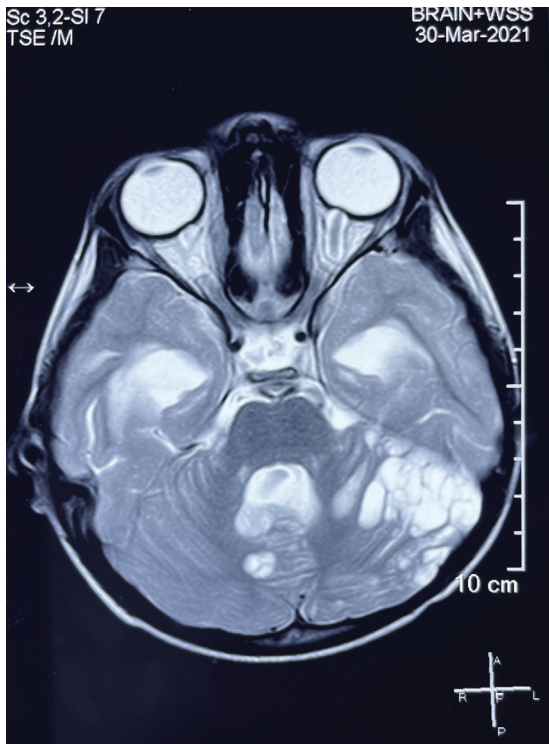


Fig. 2 T2 axial image showing cystic spaces within the cerebellar hemisphere.

while walking for the last 1 month. On examination, patient was fully conscious, with fundus suggestive of papilloedema. There was mild spasticity in the lower limbs with extensor plantars with exaggerated deep tendon reflexes.

Magnetic resonance imaging showed small, multifocal, well-defined thin-walled cystic lesions along the leptomeningeal surfaces of cerebellum (left > right) and bilateral cerebral hemispheres, with mild perilesional edema, without significant contrast enhancement. The lesions were hypointense in T1 (►Fig. 1) and hyperintense in T2 (►Fig. 2) with hydrocephalus. Imaging of the spine revealed a large focal cystic lesion in the dorsal cord (►Fig. 3). Thick irregular leptomeningeal enhancement was seen in patchy distribution along right cerebellum and bilateral sylvian fissures on postcontrast studies (►Fig. 4).

The patient underwent right side ventriculoperitoneal (VP) shunt, to relieve hydrocephalus and provide symptomatic relief. After 3 days, retrosigmoid craniotomy with biopsy of the lesion was done. The lesion was yellowish, jelly-like with ill-defined margins.

Histology showed uniform round cells with bland nuclear chromatin and perinuclear halos, mimicking oligodendroglioma like histology. Cells had inconspicuous nucleoli

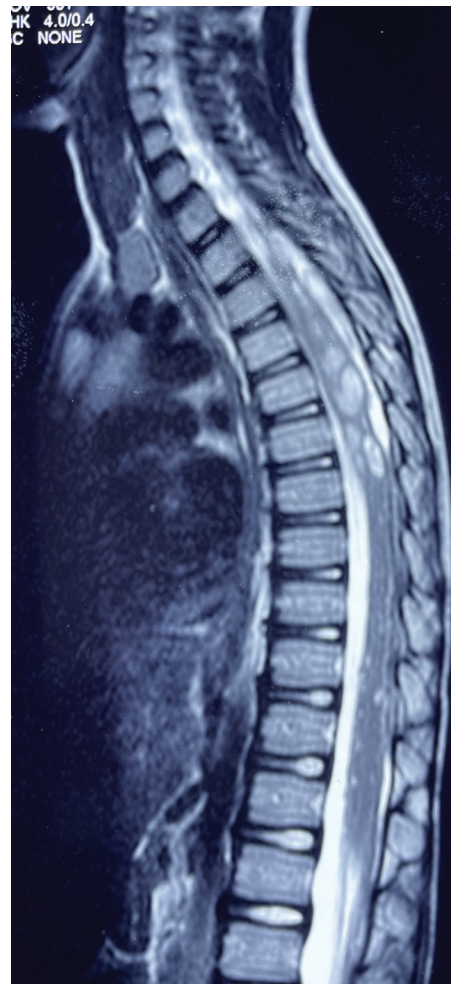

Fig. 3 Magnetic resonance imaging of the spine showing a large focal cystic lesion in the dorsal cord.

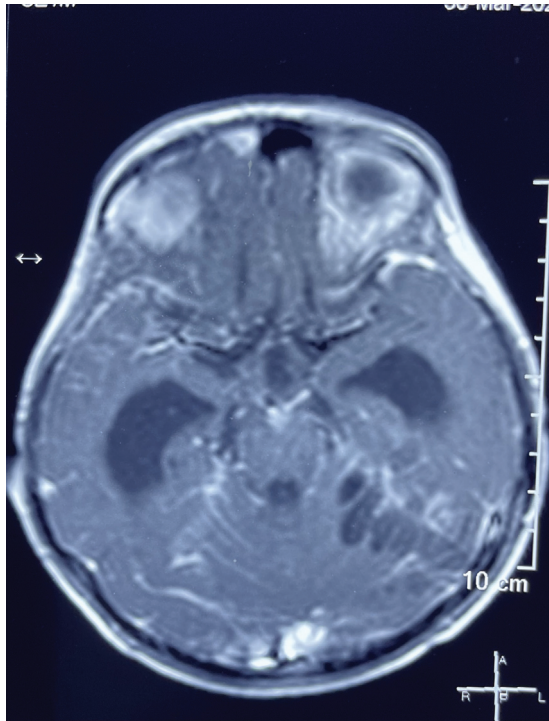


Fig. 4 T1 postcontrast images showing diffuse leptomeningeal enhancement over both the cerebral hemispheres.

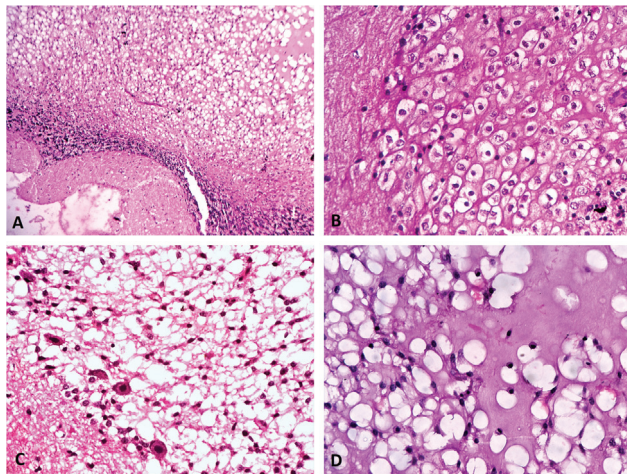


Fig. 5 Hematoxylin and eosin stain: (A) Tumor immediately adjacent to the cerebellar parenchyma without definitive infiltration (10× magnification). (B) Monomorphous round-ovoid nuclei with fine chromatin (mimic oligodendroglial-like cells) with perinuclear halo and inconspicuous nucleoli (40× magnification). (C) Focal ganglion cell differentiation (20× magnification). (D) Areas of microcystic space with pale bluish myxoid material inside (400× magnification).

without mitotic activity. Focal neuronal differentiation was seen. Some areas showed vacuolated microcystic changes with myxoid material. Areas of leptomeningeal desmoplasia were seen. Areas of necrosis and vascular proliferation were not seen (→ Fig. 5).

On immunohistochemistry, these cells showed strong positivity to glial fibrillary acidic protein and S100 stain. Synaptophysin positivity was weak and patchy in nature

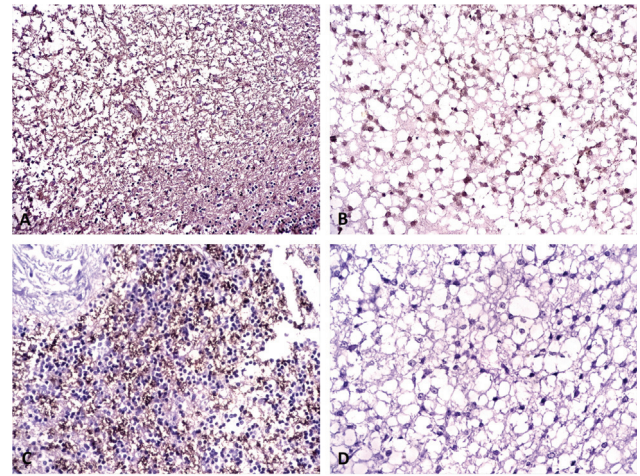


Fig. 6 Immunohistochemistry: (A) Tumor is positive for glial fibrillary acidic protein. (B) Tumor cells are positive for S100. (C) Synaptophysin expression is patchy and granular type. (D) KI-67 is almost absent.

with more granular type. The cells were negative for KI-67. These features provided a conclusive impression of DLGNT (→ Fig. 6).

The patient was referred for chemotherapy and radiotherapy.

Discussion

DLGNT has been defined in the 2016 World Health Organization (WHO) classification of CNS neoplasms as a low-grade tumor, without definite grade allotment, due to limited number of cases and their follow-up. In the recent 2021 World Health Organization (WHO) classification of CNS neoplasms, DLGNT has been subtyped into three types based on molecular basis.

1. DLGNT with 1q gain.
2. DLGNT with methylation class 1.
3. DLGNT with methylation class 2.

The clinical course of conventional DLGNT and DLGNT with methylation class 1 group is roughly like CNS WHO grade II.

DLGNT with anaplastic features, DLGNT with 1q gain, and DLGNT with methylation class 2 behave as CNS WHO grade III tumors with significant decrease in progression free and overall survival.

Because of its rarity, many clinicians and radiologists may not be aware of DLGNT.

The differential diagnosis on imaging of this condition includes bacterial and tuberculous infections,^{4,5} neurocysticercosis, disseminated CNS neoplasms like glioma, diffuse leptomeningeal gliomatosis, leukemia, neurosarcoidosis, phakomatosis, and leptomeningeal lymphomatosis. Correlation with clinical features character of leptomeningeal involvement and CSF studies helps to differentiate DLGNT from infections.

The preoperative radiological diagnosis becomes difficult when there is minimal intracranial leptomeningeal involvement (like in our case), which may be seen in 19 to 29% of the

cases of DLGNT.⁶ Some cases may present as a solitary intracranial or intraspinal mass without any leptomeningeal involvement.⁷

In our case, absence of any clinical features of infection along with presence of multiple cystic lesions in the cerebellum, leptomeningeal nodularity, and a cystic lesion in the dorsal spinal cord favored the diagnosis of DLGNT, which was confirmed by biopsy and immunohistochemistry.

Because it is a rarity, no guidelines exist for the treatment of DLGNTs as of now. The aim of treatment in DLGNT is not total tumor removal but biopsy and VP shunt for hydrocephalus. Because of the diffuse nature and leptomeningeal spread, gross total resection is not possible.

Chemotherapy with carboplatin and vincristine or temozolomide has been proposed as first-line treatment of DLGNTs. Though symptomatic improvement is seen after chemotherapy, no clear radiologic response to chemotherapy has been observed.⁸ The overall median survival is approximately 94 months.⁸

The prognosis of this condition is not altered when there is spinal metastasis. In fact, 50 to 60% cases have some spinal involvement due to leptomeningeal spread. However, because of the rarity of the lesion, the exact difference in prognosis in presence and absence of spinal metastasis cannot be established with certainty as of now.

The effect of craniospinal irradiation on the outcome of patients with DLGNT is unclear, but it is not used as the first line of management because of the significant side effects of radiation in the pediatric population and the relatively slow progression of the disease. It is recommended only in cases with disease progression.

In our case, the parents of the patient refused any further treatment by chemotherapy/radiotherapy.

One year after the diagnosis, the patient remains asymptomatic.

Conclusion

Our case would hopefully increase the awareness about this rare tumor among clinicians and radiologists and help correct diagnosis and treatment of this tumor.

Note

We the authors confirm that this manuscript or its part has not been submitted for publication anywhere.

Conflict of Interest

There is also no conflict of interest.

References

- 1 Gardiman MP, Fassan M, Orvieto E, et al. Diffuse leptomeningeal glioneuronal tumors: a new entity? *Brain Pathol* 2010;20(02):361–366
- 2 Louis DN, Perry A, Reifenberger G, et al. The 2016 World Health Organization Classification of Tumors of the Central Nervous System: a summary. *Acta Neuropathol* 2016;131(06):803–820
- 3 Louis DN, Perry A, Wesseling P, et al. The 2021 WHO Classification of Tumors of the Central Nervous System: a summary. *Neuro-oncol* 2021;23(08):1231–1251
- 4 Demir HA, Varan A, Akyüz C, Söylemezoğlu F, Cila A, Büyükpamukçu M. Spinal low-grade neoplasm with leptomeningeal dissemination mimicking tuberculous meningitis in a child. *Childs Nerv Syst* 2011;27(01):187–192
- 5 Tiwari S, Yadav T, Pamnani J, et al. Diffuse leptomeningeal glioneuronal tumor: a unique leptomeningeal tumor entity. *World Neurosurg* 2020;135:297–300
- 6 Lakhani DA, Mankad K, Chhabda S, et al. Diffuse leptomeningeal glioneuronal tumor of childhood. *AJNR Am J Neuroradiol* 2020;41(11):2155–2159
- 7 Perez-Vega C, Akinduro OO, Cheek BJ, Beier AD. Spinal cord diffuse leptomeningeal glioneuronal tumor presenting without leptomeningeal dissemination. *Pediatr Neurosurg* 2021;56(06):563–568
- 8 Aguilera D, Castellino RC, Janss A, et al. Clinical responses of patients with diffuse leptomeningeal glioneuronal tumors to chemotherapy. *Childs Nerv Syst* 2018;34(02):329–334