



Posterior Cranial Fossa Meningioma Causing Tonsillar Herniation and Giant Cervicothoracic Syringomyelia: Case Report and Review of Literature

Estelle Anne How Hong¹ Ahmed Shalid¹ Srihari Deepak¹ Gueorgui Kounin¹

¹Department of Neurosurgery, Hull University Teaching Hospitals, Hull, United Kingdom

AJNS 2022;17:515–520.

Address for correspondence Estelle Anne How Hong, MBChB, MRCS ENT, Department of Neurosurgery, Hull University Teaching Hospitals, Anlaby Road, Hull, HU3 2JZ, United Kingdom (e-mail: estellehow@doctors.org.uk).

Abstract

Syringomyelia is a fluid-filled cyst within the spinal cord and is usually associated with conditions that obstruct the cerebrospinal fluid (CSF) (flow at the foramen magnum or spinal levels such as Chiari malformations, arachnoiditis, and basilar invaginations). Very rarely, posterior cranial fossa tumors can lead to tonsillar herniation and secondary syringomyelia. There are only nine reported cases in the literature. We report a rare case of a 56-year-old female with posterior cranial meningioma and secondary syringomyelia, admitted with headache, nausea, vomiting, and ataxic gait. Magnetic resonance imaging (MRI) demonstrated a large posterior fossa lesion causing early ventriculomegaly and a giant cervicothoracic syrinx within the upper spinal cord extending from the hindbrain inferiorly to the level of T8. She underwent a posterior fossa craniectomy with left C1 hemilaminectomy and complete excision of the tumor. In 6 months following her procedure, an MRI scan showed a significant reduction in the caliber of the syringomyelia throughout its length, and there was a significant improvement in symptoms. Although the pathophysiology of syrinx formation is still poorly understood, the alteration of CSF dynamic flow has been implicated. A common unifying cause appears to be increased transcranial difference in intracranial pressure across the foramen magnum causing tonsillar herniation, irrespective of location in the posterior fossa. With high syrinx pressure, mechanical stress-induced structural change of the spinal cord occurs, allowing the persistence and progression of the syrinx in the spinal cord. Syringomyelia appears to be resolved partially or completely after craniotomy and excision of the posterior fossa lesion.

Keywords

- ▶ syringomyelia
- ▶ posterior cranial fossa
- ▶ meningioma
- ▶ tonsillar herniation

Introduction

Syringomyelia is a poly-etiological disorder characterized by a fluid-filled cyst within the spinal cord. It is associated with conditions that obstruct the cerebrospinal fluid (CSF) flow at

the foramen magnum or spinal levels such as Chiari malformations (CMs), arachnoiditis, and basilar invaginations.¹ Posterior fossa tumors are a rare cause of secondary syringomyelia. We present a rare case of a 55-year-old lady with a large posterior fossa fibrous meningioma causing secondary

DOI <https://doi.org/10.1055/s-0042-1756634>.
ISSN 2248-9614.

© 2022. Asian Congress of Neurological Surgeons. All rights reserved.

This is an open access article published by Thieme under the terms of the Creative Commons Attribution-NonDerivative-NonCommercial-License, permitting copying and reproduction so long as the original work is given appropriate credit. Contents may not be used for commercial purposes, or adapted, remixed, transformed or built upon. (<https://creativecommons.org/licenses/by-nc-nd/4.0/>)

Thieme Medical and Scientific Publishers Pvt. Ltd., A-12, 2nd Floor, Sector 2, Noida-201301 UP, India

syringomyelia extending to T8 and early ventriculomegaly. To the best of our knowledge, there have been only nine reported cases in English language literature in which most syringomyelia extended to the cervicothoracic region and our case report being the most extensive syringomyelia reported. We performed a literature review to discuss the disease course, common pathogenesis, and its management.

Case Report

A 56-year-old female, right-handed dominant with a background of hypertension, presented with a 2-year history of constant frontal headaches, severe nausea, and vomiting, and a significant weight loss of 4 stone over 12 months. Furthermore, she had a year of mild weakness of the voice as well as gross ataxic gait and poor coordination.

She underwent a magnetic resonance imaging (MRI) scan of the head and the whole spine that demonstrated a large posterior fossa lesion measuring 3.6 cm to the left of the midline that was compressing the cerebellum (→ Fig. 1), and partially effacing the fourth ventricle and right-sided tonsillar herniation extending 7 mm below the foramen magnum (→ Fig. 2). There was associated narrowing of the left foramen of Luschka and the foramen of Magendie, associated with ventriculomegaly and a syrinx within the upper cord, which extends from the hindbrain inferiorly to the level of T8 (→ Fig. 3). She was commenced on dexamethasone and a proton pump inhibitor and after a multidisciplinary team discussion, she was scheduled for surgery.

Procedure

She underwent a posterior fossa craniectomy with C1 hemilaminectomy and Simpson 1 excision of the lesion. She was positioned into a park-bench lateral position with the left

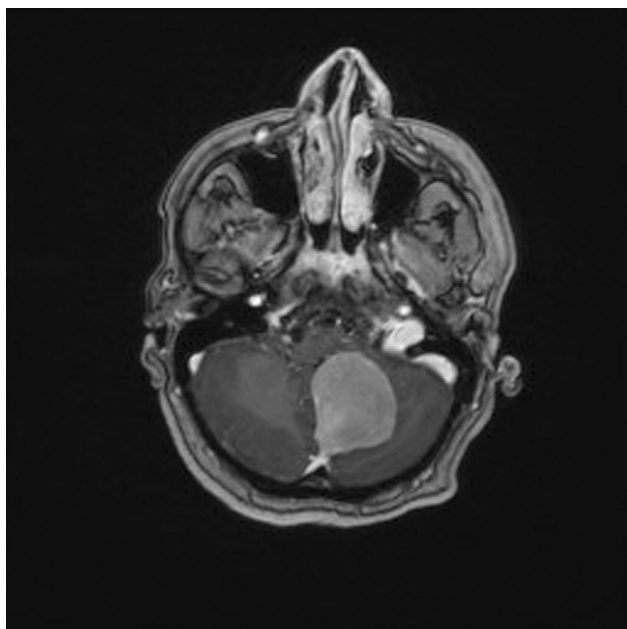


Fig. 1 T1 axial-weighted magnetic resonance imaging with contrast demonstrating a left foramen magnum meningioma.

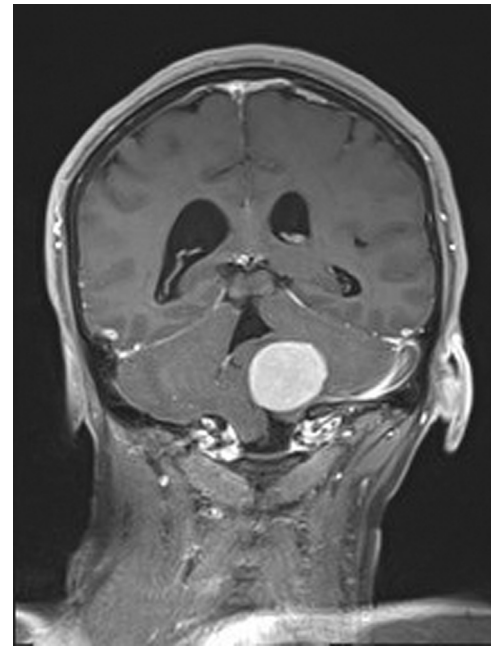


Fig. 2 T1 coronal-weighted magnetic resonance imaging with contrast demonstrating right tonsillar herniation.

side up and her head was in Mayfield pins. A left question mark/hockey stick incision was made curving back toward midline over C1/C2 and extending over the midline to the right side. Dissection was done to expose bone until foramen magnum and arch of C1. C2 was palpable with some muscle stripping on left. The left mastoid process was palpable just at the edge of exposure.

A craniectomy was performed using two burr holes and craniotome and this was extended to the superior border up toinion. A small durotomy at the superior edge was used as starting point to open the dura. The dura excised around the tumor and there was significantly dilated occipital and circular sinus with venous oozing, and therefore ties and ligaclips were used around the occipital sinus for hemostasis. There was a wide attachment base along cerebellar falx and dura toward the foramen magnum requiring a wider opening of the latter with a left partial C1 hemilaminectomy. Internal debulking of tumor was performed using the ultrasonic aspirator and subsequently, the bulk of the tumor was removed by excision along with the dural attachment.

A small further attachment of the tumor along the midline occipital sinus was removed using coagulation and microscissors. There were some adhesions between the tonsils until the obex and inferior portion of the fourth ventricle, which were divided. The posterior inferior cerebellar artery was identified and preserved.

Postoperative

After the procedure, she was kept in the intensive care unit. Postoperatively, she had regular neurological observations and her blood pressure was kept normotensive. A computed tomographic scan of the head at 48 hours postoperatively showed complete removal of the posterior fossa meningioma

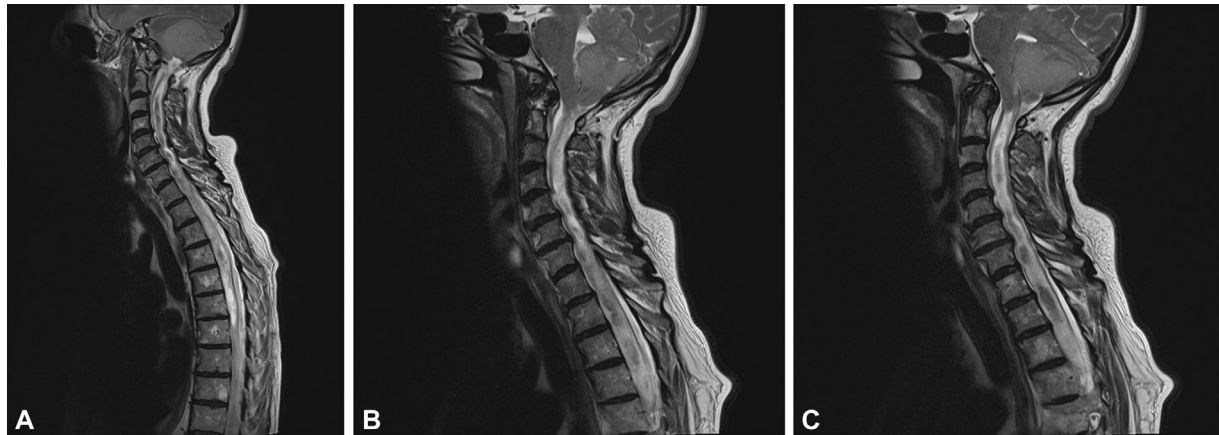


Fig. 3 (A–C) T2 sagittal magnetic resonance imaging showing the extent of the cervicothoracic syrinx and the point of tonsillar narrowing at the foramen magnum just cranial to its origin.

with no evidence of enhancing residuum. Histology confirmed a fibrous meningioma World Health Organization grade 1. She was then discharged back to her based hospital for more rehabilitation, but unfortunately, she contracted coronavirus disease 2019. However, she recovered fully and was discharged back home.

A follow-up MRI scan of the head and spine at 6 months postoperatively showed complete excision of the meningioma, no active hydrocephalus (→**Fig. 4**) and a significant reduction in the caliber of the syringomyelia along its entire length (→**Fig. 5**). The patient reported a significant improvement in the frequency of headaches and an improvement in balance and coordination when compared with the preoperative state. Nausea and vomiting had completely resolved.

Review of Literature

A PubMed literature search was performed with keywords: “syringomyelia,” “posterior fossa,” and “tumour” and approximately 120 articles reviewed. The inclusion criteria for this study were posterior fossa meningiomas causing syrinx formation. Studies including other type of space-occupying lesion or absence of syrinx identified were excluded. Articles not written in English were excluded.

Results

A total of nine isolated similar cases were identified (→**Table 1**).

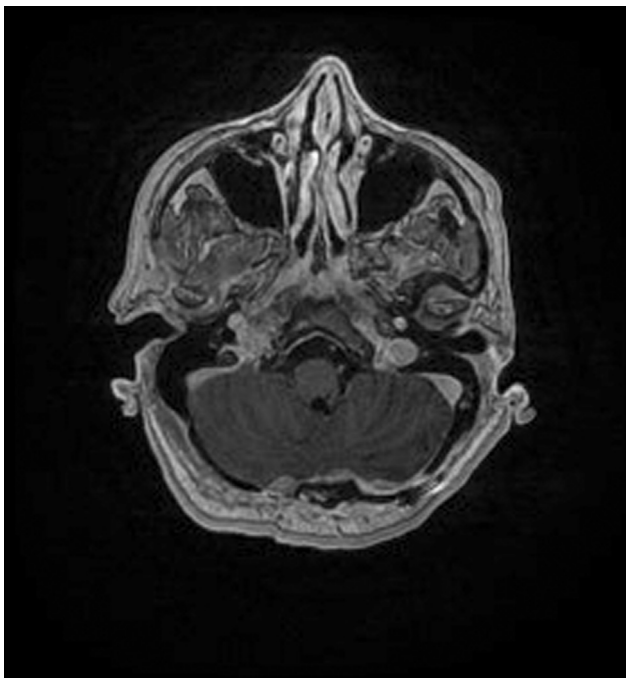


Fig. 4 T1 axial-weighted magnetic resonance imaging showing complete resection of the meningioma.

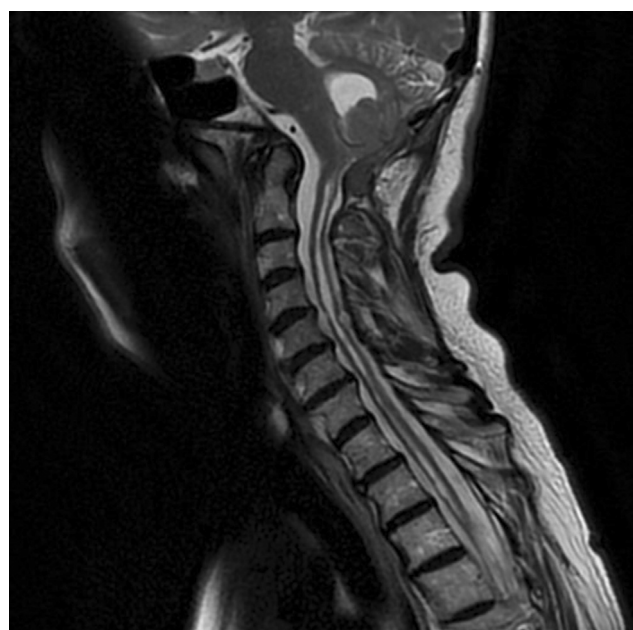

Fig. 5 T2 sagittal magnetic resonance imaging showing near-complete resolution of the syrinx throughout its length.

Table 1 Summary of the reported cases of PCF meningioma causing syringomyelia within the current literature

Author	Age/sex	Location of tumor	Primary symptoms	Duration of symptoms	Tonsillar herniation	Syrinx level and extent	Surgery	Syrinx follow-up
Tachibana et al ¹	53/F	Tentorium cerebelli	Increased ICP, cerebellar signs, none with sensory disturbance to syrinx formations	3 years	Present	C2	N/A	Reduction
	50/F	Adjacent to the pyramis	Symptoms of raised ICP; involvement of the 7th, 8th cranial nerves and cerebellar signs	2 years	Present	C1	N/A	N/A
Bouras et al 2006 ¹¹	55/F	Right-sighted extra-axial infratentorial tumor measuring 4 × 4 cm	Progressive numbness and dysesthesia	6 years	Present	C1–C4	Suboccipital craniectomy	Reduction in 1 year
Bhatoe 2004 ³	38/F	Extra-axial contrast-enhancing meningioma arising from tentorium on the right side and compressing the cerebellum	Generalized headache, vomiting, unsteady gait and increased ICP	6 months	Present	C2	Retromastoid craniectomy	Reduction in 3 months
Fox et al ⁷	53/F	4 × 4.5 cm, extra-axial, homogeneously enhancing tumor that appeared to originate from the right petrous dura compressing and displacing the lateral recess of the fourth ventricle to the left	Occipital pain, nystagmus, hypesthesia in the right C2 dermatome	6 months	Present	C2–C6	Retromastoid craniectomy	Reduction in 1 year
Karttunen et al ¹²	34/F	Tentorial	Nausea, vertigo, cerebellar ataxia, left-sided hemi syndrome	3 weeks	Present	C2–T2	Suboccipital craniectomy	Reduction in 22 months
Jaiswal and Chandra ⁸	30/F	Right cerebellopontine angle extra-axial tumor	Headache, gait ataxia, muscle wasting	5 years	Present	Cervicomedullary junction to C3	Retromastoid suboccipital craniectomy	N/A
Del Maestro et al ⁹	17/F	Left-sighted extra-axial tumor in the PCF, originating from the petrous bone, measuring 6 × 5 × 6.5 cm	Dizziness, paresthesia, headache, neck pain, loss of balance, dysesthesia in upper limb, left hearing loss, nystagmus	1 month	Present	Medulla oblongata to C7	Retrosigmoid craniectomy	Resolution of syrinx at 6 months
Kankane et al ¹⁰	35/F	Left tentorium	Suboccipital headache, vertigo, gait difficulties and nystagmus	3 years	Present	Cervicomedullary junction to C4	Suboccipital craniectomy	Resolution of syrinx in 6 months

Abbreviations: ICP, intracranial pressure; PCF, posterior cranial fossa.

Discussion

Pathogenesis

Tonsillar herniation and syringomyelia secondary to posterior cranial fossa meningiomas are rare entity, described as "external syringomyelia."² Although the pathophysiological mechanism of syrinx formation secondary to posterior cranial fossa lesion is not yet clear, it implied that the mass effect of the posterior cranial lesion leads to tonsillar herniation that amounts to syringomyelia, an entity recently described by authors as an acquired Chiari malformation (ACM).^{3,4} Unlike primary CM, in which syringomyelia is present in 30 to 70% of cases, the presence of syringomyelia in ACM was found to be 82%.⁴ In addition, there is thought to be underdevelopment of the posterior fossa dimensions in a primary CM, which is not the case with secondary tonsillar herniation.

The obstruction of CSF flow at the foramen magnum may lead to an increased pulse pressure within the spinal canal that may force the entry of CSF into the spinal cord.^{1,3,5} In our literature review, all cases of posterior fossa meningioma with syringomyelia had tonsillar herniation noted on the initial scan, further supporting this association. It is, however, difficult to distinguish if whether the posterior fossa tumor causes secondary tonsillar herniation and subsequent syringomyelia or the growth of a posterior fossa tumor predisposes to a worsening of a coexistent CM.

A hypothesis to explain this elucidates that with the presence of obstruction of CSF at the foramen magnum, various activities such as coughing, straining, assuming an erect position or pulsatile fluctuations of CSF pressure during the cardiac cycle lead to a transient increase in CSF pressure above the blockage. This leads to corresponding changes in transmural venous and capillary pressure resulting in vasodilatation below the block and collapse of vessels above the blockage. These uneven changes in vessel diameter cause mechanical stress on the spinal cord, especially more caudal to the level of blockage. This combined with dilatation of vessels finally disrupts the blood-spinal cord barrier, allowing ultrafiltration of crystalloids and accumulation of a protein-poor fluid. Over time, extensive gliosis, edema, and vascular wall thickening will occur.⁶

Presentation

Headache appears to be the most common feature in the presenting complaint as reported in six of the studies in the literature review.^{3,7-10} The most common examination finding was ataxic gait.^{1,8,10-12} It is, however, difficult to differentiate whether the symptoms are caused by cerebellar compression, associated hydrocephalus, or syrinx. The presence of secondary tonsillar herniation and the associated syringomyelia can potentially cause symptoms both independent of and in addition to those caused by the tumor. Tumor size or biology does not appear to show any direct correlation with syrinx size.⁵ The proximity of the tumor to the CSF pathway can also determine the clinical presentation.

Management

Surgical resection was performed in all nine cases reviewed in the literature. Three cases underwent retromastoid craniectomies with three others undergoing suboccipital craniectomies.^{3,7,9} A systematic review of ACM and syringomyelia secondary to space-occupying lesions showed that in all but one case the syringomyelia improved or disappeared completely with surgical resection of the underlying lesion without any patients requiring a subsequent syrinx shunt.⁴ Most patients reported improvement in symptoms after surgical resection of the tumor with five cases showing complete resolution of preoperative symptoms.^{3,8-11} Two of the cases showed some residual mild weakness in the peripheries.¹

In our case report, there was a significant reduction in the diameter of the syringomyelia along its entire length 6 months after treatment. Goel et al reported in a study of cases with longstanding benign tumor at the foramen magnum were found to have significantly higher mean spinal canal diameter at both the C6 and T2 spinal levels than in controls.² Additionally, there was a marginal reduction even in the extent of syringomyelia (which extends from the C2 to the mid T7 level, compared with the previous lower border of T8) in our case report. This is the most extensively reported secondary syringomyelia compared with our literature review. We concur with Levine that increased difference in CSF pressure, with the turbulence of flow across the foramen magnum worsened by tonsillar herniation, is strongly associated with the possibility of syrinx formation.⁶ Furthermore, with high syrinx pressure, mechanical stress-induced structural change of the spinal cord occurs, allowing the persistence and progression of the syrinx in the spinal cord that can be quite extensive as in our case. Regardless, as the patient's symptoms have significantly improved 6 months after her operation, we note that significant clinical improvement precedes radiological resolution of syringomyelia.

Conclusion

Posterior cranial fossa meningioma causing tonsillar herniation and secondary syringomyelia extending to the thoracic cord is rare. The exact pathophysiology of syrinx formation is still not completely understood but is likely related to the alteration of CSF flow dynamic, especially with daily activities and/or progression in the course of the lesion. It is important to distinguish this from a primary CM where there is thought to be underdevelopment of posterior fossa dimensions. Posterior fossa craniectomy and resection of the lesion facilitate a reduction in tonsillar herniation, thus preventing their descent and subsequent blockage of CSF at the foramen magnum. The re-establishment of CSF flow allows the resolution of hydrocephalus and syrinx with very few cases needing subsequent CSF diversion of the syrinx.

Informed Consent

The authors certify that they have obtained all appropriate patient consent forms. In the form, the patient has given her consent for her images and other clinical

information to be reported in the journal. The patient understands that name and initials will not be published and due efforts will be made to conceal identity, but anonymity cannot be guaranteed.

Funding

None.

Conflicts of Interest

None declared.

References

- 1 Tachibana S, Harada K, Abe T, Yamada H, Yokota A. Syringomyelia secondary to tonsillar herniation caused by posterior fossa tumors. *Surg Neurol* 1995;43(05):470–475, discussion 475–477
- 2 Goel A, Shah AH, Vutha R, Goel A. External syringomyelia in longstanding benign foramen magnum tumors. *Surg Neurol Int* 2020;11:92
- 3 Bhatoe HS. Tonsillar herniation and syringomyelia secondary to a posterior fossa tumour. *Br J Neurosurg* 2004;18(01):70–71
- 4 Wang J, Alotaibi NM, Samuel N, Ibrahim GM, Fallah A, Cusimano MD. Acquired Chiari malformation and syringomyelia secondary to space-occupying lesions: a systematic review. *World Neurosurg* 2017;98:800–808.e2
- 5 Galarza M, López-Guerrero AL, Martínez-Lage JF. Posterior fossa arachnoid cysts and cerebellar tonsillar descent: short review. *Neurosurg Rev* 2010;33(03):305–314, discussion 314
- 6 Levine DN. The pathogenesis of syringomyelia associated with lesions at the foramen magnum: a critical review of existing theories and proposal of a new hypothesis. *J Neurol Sci* 2004;220(1-2):3–21
- 7 Fox B, Muzumdar D, DeMonte F. Resolution of tonsillar herniation and cervical syringomyelia following resection of a large petrous meningioma: case report and review of literature. *Skull Base* 2005;15(01):89–97, discussion 98
- 8 Jaiswal AK, Chandra PS. Cerebellopontine angle meningioma with acquired Chiari and syringomyelia: neuroimage. *Neurol India* 2001;49(03):323
- 9 Del Maestro M, De Paulis D, Ricci A, Di Cola F, Galzio R. Syringobulbia associated with posterior fossa meningioma: a review of the literature. *Childs Nerv Syst* 2014;30(10):1749–1752
- 10 Kankane VK, Jaiswal G, Gupta T. Large tentorium meningioma causing Chiari malformation type-1 with syringomelia with complete resolution of syrinx and Chiari after surgical excision: rare case report with review of literature. *Rom Neurosurg* 2016;30:127–131
- 11 Bouras TI, Kouyialis AT, Boviatis EJ, Sakas DE. Symptomatic syringomyelia secondary to clinically obscure infratentorial tumour. *Br J Neurosurg* 2006;20(01):48–50
- 12 Karttunen A, Heikkinen E, Tuominen J, Jartti P. Secondary syringomyelia disappearing after removal of tentorial meningioma. *Acta Neurochir (Wien)* 2002;144(07):741–742