



Chordoma of the Clivus with Metastasis to Femur

Maruf Matmusaev^{1,2} Tetsuya Nagatani² Yugo Kishida² Ahmed Ansari^{3,4}

¹Department of Skull Base Surgery, Republican Specialized Scientific Practical Medical Center of Neurosurgery, Republic of Uzbekistan, Tashkent, Uzbekistan

²Department of Neurosurgery, Center of Neuroendoscopy, Nagoya Daini Red Cross Hospital, Nagoya, Japan

³Department of Neurosurgery, Jawaharlal Nehru Medical College, Aligarh Muslim University, Aligarh, Uttar Pradesh, India

⁴Department of Neurosurgery, Fujita Health University Banbuntane Hospital, Nagoya, Japan

Address for correspondence Maruf Matmusaev, MD, Department of Neurosurgery, Center of Neuroendoscopy, Nagoya Daini Red Cross Hospital, 2-9 Myoken, Showa, Nagoya, 466-8650, Japan (e-mail: marufmatmusayev@gmail.com).

AJNS 2022;17:536–540.

Abstract

Chordomas are aggressive and invasive tumors that are notoriously famous for their recurrence and metastasis. They present with diverse manifestations, usually with lower cranial nerve involvement. Here, we present the first reported case of chondroid chordoma with femur metastasis. A 71-year-old lady presented to us with a headache and diplopia. MRI of the brain revealed an enhanced broad and destructive mass in the infrasellar region with complete destruction of the clivus, right cavernous sinus. She underwent multiple surgeries along with gamma knife and proton therapy. The patient later presented with a trochanteric fracture and needed a hip replacement. Biopsy curettage of the femur lesion revealed a chondroid chordoma of the femur. The patient died later of a chest infection. Multimodality treatment is required in chordoma management, including surgery, gamma knife, and proton therapy. A firm discerning eye is required in the elderly toward metastatic spread to the femur in cases presenting with fractures of long bones.

Keywords

- chordoma
- clivus
- metastasis
- femur

Introduction

Chordomas are rare, mainly extradural, aggressive, invasive, locally destructive bone tumors of the axial skeleton that arise from embryonic remnants of the notochord, and account for approximately 1% of intracranial tumors with a poor prognosis.^{1–3} Also, intradural clival chordomas are extremely rare and have been reported.^{4–6} Chordomas are most often diagnosed in the second or third decade of life.⁷ Chordomas are slow-growing tumors and it usually takes 14 to 24 months from the initial symptoms until diagnosis when the tumor involves nearby neurological structures early in

the course of the disease.⁸ These remnants may appear anywhere along the axial skeleton and are most commonly present in the sacrococcygeal area (50–60%), followed by the clivus/spheno-occipital region (15–35%) and vertebral column (15%).^{7,9,10} Most commonly, the clinical presentation of chordoma is dependent on the tumor's size and anatomical location. Headache, diplopia, and cranial nerve (CN) palsies are the most common symptoms of clival chordoma. Patients may complain of multiple symptoms of lower cranial nerve palsy, such as facial numbness and asymmetry, dysphagia, hoarseness, and speech problems. Large tumors may cause compression of the brainstem and patients may present with

DOI <https://doi.org/10.1055/s-0042-1756629>.
ISSN 2248-9614.

© 2022. Asian Congress of Neurological Surgeons. All rights reserved.

This is an open access article published by Thieme under the terms of the Creative Commons Attribution-NonDerivative-NonCommercial-License, permitting copying and reproduction so long as the original work is given appropriate credit. Contents may not be used for commercial purposes, or adapted, remixed, transformed or built upon. (<https://creativecommons.org/licenses/by-nc-nd/4.0/>)

Thieme Medical and Scientific Publishers Pvt. Ltd., A-12, 2nd Floor, Sector 2, Noida-201301 UP, India

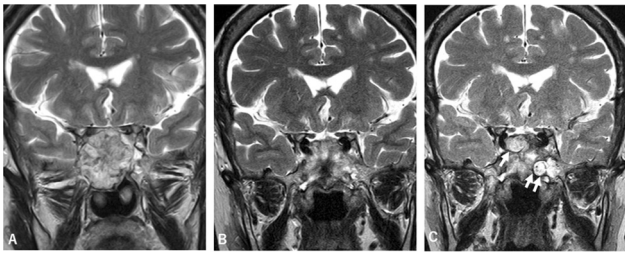


Fig. 1 Preoperative MRI coronal section revealing an enhanced broad and destructive mass in the infrasellar region with the complete destruction of the clivus, and right cavernous sinus involvement (A). MRI of the same patient's brain following 4 months (B) shows the reduced size and local recurrence was seen following 10 months (C).

long tract signs and ataxia. Other rare symptoms of clival chordoma include epistaxis and cerebrospinal fluid (CSF) rhinorrhea.^{11–14} Preoperative diagnosis of chordoma mainly depends on neuroradiology. Radiological imaging such as magnetic resonance imaging (MRI) and computed tomography (CT) of the skull plays an important role in the diagnosis and planning of surgical procedures. Biopsy and immunohistochemistry are critical for diagnosis.^{15,16}

Radical resection of skull base chordomas is not often achieved in many cases due to the anatomy and the involvement of surrounding neurovascular structures such as the internal carotid artery or the cavernous sinus, cranial nerves, and brainstem.⁷ The prognosis and life quality are poor with metastasis and recurrence. The management of chordomas includes surgical resection followed by postoperative radiation therapy and gamma knife surgery. Chemotherapy for chordoma has been proven as an ineffective modality.¹⁷

In this article, we report the first case in the literature of a clival chordoma with femur metastasis. Consent of the

patient's next of kin was taken for the publication of this report for educational purposes.

Case Report

A 71-year-old female patient presented to our neurosurgery department complaining of numbness on the right side of the face and progressively worsening headaches for 3 months. MRI of the brain revealed an enhanced broad and destructive mass in the infrasellar region with the complete destruction of the clivus, right cavernous sinus (→Fig. 1A). The patient underwent endoscopic TSS with subtotal removal. The diagnosis was confirmed with a biopsy result, which showed chondroid chordoma. Prolonged improvement in the patient's condition was seen following surgery, with repeat scans at 4 (→Fig. 1B) and 9 months post-surgery showing the reduced size of the lesion, but 10 months later (→Fig. 1C), the patient was admitted due to local recurrence and, as a result, was operated second time following proton beam treatment in the accompanying month.

Eight months later, the patient was admitted with symptoms pertaining to Rt. III, Lt. XII nerve involvement (right cavernous sinus, dorsum of clivus, left hypoglossal canal). Repeat MRI of the brain revealed an enhanced broad and destructive mass in the infrasellar region with the complete destruction of the clivus, right cavernous sinus, dorsum of clivus, and left hypoglossal canal (→Figs. 2A–C). Endoscopic transsphenoidal surgery was planned and a partial removal of the mass was achieved, followed by treatment with gamma knife. Further, the patient was subjected to radiosurgery (Novalis) therapy for a month. Short-term improvements were seen lasting 2 to 3 months. The patient presented in follow-up with an extradural lesion involving C2, Th1, and 11

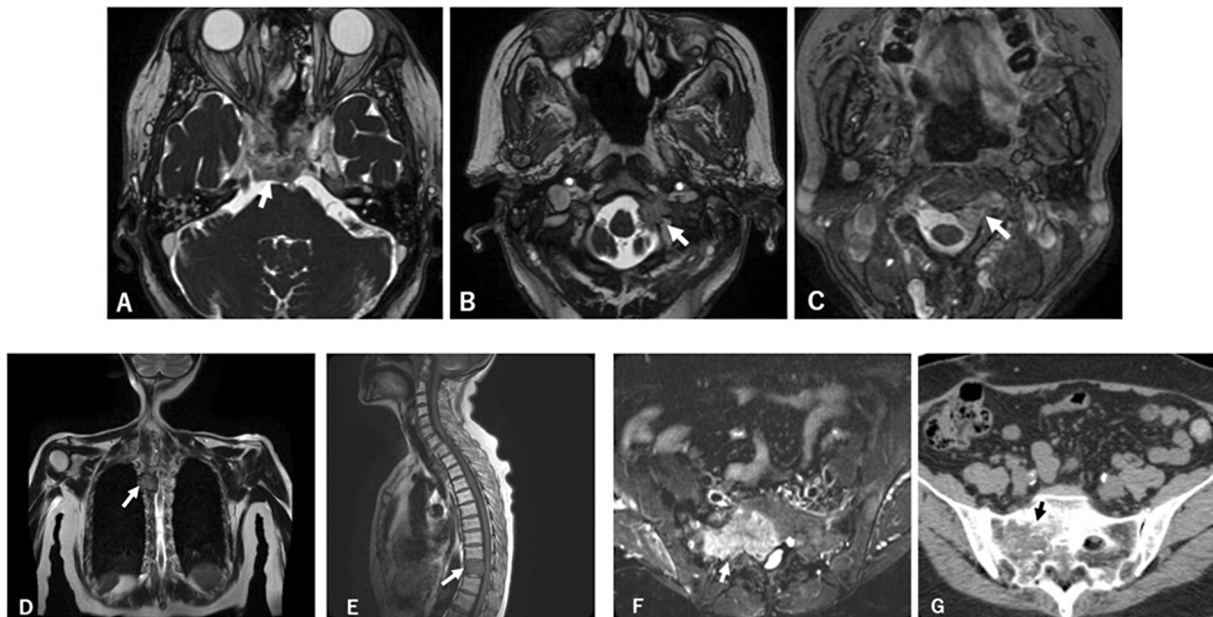


Fig. 2 MR imaging before gamma knife and Novalis. Repeat MRI (A–C) of the brain revealed an enhanced broad and destructive mass in the infrasellar region with the complete destruction of the clivus, right cavernous sinus, and left hypoglossal canal. MR imaging of the spine at the Th1 level reveals extradural lesion with right paravertebral region involvement, displacing the spinal cord to the left side (D), and Th11 lesion of the vertebral body with slight destruction (E). Involvement of the sacrum was also seen (F, G).

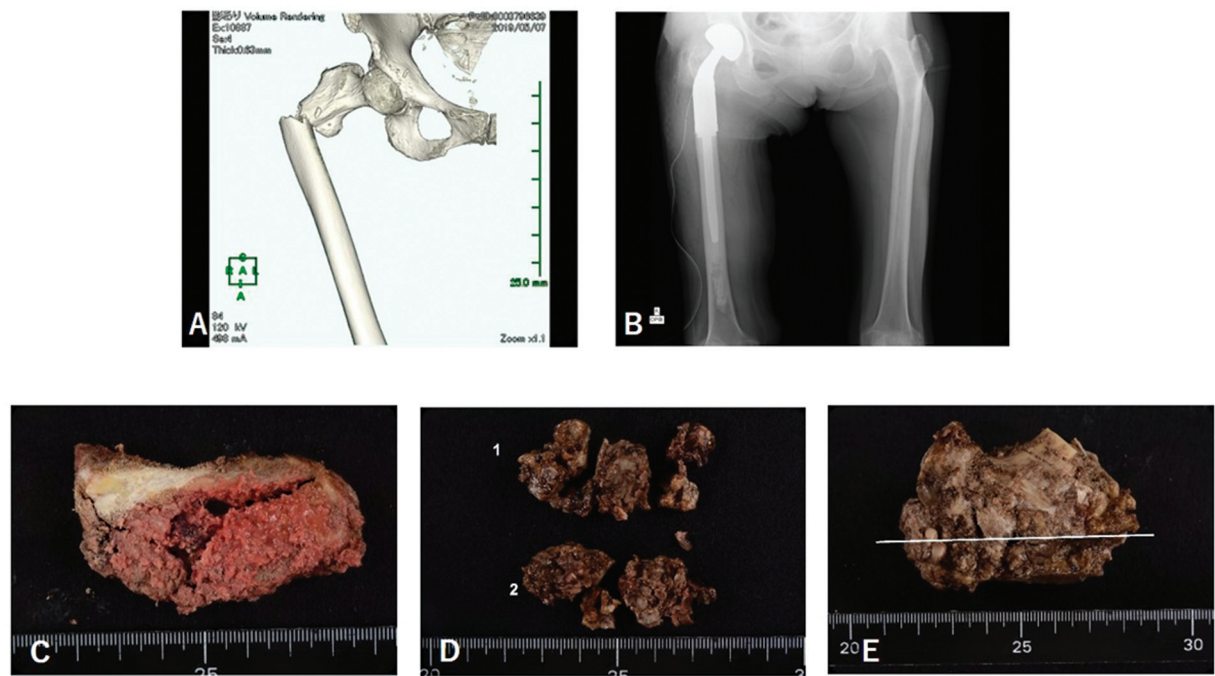


Fig. 3 Macroscopic specimen of the chordoma (A–C) and pathological fracture of the femur with hip replacement (D, E).

vertebrae. Th1 lesion involved the vertebra extradurally and paravertebral region on the right side and was displacing the spinal cord to the left side. Th11 lesion involved vertebra only. Novalis therapy (Th4 to the sacrum) was performed owing to the symptomatology relating to lower limb pain in the patient (►Figs. 2D–G). A couple of weeks later, the patient developed hydrocephalus and a ventriculoperitoneal shunt was performed. Two months later, the patient was admitted to the hospital with a right femoral bone trochanter fracture. Surgery was performed (curettage and dissecting, retraction excision of

tumor, and replacement of the artificial joint) (►Figs. 3A, B). Pathological fracture bone with tumor mass was found during surgery (►Figs. 3C–E). Histopathologically, metastasis from clival chordoma was confirmed (►Figs. 4A–E). One month later, the patient succumbed to a chest infection.

Discussion

The first case of chordoma was described microscopically in 1857 by Virchow.² The most common places of metastases

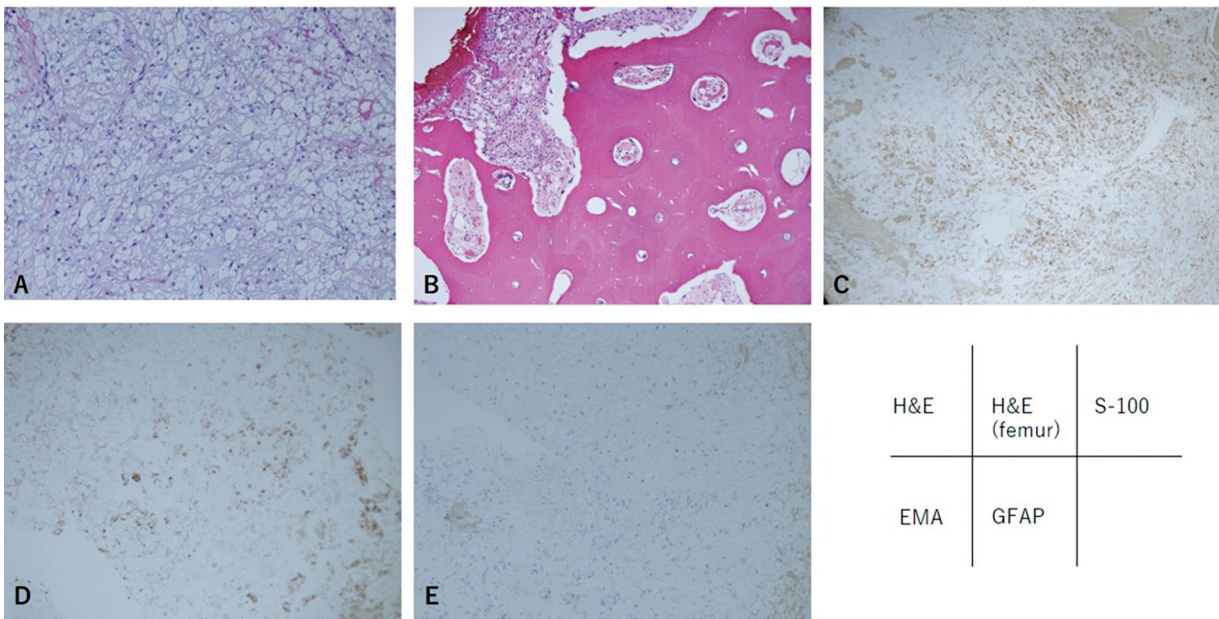


Fig. 4 Various types of physaliferous cells are separated by fibrous septa in a myxoid matrix (A). A dotted cluster of metastasis is found in the femur bone (B). Immunohistochemically, the tissue was strongly positive for S-100 (C), moderately for EMA (D), and negative for GFAP (E).

include the lungs, lymph nodes, liver, bones, skin, muscles, peritoneum, kidneys, and spleen.¹⁵ A few authors have also described metastases to the skin,^{10,11} lymphatics,⁷ heart^{18,19} and abdominal wall but to the best of our knowledge, this is the first case in the literature that reports metastases of a clival chordoma to the femoral bone.

The prognosis and life quality are poor with metastasis and recurrence. The preferred treatment for skull base chordoma is maximum resection, and high-dose radiation therapy offers the best chance for long-term survival.²⁰ Radiotherapy is frequently used in high doses, as chordomas are sometimes resistant to this treatment. Chemotherapy for chordoma has been proven as an ineffective modality.¹⁷ However, the prognosis remains unsatisfactory, with 5-year survival rates of 54 to 79%.²⁰

Clarifying the biological behavior of chordoma is important for proper postoperative management. We used EMA and CAM5.2 staining as epithelial markers, S100 and CD34 for detecting mesenchymal components, and GFAP for astrocytic tumors. Vimentin and cytokeratin were not available in this case and unfortunately, novel marker brachyury was not used. Matsuno et al²¹ studied the immunohistochemical expression of MIB-I, p53, and cyclin D1 in the chordomas of 10 patients, and identified these markers as important predictors of future recurrence. A more recent study using tumor regrowth or recurrence as an outcome measure found that higher Ki67 LI was related to recurrence. Holton et al²² have shown that the tumor doubling time can be assessed using quantitative analysis of tumor volumes on postoperative MRI, correlation of age, sex, histological parameters, and Ki67 labeling index. It was found that increasing patient age, mitotic figures, and a Ki67 labeling index above 6% were three independent factors associated with faster-growing tumors. Ito et al reported that in recurrence of chordoma in 11 patients, tumors with a MIB-1 labeling index of 3.44% or higher showed significantly higher levels of recurrence than tumors with an index lower than 3.44%, representing a lower level than in previous reports.²⁰ Tumors with a high Ki67 labeling index need close follow-ups.

In patients with residual or recurrent chordomas, gamma knife radiosurgery is an exceedingly useful treatment option. The effectiveness of gamma knife radiosurgery depends on having a small-volume tumor and a sufficient marginal dose. We intended to achieve complete remission after the second endonasal surgery, hence proton beam was given to cover the residual. This case was supposed to progress intrathecal seeding and hematogenous metastasis simultaneously. We thought we had no better choice other than Novalis (radio-surgery) therapy to control local bony metastasis in the spinal region. In our previous study, a mean tumor volume of 3.3 mL and a mean marginal dose was 17.8 Gy led to long-term control of tumors.²⁰

Conclusion

Chordomas are aggressive, usually extradural skull base lesions with a plethora of varied symptomatology and treat-

ment options ranging from surgical excision to gamma knife. Metastatic lesions are really hard to manage, with a poor quality of life. Metastasis to the femur further increases the morbidity pertaining to long immobilization in the already frail patient. The Ki67 labeling index can provide important information for predicting tumor recurrence.

Informed Consent

The patient's relatives have consented to the submission of the case report for submission to the journal.

Funding

None.

Conflict of Interest

None declared.

References

- Asano S, Kawahara N, Kirino T. Intradural spinal seeding of a clival chordoma. *Acta Neurochir (Wien)* 2003;145(07):599–603, discussion 603
- Walcott BP, Nahed BV, Mohyeldin A, Coumans JV, Kahle KT, Ferreira MJ. Chordoma: current concepts, management, and future directions. *Lancet Oncol* 2012;13(02):e69–e76
- al-Mefty O, Borba LA. Skull base chordomas: a management challenge. *J Neurosurg* 1997;86(02):182–189
- Ito E, Saito K, Nagatani T, et al. Intradural cranial chordoma. *World Neurosurg* 2010;73(03):194–197, discussion e31
- Warnick RE, Raisanen J, Kaczmar T Jr, Davis RL, Prados MD. Intradural chordoma of the tentorium cerebelli. Case report. *J Neurosurg* 1991;74(03):508–511
- Kim KH. Intradural clival chordoma: a case report. *Brain Tumor Res Treat* 2014;2(02):76–80
- Pamir MN, Kiliç T, Türe U, Ozek MM. Multimodality management of 26 skull-base chordomas with 4-year mean follow-up: experience at a single institution. *Acta Neurochir (Wien)* 2004;146(04):343–354, 354
- Diaz RJ, Cusimano MD. The biological basis for modern treatment of chordoma. *J Neurooncol* 2011;104(02):411–422
- Stacchiotti S, Casali PG, Lo Vullo S, et al. Chordoma of the mobile spine and sacrum: a retrospective analysis of a series of patients surgically treated at two referral centers. *Ann Surg Oncol* 2010;17(01):211–219
- Chugh R, Tawbi H, Lucas DR, Biermann JS, Schuetze SM, Baker LH. Chordoma: the nonsarcoma primary bone tumor. *Oncologist* 2007;12(11):1344–1350
- Alshammari J, Monnier P, Daniel RT, Sandu K. Clival chordoma with an atypical presentation: a case report. *J Med Case Reports* 2012;6:410
- Kitai R, Yoshida K, Kubota T, et al. Clival chordoma manifesting as nasal bleeding. A case report. *Neuroradiology* 2005;47(05):368–371
- Alli A, Clark M, Mansell NJ. Cerebrospinal fluid rhinorrhea secondary to ecchordosis physaliphora. *Skull Base* 2008;18(06):395–399
- Andijani M, Jamjoom A, Tøgersen A, Ram B, Bodkin P, Kamel M. An unusual presentation of clival chordoma: a case report and review of the literature. *Br J Neurosurg* 2020;34(05):549–551
- Sepulveda I, Schmidt T, Ayres G, Vera P, Fredes F. Synchronous infrasellar and cervical chondroid chordoma: a case report and review of the literature. *J Med Cases* 2017;8:127–131
- Erazo IS, Galvis CF, Aguirre LE, Iglesias R, Abarca LC. Clival chondroid chordoma: a case report and review of the literature. *Cureus* 2018;10(09):e3381

- 17 Kim SC, Cho W, Chang UK, Youn SM. Two cases of dedifferentiated chordoma in the sacrum. *Korean J Spine* 2015;12(03):230–234
- 18 Ruiz HA, Goldberg LH, Humphreys TR, Blacklock JB. Cutaneous metastasis of chordoma. *Dermatol Surg* 2000;26(03):259–262
- 19 Prompona M, Linn J, Burdorf L, et al. Pulmonary vein metastasis of a sacral chordoma extending into the left atrial cavity. *J Cardiovasc Med (Hagerstown)* 2009;10(07):557–559
- 20 Ito E, Saito K, Okada T, Nagatani T, Nagasaka T. Long-term control of clival chordoma with initial aggressive surgical resection and gamma knife radiosurgery for recurrence. *Acta Neurochir (Wien)* 2010;152(01):57–67, discussion 67
- 21 Matsuno A, Sasaki T, Nagashima T, et al. Immunohistochemical examination of proliferative potentials and the expression of cell cycle-related proteins of intracranial chordomas. *Hum Pathol* 1997;28(06):714–719
- 22 Holton JL, Steel T, Luxsuwong M, Crockard HA, Revesz T. Skull base chordomas: correlation of tumour doubling time with age, mitosis and Ki67 proliferation index. *Neuropathol Appl Neurobiol* 2000;26(06):497–503