



# Calcifying Pseudoneoplasm of the Neuraxis Presenting with Vasogenic Edema and a Perilesional Cyst

Austin Gamblin<sup>1</sup> Jarom Gropp<sup>1</sup> Vance L. Fredrickson<sup>2</sup> Hedyeh Baradaran<sup>3</sup> William T. Couldwell<sup>3</sup>

<sup>1</sup>School of Medicine, University of Utah, Salt Lake City, Utah, United States

<sup>2</sup>Department of Radiology, University of Utah, Salt Lake City, Utah, United States

<sup>3</sup>Department of Neurosurgery, Clinical Neurosciences Center, University of Utah, Salt Lake City, Utah, United States

**Address for correspondence** William T. Couldwell, MD, PhD, Department of Neurosurgery, Clinical Neurosciences Center, University of Utah, 175 N. Medical Drive East, Salt Lake City, UT 84132, United States (e-mail: neuropub@hsc.utah.edu).

AJNS 2022;17:507–510.

## Abstract

### Keywords

- ▶ calcifying pseudoneoplasms
- ▶ case report
- ▶ CAPNON
- ▶ microsurgery
- ▶ perilesional cyst
- ▶ vasogenic edema

Calcifying pseudoneoplasms of the neuraxis (CAPNONS) are uncommon benign lesions that are rarely diagnosed radiographically. We report an unusual case of a left middle cerebellar peduncle CAPNON with vasogenic edema and a perilesional cyst. The patient was a 36-year-old woman with a 20-year history of left-sided hearing loss that had recently progressed. Computed tomography and magnetic resonance imaging showed a heterogenous calcified lesion with vasogenic edema and a perilesional cyst in the left middle cerebellar peduncle. Although it is a rare radiographic feature of CAPNON, vasogenic edema should be included as a possible feature of this uncommon tumefactive lesion.

## Key Messages

CAPNONS are rare benign tumefactive lesions that occur at any point in the neuraxis. The prevalence is likely underreported because of challenging diagnostic features. Vasogenic edema is an uncommon radiographic feature that may be underreported. A perilesional cyst may represent a new radiographic presentation of this disease. Both of these things in conjunction with calcified heterogeneous lesions should cause one to consider CAPNON as a diagnosis.

## Introduction

Calcifying pseudoneoplasms of the neuraxis (CAPNONS) are rare, slow-growing, tumefactive, fibro-osseous lesions that

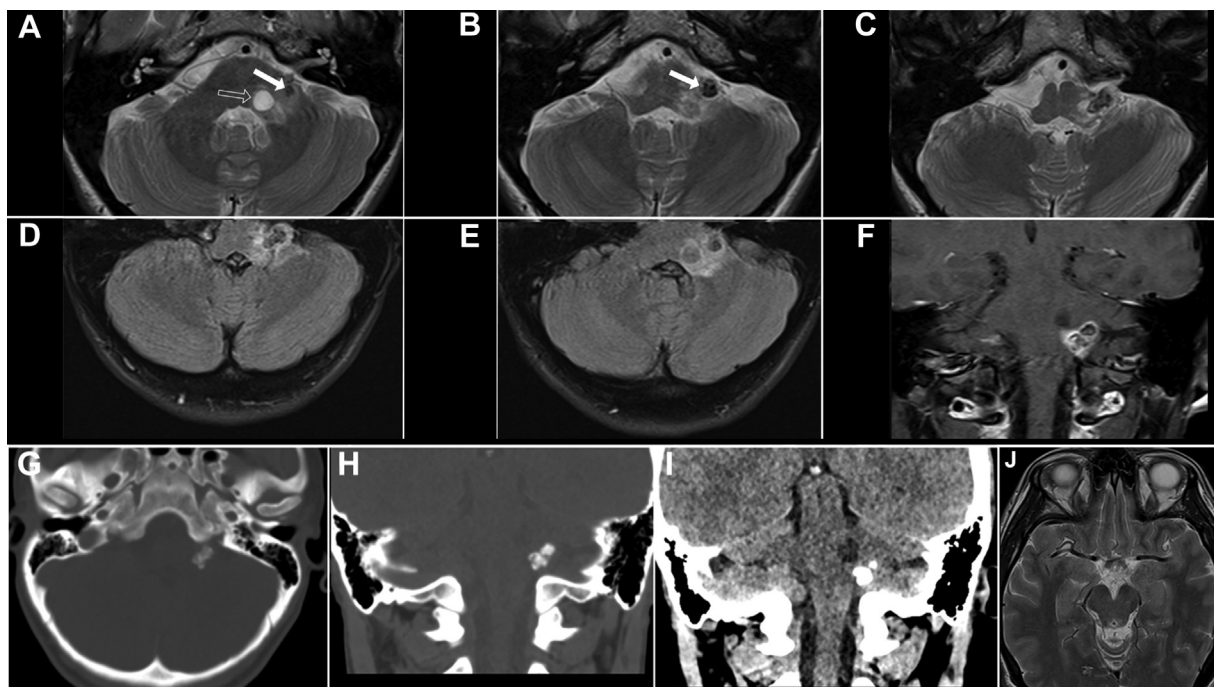
can occur throughout the entire neuraxis.<sup>1</sup> Despite being first described by Rhodes and Davis<sup>2</sup> in 1978, fewer than 150 cases of CAPNON have been reported.<sup>3</sup> Although the lesion pathogenesis remains unknown, recent hypotheses favor a reactive proliferative process over degenerative, metaplastic, neoplastic, or metabolic processes.<sup>1,4</sup> The clinical presentations of these lesions vary, depending on the location, size, and associated mass effect.<sup>1,5–8</sup> Although CAPNONS are typically definitively diagnosed histopathologically postresection,<sup>9</sup> radiographic imaging is an important part of the workup. Vasogenic edema is a rare feature on magnetic resonance imaging (MRI), and concurrent perilesional cysts have not been reported in the literature. Herein, we present a case illustrating both radiographic features.

DOI <https://doi.org/10.1055/s-0042-1756628>.  
ISSN 2248-9614.

© 2022. Asian Congress of Neurological Surgeons. All rights reserved.

This is an open access article published by Thieme under the terms of the Creative Commons Attribution-NonDerivative-NonCommercial-License, permitting copying and reproduction so long as the original work is given appropriate credit. Contents may not be used for commercial purposes, or adapted, remixed, transformed or built upon. (<https://creativecommons.org/licenses/by-nc-nd/4.0/>)

Thieme Medical and Scientific Publishers Pvt. Ltd., A-12, 2nd Floor, Sector 2, Noida-201301 UP, India



**Fig. 1** Initial imaging (A–C). Axial T2 magnetic resonance imaging (MRI) of heterogeneously T2 hypointense mass (arrows) with perilesional cyst (arrowhead) in left middle cerebellar peduncle near CN7–8 complex root entry zone. C. Exophytic part of mass extends inferiorly near CN9–11 root entry zones. (D, E) Axial T2 fluid attenuated inversion recovery shows vasogenic edema. (F) Coronal T1 MRI shows heterogeneous enhancement. (G–I) Noncontrast computed tomography of calcified mass and low-density cyst near calcification. (J) Axial T2 MRI of centrally hyperintense and peripherally hypointense 6-mm lesion in right occipital lobe, consistent with cavernous malformation.

## Case History

A 36-year-old previously healthy woman presented with a 20-year history of left-sided hearing loss that had progressed acutely over the past year. She also had aspiration events while drinking thin liquids. She denied vestibular symptoms, motor problems, or any other symptoms.

On examination, she had significant hearing loss on the left side but was otherwise neurologically intact. After clinical evaluation, she underwent MRI of the internal auditory canal to evaluate her sensorineural hearing loss, which revealed a heterogeneously enhancing solid and cystic lesion centered within the left middle cerebellar peduncle with surrounding vasogenic edema. Furthermore, the mass had areas of profound T2 hypointensity. The lesion involved the root entry zone of the left seventh and eighth cranial nerves, which accounted for her sensorineural hearing loss. Initial differential considerations for the mass included cavernous malformation and choroid plexus papilloma, with other lesions (such as hemangioblastoma, schwannoma, or metastasis) considered less likely (►Fig. 1). On subsequent computerized tomography (CT) scan of the head, the mass was found to have dense calcifications (►Fig. 1), a hallmark of CAPNON. A second lesion in the right occipital lobe stump was also seen, with imaging features consistent with a 6-mm cavernous malformation (►Fig. 1).

Given the size, symptomatic progression, and proximity of other cranial nerves, the patient elected to undergo resection of the lesion. She underwent an uncomplicated left retrosigmoid suboccipital craniectomy with microsurgical re-

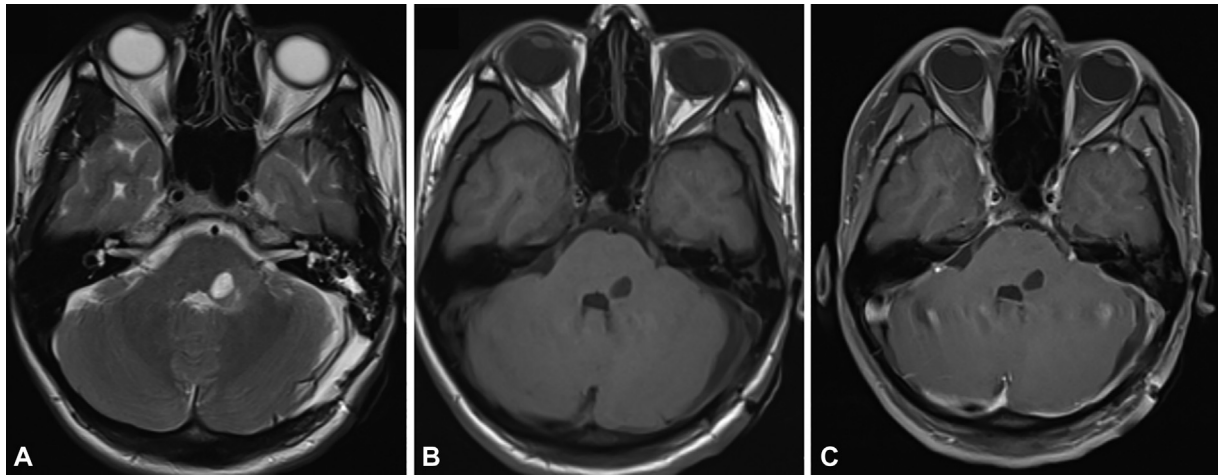
moval of the lesion. Of note, the lesion grossly appeared cystic and calcified.

The patient's postoperative recovery was uneventful, and follow-up imaging with MRI demonstrated complete resection of the lesion (►Fig. 2). Although no new deficits were noted, the patient's sensorineural hearing loss did not improve after resection.

Pathologic analysis revealed abundant dystrophic calcification, some appearing granular and others fibrillary. The islands of calcification were surrounded by layers of plump, moderately hyperchromatic cells. Ossification was present in some regions. The matrix of the lesion displayed somewhat spindled areas of moderate hypercellularity (►Fig. 3).

## Discussion

CAPNONs are rare benign pseudotumors that can affect any part of the neuraxis, including the brain, spinal cord, meninges, and adjacent tissues.<sup>10</sup> Although rare, these lesions may be underreported because of a lack of awareness of this pathology, the asymptomatic nature of some lesions, collision with other lesions, and diagnostic challenges on neuroimaging and histopathology.<sup>3,11</sup> Of the fewer than 150 cases reported in the literature, most have been found intracranially (57–63%) and present with headaches, seizures, and cranial nerve deficits; spinal lesions can cause pain, radiculopathy, and myelopathy.<sup>7</sup> Their presentation largely depends on their location and associated mass effect on surrounding structures.



**Fig. 2** (A–C) Postoperative magnetic resonance imaging demonstrates expected postoperative changes without evidence of residual enhancing mass. There is a persistent cystic structure in the left middle cerebellar peduncle.

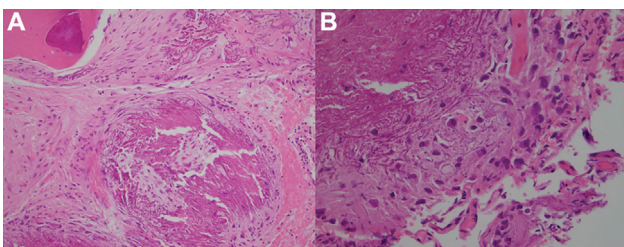
Radiographic diagnosis of CAPNON is challenging because the nonspecific imaging findings mimic other lesions such as meningiomas, cavernomas, astrocytomas, gangliomas, dysembryoplastic neuroepithelial tumors, oligodendromas, neurocysticercosis, and toxoplasmosis. On CT, CAPNON appears grossly calcified. On MRI, the lesion is often hypointense on T1 and T2 secondary to calcification, with little-to-moderate internal and rim enhancement. Margins are usually smooth but can be lobulated.<sup>11</sup> They can appear intra-, trans-, and extradural. Although vasogenic edema is an uncommon radiographic feature, there are four reported cases of vasogenic edema at the time of disease progression and in more symptomatic patients.<sup>3,11–13</sup>

On histopathological analysis, CAPNONS are typically well-circumscribed masses with variable morphologic features including a chondroid matrix with fibrillary to amorphous architecture, fibrous stroma, peripheral “ropey” cords, and a ring of palisading spindled to epithelioid to multinucleated giant cells. They may also display multifocal calcifications, metaplastic mature bone, metaplastic mature adipose, or psammoma bodies.<sup>14–16</sup> The presence of each

feature varies widely between individual lesions.<sup>17</sup> Cells along the periphery of the core display variable epithelial membrane antigen staining while granular amorphous cores stain positive for neurofilament-light.<sup>9,18</sup> Our findings were concordant with the classic features of a CAPNON. Although vasogenic edema was described clinically and radiographically, there was no evidence of it microscopically.

The presence of collision lesions, or the coexistence of two histologically distinct lesions within the same anatomic site, has been recognized to occur with CAPNONS,<sup>3,4,19,20</sup> but perilesional cysts have not been reported in the literature. This perilesional cyst, persistent on repeat imaging, may be one of those lesions. The pathogenesis of this lesion is unclear and may be a result of the remote insult, a product of cerebrospinal fluid trapping, or a result of the vasogenic edema. Co-occurrence of CAPNONS with other lesions may support the theory that pathogenesis is related to a distorted healing of inflammatory process.<sup>3,4</sup>

Asymptomatic lesions can be managed conservatively. Treatment of CAPNONS with complete resection has been attempted in most reported cases and has a high rate of cure,<sup>3</sup> with only six cases of recurrence reported in the literature.<sup>15,18,21–24</sup> Resection of CAPNONS at the skull base can be limited by adherence to cranial nerves and poses a risk of new deficit on resection. Serial imaging can be used to confirm resection and, in rare cases of symptom progression, to monitor for recurrence.



**Fig. 3** Histopathologic analysis revealed abundant dystrophic calcifications, some appearing granular and others fibrillary. The islands of calcification were surrounded by layers of plump, moderately hyperchromatic cells. Rare areas of ossification were present. The matrix of the lesion displayed somewhat spindled areas of moderate hypercellularity. Vessels were present but appeared normal. (A) An island of calcification rimmed by a layer of spindled cells. Note the osseous metaplasia in the top left corner. (B) Hyperchromatic spindled cells surrounding a calcified core.

#### Informed Consent

Written consent was provided by the patient for this case report.

#### Funding

None.

#### Conflict of Interest

None declared.

**Acknowledgment**

We thank Kristin Kraus for editorial support and Vance Mortimer for support with images.

**References**

- 1 Ho ML, Eschbacher KL, Paolini MA, Raghunathan A. New insights into calcifying pseudoneoplasm of the neuraxis (CAPNON): a 20-year radiological-pathological study of 37 cases. *Histopathology* 2020;76(07):1055–1069
- 2 Rhodes RH, Davis RL. An unusual fibro-osseous component in intracranial lesions. *Hum Pathol* 1978;9(03):309–319
- 3 Yang K, Reddy K, Chebib I, Hammond R, Lu JQ. Calcifying pseudoneoplasm of the neuraxis (CAPNON): from pathogenesis to diagnostic and therapeutic considerations. *World Neurosurg* 2021;148:165–176
- 4 Lu JQ, Popovic S, Provias J, Cenic A. Collision lesions of calcifying pseudoneoplasm of the neuraxis and rheumatoid nodules: a case report with new pathogenic insights. *Int J Surg Pathol* 2021;29(03):314–320
- 5 Ghaemi J, Wasimi M, Siripurapu R, et al. Calcifying pseudoneoplasm of the neuraxis (CaPNoN): an unusual cause of third nerve palsy in a teenager. *BJR Case Rep* 2016;2(03):20150494
- 6 Lopes AJ, Brock RS, Martins TG, et al. Intradural calcifying pseudoneoplasm of the neuraxis presenting as a cauda equina syndrome. *Surg Neurol Int* 2016;7(Suppl 42):S1102–S1105
- 7 Vallejo FA, Chen SH, Bano G, Gultekin S, Morcos J. Calcifying pseudoneoplasm of the neuroaxis presenting with refractory seizures: case report and literature review. *J Clin Neurosci* 2020;78:439–443
- 8 Wiśniewski K, Janczar K, Tybor K, Papierz W, Jaskólski DJ. Calcifying pseudoneoplasm of the foramen magnum—case report and review of the literature. *Br J Neurosurg* 2015;29(06):891–893
- 9 Yang K, Reddy K, Wang BH, et al. Immunohistochemical markers in the diagnosis of calcifying pseudoneoplasm of the neuraxis. *Can J Neurol Sci* 2021;48(02):259–266
- 10 Fletcher AM, Greenlee JJ, Chang KE, Smoker WR, Kirby PA, O'Brien EK. Endoscopic resection of calcifying pseudoneoplasm of the neuraxis (CAPNON) of the anterior skull base with sinonasal extension. *J Clin Neurosci* 2012;19(07):1048–1049
- 11 Barber SM, Low JCM, Johns P, Rich P, MacDonald B, Jones TL. Calcifying pseudoneoplasm of the neuraxis: a case illustrating natural history over 17 years of radiologic surveillance. *World Neurosurg* 2018;115:309–319
- 12 Conway KS, Jentzen J, Pratt D, Camelo-Piragua S. Sudden death due to calcifying pseudoneoplasm of the neuraxis: a case report and a review of sudden death due to undiagnosed central nervous system mass lesions. *Am J Forensic Med Pathol* 2020;41(01):70–74
- 13 Brasiliense LB, Dickson DW, Nakhleh RE, Tawk RG, Wharen R. Multiple calcifying pseudoneoplasms of the neuraxis. *Cureus* 2017;9(02):e1044
- 14 Hubbard M, Qaiser R, Clark HB, Tummala R. Multiple calcifying pseudoneoplasms of the neuraxis. *Neuropathology* 2015;35(05):452–455
- 15 Bertoni F, Unni KK, Dahlin DC, Beabout JW, Onofrio BM. Calcifying pseudoneoplasms of the neural axis. *J Neurosurg* 1990;72(01):42–48
- 16 Qian J, Rubio A, Powers JM, et al. Fibro-osseous lesions of the central nervous system: report of four cases and literature review. *Am J Surg Pathol* 1999;23(10):1270–1275
- 17 Aiken AH, Akgun H, Tihan T, Barbaro N, Glastonbury C. Calcifying pseudoneoplasms of the neuraxis: CT, MR imaging, and histologic features. *AJNR Am J Neuroradiol* 2009;30(06):1256–1260
- 18 Yang K, Reddy K, Ellenbogen Y, Wang BH, Bojanowski MW, Lu JQ. Skull base calcifying pseudoneoplasms of the neuraxis: two case reports and a systematic review of the literature. *Can J Neurol Sci* 2020;47(03):389–397
- 19 Paolini MA, Ho ML, Monahan HR, Raghunathan A. Supratentorial CAPNON associated with WHO grade II meningioma: a case report. *Neuropathology* 2018;38(05):535–538
- 20 Inukai M, Shibahara I, Hotta M, et al. Case of calcifying pseudoneoplasms of the neuraxis coexisting with interhemispheric lipoma and agenesis of the corpus callosum: involvement of infiltrating macrophages. *World Neurosurg* 2020;134:635–640.e1
- 21 Watanabe A, Nakanishi K, Kataoka K, Wakasa T, Ohta Y. Regrowth and progression of multiple calcifying pseudoneoplasms of the neuraxis: case report. *Surg Neurol Int* 2018;9:243
- 22 Higa N, Yokoo H, Hirano H, et al. Calcifying pseudoneoplasm of the neuraxis in direct continuity with a low-grade glioma: a case report and review of the literature. *Neuropathology* 2017;37(05):446–451
- 23 Chang H, Park JB, Kim KW. Intraosseous calcifying pseudotumor of the axis: a case report. *Spine* 2000;25(08):1036–1039
- 24 Fetsch JF, Montgomery EA, Meis JM. Calcifying fibrous pseudotumor. *Am J Surg Pathol* 1993;17(05):502–508