



The Treatment of Linear and Narrow Scar after Craniotomy Using the Follicular Unit Excision

Hiromi Okochi, MD, PhD¹ Masamitsu Onda, MD, PhD² Akira Momosawa, MD, PhD¹
Masayuki Okochi, MD, PhD¹

¹Department of Plastic and Reconstructive Surgery, Yamanashi University, Kofu, Yamanashi, Japan

²Shinwa Clinic, Tokyo, Japan

³Department of Plastic and Reconstructive Surgery, Teikyo University, Itabashi City, Tokyo, Japan

Address for correspondence Masayuki Okochi, MD, PhD, 2-11-1 Kaga, Itabashi, Tokyo, Japan (e-mail: oktms-okt@galaxy.ocn.ne.jp).

Arch Plast Surg 2022;49:704–709.

Abstract

Background The scar alopecia after cranioplasty (SAC) may decrease the patient's quality of life. We have treated SAC using follicular unit extraction (FUE). The aim of this study was to discuss that efficacy of FUE and how much hair follicular unit (FU) should be transplanted intraoperatively for the treatment of SAC.

Methods We treated 10 patients (4 men and 6 women) who had SAC using FUE.

Results The average age, alopecia size, and intraoperative hair density on the graft area were 29.8 ± 12.1 years, $29.8 \pm 44.5 \text{ cm}^2$, and $34.6 \pm 11.8 \text{ FU/cm}^2$, respectively. One year postoperatively, the average hair survival rate on the graft area was $66.3 \pm 6.1\%$. Hair appearance was rated as good in six, fair in three, and poor in one. Among patients whose 1-year postoperative hair density was $\geq 20 \text{ FU/cm}^2$, five of six patients achieved good results. However, among patients whose 1-year postoperative hair density was $< 20 \text{ FU/cm}^2$, all four patients achieved fair or poor results. The postoperative hair density was significantly higher in patients whose 1-year postoperative hair density was $\geq 20 \text{ FU/cm}^2$ than in patients whose 1-year postoperative hair density was $< 20 \text{ FU/cm}^2$. The rate of achieving fair or poor results was significantly higher if the postoperative hair density was $< 20 \text{ FU/cm}^2$ than if it was $\geq 20 \text{ FU/cm}^2$ ($p = 0.047$).

Conclusions FU excision is useful for the treatment of scar alopecia after craniotomy. Our results suggest that the 1-year postoperative hair density should exceed 20 FU/cm^2 to achieve good outcomes.

Keywords

- hair restoration
- craniotomy
- scar alopecia
- follicular unit extraction

Introduction

Coronal incisions (CIs) were first introduced by Hartley and Kenyon and have been widely used by neurosurgeons and maxillofacial surgeons for approaches to the cranial and

midfacial bone.^{1–7} Despite their usefulness, acute and delayed complications after CIs have been reported.^{5–7} The acute complications included hematoma, infection, and wound dehiscence.⁶ Scar alopecia is a delayed complication.^{5,6} Alopecia

received

December 7, 2021

accepted after revision

June 9, 2022

DOI <https://doi.org/10.1055/s-0042-1756286>.

eISSN 2234-6171.

© 2022. The Korean Society of Plastic and Reconstructive Surgeons. All rights reserved.

This is an open access article published by Thieme under the terms of the Creative Commons Attribution-NonDerivative-NonCommercial-License, permitting copying and reproduction so long as the original work is given appropriate credit. Contents may not be used for commercial purposes, or adapted, remixed, transformed or built upon. (<https://creativecommons.org/licenses/by-nc-nd/4.0/>)

Thieme Medical Publishers, Inc., 333 Seventh Avenue, 18th Floor, New York, NY 10001, USA

along scars affects the patients' external appearance. Novel incision shapes and surgical tools have been proposed to decrease scar alopecia; however, narrow and linear scarring occurs, which is unacceptable, especially to young patients. In some cases, such complications may decrease satisfaction with surgery.

Since Rassman et al first introduced follicular unit excision (FUE) in 2002,⁸ it has become a popular hair restoration surgery for androgenic alopecia.⁹ FUE has less associated scarring than other hair transplantation procedures. In this study, we treated scar alopecia after craniotomy using FUE. Herein, we describe our surgery and postoperative results in detail. The aim of this study was to discuss how many intraoperative hair densities should be exceeded to achieve good result.

Methods

Patients

We retrospectively analyzed our medical records and photos. The study was composed of patients who had received FUE for the treatment of scar alopecia after craniotomy in Shinwa Clinic between August 2016 and July 2020. Patients with diabetes or endocrine diseases were excluded, leaving nine patients (four men and five women). The average age and size of alopecia were 29.8 ± 12.8 years and 9.5 ± 4.1 cm², respectively (►Table 1).

Surgical Procedure

All surgical procedures were performed more than 1 year after craniotomy. FUE was performed under local anesthesia using 1% lidocaine solution. While harvesting the FUs, patients were placed in the prone position. The hair FUs were harvested from the occipital region of the scalp using a motorized punch (0.85 mm; Shinwa Clinic, Tokyo, Japan).

After harvesting the FUs, a motorized punch (0.63 mm; Shinwa Clinic) was used to make recipient holes. Then, the FUs were inserted into the recipient holes using a pneumatic implanter. Two days after surgery, the patients were allowed to wash their hair themselves.

Postoperative Evaluation

The postoperative results were evaluated 1 year after surgery by two hair transplant surgeons. The results were divided into three groups according to the degree of improvement of the patient's external appearance (good, fair, and poor). In the good group, the external appearance was improved, and scar alopecia was camouflaged. In the fair group, the external appearance was slightly improved, but scar alopecia was quite visible. In the poor group, the external appearance was not improved, and scar alopecia was quite visible. Next, patients were divided into two groups according to their 1-year postoperative hair density (low density (LD): hair density < 20 FU/cm², high density (HD): hair density \geq 20 FU/cm²), and the proportion of patients whose 1-year postoperative result was good was compared between the two groups.

Statistical Analysis

Average values of intraoperative hair density and survival rate were compared between the LD and HD groups using the Mann-Whitney *U* test. Fisher's exact test was used for comparing the proportion of patients with good results between the HD and LD groups. The significance threshold was set at 5% ($p < 0.05$). All statistical analyses were performed using Excel statistics (Bell Curve, Tokyo, Japan).

Results

The reasons for craniotomy were traffic accidents in seven cases, congenital deformity in two cases, and moyamoya

Table 1 Information of patients

Case	Age	M/F	Transplanted hair (FU)	Transplanted area (cm ²)	Intraoperative hair density	Survival rate	One year postop hair density	Cause of cranioplasty	Result
1	42	M	340	9.0 × 1.5	25.2	67.5	17	Traffic accident	Fair
2	12	F	200	10.0 × 0.5	40.0	72.5	29	Traffic accident	Good
3	21	F	350	9 × 1.0	38.9	56.6	22	Traffic accident	Good
4	23	F	100	15.0 × 0.5	14.3	77.0	11	Traffic accident	Poor
5	33	M	800	28.0 × 0.5	57.1	61.3	35	Cranial deformity	Good
6	18	M	250	22.0 × 0.5	22.7	70.4	16	Cranial deformity	Fair
7	52	F	130	6.5 × 0.5	40.0	62.5	25	Moyamoya disease	Good
8	28	F	100	10 × 0.3	33.3	69.0	23	Traffic accident	Good
9	30	F	150	9 × 0.6	37.1	62.0	17	Traffic accident	Fair
10	39	M	150	4.0 × 1.0	37.5	64.0	24	Traffic accident	Good
Average ± SD	29.8 ± 12.1		257.0 ± 211.3	29.8 ± 44.5	34.6 ± 11.8	66.3 ± 6.1	21.9 ± 7.0		

Abbreviations: F, female; FU, follicular unit; M, male; SD, standard deviation.

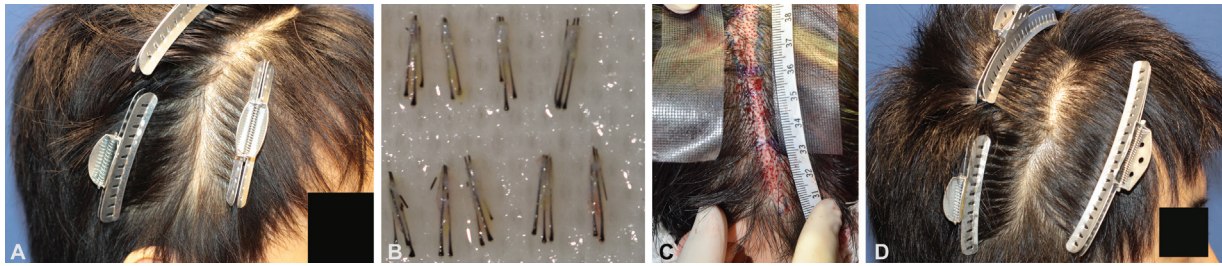


Fig. 1 (A) Preoperative view. Patients received cranioplasty 8 years ago. The width of the scar was 5 mm. (B) Intraoperative view. Follicular units were harvested from the occipital region of the scalp. (C) Intraoperative view of surgical site. After harvesting the hair follicular units (FUs), a 0.63-mm motorized punch was used to make recipient holes. FUs were transplanted into the recipient holes. (D) Postoperative view. One year after surgery, the appearance of the scalp was improved. The final result was categorized as excellent.

disease in one case. The average number of grafted FUs was 257.0 ± 211.3 FUs, and the intraoperative density was 34.6 ± 11.8 FU/cm². The FU survival rate was $66.3 \pm 6.1\%$. One-year postoperative hair density was 21.9 ± 7.0 FU/cm². The results for external appearance were good in 6, fair in 3, and poor in 1 (►Table 1). In the HD group, intraoperative hair density and survival rate were 41.1 ± 7.5 FU/cm² and $64.3 \pm 5.2\%$. In the LD group, intraoperative hair density and survival rate were 24.8 ± 9.4 FU/cm² and $69.2 \pm 6.2\%$. Intraoperative density was significantly higher in the HD group than the LD group ($p = 0.025$). The proportion of patients reporting good result was also significantly higher in the HD group than the LD group ($p = 0.047$). On the other hand, there was no significant difference in the survival rate between the two groups ($p = 0.286$) (►Table 2).

Case Presentation

Case 1

A 12-year-old female patient received craniotomy due to a traffic accident 9 years ago. Despite a scar revision performed at another hospital 3 years ago, a linear scar remained (►Fig. 1A). She was referred to our clinic for the treatment of her scalp alopecia. The size of the scar was 10×0.5 cm. FUs were harvested from the occipital region of the scalp (►Fig. 1B). A recipient hole was made (►Fig. 1C), and then 200 FUs (40 FU/cm²) were grafted. One year after the operation, the patient's external appearance had improved well (►Fig. 1D). The survival rate of FUs was 72%. The patient was satisfied with the postoperative result, and we categorized her postoperative result as good.

Case 2

A 52-year-old female patient received bypass surgery due to moyamoya disease 2 years ago. She was referred to our clinic for alopecia treatment (►Fig. 2A). The patient had a 19×0.5 cm mature scar at the temporal region of her scalp. Although the scar was long and visible, she only wanted to treat a 6.5-cm portion of the scar from the hairline. One year or more after the operation, FUE was performed. The recipient hole was made, and then 130 FUs (40 FU/cm²) were grafted. One year after the operation, the FUs that had been transferred from the occipital region were able to cover the scar alopecia (►Fig. 2B). The survival rate of FUs was 62%, and

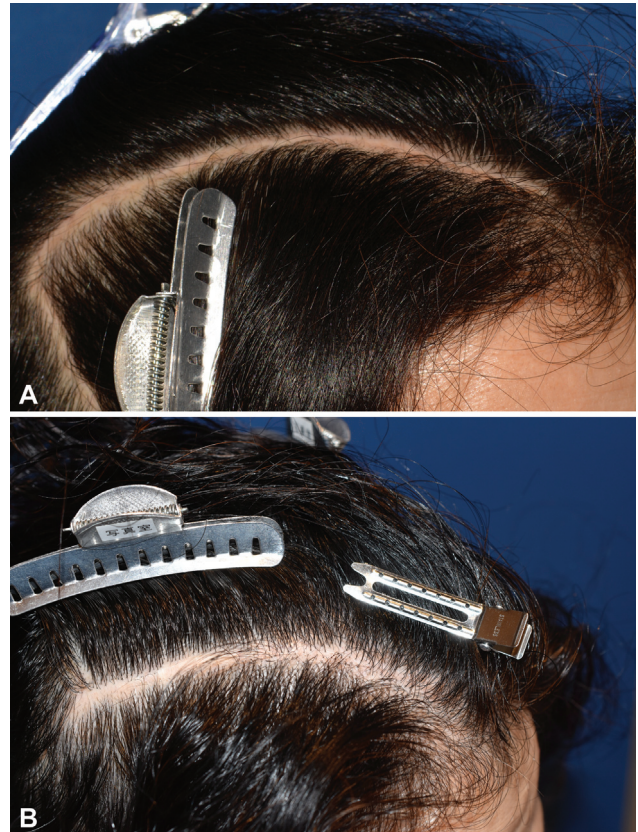


Fig. 2 (A) Preoperative view of case no. 2. The patient had a 19×0.5 cm mature scar at the temporal region of the scalp after bypass surgery due to moyamoya disease. The patient asked for treatment of the scar 6.5 cm from the hairline. (B) One year after the operation of case no. 2. The differences between surgical and nonsurgical sites were observed. The patient was satisfied with the postoperative result. We categorized her postoperative result as excellent.

the patient was satisfied with the postoperative result. We categorized her postoperative result as good.

Case 3

An 18-year-old male patient received craniotomy due to Crouzon disease 14 years ago. He was referred to our clinic because a 22.0×0.5 cm mature scar remained on his scalp (►Fig. 3A). One year after transferring 250 FUs to the scar (22.3 FU/cm²), the survival rate of grafted FUs was 70%. However, the

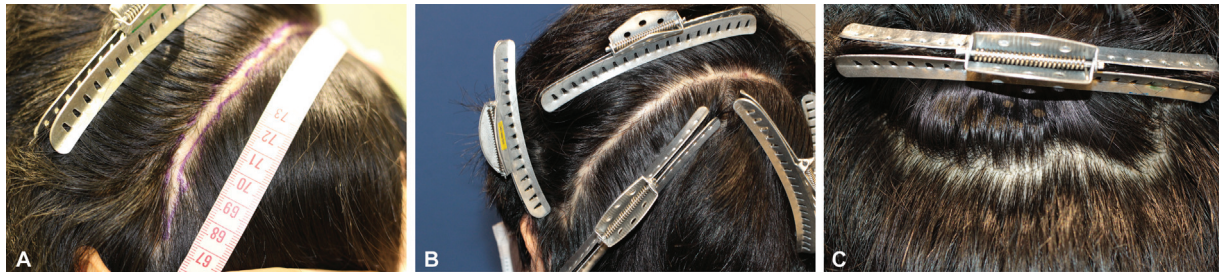

Fig. 3 (A) Preoperative view of case no. 3. The patient received coronal incision due to Crouzon disease 14 years ago. He was referred to our clinic because a 22.0×0.5 cm mature scar was left on his scalp. Two hundred and fifty follicular units were transferred to the scar (22.3 FU/cm^2). (B) One year after the operation of case no. 3. The survival rate of the grafted follicular units (FUs) was 70%. The patient did not feel any improvement in the external appearance. We categorized his postoperative result as fair. (C) The donor site of case no. 3. Scar was not visible. Even after brushing his hair.

patient did not feel that the external appearance had improved (►Fig. 3B). We categorized his postoperative result as fair.

Discussion

We found that FUE can improve the external appearance of narrow-scar alopecia after craniotomy. Used by neurosurgeons and maxillofacial surgeons, CIs are useful; however, 0.4 to 18%^{2,5} patients who had received CI developed scar alopecia postoperatively. We can avoid wide and visible scar alopecia on the scalp by making the incision parallel to the long axis of the hair follicles,¹⁰ and the incision line should be straight rather than zigzag.^{10,11} Subcutaneous sutures should be placed on the galea to decrease tension, and superficial sutures should not injure hair follicles.¹⁰ Nitta et al reported that electrocautery skin incision is effective because it has little associated blood loss from the skin incision and can possibly avoid alopecia caused by skin clips.^{12,13}

A tissue expander is a useful therapeutic alternative to treat wide and visible scarring on the scalp.^{14,15} Several authors have reported the use of a V-Y advancement flap,¹⁶ Z plasty,¹⁷ and a hair-bearing flap¹⁸ to treat scar alopecia. Burm and Oh reported the treatment procedure of a wide scar.¹⁹ In their report, incisions were placed at a 30-degree angle, the relax incision was made on the galea, and relaxation sutures were placed on the galea. These procedures made it possible to decrease the size of scar alopecia. However, there was a limitation to decreasing the scar width, and additional alopecia was related to the additional incisions in some procedures. Even though scar alopecia is narrow and linear, some patients are not satisfied with their alopecia.

The FUE^{8,9} and follicular unit transfer (FUT) procedures^{20,21} are effective for adults with androgenic alopecia. And the success of FUE and FUT hair transplantation procedures for burn scars or operative scars has been also reported recently.^{21–27} In our cases, the average intraoperative hair density was $34.6 \pm 11.8 \text{ FU/cm}^2$. There are no guidelines regarding how much FUs should be transplanted for scar tissue. The literature reports an average hair density of 20 to 36.2 FU/cm^2 and the survival rate of FUs as 78.9 to 80.7% for the treatment of scar alopecia.^{23,25} Previous studies have

reported that the survival rate of FUs for the normal scalp is 80 to 90%,²⁸ which means the survival rate of FUs for scars is lower than that for the normal scalp. The reason for low survival rate of hair follicle in scar was not still elucidated, the tissue oxygen level of scar tissue is lower than in the normal skin^{29–31} and blood circulation is also less than intact skin.³² These conditions may decrease the survival rate of hair follicular in the scar tissue.

Loganathan et al and Salanitri et al presented surgical result and postoperative complications of FUT.^{20,21} In their report, no severe bleeding and infection were observed. It is reported that there was no differences of postoperative survival rate of grafted hair for scar tissue between FUT and FUE.³³ However, donor site of hair follicular unit should be closed directly in FUT and 1.9%²¹ to 15%²⁰ of patients had scar enlargement, postoperatively. Although they did not define the width of wide scar, their result suggested not small number of patients may have a scar alopecia on donor site. On the other hand, postoperative scars at the donor site were invisible when FUE was applied (►Fig. 3C). We have treated androgenic alopecia patients using FUE.⁹ Herein, we applied this procedure to treat narrow-scar alopecia after neurosurgery. There is no reported relationship between hair density immediately after FUE for scar tissue and survival rate. Although we have performed more than 500 FUEs annually, we perform less than three FUEs annually for scar alopecia after craniotomy. Because of the small number of cases, we analyzed the relationship between intraoperative results and 1-year postoperative external appearance using the Fisher's exact test. To analyze relationship between intraoperative density and postoperative density and postoperative result precisely, we need to increase the number of cases. In our cases, high intraoperative density cases could achieve not only high postoperative hair density but also good results. In addition, low intraoperative density cases only achieved low postoperative hair density and poor result (►Fig. 4A, B). On the other hand, survival rate was not decreased even after HD hair transplant. Our results suggested that FUE with $\geq 40 \text{ FU/cm}^2$ is possible even for scar tissue. Although further study should be conducted, we believe that to achieve good postoperative results, the intraoperative density should exceed 40 FU/cm^2 .

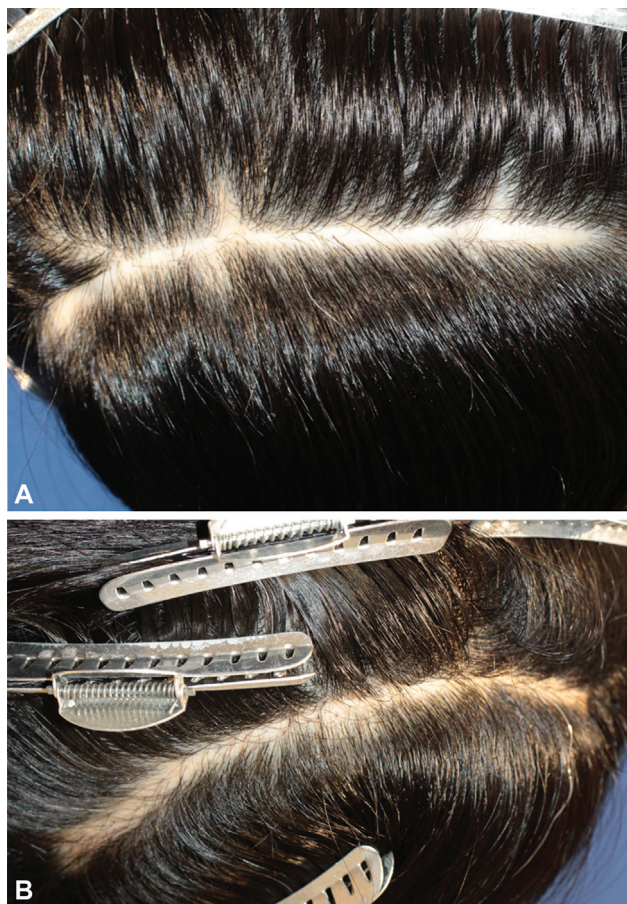

Fig. 4 (A) The example picture of patients who achieved poor result. Preoperative view. (B) One year after the operation of A. The intraoperative density was 14 cm^2 .

FUE is useful for the treatment of scar alopecia after craniotomy. Our results suggest that the 1-year postoperative hair density should exceed 20 FU/cm^2 to achieve good outcomes.

Ethical Approval

The study was approved by the Institutional Review Board of Shinwa Clinic (IRB No. SC-2022-01) and performed in accordance with the principles of the Declaration of Helsinki.

Patient Consent

The patients provided written informed consent for the publication and the use of their images

Authors' Contributions

Conceptualization: M.O., H.O.

Data curation: H.O.

Formal analysis, methodology: M.O.

Writing - original draft: H.O.

Review and editing: M.O., A.M.

Funding

None.

Table 2 The relationship between 1-year postoperative hair density, intraoperative hair density, survival rate, and proportion of patients whose 1-year postoperative result was good

	One-year postoperative hair density		p-Value
	HD (n = 6)	LD (n = 4)	
Intraoperative hair density (FU)	41.1 ± 7.5	24.8 ± 9.4	0.025
Survival rate (%)	64.3 ± 5.2	69.2 ± 6.2	0.286
Postoperative result (good: fair, poor)	5: 1	0: 4	0.047

Abbreviation: FU, follicular unit.

Note: Fisher's exact test was used for comparing the proportion of patients with good results, with the significance threshold set at 5% ($p < 0.05$). LD: low density group (hair density $< 20 \text{ FU/cm}^2$) HD: high density group (hair density $\geq 20 \text{ FU/cm}^2$).

Conflict of Interest

None declared.

References

- Hartley F, Kenyon JH. Experiences in cerebral surgery. *Ann Surg* 1907;45(04):481-530
- Kleinberger AJ, Jumaily J, Spiegel JH. Safety of modified coronal approach with dissection deep to temporalis fascia for facial nerve preservation. *Otolaryngol Head Neck Surg* 2015;152(04):655-660
- Liu M, Lv K, Li Z, Yang X. Using a modified postauricular hemi-coronal incision to manage unilateral zygomaticomaxillary complex fracture. *J Craniofac Surg* 2019;30(08):e740-e741
- Zhuang QW, Zhang XP, Wang X, et al. Coronal approach to zygomaticomaxillary complex fractures. *Eur Rev Med Pharmacol Sci* 2015;19(05):703-711
- Gabrielli MA, Monnazzi MS, Gabrielli MF, Hochuli-Vieira E, Pereira-Filho VA, Mendes Dantas MV. Clinical evaluation of the bicoronal flap in the treatment of facial fractures. Retrospective study of 132 patients. *J Craniomaxillofac Surg* 2012;40(01):51-54
- Kadakis S, Badhey A, Ashai S, Lee TS, Ducic Y. Alopecia following bicoronal incisions. *JAMA Facial Plast Surg* 2017;19(03):220-224
- Kumar VS, Rao NK, Mohan KR, et al. Minimizing complications associated with coronal approach by application of various modifications in surgical technique for treating facial trauma: a prospective study. *Natl J Maxillofac Surg* 2016;7(01):21-28
- Rassman WR, Bernstein RM, McClellan R, Jones R, Worton E, Uyttendaele H. Follicular unit extraction: minimally invasive surgery for hair transplantation. *Dermatol Surg* 2002;28(08):720-728
- Okochi M, Fukushima T, Okochi H, Takita K, Onda M. Donor site of follicular unit excision hair transplantation: the relationship between appearance and actual hair density, and hair diameter. *J Plast Surg Hand Surg* 2020;54(03):172-176
- Sanada Y, Yabuuchi T, Yoshioka H, Kubota H, Kato A. Zigzag skin incision effectively camouflages the scar and alopecia for moyamoya disease: technical note. *Neurol Med Chir (Tokyo)* 2015;55(03):210-213
- Frodel J-L, Mabrie D. Optimal elective scalp incision design. *Otolaryngol Head Neck Surg* 1999;121(04):374-377
- Nitta N, Fukami T, Nozaki K. Electrocautery skin incision for neurosurgery procedures-technical note. *Neurol Med Chir (Tokyo)* 2011;51(01):88-91

- 13 Ismail A, Abushouk AI, Elmaraezy A, et al. Cutting electrocautery versus scalpel for surgical incisions: a systematic review and meta-analysis. *J Surg Res* 2017;220:147–163
- 14 Shin H, Shin J, Lee JY. Scarred scalp reconstruction with a rectangular expander. *Arch Craniofac Surg* 2020;21(03):184–187
- 15 Laitung JK, Brough MD, Orton CI. Scalp expansion flaps. *Br J Plast Surg* 1986;39(04):542–548
- 16 Sahin B. Reconstruction of large alopecia with old technique: V-Y-S plasty. *Int Wound J* 2016;13(05):984–985
- 17 Nelson BR, Stough DB, Gillard M, Stough DB, Johnson TM. The paramedian scalp reduction with posterior Z-plasty. A technique to minimize the “slot” defect. *J Dermatol Surg Oncol* 1992;18(11):996–998
- 18 Yotsuyanagi T, Watanabe Y, Yamashita K, Urushidate S, Yokoi K, Sawada Y. New treatment of a visible linear scar in the scalp: multiple hair-bearing flap technique. *Br J Plast Surg* 2002;55(04):324–329
- 19 Burm JS, Oh SJ. Prevention and treatment of wide scar and alopecia in the scalp: wedge excision and double relaxation suture. *Plast Reconstr Surg* 1999;103(04):1143–1149
- 20 Loganathan E, Sarvajnamurthy S, Gorur D, Suresh DH, Siddaraju MN, Narasimhan RT. Complications of hair restoration surgery: a retrospective analysis. *Int J Trichology* 2014;6(04):168–172
- 21 Salanitri S, Gonçalves AJ, Helene A Jr, Lopes FH. Surgical complications in hair transplantation: a series of 533 procedures. *Aesthet Surg J* 2009;29(01):72–76
- 22 Anegawa S, Hayashi T, Torigoe R, Harada K, Araki T, Yoshikawa A. Linear transverse forehead incision for patients with alopecia praematura—technical note. *Neurol Med Chir (Tokyo)* 1995;35(08):604–606
- 23 Kasai Y, Igawa H, Abe N, et al. Successful follicular unit extraction hair transplant for bald area after skin graft. *J Plast Reconstr Aesthet Surg* 2017;13:71–76(open)
- 24 Yoo H, Moh J, Park JU. Treatment of postsurgical scalp scar deformity using follicular unit hair transplantation. *BioMed Res Int* 2019;2019:3423657
- 25 Shao H, Hang H, Yunyun J, et al. Follicular unit transplantation for the treatment of secondary cicatricial alopecia. *Plast Surg (Oakv)* 2014;22(04):249–253
- 26 Farjo B, Farjo N, Williams G. Hair transplantation in burn scar alopecia. *Scars Burn Heal* 2015;1:2059513115607764
- 27 Mohebi P, Tassman WR. Hair restoration in cranial surgery patients. *Hair Transplant Int* 2018;28:97
- 28 Parsley WM, Perez-Meza D. Review of factors affecting the growth and survival of follicular grafts. *J Cutan Aesthet Surg* 2010;3:69–75
- 29 Kischer CW, Shetlar MR, Chvapil M. Hypertrophic scars and keloids: a review and new concept concerning their origin. *Scan Electron Microsc* 1982;4(Pt 4):1699–1713
- 30 Zheng J, Song F, Lu SL, Wang XQ. Dynamic hypoxia in scar tissue during human hypertrophic scar progression. *Dermatol Surg* 2014;40(05):511–518
- 31 Kischer CW. The microvessels in hypertrophic scars, keloids and related lesions: a review. *J Submicrosc Cytol Pathol* 1992;24(02):281–296
- 32 Filippova OV, Afonichev KA, Krasnogorskiy IN, et al. *Traumatol. Orthopaed Reconst Surg* 2017;5:25–35
- 33 Josephitis D, Shapiro R. FUT vs. FUE graft survival: a side-by-side study of 3 patients undergoing a routine 2,000+ graft hair transplantation. *Hair Transplant Forum International* 2018;28:179–182