



Distal Endoscopic Attachments

Pankaj N. Desai¹ Chintan N. Patel¹ Mayank Kabrawala² Subhash Nanadwani² Rajiv Mehta²
Ritesh Prajapati² Nisharg Patel² Mohit Sethia²

¹Department of Endoscopy and Endosonography, SIDS Hospital & Research Centre, Surat, Gujarat, India

²Department of Gastroenterology, SIDS Hospital & Research Centre, Surat, Gujarat, India

³Department of Radiology, Surat Institute of Digestive Sciences (SIDS), Surat, Gujarat, India

Address for correspondence Pankaj Desai, MS, FASGE, FAIGE, Department of Endoscopy and Endosonography, Surat Institute of Digestive Sciences (SIDS), Majura Gate, Ring Road, Surat, Gujarat, India 395002 (e-mail: drp_desai@hotmail.com).

J Digest Endosc 2022;13:243–250.

Abstract

Endoscopy is an evolving science and the last two decades has seen it expand exponentially at a pace unapparelled in the past. With the advancement in new procedures like image-enhanced endoscopy, magnifying endoscopy, third space endoscopy, and highly advanced endoscopic ultrasound procedures, endoscopic accessories are also evolving to cater the unmet needs. Endoscopic cap or distal attachment cap is a simple but very important accessory in the endoscopists' armamentarium which has changed the path of endoscopic procedures. It has so far been used commonly mostly for variceal ligation and endoscopic mucosal resections for colorectal polyps. But the horizon of its use has expanded in the recent years for difficult clinical scenarios like providing stability to the endoscope, overcoming blind spots during screening colonoscopies, maintaining clear field of vision during endotherapy of gastrointestinal bleeding, and during magnification endoscopy for lesion characterizations and so on. These caps are of different shapes, sizes, colors, and material depending on manufacturers and their implications while performing varied endoscopies. This review summarizes the clinical utilities of the cap in diagnostic as well as therapeutic endoscopy and its expanding indications of use.

Keywords

- ▶ distal attachment cap
- ▶ EMR
- ▶ endoscopy
- ▶ ESD
- ▶ magnification endoscopy
- ▶ POEM

Introduction

Endoscopy is an evolving science and the last two decades has seen it expand exponentially at a pace unapparelled in the past. With the advancement in new procedures like image-enhanced endoscopy, magnifying endoscopy, third space endoscopy, and highly advanced endoscopic ultrasound (EUS) procedures, endoscopic accessories are also evolving to cater the unmet needs. Endoscopic cap or distal attachment cap is a simple but very important accessory in the endoscopists' armamentarium which has changed the path of endoscopic procedures.

Commercially available endoscopic caps or distal attachments come either as a part of single-use endoscopic mucosal resection (EMR) kit or as a solo reusable/single-use distal attachment. They come in different shapes, sizes, with rim or without rim, with or without side hole, with or without a marking notch, and variable consistency depending on their manufacturing material and colors. Caps are hollow cylinders which can be transparent, opaque, or colored and can be attached to distal end of the scope. It has a proximal end which attaches to the outer part of the scope tip which may be fixed with an adhesive tape to prevent its dislodgement during procedures. The diameter of the caps is such that they

DOI <https://doi.org/10.1055/s-0042-1755336>.
ISSN 0976-5042.

© 2022. The Author(s).

This is an open access article published by Thieme under the terms of the Creative Commons Attribution License, permitting unrestricted use, distribution, and reproduction so long as the original work is properly cited. (<https://creativecommons.org/licenses/by/4.0/>)

Thieme Medical and Scientific Publishers Pvt. Ltd., A-12, 2nd Floor, Sector 2, Noida-201301 UP, India

snugly fit to the distal end of scopes manufactured by any of the standard companies. The distal end of the cap, which is the actual working part, can be conical, spherical, or funnel shaped and may have a horizontal or beveled edge internally. Black colored cap is mostly used to enhance the magnification and near focus functions for detection and characterization of early neoplastic lesions. Black color prevents reflection of light and thereby negates shadow formation or halation. Transparent or opaque caps with different shapes are used for mainly therapeutic applications depending on the procedure and endoscopists choice. These caps usually have a side hole which fits in the axis of the lens and is meant for drainage of accumulated fluid during procedure which can impair visualization. Caps for use in EMR have a notch or small cut to be aligned in line of working channel and facilitate the opening of the snare in the groove and helps in getting the lesion sucked in completely and be resected en bloc. Depth of the caps can be predetermined (fixed) or can be adjusted. This is very important in diagnostic and therapeutic endoscopy. They are classified as short (1–2 mm), medium (3–4 mm), and long (> 4 mm) as per the depth of caps.

This review summarizes the clinical utilities of the cap in diagnostic as well as therapeutic endoscopy and its expanding indications of use.

Advantages of Using Caps in Endoscopy

It has so far been used commonly mostly for variceal ligation and EMRs for colorectal polyps. But the horizon of its use has expanded in the recent years for difficult clinical scenarios like providing stability to the endoscope, overcoming blind spots during screening colonoscopies, maintaining clear field of vision during endotherapy of gastrointestinal (GI) bleeding, and during magnification endoscopy for lesion characterizations and so on.

Classification of Caps

1. Straight and oblique caps

EMR using a transparent plastic cap-fitted panendoscope (EMRC) is a further development to conventional EMR. This ready-to-use kit may have a soft straight or wide oblique cap (outer diameter 13.9 mm/14.9 mm, 12 mm length) with a rim along with spray catheter, injection catheter, and electrosurgical snare required for EMR (Olympus Medical, EMR-Kit). Straight or oblique cap are to be used depending upon the site of lesion, oblique caps are preferred when EMR is to be performed tangentially. These distal attachments and suction enable quick resections of a wider area at the same time by providing secure capture of a targeted lesion without letting it slip.

2. Soft cap

These come as sterile single-use soft transparent, colorless cap either straight or oblique for EMR, endoscopic submucosal dissection (ESD), and other third space endoscopic procedures. These distal attachments allow optimal field of vision by providing a proper focus be-

tween the endoscope tip and the targeted lesion, thus eliminating “red-outs.” The side holes provide clear working space by continuous drainage of fluid during the resection. Caps provide stability to the scope at difficult angles and can facilitate resection by pushing and flattening the folds for lesions lying behind them. The soft material prevents damage to the mucosa during scope maneuvering. Straight single-use caps have a distance of 4 mm from distal end of scope whereas the caps designed for diagnosis and characterization of lesion, mainly for zoom endoscopes has a distance of 2 mm. The straight caps for therapeutic procedures come in sizes which are compatible with enteroscopes, colonoscopes, and gastroscopes with outer diameters starting from 11.4 to 15.7 mm depending on the make of the scope. Single-use caps for zoom endoscopes have an outer diameter of 12.1 and 12.7 mm and are compatible with gastroscopes depending on their make. Single-use wide oblique cap has an outer diameter of 18.1 mm with a rim and a notch for optimal placement of distal tip. They are specially designed for tangentially placed lesions and for resections of wider area using EMRC. These caps are largely manufactured by Olympus Medical and US Endoscopy (Reveal Cap). Reveal Cap comes with an outer diameter of 11.8 and 13.4 mm (►Fig. 1A, B).

3. Black cap

Reusable cap for zoom endoscope come in black color. Black color helps by eliminating reflection of the light and provides clear view for lesion characterization (►Fig. 2).

4. Endocuffs and Endorings

Endocuffs (Olympus Medical) are specially designed distal attachments to increase adenoma detection rate (ADR) during screening colonoscopies. They help by preventing slipping of the scope and improve visualization behind the colonic folds by gently straightening and spreading them. They come in small purple, medium blue, large green, and extralarge orange variety.

Endorings (Steris Endoscopy) are three circular rows of flexible silicone rings attached together around distal tip of colonoscope. During withdrawal, they straighten the colonic folds mechanically and keeps the colonic lumen in center thereby improving the visualization of colonic mucosa. The packings are color-coded having pink color compatible with adult colonoscope with an outer diameter of 12.8 to 14.5 mm and yellow color compatible with

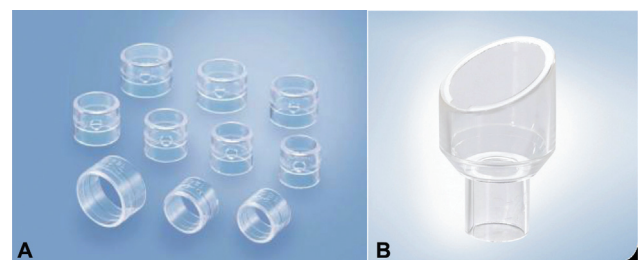


Fig. 1 (A) Soft straight and oblique caps for single use (Olympus Medical Systems, India). (B) Reveal distal attachment (US Endoscopy, USA).



Fig. 2 Black cap for lesion characterization and zoom endoscopy (Olympus Medical Systems, India).

slim adult colonoscope with an outer diameter of 11.5 to 13 mm (►Fig. 3A, B).

5. Hood knife caps

Conventional EMR has a limitation of en bloc resection of lesions larger than 2 cm. To overcome this, the concept of widespread EMR was evolved and to resect a wider area en bloc specialized prototype knife was developed which is known as hood knife (Olympus, Tokyo). It can be either longitudinal or circular. They consist of a transparent cap with an electro-surgical wire placed either horizontally or longitudinally at the distal tip. This particular cap has been used for resection of larger area in Barrett's mucosa with high grade dysplasia for an intent to get a margin-free resection and optimal histological assessment, a pilot study is going on for the same (►Fig. 4).

6. Foreign body removal hood

Simple latex protectors or hoods are available which can be very helpful during removal of sharp foreign bodies, they get unfolded at gastroesophageal junction when the sharp object is grasped with a foreign body forceps and pulled. The hood thereby covers the sharp foreign body and prevents mucosal and deep injury during retrieval through the esophagus (►Fig. 5).

7. Bougie cap

Bougie cap (Ovesco, Germany) is a single-use, clear, conical endoscopic cap which can be mounted at the distal end of the scope and act as a mediator for applying radial and longitudinal force vector during dilatation of benign strictures. This cap allows the direct visual control during stricture dilatation. These caps are available in six sizes

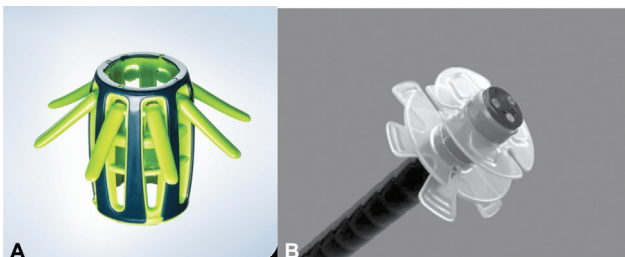


Fig. 3 (A) Endocuff (Olympus Medical Systems, India). (B) Endoring (Steris Endoscopy, USA).

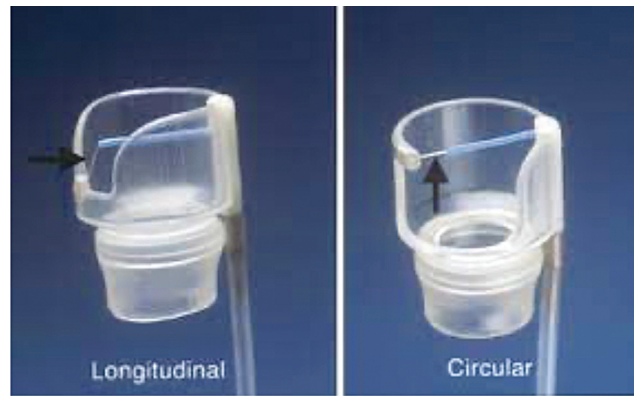


Fig. 4 Hood knives (Olympus Medical Systems, Tokyo).

(7–8, 10–12, and 14–16 mm) with two lateral holes for suction and air insufflation and one central hole for guidewire insertion (►Fig. 6).

Cap-Assisted Diagnostic Endoscopy

1. For routine examination of ampulla of Vater

Endoscopic training guidelines and literature recommend the complete visualization and examination of papilla during standard upper GI endoscopic evaluation. This is not always possible due to anatomical variation, tangential placement of papilla, and looping of the scope in the second part of duodenum.¹ This necessitates using a side viewing duodenoscope which is not easily available in all endoscopy suites, And adds to the cost. Use of distal caps allows maintaining optimal distance for examination and prevents sticking of duodenal mucosa to the tip of endoscope. It also prevents looping by hooking to duodenal mucosa and helps straightening the tangential angle for better visualization. Choi et al suggested that cap-assisted endoscopy was effective when regular upper GI endoscopy fails in visualizing ampulla of Vater and increases diagnostic accuracy while using forward-viewing scope and decreases the need for side-viewing scopy.²



Fig. 5 Foreign body removal hood (upper part, insertion position; lower part, retrieval position).



Fig. 6 Bougie cap (Ovesco Endoscopy, Germany).

Similarly, Silva et al demonstrated that cap-assisted endoscopy was feasible and safe with a higher success for complete visualization of ampulla as compared with forward-viewing scopy.³

2. Lesion characterization and improved visualization

For better visualization of mucosa and lesion characterization, optimal distance is required for focusing during magnification or zoom endoscopy. To get the scope to focus precisely, combination of scope movement, gradual adjustment of magnification by lever, and optimal air

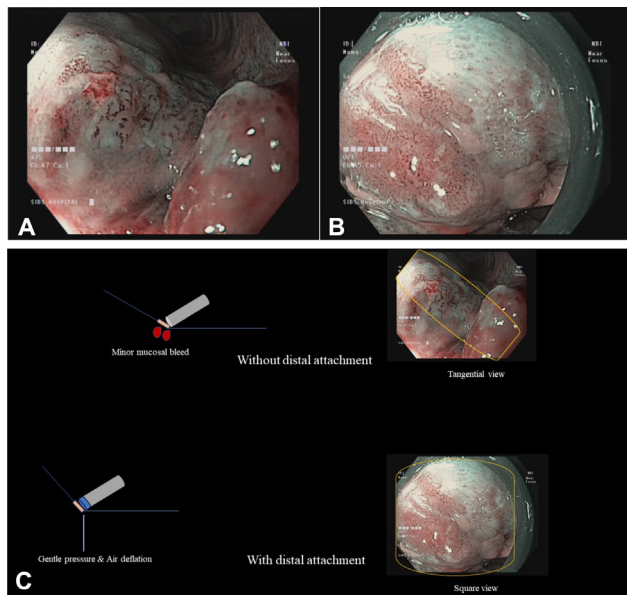


Fig. 7 (A) Intrapapillary capillary loop (IPCL) type V without use of cap, distal portion is not well focused. (B) IPCL type V with use of cap, making a square view. (C) Use of cap versus without cap for lesion characterization in magnification endoscopy. Tips for better visualization. Schematic presentation.

insufflation control is mandatory. There are chances of oozing due to scope trauma causing artifacts and uncontrolled air insufflation resulting in tangential field of view when the lesion is examined without using distal attachment. The use of soft cap enables the lesion to come into square view and gentle suction with control of air insufflation provides optimal depth to focus the lesion with precision and improves characterization.⁴ A black-colored soft, short cap protruding to distance of 2 mm from the distal end to scope is available which helps in reducing glare and halation during magnifying endoscopy (→ Fig. 7A–C).

3. Screening colonoscopy and adenoma detection

Despite significant advancement in colonoscope designs and software, there are certain blind folds where the early small flat lesions can be missed. Endoscopic caps, cuffs, and rings are a good adjunct to increase the visibility of such areas. These accessories improve visualization by pushing folds aside, decreasing loop formation by providing stability, and maintaining lumen patency by allowing optimal air insufflation. Clinical studies have documented higher efficacy of cap-assisted endoscopy compared with without cap in terms of increased adenoma and polyp detection rate without increase procedure time or patient discomfort.⁵ Caps provide an added advantage during ileal intubation in difficult colonoscopies and where conventional colonoscopy fails. Minor mucosal lacerations, displacement of distal attachment, and, on rare occasions, perforations are adverse events that may occur especially in rectosigmoid regions.⁶ A recent meta-analysis of prospective studies showed that the cap-assisted colonoscopy significantly increases ADR.⁷ Multiple studies have demonstrated faster cecal intubation rate in cap-assisted colonoscopy group as compared with standard colonoscopy group.^{8–12} Multiple studies have shown a higher ADR in cap-assisted arm as compared with standard colonoscopy.^{13–16}

Cap-Assisted Therapeutic Endoscopy

1. EMRC

Inoue et al introduced EMRC in 1992, since then it is widely used for mucosal lesions without lymphovascular involvement.^{12,17} EMRC involves certain specific steps which are as follows:

2. i. Marking of lesion and submucosal injection

After lesion characterization and decision of EMRC has been taken, a lesion is marked with a margin of 2 mm with use of snare tip, needle knife, or any other accessories available for ESD, using soft coagulation. Marking is particularly used for larger or irregular lesions where, after submucosal injection, the margin may get distorted or indistinct. For smaller lesions with distinct margins, marking of lesion can be avoided to decrease the procedure time. A submucosal cushion is made with use of diluted indigo-carmin or methylene blue depending upon availability mixed with normal

saline. Amount of injection varies depending on the size of lesion; optimal submucosal lift circumferentially is the endpoint of injection. This submucosal cushion minimizes the risks of perforation and thermal muscle injury. Absence or suboptimal mucosal lift indicates deeper invasion and EMR should be avoided in such cases. Multiple injections may be required while resecting larger lesions when procedure time is longer due to dissipation of injected fluid through resected sites.

3. ii. Resection

A distal cap depending on the operator's choice and availability is attached to the tip of the scope. A snare is prelooped to the rim of the cap. The scope is then advanced toward the targeted lesion and the lesion is completely suctioned in the cap. Once the lesion is suctioned completely, the prelooped snare is closed and lesion is resected using an endocut current. Still applying suction, the resected lesion is suctioned in cap and endoscope is withdrawn. If the lesion is larger, the same procedure can be repeated starting the second injection and resection from the margin of the previous resection, till the entire lesion is resected. The resected site should be checked for any target sign (→ Fig. 8).

1. Third space endoscopy procedures

Caps are now an integral part of third space endoscopic procedures which include peroral endoscopic myotomy (POEM) and its variants, ESD, submucosal dissection tunneling endoscopic resection (STER), and submucosal tunneling endoscopic septum division (STESD). The caps provide optimal field of view during submucosal dissection, prevent red-outs, help in submucosal dissection by pressure over resected lesion, help to house accessory during control of bleeding, provide tamponade, and help maintaining a clear plane of dissection by draining accumulated fluid and blood from side holes.

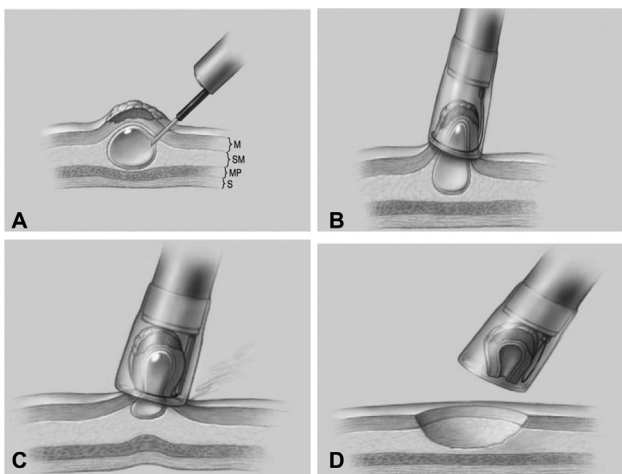


Fig. 8 Steps of cap-assisted endoscopic mucosal resection (EMRC). (A) Submucosal injection using diluted methylene blue and normal saline. (B) Aspiration of entire lesion in cap. (C) Strangulation with snare. (D) Resection.

In POEM, after submucosal injection and submucosal cushion formation, a submucosal tunnel is made going parallel to muscles and extended 2 to 3 cm across the gastroesophageal junction, followed by myotomy, the length of which depends on the type of achalasia followed by mucosal flap closure with clips. Caps provide scope stability, clear field of view, and optimal distance from scope tip to targeted tissue during submucosal dissection. Caps help during active bleeding to creating tamponade till a coagulation grasper is housed within it and then slow withdrawal gives a precise bleeding point for coagulation. They also are useful at tight gastroesophageal junction for maneuvering scope between the mucosa and the muscle layer by mechanical stretching to give some working space for locating the site of further injection and dissection by a hybrid or triangular tip knife.

During ESD, similarly after submucosal injection, the lesion is dissected out after circumferential incision conventionally or by pocket or tunnel creation method for larger lesions. During submucosal dissection, cap helps to maintain a proper field of dissection and helps in hemostasis of intervening vessels. Cap gives stability to scope during dissection at difficult angles and traction can be applied to lift the resected part for further dissection.

STER follows the principles of POEM for resection of small submucosal lesions.

STESD is a novel method used to treat Zenker's or other esophageal diverticuli and is based on principles of POEM. After submucosal injection at 2 to 3 cm away from septum, a tunnel is created till septum and dissection is performed on both esophageal and diverticulum side till its base with hemostasis of intervening vessels. Once dissection is complete on both sides, septum division is performed under direct endoscopic vision with accessory of choice depending upon the endoscopist's preference. Mucosal incision is then closed with hemoclips.

2. Control of bleeding

Band ligation: Band ligation is an established procedure for control of bleeding esophageal varices with pre-loaded bands on a transparent cap. Band ligation has also been reported for the treatment of Dieulafoy's lesion, Mallory-Weiss tear, inflammatory polyps, gastric antral vascular ectasia and hemorrhoids.^{7,18,19} (→ Fig. 9A–C).

Bleeding from ulcers on posterior wall of stomach, duodenal bulb, and D1-D2 junction can be tricky and difficult to manage because of tangential placement and recurrent scope retraction. Use of cap enables to locate the bleeding point precisely by making the scope stable and enables tamponade. Cap has an added advantage of modifying the angle that can be useful while performing endotherapy at difficult angles and turns. Mota et al recently published a case series where four patients with acute upper GI bleeding in which prior endoscopy failed to localize the site, a cap-fitted scope with water immersion technique could localize the bleeding point and aided in control of bleeding.²⁰ Moreels et al described that distal attachment

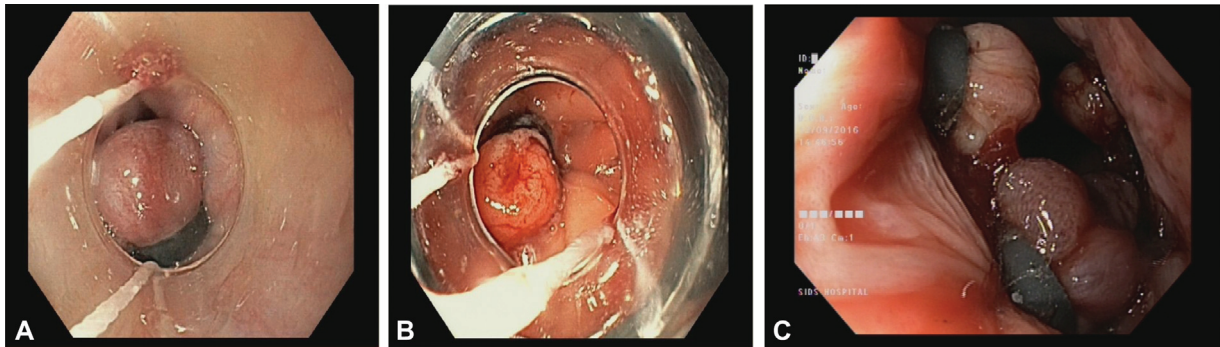


Fig. 9 (A) Band ligation for esophageal varices. (B) Band ligation for gastric antral vascular ectasia (GAVE). (C) Band ligation for hemorrhoids.

helps in rapid exchange of scope insertion and removal of large clots during emergency procedures in case of active GI bleeding in vitally unstable patients by improving aspiration force and contact surface where standard suctioning can cause blockage of suction channel and other accessories like snare would not work as they cut into the blood clots²¹ (► **Fig. 10A, B**).

3. Foreign body removal

Use of cap or protective hood is helpful during removal of impacted food bolus by dislodging it, and prevents mucosal injury after pulling sharp end into the cap itself. Small spherical foreign bodies that are difficult to grasp with other accessories can be successfully suctioned into the cap and removed. Fang et al evaluated the role of transparent cap in removal of foreign bodies in the esophagus with a propensity score-matched analysis which suggested that it was associated with shorter procedure time and higher rates of clear endoscopic view.²² Study by Zhang et al shows less mucosal injuries during removal of foreign bodies in the transparent cap-assisted group.²³ Ooi et al reported the shorter procedure time, higher rate of en bloc removal, and less adverse events in cap-assisted endoscopy compared with the traditional way.²⁴ Similar findings were observed by Wahba et al making cap-assisted foreign body removal a first choice while dealing with sharp objects and food bolus impaction.²⁵

4. Diagnosis and treatment of colonic diverticular bleeding

Diverticular bleeding is often troublesome and the culprit diverticula are difficult to locate. Use of cap facilitates

better visualization of the interior of the diverticulum by partially retracting the diverticular fold and then with help in irrigation, suction, and fibrin clot dislodgement to detect the precise location of the bleeding site.²⁶ They are also helpful in examination of diverticulum lying behind the folds. Once the bleeding site is identified, a hemoclip can be housed and adjusted in the hood for precise targeting and hemostasis. Few studies have described use of band ligation for control of diverticular bleed.^{27,28}

5. During enteroscopy

Soft short caps can be used to prevent red-outs and facilitates deep intubation with minimal air insufflation during enteroscopy. Caps allow better luminal visualization and of the targeted lesion when used with therapeutic intent. A prospective randomized control trial by Hasak et al demonstrated the higher rate of vascular malformation detection and better depth of insertion while enteroscopy was performed with distal cap.²⁹

6. Cap-assisted necrosectomy

After an initial EUS-guided walled-off necrosis drainage, endoscopic necrosectomy can be cumbersome due to lack of procedure-specific accessories, friable necrotic tissue, and recurrent bleeding, hampering the field of vision and fogging of the lens. Frequent cleaning of lens leads to increased procedure time. Use of a cap in such situations provides an optimal distance from lens to distal tip and hence provides a clear field of vision. Accessories can be guided through the cap and the cap itself can be used to remove resected necrotic phlegmon by suctioning or

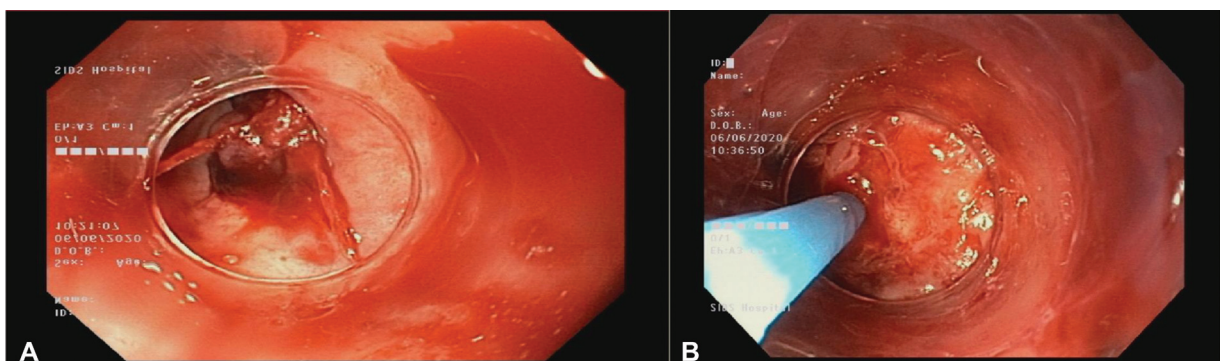


Fig. 10 Endotherapy of gastrointestinal (GI) bleed using cap. (A) Active spurt. (B) Cap-assisted tamponade, point localization, and targeted delivery.

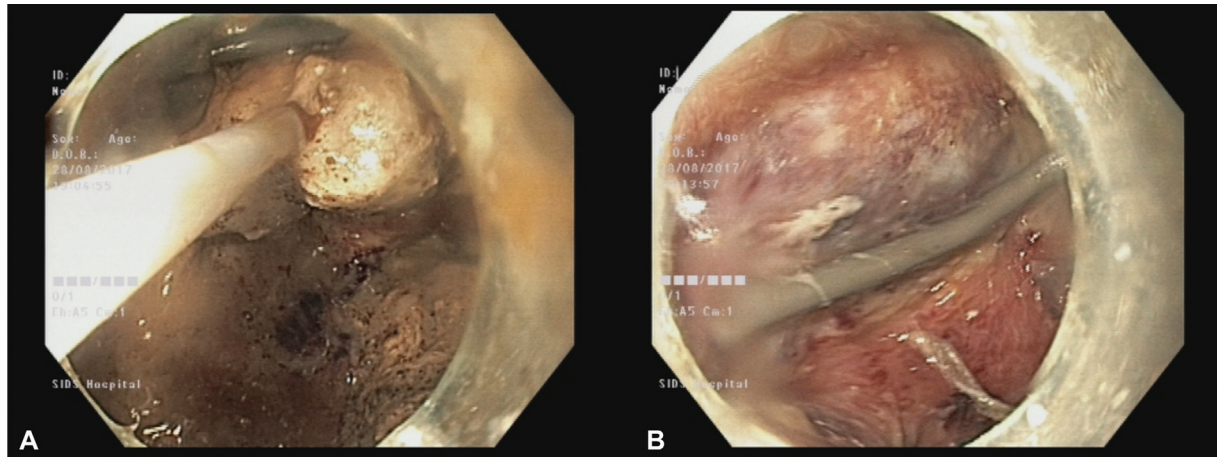


Fig. 11 Cap-assisted necrosectomy. (A) Necrosectomy with snare. (B) Completed necrosectomy with clear cavity and stent in situ.

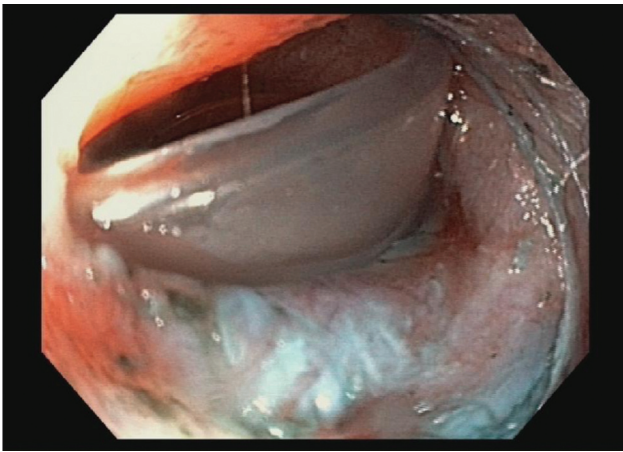


Fig. 12 Impacted cap during peroral endoscopic myotomy (POEM) at tight gastroesophageal (GE) junction when it was not secured with tap.

scraping. Puri et al observed the cap-assisted necrosectomy to be safe for extraction of necrosium with less intervention and without risk of dislodgement of metal stent³⁰ (►Fig. 11A, B).

Limitations and Adverse Events

Cap can reduce the maneuverability and narrow the field of view. They may make the intubation difficult at sharp bends and angles. When working in very narrow spaces, they may get dislodged and get impacted which may cause mucosal trauma and bleeding during its removal. Minor mucosal injury and on rare occasions perforation can occur specially in rectosigmoid regions (►Fig. 12).

Conclusion

Caps come handy for the endoscopists during tricky and difficult situations during conventional endoscopy. Caps are easy to use and facilitate the diagnosis and treatment in areas otherwise poorly accessible during endoscopy. Appropriate selection of the cap according to site and size of lesion and for

the correct indication helps improve patient outcomes. The indications are not limited to a few procedures but are expanding with the endoscopists becoming more and more aggressive in interventional procedures.

Conflict of Interest

None declared.

References

- Block B, Schachschal G, Schmidt H. Endoscopy of the Upper GI Tract. Thieme Medical Publishers Inc; 2004:52–59
- Choi YR, Han JH, Cho YS, et al. Efficacy of cap-assisted endoscopy for routine examining the ampulla of Vater. *World J Gastroenterol* 2013;19(13):2037–2043
- Silva, et al. *Gastroenterology*. BMC; 2020
- Urita Y, Nishino M, Arika H, Ozaki M, Naruki Y, Otsuka S. A transparent hood simplifies magnifying observation of the colonic mucosa by colonoscopy. *Gastrointest Endosc* 1997;46(02):170–172
- Tada M, Inoue H, Yabata E, Okabe S, Endo M. Feasibility of the transparent cap-fitted colonoscope for screening and mucosal resection. *Dis Colon Rectum* 1997;40(05):618–621
- Jain D, Sandhu N, Singhal S. New developments in mechanical enhancement of colonoscopy: cuffs, caps and rings. *Digestion* 2016;93(03):234–247
- Gerson LB, Yap E, Slosberg E, Soetikno RM. Endoscopic band ligation for actively bleeding Dieulafoy's lesions. *Gastrointest Endosc* 1999;50(03):454–455
- Frieling T, Neuhaus F, Kuhlbusch-Zicklam R, et al. Prospective and randomized study to evaluate the clinical impact of cap assisted colonoscopy (CAC). *Z Gastroenterol* 2013;51(12):1383–1388
- Lee YT, Lai LH, Hui AJ, et al. Efficacy of cap-assisted colonoscopy in comparison with regular colonoscopy: a randomized controlled trial. *Am J Gastroenterol* 2009;104(01):41–46
- de Wijkerslooth TR, Stoop EM, Bossuyt PM, et al. Adenoma detection with cap-assisted colonoscopy versus regular colonoscopy: a randomised controlled trial. *Gut* 2012;61(10):1426–1434
- Rastogi A, Bansal A, Rao DS, et al. Higher adenoma detection rates with cap-assisted colonoscopy: a randomised controlled trial. *Gut* 2012;61(03):402–408
- Park SY, Kim HS, Yoon KW, et al. Usefulness of cap-assisted colonoscopy during colonoscopic EMR: a randomized, controlled trial. *Gastrointest Endosc* 2011;74(04):869–875
- Floer M, Biecker E, Fitzlaff R, et al. Higher adenoma detection rates with endocuff-assisted colonoscopy - a randomized controlled multicenter trial. *PLoS One* 2014;9(12):e114267

- 14 Biecker E, Floer M, Heinecke A, et al. Novel endocuff-assisted colonoscopy significantly increases the polyp detection rate: a randomized controlled trial. *J Clin Gastroenterol* 2015;49(05):413–418
- 15 Tee HP, Corte C, Al-Ghamdi H, et al. Prospective randomized controlled trial evaluating cap-assisted colonoscopy vs standard colonoscopy. *World J Gastroenterol* 2010;16(31):3905–3910
- 16 Dik VK, Gralnek IM, Segol O, et al. Multicenter, randomized, tandem evaluation of EndoRings colonoscopy—results of the CLEVER study. *Endoscopy* 2015;47(12):1151–1158
- 17 Inoue H, Endo M, Takeshita K, Yoshino K, Muraoka Y, Yoneshima H. A new simplified technique of endoscopic esophageal mucosal resection using a cap-fitted panendoscope (EMRC). *Surg Endosc* 1992;6(05):264–265
- 18 Park CH, Min SW, Sohn YH, et al. A prospective, randomized trial of endoscopic band ligation vs. epinephrine injection for actively bleeding Mallory-Weiss syndrome. *Gastrointest Endosc* 2004;60(01):22–27
- 19 Wells CD, Harrison ME, Gurudu SR, et al. Treatment of gastric antral vascular ectasia (watermelon stomach) with endoscopic band ligation. *Gastrointest Endosc* 2008;68(02):231–236
- 20 Mota FL, Centeno DM, de Oliveira FJS, et al. The use of the cap and underwater technique as an aid in endoscopic diagnosis and treatment of upper gastrointestinal bleeding: case series. *Video-GIE* 2021;6(11):518–521
- 21 Moreels TG, Lotry M, Roth B, Pelckmans PA. Distal cap to facilitate removal of blood clots during endoscopic hemostasis for upper gastrointestinal bleeding. *Endoscopy* 2009;41(1, Suppl 2):E152
- 22 Fang R, Cao B, Zhang Q, Li P, Zhang ST. The role of a transparent cap in the endoscopic removal of foreign bodies in the esophagus: a propensity score-matched analysis. *J Dig Dis* 2020;21(01):20–28
- 23 Zhang S, Wang J, Wang J, Zhong B, Chen M, Cui Y. Transparent cap-assisted endoscopic management of foreign bodies in the upper esophagus: a randomized, controlled trial. *J Gastroenterol Hepatol* 2013;28(08):1339–1342
- 24 Ooi M, Young EJ, Nguyen NQ. Effectiveness of a cap-assisted device in the endoscopic removal of food bolus obstruction from the esophagus. *Gastrointest Endosc* 2018;87(05):1198–1203
- 25 Wahba M, Habib G, Mazny AE, et al. Cap-assisted technique versus conventional methods for esophageal food bolus extraction: a comparative study. *Clin Endosc* 2019;52(05):458–463
- 26 Kaltenbach T, Watson R, Shah J, et al. Colonoscopy with clipping is useful in the diagnosis and treatment of diverticular bleeding. *Clin Gastroenterol Hepatol* 2012;10(02):131–137
- 27 Ishii N, Setoyama T, Deshpande GA, et al. Endoscopic band ligation for colonic diverticular hemorrhage. *Gastrointest Endosc* 2012;75(02):382–387
- 28 Farrell JJ, Graeme-Cook F, Kelsey PB. Treatment of bleeding colonic diverticula by endoscopic band ligation: an in-vivo and ex-vivo pilot study. *Endoscopy* 2003;35(10):823–829
- 29 Hasak S, Lang G, Early D, et al. Use of a transparent cap increases the diagnostic yield in antegrade single-balloon enteroscopy for obscure GI bleed. *Dig Dis Sci* 2019;64(08):2256–2264
- 30 Puri N, Hallac A, Srikureja W. Early experience with cap-assisted endoscopic pancreatic necrosectomy: a technique to enhance safe tissue extraction and decrease interventions. *Endosc Int Open* 2019;7(07):E912–E915