Article published online: 2022-08-30

MELAS (Mitochondrial Encephalopathy, Lactic Acidosis and Stroke-Like Episodes)—Usual and Unusual MRI Finding

Sameeta M. Prabhu[1] Bidisha Banerjee[1] Ullas Acharya[2] Poonam P Hegde[3] Mitesh Shetty[4]

[1] Department of Paediatric Neurology, Manipal Hospital, Bangalore, Karnataka, India
[2] Department of Neuroradiology, Manipal Hospital, Bangalore, Karnataka, India
[3] Department of Radiology, Manipal Hospital, Bangalore, Karnataka, India
[4] Department of Medical Genetics, Manipal Hospital, Bangalore, Karnataka, India

Address for correspondence Sameeta Prabhu, MD, Manipal Hospital, Old Airport Road, Bangalore 560017, Karnataka, India (e-mail: sameetamp@gmail.com).

Indian J Radiol Imaging 2022;32:625–626.

MELAS (mitochondrial encephalopathy, lactic acidosis, and stroke-like syndrome) is a mitochondrial cytopathy presenting with stroke-like episodes, seizures, dementia, headache, and vomiting in a child with normal early psychomotor development. Investigation shows lactic acidosis and/or ragged-red fibers on muscle biopsy.[1] Magnetic resonance imaging (MRI) is pivotal in diagnosis and differentiation from close mimics. The m.3243A > G pathogenic variant in the mitochondrial gene MT-TL1 is present in approximately 80% of MELAS.[1] Acute administration of L-arginine attenuates severity of symptoms and regular supplementation reduces further episodes.[2]

An 8-year-old, developmentally normal boy, born uneventfully to a nonconsanguineous couple, presented with three episodes of sudden-onset stroke-like episodes. He had headache, vomiting, blurred vision, slurred speech, unstable gait with preceding fever during the first and second episodes. During the third episode, he had left focal seizures and paraesthesia. He also had exercise intolerance. Neurological examination showed short stature, decreased color vision, unreliable visual fields, dysmetria, and transient mild left hemiparesis.

On investigation, high plasma lactate with maximum of 57.3mg/dL and raised CPK (creatinine phosphokinase) with maximum of 343 IU/L were noted. Genetic evaluation (whole mitochondrial genome sequencing) detected a heteroplasmic exonic noncoding variation in the MT-TL1 gene (chrM: 3243A > G; depth: 9550 ×).

MRI brain, during the first episode, showed diffusion restriction involving left parieto-occipitotemporal gyri with corresponding regional hyperperfusion on arterial spin labeling (ASL) and prominent left posterior cerebral artery on magnetic resonance angiography (MRA). Susceptibility-weighted imaging showed reduced susceptibility (►**Fig. 1A–D**). Magnetic resonance spectroscopy (MRS) showed high lactate peak (►**Fig. 2D**). During the second episode, MRI showed similar changes in right occipitotemporal lobe (►**Fig. 2A**) with resolution of prior abnormal MRI signals (►**Fig. 2C**). During third episode, MRI showed involvement of bilateral postcentral gyri (►**Fig. 2B**).

He received oral L-arginine 500 mg/kg stat and was discharged with oral L-arginine at 300 mg/kg/day, coenzyme Q and L-carnitine during all episodes with additional daily oral L-citrulline (same dose and frequency as L-arginine) during the last episode, following which he remained symptom-free for the last 6 months.

The diagnosis of MELAS remains challenging, because of its rarity and multisystem involvement. It has clinically relapsing-remitting episodes with transient fleeting cortical lesions.[3] MRI aids in diagnosis and differentiation from ischemic stroke. Though mostly vasogenic, cytotoxic edema has also been reported.[4] Lesions are not confined to vascular territories. Regional hyperperfusion on ASL indicates compensatory effort to meet demands of affected neurons and increased regional lactate causing abnormal local vascular permeability or vasodilation, a feature not seen in ischemic stroke. MRA shows normal or dilated cerebral artery, in contrast to stenosis or thrombosis in ischemic stroke. Elevated lactate peak on MRS is a feature seen in both.

published online
August 30, 2022

DOI https://doi.org/10.1055/s-0042-1755241.
ISSN 0971-3026.

© 2022. Indian Radiological Association. All rights reserved.
This is an open access article published by Thieme under the terms of the Creative Commons Attribution-NonDerivative-NonCommercial-License, permitting copying and reproduction so long as the original work is given appropriate credit. Contents may not be used for commercial purposes, or adapted, remixed, transformed or built upon. (https://creativecommons.org/licenses/by-nc-nd/4.0/)
Thieme Medical and Scientific Publishers Pvt. Ltd., A-12, 2nd Floor, Sector 2, Noida-201301 UP, India

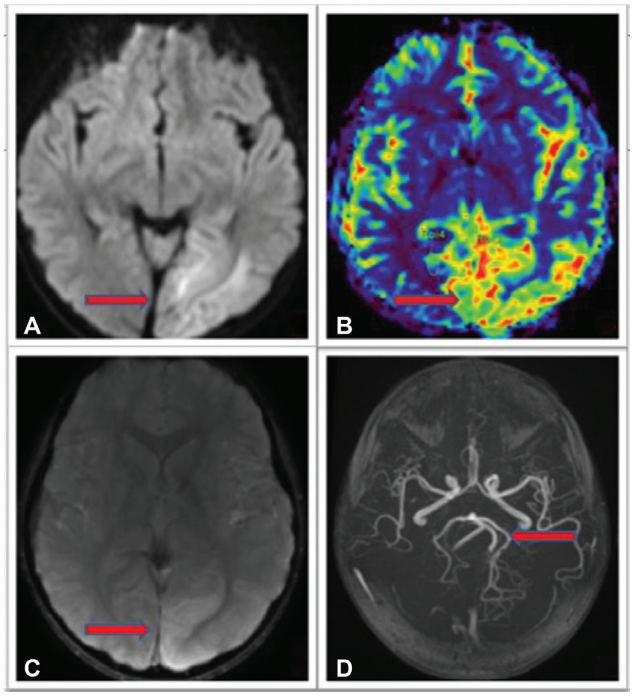

Fig. 1 Restricted diffusion on diffusion-weighted imaging (**A**), increased perfusion signals on arterial spin labeling (**B**), reduced susceptibility signals on susceptibility-weighted imaging (**C**) in left occipital region; relatively prominent left posterior cerebral artery in magnetic resonance angiography (**D**) during the first event involving left occipital lobe.

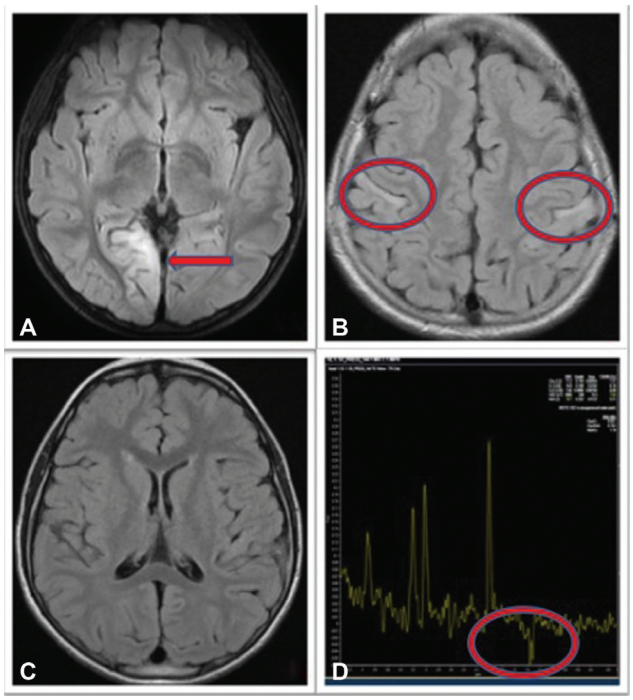

Fig. 2 Fluid-attenuated inversion recovery hyperintensity in right occipital lobe (**A**) during second event and bilateral postcentral gyri during third event (**B**). Resolution of signal changes in prior involved areas (**C**). Magnetic resonance spectroscopy showing inverted lactate peak (**D**).

Perirolandic cortex involvement in MELAS is an unusual, yet differentiating feature from vascular infarct in view of its bilaterality. It may be also be seen in hypoxic–ischemic injury and metabolic encephalopathies in patients with other distinct clinical features.

Other imaging differentials of MELAS include viral encephalitis with predominant involvement of the limbic system and status epilepticus, usually involving unilateral thalamus and hippocampus. Vasculitis presents with multifocal strokes with distinct MRA findings. Other mitochondrial disorders like Leigh syndrome with pronounced brain stem and basal ganglia involvement or Kearns-Sayre syndrome involving subcortical white matter are other differentials.

The prompt identification of MELAS in a child with acute onset neurologic deficit with expeditious neuroimaging aids acute treatment with L-arginine, leading to alleviation of deficits. It is, therefore, important to exclude other clinical and radiological mimics of MELAS. Nitric oxide (NO) deficiency contributes to the pathogenesis and hence use of NO precursors (L-arginine and L-citrulline) alleviates acute symptoms and regular supplementation results in reduction of further stroke like episodes.[5]

Source(s) of Support in the Form of Grants, Equipment, Drugs, or All of These
Manipal Hospital, Old Airport Road, Bangalore.

If the Manuscript was Presented as Part at a Meeting, the Organization, Place, and Exact Date on Which it was Read
NEUROPEDICON 2021, Bangalore, 24–10–2021.

Conflict of Interest
None.

Acknowledgment, If Any
• Banerjee, Bidisha, DM, Pediatric Neurology, Manipal Hospital, Old Airport Road, Bangalore.
• Acharya Ullas, DM, Neuroradiology, Manipal Hospital, Old Airport Road, Bangalore.
• Shetty Mitesh, Phd, Medical Genetics, Manipal Hospital, Old Airport Road, Bangalore.

References

1 Hirano M, Ricci E, Koenigsberger MR, et al. Melas: an original case and clinical criteria for diagnosis. Neuromuscul Disord 1992;2(02):125–135
2 Koga Y, Povalko N, Inoue E, et al. Therapeutic regimen of L-arginine for MELAS: 9-year, prospective, multicenter, clinical research. J Neurol 2018;265(12):2861–2874
3 Castillo M, Kwock L, Green C. MELAS syndrome: imaging and proton MR spectroscopic findings. AJNR Am J Neuroradiol 1995;16(02):233–239 Medline.
4 Kim JH, Lim MK, Jeon TY, et al. Diffusion and perfusion characteristics of MELAS (mitochondrial myopathy, encephalopathy, lactic acidosis, and stroke-like episode) in thirteen patients. Korean J Radiol 2011;12(01):15–24
5 El-Hattab AW, Almannai M, Scaglia F. Arginine and citrulline for the treatment of MELAS syndrome. J Inborn Errors Metab Screen 2017;5:1–5

 © 2022. Indian Radiological Association. All rights reserved.