



Primary Angiosarcoma of the Breast: A Rare Case Report in Postmenopausal Women

Pratibha Issar¹ Ravindranath M.² Manish Dewangan³ Arnesh Kumar Issar⁴

¹Department of Radiodiagnosis, J.L.N Hospital and Research Centre, Bhilai, Chhattisgarh, India

²Department of Pathology, J.L.N. Hospital and Research Centre, Bhilai, Chhattisgarh, India

³Department of Surgery, J.L.N. Hospital and Research Centre, Bhilai, Chhattisgarh, India

⁴Indian Institute of Technology, Kharagpur, West Midnapore District, West Bengal, India

Address for correspondence Pratibha Issar, MD, FICR, J.L.N Hospital and Research Centre, Bhilai, Chhattisgarh, 490009, India (e-mail: pratibhaissar@gmail.com).

Indian J Radiol Imaging 2022;32:607–610.

Abstract

Primary angiosarcoma (PAS) of the breast is a rare malignant tumor arising from endothelial cells lining the blood vessel and accounts for 0.04% of all breast tumors. It occurs predominantly in young patients usually presenting as nonspecific imaging features and is often overlooked and misdiagnosed at radiology and pathology. Angiosarcoma prognosis is generally poor; however, surgery followed by adjuvant chemotherapy and radiotherapy improves the prognosis. We report a rare case of PAS in a 65-year-old postmenopausal woman. She was diagnosed with PAS based on typical clinical, mammography, ultrasound, and magnetic resonance imaging (MRI) features followed by core biopsy of the lesion. Our case had the unique features of enlarged vessels within and surrounding the lesion in mammography, as well as in MRI, which could be very helpful for future diagnosis of this rare PAS in postmenopausal women.

Keywords

- ▶ primary angiosarcoma
- ▶ mammography
- ▶ ultrasound
- ▶ MRI

Introduction

Angiosarcoma of the breast is a rare tumor divided into primary and secondary. Primary breast angiosarcoma occurs in young women and presents as a palpable mass, usually in the third and fourth decades of life. Bluish skin discoloration can be seen in one-third of the patients and is attributed to the vascular nature of the tumor. Secondary angiosarcoma occurs most frequently after breast conservation therapy with radiation therapy and the average latent period is 5 to 6 years. It is scarce to see primary angiosarcoma (PAS) in old age.^{1,2}

This work is carried out at department of Radiodiagnosis, J.L.N Hospital and Research Centre, Bhilai, Chhattisgarh.

Case Report

We present a rare case of PAS in a 65-year-old woman who complained of a lump in the left breast's lower inner aspect associated with bluish discoloration of the overlying skin for 1 month. There was no history of pain, nipple discharge, hormonal therapy, trauma, breast surgery, or radiation therapy. She did not have any family history of breast cancer.

On examination, a mobile, firm consistency lump was palpated in the lower inner quadrant of the left breast. It was associated with mild bluish discoloration of the overlying skin. No axillary lymphadenopathy was noticed.

A diagnostic CR-mammogram performed on alpha-RT (GE-Wipro) showed heterogeneous dense breast with an oval, high density lesion with microlobulated margins

published online
August 30, 2022

DOI <https://doi.org/10.1055/s-0042-1754358>.
ISSN 0971-3026.

© 2022. Indian Radiological Association. All rights reserved.
This is an open access article published by Thieme under the terms of the Creative Commons Attribution-NonDerivative-NonCommercial-License, permitting copying and reproduction so long as the original work is given appropriate credit. Contents may not be used for commercial purposes, or adapted, remixed, transformed or built upon. (<https://creativecommons.org/licenses/by-nc-nd/4.0/>)
Thieme Medical and Scientific Publishers Pvt. Ltd., A-12, 2nd Floor, Sector 2, Noida-201301 UP, India

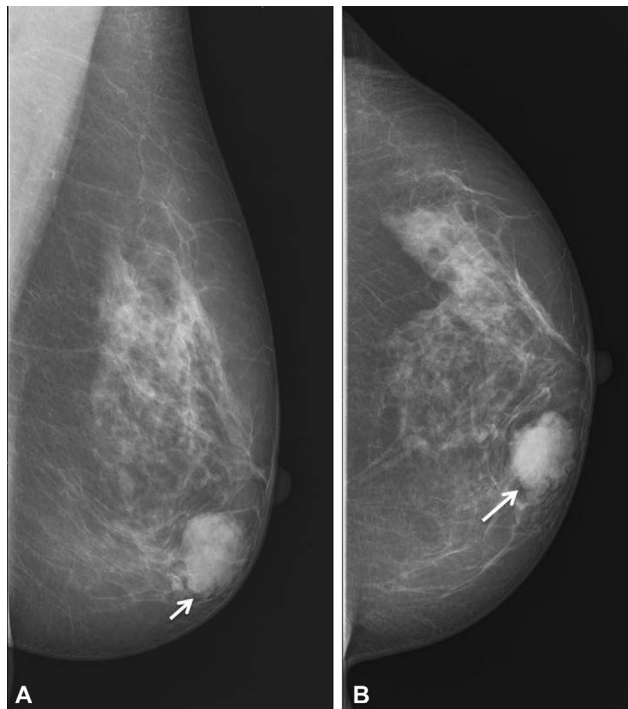


Fig. 1 Mediolateral oblique (A) and craniocaudal (B) mammogram of the left breast, showing an oval, high density mass with microlobulated margin in lower inner quadrant left breast in anterior third depth (white arrow).

measuring $\sim 3 \times 2.6$ cm in lower inner quadrant left breast in third anterior depth (\rightarrow Fig. 1). No intralesional calcification, skin thickening, nipple retraction, or axillary lymphadenopathy was appreciated. Breast imaging-reporting and data system 4 (BIRADS 4) category was assigned to the left breast mass on mammography.

A breast ultrasound (US) was performed on Samsung RS 80A, using a 4 to 18 MHz linear probe with an elastography facility. The US revealed an irregular shape, parallel orientation, microlobulated margin, heterogeneously hypoechoic lesion with posterior acoustic enhancement in the left breast at 8 to 9 o'clock in zone two. The lesion showed peripheral and center vascularity with an E-Strain of 3.6. Right breast parenchyma was normal. Bilateral benign axillary lymph nodes were noticed (\rightarrow Fig. 2). BIRADS 4 lesion was suspected on US imaging.

Plain and contrast magnetic resonance imaging (MRI) of the breast were performed for further assessment of the characteristics and extent of the lesion. MRI of the breast was done on a 1.5 Tesla MR system (GE Signa Excite) using a

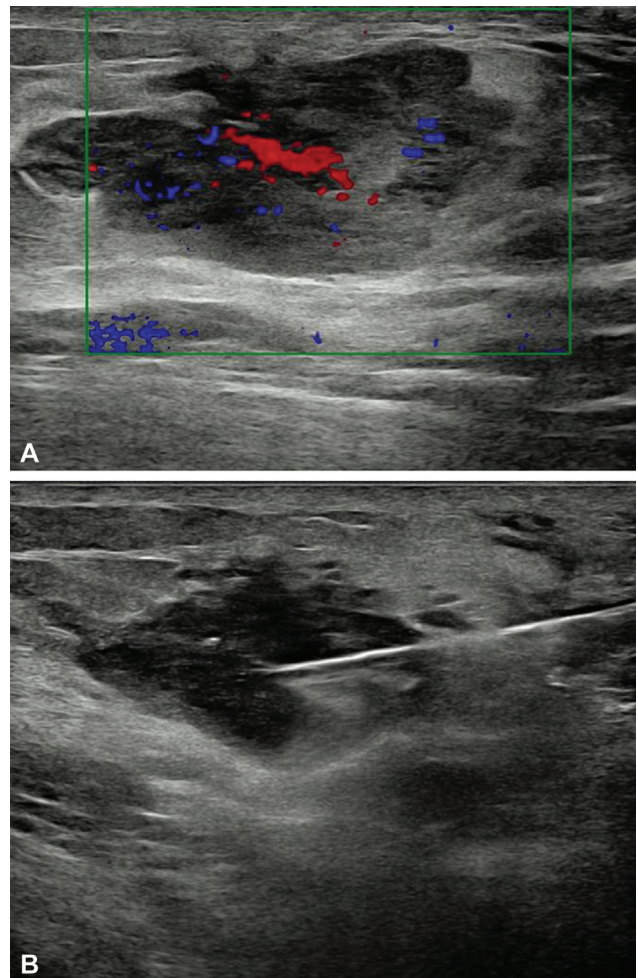


Fig. 2 Ultrasonography demonstrates an irregular shape, parallel orientation, microlobulated margins, heterogeneously hypoechoic mass with posterior enhancement in left breast at 8 to 9 o'clock position in zone two with an area of increased vascularity (A). A biopsy needle is seen within the lesion (B).

dedicated eight-channel breast coil. On MRI examination, bilateral breast tissue was heterogeneous fibroglandular with minimal background parenchymal enhancement. An oval-shaped, irregular margin, altered signal intensity lesion measuring 3×2.5 cm was seen in the lower inner quadrant of the left breast at 8 o'clock. The lesion appears hypointense on T1-weighted (T1WI) images (\rightarrow Fig. 3A), heterogeneous hyperintense on T2-weighted (T2WI), and T2 fat saturated images (\rightarrow Fig. 3B). Few areas showed diffusion-weighted imaging restriction with the

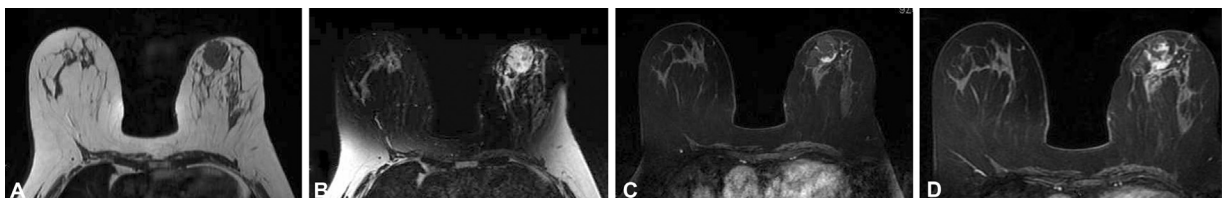


Fig. 3 The lesion appears hypointense on T1-weighted images (A), heterogeneous hyperintense on T2 fat-saturated images (B). On dynamic postcontrast evaluation, heterogeneous enhancement of the mass seen with dilated vessel within as well as on the periphery of the lesion. Early (C) and delayed postcontrast images (D).

hypointense signal on the apparent diffusion coefficient (ADC) map (ADC value 1.12×10^{-9}). The lesion was isointense on precontrast images. On dynamic postcontrast evaluation, heterogeneous enhancement of the mass with type II kinetic curve (early rapid uptake of contrast with persistent delayed enhancement) was noticed. Dilated vessels were seen within and on the periphery of the lesion. While early images showed peripheral enhancement, delayed images showed contrast enhancement in the central portion of the tumor (►Fig. 3C, D). No invasion of underlying pectoral fascia, muscles, or the overlying skin was seen. No enlarged axillary lymphadenopathy was identified. Above findings point toward BIRADS 4 lesion in the left breast.

Based on bluish skin discoloration, dilated tubular structure within and in the periphery of the lesion on mammography, US features of hypervascularity, absence of axillary lymphadenopathy, MRI features of heterogeneous enhancement with center contrast enhancement in the delayed phase led to the possible diagnosis of PAS of the breast.

Consequently, a core biopsy was performed under US guidance with a sample taken from multiple sites. Histopathological examination revealed a predominantly necrotic vascular neoplasm compressing closely proliferating hyalinized blood vessels lined by neoplastic endothelial cells expressing CD31 and CD34 with a Ki 67 index of 30 to 40%. These cells do not express pan CK. Mitotic rate was 5 to 6 per high power examination. Features were suggestive of angiosarcoma of the breast (►Fig. 4A–D).

The patient underwent a modified radical mastectomy. There was bluish discoloration of skin in the medial, lower quadrant. On the cut section deep to the bluish skin discoloration, a gray-brown area measuring $3.5 \times 2 \times 2$ cm was noticed 1 cm below the skin margin. The microscopic section studied shows varying sizes of the blood vessel. Some of which were ectatic and some have a slit-like appearance. These vascular spaces were lined by round to oval spindle-shaped cells, with finely dispersed chromatin, inconspicuous nucleoli, and moderate cytoplasm. The vascular channels were seen communicating with each other, forming a net-

work of sinusoids. These vascular channels were seen dissecting through the subcutaneous fat and collagen. Few mitotic figures were seen, along with the area of hemorrhage and necrosis. Nipple-areola and deep surgical margins were free of tumor infiltration. No lymph node involvement was seen. On immunohistochemistry (IHC), tumor cells were positive for CD34/CD31 and negative for pan CK with a Ki 67 index of 20 to 25%. A diagnosis of low-grade angiosarcoma of the left breast was made.

Discussion

Angiosarcoma is a rare malignant tumor arising from vascular endothelial cells. PAS is rare and constitutes 0.04% of all malignant breast tumors.¹ Angiosarcoma of the breast can have no known risk factors and often develops in young women. Very few cases of PAS have been reported in postmenopausal women. Secondary angiosarcoma develops mainly after breast conservative therapy accompanied by radiation therapy. Angiosarcoma arising in the region of chronic lymphedema after conservative breast therapy regardless of radiation exposure is known as Stewart Treves syndrome.^{3–5}

PAS usually arises in younger women in their third and fourth decades of life and is often associated with pregnancy. These patients typically present with a painless discrete palpable mass that grows rapidly, and ~2% of patients may present with diffuse enlargement of the breast. Bluish discoloration of the overlying skin may be there in one-third of patients and is attributed to the vascular nature of the tumor.^{6,7}

PAS may be missed on mammography due to the high density of breasts in young women. They may present focal asymmetry or masses with round, oval, or irregular shapes and may exhibit circumscribed or indistinct margins. They lack speculation and microcalcification, often seen in breast carcinomas. Sonography usually shows a mass with circumscribed or indistinct margins, with hypo or heterogeneous echotexture. Acoustic enhancement may be seen. Color Doppler may show hypervascularity.^{8–11}

MRI of angiosarcoma shows a mass with a hypointense signal on T1WIs and a hyperintense signal on T2WIs. The latter suggests the presence of a vascular channel containing slow-flowing blood. Irregular area of high T1 signal may be seen in the high-grade lesions; these represent the area of hemorrhage or venous lakes. Low-grade angiosarcoma shows progressive enhancement. High-grade angiosarcoma shows rapid enhancement and washout or persistent enhancement. MRI is useful in the presurgical evaluation of the patient.^{12,13} Three grades of PAS have been described, namely (a) low-grade (comprising of anastomosing vascular channels that invade the surrounding breast tissue), (b) intermediate-grade (solid neoplastic vascular growth and an increased mitotic rate, and (c) high-grade (frankly sarcomatous areas with an area of necrosis, hemorrhage, and infarction). Five years survival rate for low-grade angiosarcoma can be 76%, while 70% for intermediate grade and ~15% for high grade. Large-sized tumors of PAB can lead to

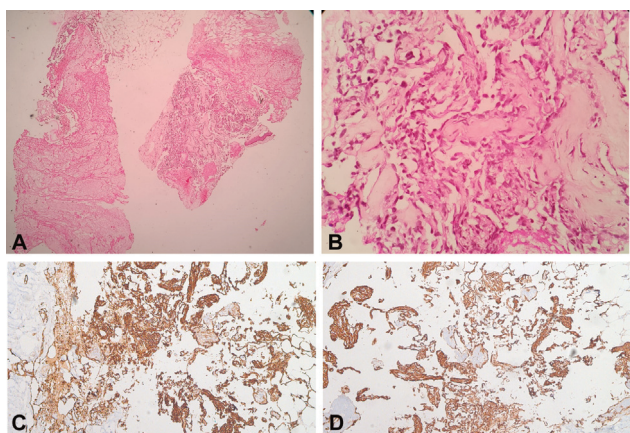


Fig. 4 Ectatic vascular spaces lined by atypical endothelial cells and surrounded by collagenous stroma, low power (A), high power (B). Immunohistochemistry showing positive tumor cells for CD34 (B) and CD31 (C).

thrombocytopenia and hemorrhagic manifestations (Kasabach-Merritt syndrome).

IHC for specific biomarkers can differentiate angiosarcoma from invasive carcinomas (ductal/lobular), absence of cytokeratin, and presence of endothelial markers such as CD31 and CD34 confirm angiosarcoma. CD31 is more specific, and CD34 is a more sensitive marker for endothelial differentiation.

Positron emission tomography with fluorodeoxyglucose (FDG) helps in tumor staging by showing FDG uptake in regions with angiosarcoma spread.

PAS of the breast in a postmenopausal female is very rare. Very few cases have been reported till now. Previous studies have reported cases of PAS of the breast in 60-year and 70-year-old postmenopausal women, where only the US was done. It showed a cystic lesion with an internal hypoechoic mural nodule associated with vascularity or a pure cystic lesion.^{14,15}

In our case, we have investigated the patient through mammography, US, and MRI. After a core biopsy of angiosarcoma, a metastatic workup was done, which came out to be negative. Mastectomy was performed, and the final diagnosis was low-grade PAS. Differential diagnosis of this rare malignancy includes benign hemangioma, hamartoma, stromal sarcoma, malignant phyllodes, metaplastic carcinoma, fibromatosis, fibrosarcoma, liposarcoma, and reactive spindle cell proliferative lesions.¹²

The treatment is primarily surgical, either by mastectomy or wide excision. Axillary clearance is unnecessary for all patients because angiosarcoma does not usually follow a lymphatic way of dissemination. Chemotherapy and radiation therapy are needed in patients with high-grade tumors and distant metastasis. Common sites of metastasis of PAS of the breast are skin, lung, bone, liver, brain, and ovary.

Conclusion

Our case report of PAS in a postmenopausal woman is a rare case showing typical bluish discoloration of overlying skin, dilated vessels on mammography, and MRI with the increased center as well as peripheral vascularity on US. All these findings can help in early diagnosis of Angiosarcoma so that timely management is possible.

Ethical Approval

This case was approved by the ethical committee for publication.

Conflict of Interest

The authors declare to have no conflict of interest.

Authors' Contributions

Pratibha Issar performed diagnostic workup and preparation of the manuscript. M Ravindranathan provided pathology and immunohistologic images. Manish Dewangan operated on the case. Arnesh Kumar Issar was involved in manuscript revision, preparation, and compilation.

References

- 1 Vorburger SA, Xing Y, Hunt KK, et al. Angiosarcoma of the breast. *Cancer* 2005;104(12):2682–2688
- 2 Glazebrook KN, Magut MJ, Reynolds C. Angiosarcoma of the breast. *AJR Am J Roentgenol* 2008;190(02):533–538
- 3 Desbiens C, Hogue J-C, Lévesque Y. Primary breast angiosarcoma: avoiding a common trap. *Case Rep Oncol Med* 2011;2011:517047. Doi: 10.1155/2011/517047
- 4 Lim RF, Goei R. Best cases from the AFIP: angiosarcoma of the breast. *Radiographics* 2007;27(Suppl 1):S125–S130
- 5 Brown AL, Wahab RA. MRI of primary angiosarcoma of the breast. *Radiology* 2020;297(01):31. Doi: 10.1148/radiol.2020201377
- 6 Bordoni D, Bolletta E, Falco G, et al. Primary angiosarcoma of the breast. *Int J Surg Case Rep* 2016;20S:12–15
- 7 Bennani A, Chbani L, Lamchahab M, et al. Primary angiosarcoma of the breast: a case report. *Diagn Pathol* 2013;8:66
- 8 Pandey M, Martin MG. Primary angiosarcoma of the breast: a case report and review of literature. *World J Oncol* 2014;5(03):144–148
- 9 Varghese B, Deshpande P, Dixit S, Koppiker CB, Jalnapurkar N. Primary angiosarcoma of the breast: a case report. *J Radiol Case Rep* 2019;13(02):15–25
- 10 Vimugdha P, Shubhangi A, Anjum S, et al. Primary breast angiosarcoma in a postmenopausal female. *Breast J* 2020;26(11):2257–2259
- 11 Lee K, Jin Seo K, Whang Y. Primary angiosarcoma of the breast: MRI findings. *iMRI* 2018;22:194–199
- 12 Bhosale SJ, Kshirsagar AY, Patil MV, Wader JV, Nangare N, Patil PP. Primary angiosarcoma of breast: a case report. *Int J Surg Case Rep* 2013;4(04):362–364
- 13 Nagarajan BV, Autkar GM, Lad SV. Primary angiosarcoma of the breast: a case report with multimodality imaging workup. *International Journal of Anatomy, Radiology and Surgery* 2020;9(01):RC09–RC11
- 14 Rohan VS, Hanji AM, Patel JJ, Tankshali RA. Primary angiosarcoma of the breast in a postmenopausal patient. *J Cancer Res Ther* 2010;6(01):120–122
- 15 Athar M, Singh S, Chaudhary AK, et al. Primary angiosarcoma of the breast in a seventy-year-old female: a rare case report. *Ann Res Hosp* 2017;1:7