




EUS-Guided Rendezvous and Tractogastrostomy: A Novel Technique for Disconnected Pancreatic Duct Syndrome with External Pancreatic Fistula

Vikas Singla¹  Anil Arora² Surinder Singh Rana³ Manoj Kohle² Shivam Khare² Ashish Kumar²
Naresh Bansal² Praveen Sharma²

¹ Center for Gastroenterology, Hepatology and Endoscopy, Max Superspeciality Hospital, Saket, New Delhi, India

² Institute of Liver, Gastroenterology and Pancreaticobiliary Sciences, Sir Ganga Ram Hospital, New Delhi, India

³ Department of Gastroenterology, Postgraduate Institute of Medical Education and Research, Chandigarh, India

Address for correspondence Vikas Singla, MD, DM, Center for Gastroenterology, Hepatology and Endoscopy, Max Superspeciality Hospital, Saket, New Delhi 110017, India (e-mail: singlavikas1979@gmail.com).

J Digest Endosc 2022;13:129–135.

Abstract

Background and Aims External pancreatic fistula occurring in the setting of disconnected pancreatic duct syndrome leads to significant morbidity, often requiring surgery. The aim of this study is to report a new technique of endoscopic ultrasound (EUS)-guided rendezvous and tractogastrostomy in patients with disconnected pancreatic duct syndrome and external pancreatic fistula.

Methods This study is retrospective analysis of the data of the patients with external pancreatic fistula who had undergone EUS-guided rendezvous and tractogastrostomy. Internalization of pancreatic secretions was performed by placing a stent between tract and the stomach. Technical success was defined as placement of stent between the tract and the stomach. Clinical success was defined as removal of external catheter and absence of peripancreatic fluid collection, ascites or external fistula at 3 months after the tractogastrostomy.

Results Four patients, all male, with median age of 33.5 years (range: 29–45), underwent EUS-guided tractogastrostomy. Technical and clinical success was 100%, without any procedure related complication. External catheter could be removed in all the patients. During the median follow-up of 10.5 months (range: 8–12), two patients had stent migration and peripancreatic fluid collection, which were managed by EUS-guided internal drainage.

Conclusions EUS-guided rendezvous and tractogastrostomy are a safe and effective technique for the treatment of external pancreatic fistula.

Keywords

- ▶ acute pancreatitis
- ▶ EUS-guided tractogastrostomy
- ▶ external pancreatic fistula

DOI <https://doi.org/10.1055/s-0042-1754334>.
ISSN 0976-5042.

© 2022. Society of Gastrointestinal Endoscopy of India. All rights reserved.

This is an open access article published by Thieme under the terms of the Creative Commons Attribution-NonDerivative-NonCommercial-License, permitting copying and reproduction so long as the original work is given appropriate credit. Contents may not be used for commercial purposes, or adapted, remixed, transformed or built upon. (<https://creativecommons.org/licenses/by-nc-nd/4.0/>)

Thieme Medical and Scientific Publishers Pvt. Ltd., A-12, 2nd Floor, Sector 2, Noida-201301 UP, India

Introduction

In patients with acute pancreatitis, percutaneous catheter drainage (PCD) is an important intervention in the management of infected pancreatic fluid collections.¹ Acute necrotizing pancreatitis (ANP) may be associated with either partial or complete disruption of pancreatic duct (PD). PCD in the setting of PD disruption can lead to development of external pancreatic fistula (EPF).¹ EPF formation is an important cause of significant morbidity in patients with pancreatitis.

The management options for EPF include conservative treatment or interventional treatment in the form of either endoscopic or surgical therapy. Conservative therapy in the form of prolonged fasting, nasojejunal feeding, parenteral nutrition, and administration of somatostatin or octreotide, has variable success rates.² Surgery is usually effective in majority of patients, but is associated with significant morbidity. Endoscopic transpapillary drainage is a minimally invasive, safe, and effective therapeutic option for the management of patients with EPF and is considered as treatment of choice for patients with EPF. Studies have shown that endoscopic transpapillary drainage is successful when the PD disruption is partial and can be bridged with endoprosthesis.³ The results of endoscopic drainage are usually poor when the disruption is complete and cannot be bridged by endoprosthesis.⁴

Complete PD disruption with viable upstream pancreatic parenchyma leads on to disconnected pancreatic duct syndrome (DPDS). Upstream viable parenchyma keeps secreting the pancreatic juices, which follows the path of least resistance leading to persistent EPF. The natural history of EPF with DPDS has been infrequently studied. A recent study has suggested that low-output (<200 mL/day) EPF in patients with DPDS secondary to ANP may heal spontaneously due to atrophy of the upstream pancreatic parenchyma.⁵ However, patients with high-output EPF with DPDS are a therapeutic challenge as untreated high EPF frequently leads to malnutrition, electrolyte imbalance, and infective complications. Surgical resection or drainage of upstream pancreas is the therapeutic option, but is associated with high morbidity.⁶ In recent years, several complex endoscopic interventions including endoscopic ultrasound (EUS)-guided transmural interventions have been described for successful treatment of patients of EPF with DPDS.⁷⁻⁹ Various endoscopic options described include artificial creation of fluid collection via PCD followed by EUS-guided internal drainage, EUS-guided transmural drainage of PD of upstream viable pancreatic parenchyma, and combined endoscopic/percutaneous rendezvous procedures to internalize the fistula.⁸ In this study, we report the efficacy and safety of a novel EUS-guided technique of internalizing the EPF in patients with DPDS.

Patients and Methods

This study is retrospective analysis of prospectively collected database of patients with EPF following acute pancreatitis at a tertiary care center of North India. The database between

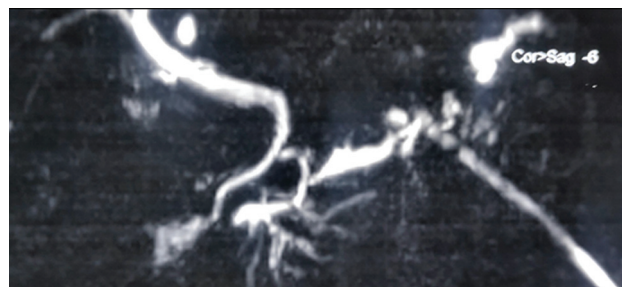


Fig. 1 Magnetic resonance cholangiopancreatography study showing complete ductal disconnection.

January 2019 and December 2019 was searched to identify patients who underwent internalization of EPF using a novel technique of EUS-guided rendezvous and tractogastrostomy. This novel EUS-guided drainage technique was attempted in patients of EPF with DPDS who had tip of PCD catheter located close to the stomach and attempts to create artificial fluid collection by injecting fluid through PCD failed. The demographic, clinical as well as procedural and follow-up data were retrieved from the database. Institutional review board approved the study protocol (EC/02/20/1680), and an informed consent for the procedure was obtained from all the patients after explaining in detail about this novel technique and possible complications, as well as alternative treatment options including surgery. All included patients had EPF, after PCD for walled off pancreatic necrosis occurring in the setting of acute pancreatitis. EPF was defined as cutaneous fistula draining more than 50 mL amylase rich fluid, persisting after stabilization of episode of acute pancreatitis. DPDS was defined based on magnetic resonance cholangiopancreatography (MRCP) or endoscopic retrograde cholangiopancreatography (ERCP) findings.^{10,11} MRCP criteria were complete ductal discontinuation with residual upstream pancreatic parenchyma (► **Fig. 1**). During ERCP, DPDS was defined as ductal discontinuation and inability to demonstrate upstream PD on pancreatogram (► **Fig. 2**). The included patients had EPF persisting for more than 6 weeks and none of the patients received parenteral nutrition or octreotide.

EUS-Guided Tractogastrostomy

All the procedures were performed by two endoscopists (VS/AA), under moderate sedation with propofol, in the left lateral position. All the patients received prophylactic intravenous antibiotics. Transgastric echoendosonography was performed using a linear echoendoscope (GF UCT 180, Olympus, Gurugram, Haryana, India). Initially, PCD catheter tip was localized using EUS examination and fluoroscopy. During EUS examination, the PCD catheter was seen as two echogenic lines (► **Fig. 3**). After localization of PCD catheter, transgastric puncture was made with 19 G EUS fine-needle aspiration (Expect 19G, Boston Scientific, Gurugram, Haryana, India) needle, and tip of the needle was placed close to the PCD catheter (► **Fig. 4**). Thereafter, a 0.035" hydrophilic guide wire (Terumo Corporation, Shibuya-Ku, Tokyo, Japan) was passed through the needle. Wire was maneuvered under

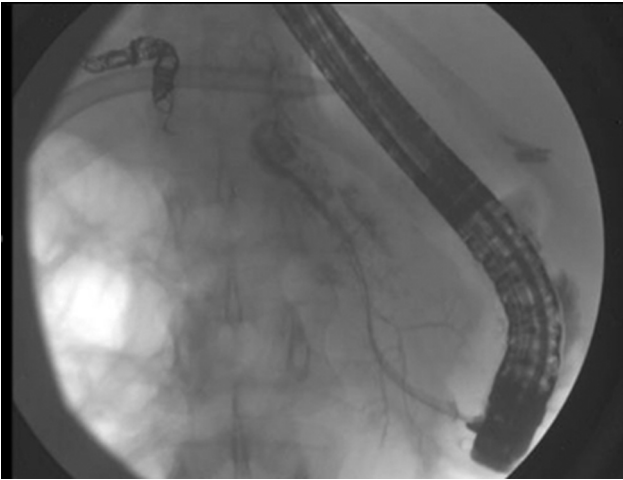


Fig. 2 Endoscopic pancreatography showing complete cutoff and failure to opacify pancreatic duct in body and tail region.

fluoroscopy, and manipulated to glide alongside the drain, till it exited at the site of PCD catheter (►**Fig. 5**). No endoscopic or percutaneous accessory was used for manipulation or grasping the wire. Once the wire exited from the fistula site, it was grasped with artery forceps, and secured. After securing guide wire, the transmural tract was dilated using 6 Fr cystotome (Endoflex, GmbH, Voerde, Germany, pure cut mode, effect 5, 100W) followed by dilatation with 6 mm biliary balloon (Hurricane, Boston Scientific, Gurugram, Haryana, India). Dilatation was performed throughout the tract from gastric puncture site to the external fistula site. This was followed by placement of 10 Fr, 5 cm double pigtail plastic stent (C-Flex Boston Scientific, Gurugram, Haryana, India) between gastric lumen and the tract. Following stent placement, exchange wire (0.025" Visiglide Olympus, Gurugram, Haryana, India or 0.035" Jagwire, Boston, Gurugram, Haryana, India) was passed through the tract and secured both at PCD catheter site and outside the endoscope channel. Over the wire, 7 Fr 7cm double pigtail stent (Drain X, Endomed, New Delhi, India) was placed (►**Fig. 6**). In all the patients, two stents were placed between gastric lumen and the tract (►**Fig. 7**). First stent was pushed through the working channel of the scope, whereas

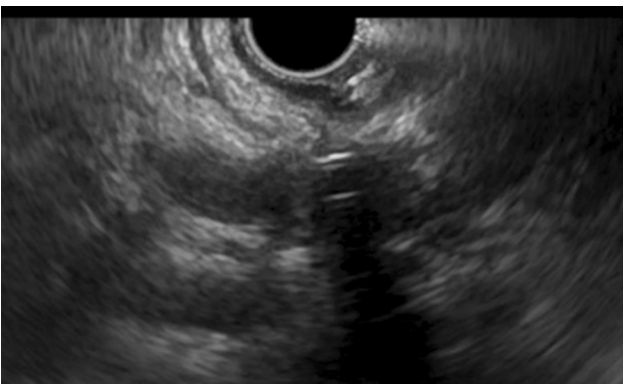

Fig. 3 Transgastric endoscopic ultrasonography showing percutaneous catheter as two echogenic lines.

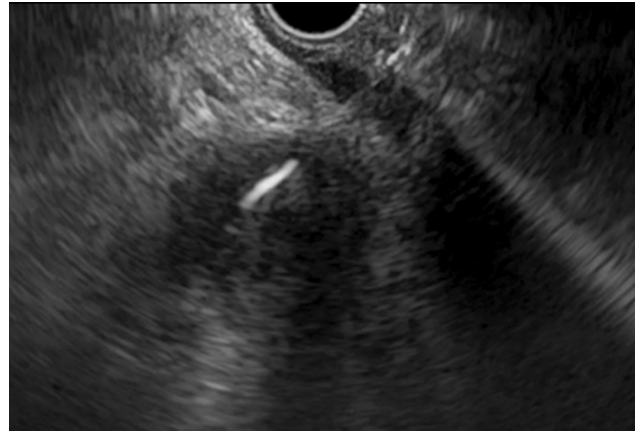

Fig. 4 Endoscopic ultrasound-guided puncture with 19G needle around the drain.

the second stent was deployed either through the scope or through the external fistula site. Two stents were chosen to reduce the risk of migration. All the adverse events during the procedure were recorded.

Follow-Up

All the patients were admitted for 72 hours after the procedure and were given intravenous antibiotics. Liquid diet was allowed next day. Patients were discharged on day 4 with the advice to follow up in the clinic.

Removal of external drain: Drains were clamped after 24 hours of the procedure. Transabdominal ultrasonography was performed after 7 days, and if there was no ascites or localized collection, percutaneous drains were removed. Follow-up evaluation was done clinically and with transabdominal ultrasonography at 15, 30, 60, and 90 days after

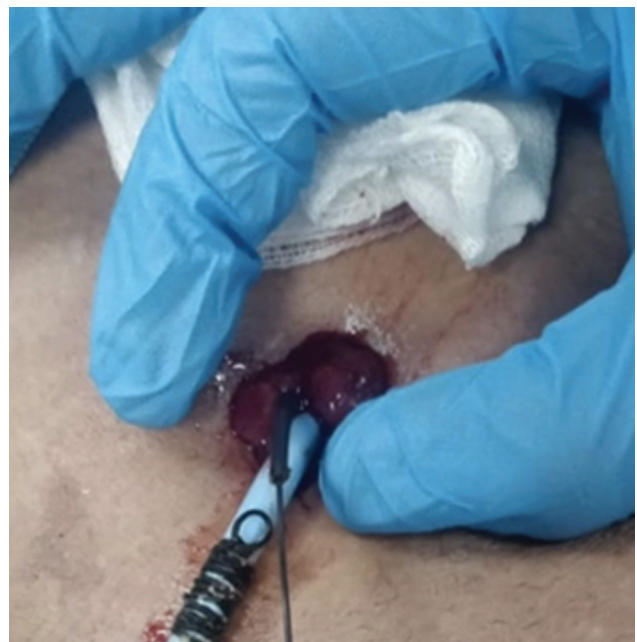

Fig. 5 Exit of guide wire at percutaneous catheter site.

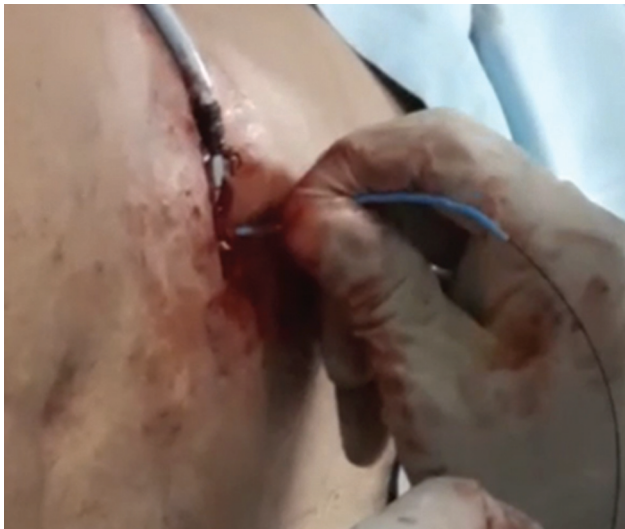

Fig. 6 Deployment of 7 Fr stent from percutaneous catheter site.

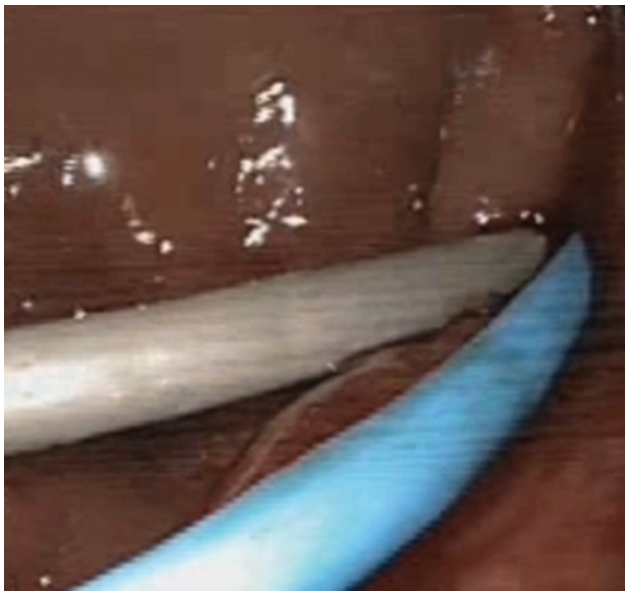

Fig. 7 Final deployment of two stents between gastric lumen and tract.

the procedure. Adverse effects, if any, were retrieved from the endoscopic as well as follow-up database.

Study Definitions

Technical success: Successful placement of pigtail stent to create tractogastrostomy. Successful closure of EPF with complete cessation of drainage of pancreatic juice from cutaneous site and no formation of any new fluid collection or ascites at 12 weeks after the procedure without any need of additional endoscopic or surgical procedure.

Results

Four patients underwent EUS-guided tractogastrostomy for EPF associated with DPDS. Baseline, intra-procedural, and follow-up findings have been summarized in **Table 1**. Me-

dian age was 33.5 years (range: 29–45), and all the patients were male. Median duration of EPF was 32 (range: 13–52) weeks. Median drain output was 300 mL (range: 250–400); etiology of acute pancreatitis was biliary and idiopathic in two patients each. No of PCD catheters were 1 and 2 in two patients each. Endoscopic transpapillary drainage failed in all these patients because of complete disruption of the PD. Site of disruption was body and tail in two patients each.

Technical success could be achieved in all the patients with placement of stent between tract and gastric lumen. No difficulty was encountered in negotiating the guide wire along the tract of PCD catheter in any of these patients. In three patients, both the plastic stents were placed through the echoendoscope, whereas in one patient one stent was pushed through the echoendoscope, whereas the other stent was pushed through the PCD catheter site. The median duration of procedure was 45 minutes (range: 35–60 minutes) and no procedural or anesthesia related complication occurred in any patient. The PCD could be removed in all the patients at 7th day after the procedure. Three patients had uneventful course and were discharged after 72 hours. One patient developed abdominal pain after the procedure that required prolonged admission for 7 days. There was no evidence of gastric leak, pancreatic fluid collection, or ascites in this patient, and the pancreatic enzymes levels were normal.

Outcome after Endoscopic Intervention

Treatment was successful in all the patients. At 3 months follow-up, none of the patients had recurrence of external fistula, ascites, or peripancreatic collection. On further follow-up, two patients had peripancreatic fluid collection (PFC) at 6 months follow-up after EUS-guided tractogastrostomy; plastic stents had migrated in both the patients. Both these patients could be successfully treated with EUS-guided transmural drainage and the plastic stents were left permanently in situ. After median follow-up of 10.5 months (range: 8–12), all the four patients are asymptomatic and none of the patients had developed endocrine or exocrine insufficiency.

Discussion

DPDS with EPF is a complex clinical situation requiring specialized care. The situation mostly occurs after an attack of moderate-to-severe acute pancreatitis leading to PD necrosis and disruption. Continuous medical care, surgery, or complex endoscopic procedures are usually the next line of management. Recent study by Rana et al⁵ has shown that conservative treatment may be effective in the patients of DPDS and EPF with low output because of gradual atrophy of residual upstream pancreatic parenchyma. The strategy of wait and watch cannot be followed in patients with high-output fistula as they usually do not respond to non-interventional measures and also have higher frequency of metabolic, nutritional, and infective complications.^{12,13} Surgery, the only effective therapeutic option in this situation, is associated with high morbidity.

Table 1 Baseline data and treatment outcome

	Patient 1	Patient 2	Patient 3	Patient 4
Age, years	29	45	35	32
Gender	Male	Male	Male	Male
Etiology	Biliary	Idiopathic	Idiopathic	Biliary
Underlying disease	Acute pancreatitis	Acute pancreatitis	Acute pancreatitis	Acute pancreatitis
No of percutaneous drainage catheters	Two	One	Two	One
Site of percutaneous drains	Left paracolic, epigastric	Left paracolic	Left paracolic, epigastric	Left paracolic
ERCP attempted	Yes	Yes	Yes	Yes
MRCP: Site of ductal discontinuation	Body	Body	Neck	Neck
Interval between tractogastrostomy and fistula formation, weeks	13	34	30	52
Daily drain output, mL/day	250	300	400	300
Drain fluid amylase IU/L	82,950	40,500	22,300	44,000
Duration of procedure, minutes	50	60	40	35
Complications	Nil	Nil	Pain abdomen, lasting for 5 days	Nil
Day 7 USG	No collection	No collection	No collection	No collection
Day 30 USG	No collection	No collection	No collection	No collection
Day 90 USG	No collection	No collection	No collection	No collection
Successful closure of EPF at 90 days	Yes	Yes	Yes	Yes
Duration of follow-up, months	12	12	9	8
Events during follow-up	Stent migration, fluid collection at 6 months, EUS-guided transmural drainage	Stent migration, fluid collection at 8 months, EUS-guided transmural drainage	None	None

Abbreviations: EPF, external pancreatic fistula; ERCP, endoscopic retrograde cholangiopancreatography; EUS, endoscopic ultrasound; MRCP, magnetic resonance cholangiopancreatography; USG, ultrasonography.

Recently, complex endoscopic procedures have been described for the treatment of DPDS with EPF.⁷⁻⁹ The basic principle of these complex endoscopic procedures is to internalize the EPF by placing a long-term indwelling transmural stent between the tract and the stomach. This will create an alternate path for the fluid to track inside the stomach, leading to closure of external fistula. As there is no fluid collection around the tract, the exact puncture of tract becomes challenging. Various techniques have been described in the literature to overcome this difficulty. External drain can be clamped leading to formation of fluid collection, which can be drained endoscopically.⁹ In a subset of patients, external drain passes through the stomach, which gives an opportunity to internalize the external drain.¹⁴ Other techniques include EUS-guided transmural drainage of coexis-

tent PFC⁷ or artificial PFC created by injection of water or contrast medium through PCD⁹ or EUS-guided transmural drainage of PD (if dilated) of disconnected segment of pancreas (pancreatico-gastrostomy/pancreatico-duodenostomy).^{7,15} Direct EUS-guided puncture of the fistula tract and creation of tract between fistula path and stomach has also been described (tractogastrostomy).⁷⁻⁹

Various techniques of creating EUS-guided tractogastrostomy have been described in the literature. Irani et al⁸ reported a combined endoscopic and percutaneous rendezvous technique to close EPF associated with DPDS in a case series of 15 patients. In this technique, a tractogastrostomy was created using an outside-in interventional radiologist-guided transgastric or transduodenal puncture technique. A stiff guide wire and the transjugular intrahepatic

portosystemic shunt needle were passed from the existing percutaneous site. Thereafter, impression of needle was seen during endoscopy, which guided the puncture site. An important limitation of the technique is that since it is a blind outside to inside puncture, there is a theoretical risk of injury to blood vessels around the stomach or duodenum. In few patients, authors also directly punctured the tract directly under EUS guidance and the guide wire was passed in the tract that was grasped with a basket that was passed from outside through the percutaneous tract. In our technique of tractogastrostomy, the tract was directly punctured under EUS guidance avoiding blood vessels and the guide wire was manipulated from inside with no assistance from the radiologist to grasp the wire. The wire could be negotiated across PCD catheter easily in all the four patients. No instrument was passed blindly inside the track, obviating the risk of vascular injury or leakage from the tract. We relied on manipulation of hydrophilic guide wire to guide it through the tract.

In a case series by Arvanitakis et al,⁷ three patients were treated by tractogastrostomy. In these patients, outside-in transgastric or transduodenal puncture technique was used, and EPF closed in two patients. Rana et al⁹ published data of 18 patients with DPDS and EPF, one patient underwent direct EUS-guided puncture of tract, and the wire was left in the tract without exit at the external drain site, and stent was placed between tract and gastric lumen. We chose to bring the wire from outside at the external site of fistula, which confirms that wire is truly inside the tract and rules out the possibility of false tract formation and leakage from the tract.

A recent meta-analysis has shown superiority of transmural drainage over the transpapillary drainage in the management of DPDS.¹⁶ Studies with pancreatic fluid collections and the EPF were included in the analysis. In our study, all the patients had failure of conventional ERCP and were successfully managed with transmural technique.

Highlights of our technique is gentle manipulation of hydrophilic wire inside the tract, no blind use of sharp instruments in the tract except for initial puncture, no need of assistance from radiologist, and securing the guide wire at two sites, thus decreasing the risk of accidental slippage of wire.

Though all our patients had closure of fistula at 3 months, two patients had spontaneous stent migration on follow-up leading on to formation of pseudocyst. Spontaneous migration of permanent indwelling transmural stents is seen in up to one-third of patients and can lead on to recurrence of symptoms/fluid collections.^{9,17} Pancreatic fluid collections are easier to manage than the difficult problem of EPF. Better stent design or modification of technique with lesser dilatation of transmural tract or using shorter and wider stents are the options that need to be explored by larger studies.

The main limitation of our study is the preliminary experience of small sample size; hence, conclusion regarding the safety and efficacy cannot be withdrawn with confidence. Moreover, this technique may not be feasible in all patients with EPF as it requires the tip of PCD being

close to the stomach and ability to bring the guide wire outside through PCD tract.

In conclusion, we have described a new and relatively simpler technique of EUS-guided tractogastrostomy for the successful management of EPF associated with DPDS. However, the safety and efficacy of this technique need to be evaluated in larger cohort of patients.

Conflict of Interest

None declared.

References

- van Santvoort HC, Besselink MG, Bakker OJ, et al; Dutch Pancreatitis Study Group. A step-up approach or open necrosectomy for necrotizing pancreatitis. *N Engl J Med* 2010;362(16):1491–1502
- Li-Ling J, Irving M. Somatostatin and octreotide in the prevention of postoperative pancreatic complications and the treatment of enterocutaneous pancreatic fistulas: a systematic review of randomized controlled trials. *Br J Surg* 2001;88(02):190–199
- Varadarajulu S, Rana SS, Bhasin DK. Endoscopic therapy for pancreatic duct leaks and disruptions. *Gastrointest Endosc Clin N Am* 2013;23(04):863–892
- Varadarajulu S, Noone TC, Tutuian R, Hawes RH, Cotton PB. Predictors of outcome in pancreatic duct disruption managed by endoscopic transpapillary stent placement. *Gastrointest Endosc* 2005;61(04):568–575
- Rana SS, Sharma R, Kang M, Gupta R. Natural course of low output external pancreatic fistula in patients with disconnected pancreatic duct syndrome following acute necrotising pancreatitis. *Pancreatology* 2020;20(02):177–181
- Morgan KA, Adams DB. Management of internal and external pancreatic fistulas. *Surg Clin North Am* 2007;87(06):1503–1513, x
- Arvanitakis M, Delhaye M, Bali MA, Matos C, Le Moine O, Devière J. Endoscopic treatment of external pancreatic fistulas: when draining the main pancreatic duct is not enough. *Am J Gastroenterol* 2007;102(03):516–524
- Irani S, Gluck M, Ross A, et al. Resolving external pancreatic fistulas in patients with disconnected pancreatic duct syndrome: using rendezvous techniques to avoid surgery (with video). *Gastrointest Endosc* 2012;76(03):586–93.e1, 3
- Rana SS, Sharma R, Gupta R. Endoscopic treatment of refractory external pancreatic fistulae with disconnected pancreatic duct syndrome. *Pancreatology* 2019;19(04):608–613
- Tann M, Maglinte D, Howard TJ, et al. Disconnected pancreatic duct syndrome: imaging findings and therapeutic implications in 26 surgically corrected patients. *J Comput Assist Tomogr* 2003;27(04):577–582
- Pelaez-Luna M, Vege SS, Petersen BT, et al. Disconnected pancreatic duct syndrome in severe acute pancreatitis: clinical and imaging characteristics and outcomes in a cohort of 31 cases. *Gastrointest Endosc* 2008;68(01):91–97
- Howard TJ, Stonerock CE, Sarkar J, et al. Contemporary treatment strategies for external pancreatic fistulas. *Surgery* 1998;124(04):627–632, discussion 632–633
- Lansden FT, Adams DB, Anderson MC. Treatment of external pancreatic fistulae with somatostatin. *Am Surg* 1989;55:695–698
- Rana SS, Sharma V, Bhasin DK. External pancreatic fistula with disconnected pancreatic duct treated by transmural stent insertion through the transgastric percutaneous catheter site. *Gastrointest Endosc* 2015;82(06):1130–1131, discussion 1131–1132
- François E, Kahaleh M, Giovannini M, Matos C, Devière J. EUS-guided pancreaticogastrostomy. *Gastrointest Endosc* 2002;56(01):128–133

- 16 Chong E, Ratnayake CB, Saikia S, et al. Endoscopic transmural drainage is associated with improved outcomes in disconnected pancreatic duct syndrome: a systematic review and meta-analysis. *BMC Gastroenterol* 2021;21(01):87
- 17 Rana SS, Bhasin DK, Rao C, Sharma R, Gupta R. Consequences of long term indwelling transmural stents in patients with walled off pancreatic necrosis & disconnected pancreatic duct syndrome. *Pancreatology* 2013;13(05):486–490