




Stent-Graft Migration Post-Endovascular Repair of Thoracic Aorta: A Retrospective Cohort Study

Amit Ajit Deshpande¹ Niraj Nirmal Pandey¹ Manish Shaw¹ Sanjeev Kumar¹ Priya Jagia¹
Sanjiv Sharma¹ Shiv Choudhary²

¹Department of Cardiovascular Radiology & Endovascular Interventions, All India Institute of Medical Sciences, New Delhi, India

²Department of Cardiothoracic and Vascular Surgery, All India Institute of Medical Sciences, New Delhi, India

Address for correspondence Sanjeev Kumar, MD, Department of Cardiovascular Radiology & Endovascular Interventions, All India Institute of Medical Sciences, New Delhi 110029, India (e-mail: sanjeevradio@gmail.com).

Indian J Radiol Imaging 2022;32:324–331.

Abstract

Background Migration of the stent-graft post-thoracic endovascular aortic repair (TEVAR) is not uncommon; however, it is sparsely reported. The objective of this study was to assess the incidence, risk factors, and complications of stent-graft migration post-TEVAR.

Materials and Methods Thirty-one patients who underwent TEVAR were retrospectively analyzed. The demographic, anatomical, and procedure-related factors were assessed. The measurements were done along the greater curvature of aorta around two fixed anatomic landmarks, that is, left common carotid artery or neoinnominate artery (hybrid repair) proximally and celiac artery distally. Aortic elongation and migration at proximal, distal, as well as at overlapping zone were measured. More than 10 mm of migration was considered significant.

Results Significant migration was observed in six (19%) patients. No significant migration was observed in the overlapping zone. The proximal landing zone 3 (odds ratio [OR] 12.78, p 0.01) was a significant risk factor, whereas landing zone 2 was a protective factor against the migration (OR 0.08, p 0.02). The odds for migration were more in segments I/3 and II/3 compared with I/2 and II/2, respectively, as per Modified Arch Landing Areas Nomenclature. A single complication was seen in the migration group which was treated by an overlapping stent graft.

Conclusion The stent-graft migration after TEVAR is not uncommon. Type 3 proximal landing zone was a significant risk factor for migration with an increased risk toward I/3 and II/3. Proximal landing zone 2 as well as adequate overlapping distance in multiple stent grafts can prevent migration.

Ethical Approval No IECPG-227/24.06.2020

Keywords

- ▶ TEVAR
- ▶ stent migration
- ▶ aortic dissection
- ▶ aortic aneurysm
- ▶ MALAN

published online
July 31, 2022

DOI <https://doi.org/10.1055/s-0042-1754317>.
ISSN 0971-3026.

© 2022. Indian Radiological Association. All rights reserved.
This is an open access article published by Thieme under the terms of the Creative Commons Attribution-NonDerivative-NonCommercial-License, permitting copying and reproduction so long as the original work is given appropriate credit. Contents may not be used for commercial purposes, or adapted, remixed, transformed or built upon. (<https://creativecommons.org/licenses/by-nc-nd/4.0/>)
Thieme Medical and Scientific Publishers Pvt. Ltd., A-12, 2nd Floor, Sector 2, Noida-201301 UP, India

Introduction

Thoracic endovascular aortic repair (TEVAR) for dissection, aneurysm, and pseudoaneurysm is a well-established procedure. Like any other procedure, it is associated with many intra- and postprocedural complications which can be systemic (cerebrovascular accidents or ischemic injuries to viscera, limb, or spine) and device-related (endoleaks, endograft infection, endograft collapse, or endograft migration).^{1,2} Stent-graft migration is rare and therefore often overlooked. But it can be of serious consequences such as endoleaks and pseudoaneurysm formation. The early and late migration of the aortic stent graft is discussed previously.³⁻⁵ Anatomic factors (e.g., type of aortic arch) and procedural factors (the type of proximal landing zone) can also influence the migration of stent grafts. However, there is not much evidence in the literature regarding the incidence and risk factors for stent-graft migration. The goal of this study is to evaluate the incidence, risk factors, and complications of stent-graft migration in a tertiary care institute.

Materials and Methods

This was a retrospective, cohort study done at a tertiary care institute, including all the TEVAR procedures done between March 2015 and November 2019 for type B aortic dissection (TBAD), thoracic aortic aneurysms (TAAs), or traumatic aortic injury (TAI) with at least one follow-up computed tomogram angiography (CTA) study. Procedures that required hybrid repair (neoaortic arch formation or carotid-carotid bypass) were also included in the study. Procedures without follow-up CTA scans were excluded from the study. The catheter angiography and CTA images were retrospectively analyzed for the stent-graft migration. A total of 51 TEVAR were done in the study period, out of which 31 patients were as per the inclusion criteria.

Procedure

All the TEVAR procedures were done with the oversizing of the stent graft by at least 15 to 20% and 10 to 15% in TBAD and TAA/TAI, respectively. The decision of a single or multiple stent grafts was left at the discretion of the operator. The second device was oversized by at least 20% compared with the distal diameter of the proximal device and an overlapping distance of at least 5 cm was ensured. A minimum of 1.5 cm proximal neck length was confirmed in all the cases, proximal to the entry tear in descending thoracic aorta. Accordingly, TEVAR was done with left subclavian artery coverage, hybrid repair with carotid-carotid bypass, or debranching with neoaortic arch formation for proximal landing zones 2, 1, and 0, respectively, if the proximal neck length was inadequate.

Measurements

The significant migration was defined as a migration of > 10 mm from a fixed anatomic landmark.⁵ All the measurements were done along the greater curvature of the aorta as described by Iwakoshi et al⁶ on catheter angiography images,

maximum intensity projections, and volume-rendered reconstructions of dual-source CTA (SOMATOM Force; Siemens, Germany) images. The measurements were done concerning two fixed anatomic landmarks, that is, left common carotid artery (LCCA) or neoinnominate artery (in case of hybrid repair with debranching and neoaortic arch formation) proximally and celiac artery distally. Aortic elongation was calculated as a change in distance between the two landmarks in the preprocedure and the follow-up CT scan images. The proximal migration was defined as a change in the distance between the proximal landmark and proximal-most point of stent graft along the greater curvature of the aorta (→ Fig. 1A). Similarly, distal migration was defined as a change in the distance between the distal-most point of stent graft and celiac artery ostium (→ Fig. 1A). The migration of the overlapped segment was also measured if multiple stent grafts were used (→ Fig. 1A). All the measurements were done in preprocedure CTA, catheter angiogram (wherever applicable), and follow-up CTA scans. In addition to these, the tortuosity index was calculated by dividing the distance between LCCA and the celiac artery along the greater curvature of the aorta by the straight line distance (→ Fig. 1B). Proximal landing zones and type of aortic arch were identified as per the described definitions (→ Fig. 2).^{7,8}

Statistical Analysis

The data were analyzed using MedCalc statistical software (version 14.8.1). Continuous data were represented as mean ± standard deviation and categorical data as absolute numbers and percentages. Univariate analysis was done with the Fisher's exact test for categorical data and an independent

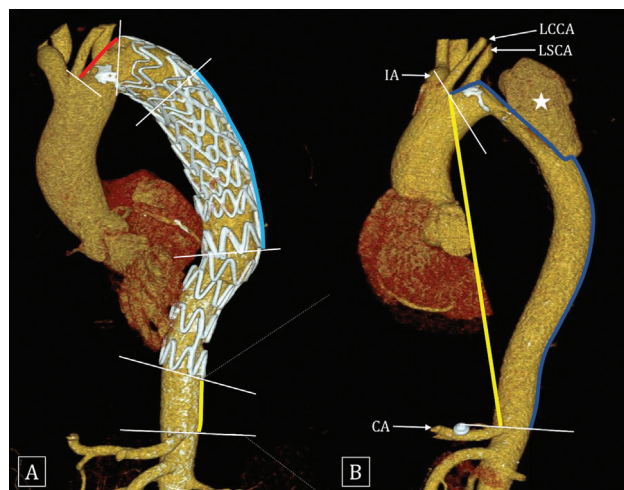


Fig. 1 Volume rendered computed tomography (CT) images show the measurements used in this study. Distance between left common carotid artery (LCCA) and proximal-most point of stent graft (red line in A) was measured for proximal migration. Distance between the distal-most part of stent graft (yellow line in A) and carotid artery (CA) was measured for distal migration. An overlapping segment of the multiple stent grafts (blue line in A) was measured for the migration of an overlapping segment. The tortuosity index was calculated by dividing the distance between LCCA and CA (blue line in B) with straight distance (yellow line in B) between the same two landmarks. All the distances were taken along the greater curvature of the aorta. Sac of the pseudoaneurysm (asterisk) is noted in B.

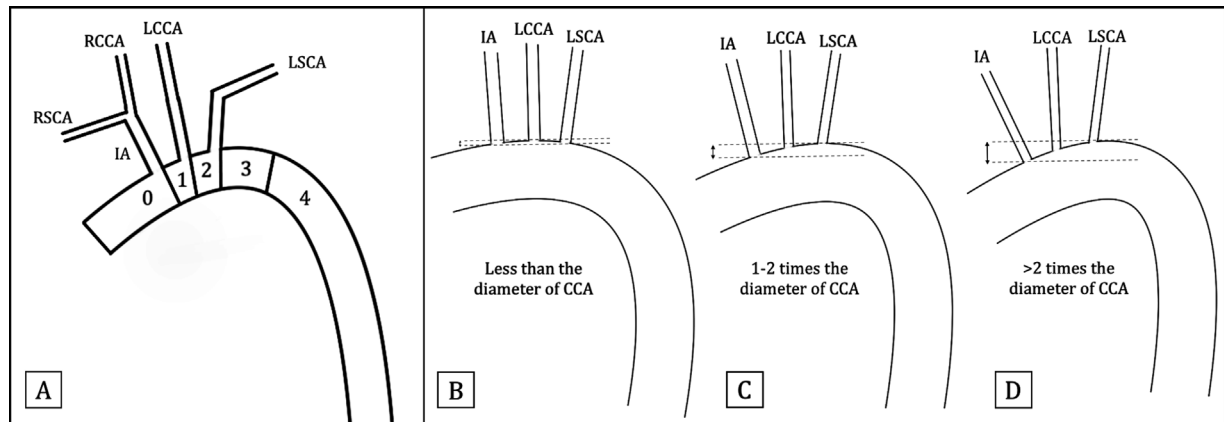


Fig. 2 Schematic diagrams showing Ishimaru's proximal landing zones of thoracic endovascular aortic repair (TEVAR) (A) and types of the aortic arch I (B), II (C), and III (D). The type of aortic arch is determined by comparing the distance between two parallel horizontal lines (at the top of the aortic arch and the ostium of innominate artery [IA]) and the diameter of left common carotid artery (LCCA). Modified Arch Landing Areas Nomenclature (MALAN) classification combines the proximal landing zone and type of aortic arch.

sample *t*-test was used for continuous data. The odds ratio (OR) with a 95% confidence interval (CI) was calculated for each risk factor.

Ethical approval was obtained from the institutional review committee for this study.

Results

The study population was predominantly male (male, 26 and female, 5) with a mean age of 51.5 ± 15.5 years. TEVAR was done for 18 (58%) type B dissections, 2 of which had aneurysmal dilatation of false lumen. Other indications were descending TAA in 11 (35.5%) patients and TAI (traumatic pseudoaneurysm) in 2 (6.5%) patients. The demographic, anatomic, and procedural details are given in **Table 1**. Mean duration of follow-up was 389 (95% CI 144–634) days. Type I aortic arch was most common (59.2% of patients). The left vertebral artery (VA) was dominant in 51.6% of cases, followed by codominant (32.3%) and right dominant VA (16.1%). Four hybrid procedures were done, three of which had a neoaortic formation and one had a carotid-carotid bypass. The majority of the stent grafts were deployed in proximal landing zone 2 and 3, comprising 86.9% of the cases. Marrocco-Trischitta et al⁹ have proposed a new nomenclature (Modified Arch Landing Areas Nomenclature [MALAN]) for proximal landing zone combining the type of arch and the Ishimaru's aortic arch map.⁸ The most common combination in this study was I/2 and I/3 comprising nearly 50% of cases. The hybrid procedure was done in three patients with neoaortic formation with proximal landing zone 0.

Ankura Stent Graft (Lifetech Scientific Ltd., Shenzhen, China) was used in 64.5% of cases, followed by Valiant Captivia thoracic stent graft (Medtronic, Santa Rosa, California, United States) in 25.8%, Zenith (Cook Inc, Bloomington, Indiana, United States) in 6.4%, and Endurant (Medtronic) in 3.2% of cases.

Significant migration was observed in six patients (three in proximal and distal migration each). Multiple devices

were used in 12 (38.7%) patients; however, none of them showed significant migration at the device-overlap segment. One patient with significant proximal migration developed a pseudoaneurysm at the distal end of stent graft. It was managed by deploying another overlapping stent graft (**Fig. 3**). None of the other patients developed any complications and were managed conservatively (**Tables 2 and 3**). Univariate analysis (**Table 4**) showed proximal landing zone type 3 was a risk factor for migration (OR 12.78, p 0.01), whereas proximal landing zone type 2 was a protective factor against the migration (OR 0.08, p 0.02). The odds of migration were more in segments I/3 and II/3 compared with I/2 and II/2, respectively, as per MALAN; however, it was not statistically significant. The risk of migration in different combinations with type III aortic arch could not be evaluated due to lack of patients in III/1 and III/3 subgroups. The aortic elongation, type of aortic arch, type of devices used, use of multiple devices, and tortuosity index were not significantly associated with the migration.

Discussion

TEVAR has become a standard of treatment for TAA, TBAD, and TAI.¹⁰ There is limited literature published on the incidence and risk factors for migration of stent graft after TEVAR. The incidence of migration was found to be 19.3% (6/31) in our study, which is higher than a few of the previously published data^{5,11–15}; however, it is consistent with the study done by Nasr et al.¹⁶

Proximal landing zone 3 was a risk factor for stent-graft migration in our study, while zone 2 was a protective factor for migration. Although none of the combinations as per MALAN classification showed a significant association, the OR showed an increasing trend for migration toward I/3 and II/3. It can be explained based on the displacement forces acting on the stent graft due to aortic angulation.^{17–19} An increase in neck angulation is a significant risk factor for migration after endovascular repair of abdominal aortic aneurysms along with proximal neck length and diameter.²⁰

Table 1 Demographic, anatomic, and procedural details of the study

Parameter	Value (N 31)
Age (in years)	51.5 ± 15.5
Male	26/31 (83.9)
Female	5/31 (16.1)
Diagnosis	
TBAD	18/31 (61.3)
TAA	11/31 (32.2)
TAI	2/31 (6.5)
Aortic tortuosity index	0.71 ± 0.08
Hybrid procedure (4/31)	
Neoaarch formation	3/4 (75)
Carotid-carotid bypass	1/4 (25)
Type of landing zones	
Zone 0	3/31(9.7)
Zone 1	1/31 (3.2)
Zone 2	19/31 (61.3)
Zone 3	7/31 (25.6)
Zone 4	1/31 (3.2)
Aortic arch anatomy ^a	
Bovine trunk	8/28 (28.6)
Common origin of LSCA and LCCA	1/28 (3.6)
Normal arch anatomy	20/28 (67.8)
Type of aortic arch ^a	
Type I	15/28 (53.5)
Type II	6/28 (21.4)
Type III	7/28 (25.1)
MALAN classification	
Neoaarch/0	3/31 (9.67)
I/1	0
I/2	8/31 (25.8)
I/3	7/31 (22.6)
I/4	0
II/1	1/31 (3.2)
II/2	4/31 (12.9)
II/3	1/31 (3.2)
II/4	0
III/1	0
III/2	7/31 (22.6)
III/3	0
III/4	0
Vertebral artery dominance	
Right	5/31 (16.1)
Left	16/31 (51.6)
Codominant	10/31 (32.3)

(Continued)

Table 1 (Continued)

Parameter	Value (N 31)
Type of device used	
Lifetech Ankura	20/31 (64.5)
Medtronic Valiant	8/31 (25.8)
Cook Zenith	2/31 (6.4)
Medtronic Endurant	1/31 (3.2)
Multiple devices	12/31

Abbreviations: LCCA, left common carotid artery; LSCA, left subclavian artery; MALAN, Modified Arch Landing Areas Nomenclature; SD, standard deviation; TAA, thoracic aortic aneurysm; TAI, traumatic aortic injury; TBAD, type B aortic dissection.

^aThree patients who underwent a hybrid procedure (neoaarch formation) were excluded. Continuous data are represented as mean ± SD and categorical data as absolute numbers (percentages in parentheses).

Marrocco-Trischitta et al^{9,19} studied the effect of type aortic arch with the type of proximal landing zone on angulation and tortuosity of the aortic arch by fluid dynamics modeling. The angulation of > 60 degrees is found to be a risk factor for migration in abdominal aortic aneurysms. The angulation is observed to be > 60 degrees in proximal landing zone 2 and 3 in combination with all three types of arches (more so in types II and III).⁹ Also, the displacement forces tend to be higher in zone 3 mainly in combination with type II and III aortic arches.²⁰ TEVAR in proximal landing zone 3 is often associated with limited proximal neck length due to anatomic constraint.²¹ A short proximal length (< 15 mm) is shown to be associated with higher chances of migration in the studies.¹⁷ So, the short proximal neck, higher displacement forces along with the angulation and tortuosity of the aorta resulting in a higher incidence of migration in proximal landing zone 3. Note that 50% (3/6) of migration occurred in proximal landing zone 3 consistent with these findings. However, we ensured a proximal neck length of at least 1.5 cm in all the cases.

Geisbüsch et al⁵ have stated that aortic elongation is an independent risk factor for migration. In our study also the mean value of aortic elongation was numerically higher in the migration group (16.50 ± 24.07 vs. 9.04 ± 18.28 mm), however, it did not reach statistical significance ($p = 0.408$). The patients showing significant distal migration can be attributable to aortic elongation as the stent graft conforms to the outer curvature of the aorta (→ Fig. 4). Aortic elongation can pull out the ends of stent grafts from landing zones mainly at the distal end and may require additional stent-graft coverage.

Migration at the overlapping zone of multiple stent grafts is described in the previous studies^{5,15} with an incidence of around 3%. It frequently leads to endoleak with increased secondary intervention rates. In our study, 12 patients underwent TEVAR with multiple stents with 20% oversizing of the second stent to the first stent and > 5 cm

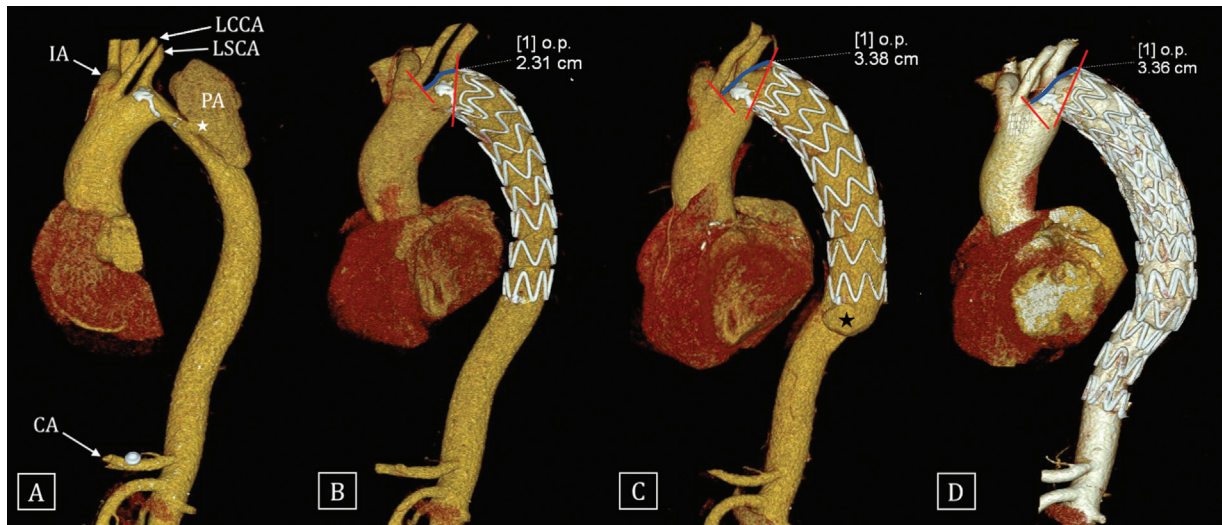


Fig. 3 Volume rendered computed tomography (CT) images show the evolution of a case with descending thoracic aorta (DTA) pseudoaneurysm (asterisk in A) treated by thoracic endovascular aortic repair (TEVAR). Stent graft was deployed in proximal landing zone 3 with technical success (B). The follow-up CT after 8 months (C) of the procedure showed significant proximal migration of the stent graft (~11 mm) and development of pseudoaneurysm (asterisk in C) at the distal end of stent graft. This was treated with another overlapping stent graft with the exclusion of pseudoaneurysm.

Table 2 Details of the patients with significant migration

Serial no.	Etiology	Type of graft	Site of migration	Type of arch	PLZ	Complication	Management
1	TAA	Ankura Lifetech	Proximal	Neoarch	0	–	
2	TBAD	Ankura Lifetech	Distal	I	3	–	
3	TBAD	Ankura Lifetech	Proximal	II	3	Pseudoaneurysm at the distal end of stent graft	Additional stent graft placement
4	TBAD	Ankura Lifetech	Distal	II	2	–	
5	TAA	Valiant Medtronic	Proximal	I	3	–	
6	TBAD	Valiant Medtronic	Distal	I	3	–	

Abbreviations: PLZ, proximal landing zone; TAA, thoracic aortic aneurysm; TBAD, type B aortic dissection.

Table 3 Absolute values of migration and aortic elongation case by case basis

Serial no.	LCCA - CA	LCCA - PSG	DSG - CA	Overlap
1	9	11	0	8
2	44	1	13	–
3	29	11	0	3
4	40	1	25	–
5	3	19	0	–
6	21	0	16	5

Abbreviations: CA, carotid artery; DSG, distal stent graft; LCCA, left common carotid artery; PSG, proximal stent graft.

Note: All values are in mm. Only one stent graft was used in patients no. 2, 4, and 5.

DSG - CA - distal migration, overlap - migration at the overlapping segment; LCCA - CA - aortic elongation; LCCA - PSG - proximal migration.

overlapping distance. None of those 12 patients showed significant migration or complications.

All the migration in the current study happened in the TBAD and TAA group and none in the TAI group consistent with the previous study.⁵ In TAA and TBAD, the entire thoracic aorta is frequently diseased leading to higher tortuosity leading to issues with proximal fixation point as opposed to focal abnormality usually seen in TAI. The migration was observed in two patients of TAA and 4 patients of TBAD; however, there was no statistically significant difference. Different types of stent grafts were used for the procedures (Ankura Lifetech, Valiant Medtronic, Zenith Cook, and Endurant Medtronic). The significant migration was observed in four patients with Ankura Lifetech device and two patients with Valiant Medtronic device. However, the type of device was not found to be a risk factor for migration.

Table 4 Univariate analysis of the risk factors for stent-graft migration

Parameter	Migration group (6)	Nonmigration group (25)	p-Value	OR	95% confidence interval
Age (y)	51.33 ± 20.37	51.56 ± 14.68	0.63	0.98	0.91 to 1.05
Sex			0.96	1.05	0.095 to 11.55
Male	5 (83)	21 (84)			
Female	1 (17)	4 (16)			
Type of proximal zone					
Zone 0	1 (17)	2 (8)	0.32	3.6	0.28 to 44.82
Zone 1	0	1 (4)	0.89	1.25	0.045 to 34.59
Zone 2	1 (17)	18 (72)	0.03	0.07	0.007 to 0.789
Zone 3	4(66)	3 (12)	0.01	14.67	1.82 to 117.67
Zone 4	0	1 (4)	0.89	1.25	0.098 to 14.46
Etiology					
TBAD	4 (67)	14 (56)	0.63	1.57	0.24 to 10.21
TAA	2 (33)	9 (36)	0.9	0.88	0.13 to 5.84
TAI	0	2 (8)	0.84	0.72	0.030 to 17.01
Type of device used					
Lifetech Ankura	4 (67)	16 (64)	0.9	1.12	0.17 to 7.39
Medtronic Valiant	2 (33)	6 (24)	0.64	1.58	0.22 to 10.90
Cook Zenith	0	2 (8)	0.84	0.72	0.030 to 17.01
Medtronic Endurant	0	1 (4)	0.84	0.72	0.030 to 17.01
Multiple devices	3 (50)	9 (36)	0.53	1.77	0.29 to 10.71
Type of aortic arch					
Type I	3 (60)	12 (48)	0.92	1.08	0.18 to 6.43
Type II	2 (22.2)	4 (16)	0.97	0.34	0.35 to 19.51
Type III	0	6 (24)	0.33	0.23	0.01 to 4.68
Bovine arch	1 (17)	5 (20)	0.57	0.51	0.05 to 5.22
Tortuosity index	0.72 ± 0.10	0.73 ± 0.08	0.74	0.17	0 to 8603.46
Change in LCCA to CA (mm)	16.50 ± 24.07	9.04 ± 18.28	0.27	0.98	0.97 to 1.07
MALAN classification					
Neo/0	1 (16.7)	2 (8)	0.52	2.3	0.17 to 30.59
I/2	0	8 (32)	0.22	0.16	0.007 to 3.152
I/3	3 (50)	4 (16)	0.09	5.25	0.76 to 35.97
II/1	0	1 (4)	0.89	1.25	0.045 to 34.59
II/2	1 (16.7)	3 (12)	0.76	1.45	0.12 to 17.21
II/3	1 (16.7)	0	0.12	13.9	0.49 to 388.85
III/2	0	7 (28)	0.27	0.19	0.009 to 3.80

Abbreviations: CA, carotid artery; LCCA, left common carotid artery; MALAN, Modified Arch Landing Areas Nomenclature; OR, odds ratio; SD, standard deviation; TAA, thoracic aortic aneurysm; TAI, traumatic aortic injury; TBAD, type B aortic dissection.

Note: Continuous data are represented as mean ± SD and nominal data as a percentage. Boldfaced values indicate statistically significant p-values.

Thoracic stent-graft migration is a risk factor for complications like endoleaks and pseudoaneurysm formation.^{2,5} In this study, one patient developed an aortic pseudoaneurysm as a result of migration which was treated by deploying additional stent graft across the lesion. None of the other patients showed any complication in the form of endoleaks and were managed conservatively.

Limitations

There are a few limitations to this study. First is the nonrandomized retrospective design of the study. Second, the smaller sample size and a smaller number of patients in different subgroups precluded the optimal evaluation of the

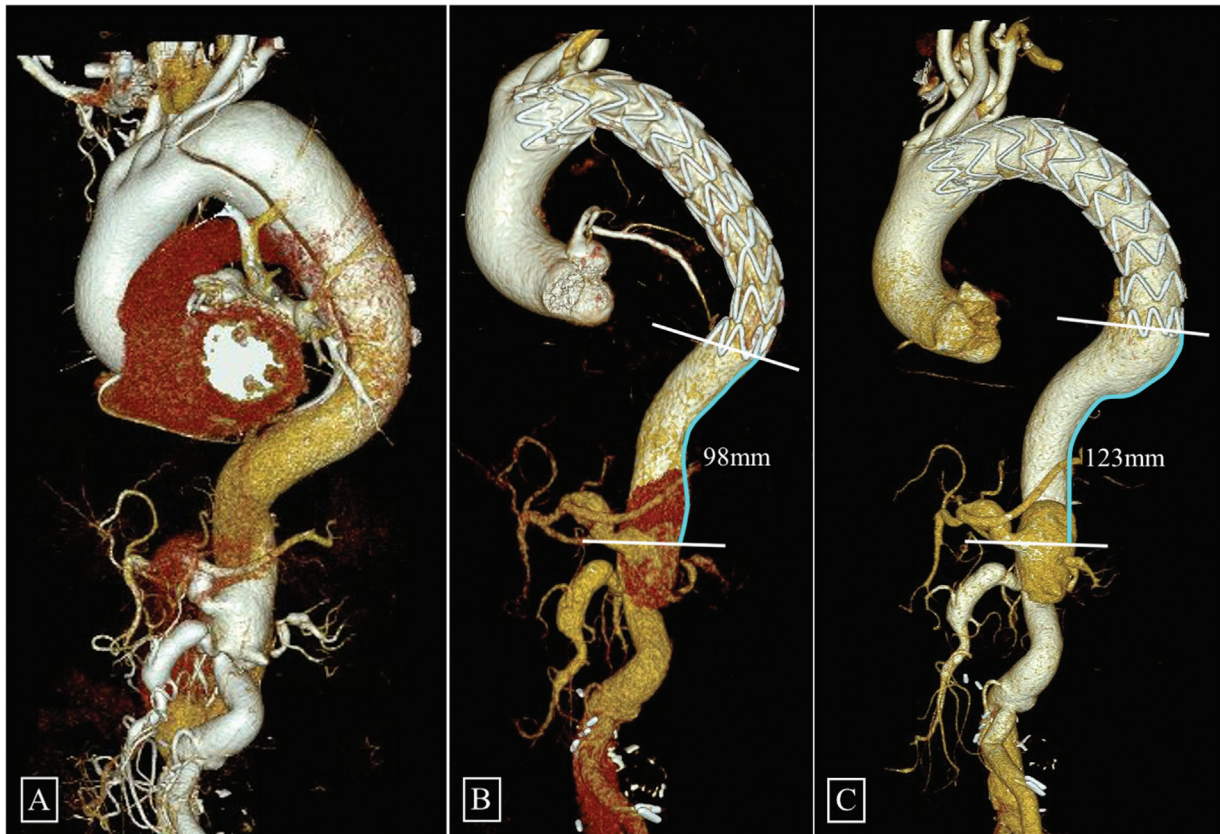


Fig. 4 Volume rendered computed tomography (CT) images of a patient with type B aortic dissection (TBAD) at baseline (A). The patient underwent a thoracic endovascular aortic repair (TEVAR) in proximal landing zone 2 due to inadequate landing zone distal to the left subclavian artery (LSCA) (B). The follow-up CT done 16 months postprocedure (C) showed significant migration at the distal end of the stent graft (25 mm). The patient also had a significant aortic elongation at the last follow-up (~40 mm) compared with the baseline scan.

risk factors. Third, a large number of patients who underwent TEVAR had to be excluded from the study due to lack of follow-up imaging. Nonetheless, stent-graft migration after TEVAR is a less studied phenomenon and identification of this complication is important so that a frequent follow-up of the patients can pick up endoleaks or pseudoaneurysm and management of the same promptly.

Conclusion

The stent-graft migration after TEVAR is not uncommon. Type 3 proximal landing zone was a significant risk factor for migration. Proximal landing zone 2 as well as adequate oversizing and overlapping distance in multiple stent grafts can prevent migration. The odds of migration were more in segments I/3 and II/3 compared with I/2 and II/2, respectively, as per the MALAN classification. However, further studies with a larger sample size are required to explore the risk as per MALAN classification.

Meeting Presentation

None.

Ethical Approval

Institute of Ethics Committee for Post Graduate Research, All India Institute of Medical Sciences, Ansari Nagar, New Delhi 110029, India (Ref No. IECPG-227/24.06.2020).

Financial Grant

None.

Conflict of Interest

None declared.

References

- 1 Nation DA, Wang GJ. TEVAR: endovascular repair of the thoracic aorta. *Semin Intervent Radiol* 2015;32(03):265–271
- 2 Daye D, Walker TG. Complications of endovascular aneurysm repair of the thoracic and abdominal aorta: evaluation and management. *Cardiovasc Diagn Ther* 2018;8(Suppl 1):S138–S156
- 3 O'Neill S, Greenberg RK, Resch T, et al. An evaluation of centerline of flow measurement techniques to assess migration after thoracic endovascular aneurysm repair. *J Vasc Surg* 2006;43(06):1103–1110
- 4 Piffaretti G, Negri S, Ferraro S, et al. Delayed graft dislocation after thoracic aortic endovascular repair. *Kathmandu Univ Med J (KUMJ)* 2014;12(46):97–100 (KUMJ)
- 5 Geisbüsch P, Skrypnik D, Ante M, et al. Endograft migration after thoracic endovascular aortic repair. *J Vasc Surg* 2019;69(05):1387–1394
- 6 Iwakoshi S, Ichihashi S, Inoue T, et al. Measuring the greater curvature length of virtual stent graft can provide accurate prediction of stent graft position for thoracic endovascular aortic repair. *J Vasc Surg* 2019;69(04):1021–1027
- 7 Demertzis S, Hurni S, Stalder M, Gahl B, Herrmann G, Van den Berg J. Aortic arch morphometry in living humans. *J Anat* 2010;217(05):588–596

- 8 Ishimaru S. Endografting of the aortic arch. *J Endovasc Ther* 2004; 11(Suppl 2):II62-II71
- 9 Marrocco-Trischitta MM, de Beaufort HW, Secchi F, et al. A geometric reappraisal of proximal landing zones for thoracic endovascular aortic repair according to aortic arch types. *J Vasc Surg* 2017;65(06):1584-1590
- 10 Riambau V, Böckler D, Brunkwall J, et al; Esvs Guidelines Committee. Editor's Choice - management of descending thoracic aorta diseases: clinical practice guidelines of the European Society for Vascular Surgery (ESVS). *Eur J Vasc Endovasc Surg* 2017;53(01):4-52
- 11 Matsumura JS, Melissano G, Cambria RP, et al; Zenith TX2 Clinical Trial Investigators. Five-year results of thoracic endovascular aortic repair with the Zenith TX2. *J Vasc Surg* 2014;60(01):1-10
- 12 Morales JP, Greenberg RK, Morales CA, et al. Thoracic aortic lesions treated with the Zenith TX1 and TX2 thoracic devices: intermediate- and long-term outcomes. *J Vasc Surg* 2008;48(01):54-63
- 13 Hassoun HT, Mitchell RS, Makaroun MS, Whiting AJ, Cardeira KR, Matsumura JS. Aortic neck morphology after endovascular repair of descending thoracic aortic aneurysms. *J Vasc Surg* 2006;43(01):26-31
- 14 Makaroun MS, Dillavou ED, Wheatley GH, Cambria RP, Gore TAGGore TAG Investigators. Five-year results of endovascular treatment with the Gore TAG device compared with open repair of thoracic aortic aneurysms. *J Vasc Surg* 2008;47(05):912-918
- 15 Foley PJ, Criado FJ, Farber MA, et al; VALOR Investigators. Results with the Talent thoracic stent graft in the VALOR trial. *J Vasc Surg* 2012;56(05):1214-21.e1
- 16 Nasr B, Savean J, Albert B, et al. Thoracic stent-graft migration: the role of the geometric modifications of the stent-graft at 3 years. *Ann Vasc Surg* 2019;58:16-23
- 17 Altnji HE, Bou-Saïd B, Walter-Le Berre H. Morphological and stent design risk factors to prevent migration phenomena for a thoracic aneurysm: a numerical analysis. *Med Eng Phys* 2015;37(01):23-33
- 18 Molony DS, Kavanagh EG, Madhavan P, Walsh MT, McGloughlin TM. A computational study of the magnitude and direction of migration forces in patient-specific abdominal aortic aneurysm stent-grafts. *Eur J Vasc Endovasc Surg* 2010;40(03):332-339
- 19 Marrocco-Trischitta MM, van Bakel TM, Romarowski RM, et al. The Modified Arch Landing Areas Nomenclature (MALAN) improves prediction of stent graft displacement forces: proof of concept by computational fluid dynamics modelling. *Eur J Vasc Endovasc Surg* 2018;55(04):584-592
- 20 Asenbaum U, Schoder M, Schwartz E, et al. Stent-graft surface movement after endovascular aneurysm repair: baseline parameters for prediction, and association with migration and stent-graft-related endoleaks. *Eur Radiol* 2019;29(12):6385-6395
- 21 Melissano G, Civilini E, Bertoglio L, et al. Results of endografting of the aortic arch in different landing zones. *Eur J Vasc Endovasc Surg* 2007;33(05):561-566