



Indian College of Radiology and Imaging Consensus Guidelines on Interventions in Pancreatitis

Pankaj Gupta¹  Kumble S. Madhusudhan² Aswin Padmanabhan³ Pushpinder Singh Khara⁴

¹ Department of Radiodiagnosis and Imaging, Postgraduate Institute of Medical Education and Research, Chandigarh, India

² Department of Radiology, All India Institute of Medical Sciences, New Delhi, India

³ Division of Clinical Radiology, Department of Interventional Radiology, Christian Medical College, Vellore, Tamil Nadu, India

⁴ Department of Diagnostic and Interventional Radiology, All India Institute of Medical Sciences, Jodhpur, Rajasthan, India

Address for correspondence Pankaj Gupta, MD, Department of Radiodiagnosis and Imaging, Postgraduate Institute of Medical Education and Research, Chandigarh 160012, India (e-mail: Pankajgupta959@gmail.com).

Indian J Radiol Imaging 2022;32:339–354.

Abstract

Acute pancreatitis (AP) is one of the common gastrointestinal conditions presenting as medical emergency. Clinically, the severity of AP ranges from mild to severe. Mild AP has a favorable outcome. Patients with moderately severe and severe AP, on the other hand, require hospitalization and considerable utilization of health care resources. These patients require a multidisciplinary management. Pancreatic fluid collections (PFCs) and arterial bleeding are the most important local complications of pancreatitis. PFCs may require drainage when infected or symptomatic. PFCs are drained endoscopically or percutaneously, based on the timing and the location of collection. Both the techniques are complementary, and many patients may undergo dual modality treatment. Percutaneous catheter drainage (PCD) remains the most extensively utilized method for drainage in patients with AP and necrotic PFCs. Besides being effective as a standalone treatment in a significant proportion of these patients, PCD also provides an access for percutaneous endoscopic necrosectomy and minimally invasive necrosectomy. Endovascular embolization is the mainstay of management of arterial complications in patients with AP and chronic pancreatitis. The purpose of the present guideline is to provide evidence-based recommendations for the percutaneous management of complications of pancreatitis.

Keywords

- ▶ acute pancreatitis
- ▶ fluid collections
- ▶ percutaneous drainage
- ▶ pseudoaneurysm
- ▶ walled-off necrosis

Methodology

The guideline was developed under the auspices of the Indian College and Radiology and Imaging. A working group consisting of interventional radiologists actively involved in the multidisciplinary management of patients with acute

pancreatitis (AP) developed these recommendations. The working group established the research questions and performed a systematic review for the supporting evidence. The recommendations pertain the interventional radiological management of local complications of pancreatitis. The

published online
July 31, 2022

DOI <https://doi.org/10.1055/s-0042-1754313>.
ISSN 0971-3026.

© 2022. Indian Radiological Association. All rights reserved.
This is an open access article published by Thieme under the terms of the Creative Commons Attribution-NonDerivative-NonCommercial-License, permitting copying and reproduction so long as the original work is given appropriate credit. Contents may not be used for commercial purposes, or adapted, remixed, transformed or built upon. (<https://creativecommons.org/licenses/by-nc-nd/4.0/>)
Thieme Medical and Scientific Publishers Pvt. Ltd., A-12, 2nd Floor, Sector 2, Noida-201301 UP, India

key areas included in the recommendations are clinical presentation, investigation required, management, interventional radiology (IR) management, indications and contraindications, procedure details, expected outcome, complications, and follow-up. A total of 34 questions were identified. The evidence was evaluated according to the GRADE (Grading of Recommendations Assessment, Development, and Evaluation) approach.¹

► **Table 1** summarizes the guideline recommendations and grading.

► **Figs. 1 and 2** show the stepwise management of pancreatic fluid collections (PFCs) and pseudoaneurysm (PSA) bleed.

Summary of the Evidence

A1. What is the clinical presentation of patients with PFCs and infected pancreatic necrosis?

Most of the PFCs are asymptomatic and resolve spontaneously. Persistent PFCs may be associated with persistent systematic inflammatory response, mass effect on adjacent organs, or development of infection. Patients having infected pancreatic necrosis present with fever, leukocytosis, persistent or new-onset organ failure, or nonimprovement in clinical condition (*GRADE 1B*).

Remarks

PFCs are common in AP. Acute necrotic collections (ANCs) have been reported in >90% patients with severe disease. Most of the acute PFCs in mild AP resolve spontaneously without complications.² Progression to walled-off necrosis (WON) is seen in about half of patients with ANCs. Most patients with PFCs are asymptomatic. Those with persistent PFCs may develop refractory pain, clinical manifestations secondary to pressure on adjacent organs, rupture into the gastrointestinal (GI) tract, vascular complications, or infection. In patients with acute necrotizing pancreatitis (ANP), infected necrosis should be suspected when there is a clinical deterioration of a previously stable patient or when there is a new-onset organ failure.² The timing when the clinical worsening happens is important in guiding a differential diagnosis.² In the early phase (<14 days), fever, leukocytosis, and organ dysfunction are mostly due to systemic inflammatory response syndrome (SIRS). Infection of pancreatic necrosis usually occurs after this period. Most patients with necrosis develop infection after 3 to 4 weeks of onset of pain. In patients with necrotic collection and development of fever in the later phase of ANP, infected necrosis may be clinically suspected (in the absence of air in the collection) after exclusion of pulmonary, urinary tract, and intravenous access infections.²

A2. What is the clinical presentation of patients with vascular complications?

Arterial complications present as hematemesis, melena, or hematochezia when bleeding occurs into the lumen of GI tract. When the hemorrhage occurs into the cavity, patients

may present with hypotension, shock, abdominal pain, anemia (hemoglobin drop), and bleeding in the drainage catheters. Venous complications are mostly asymptomatic (*GRADE 1C*).

Remarks

Vascular complications occur in approximately 25% cases with AP.³ The vascular complications occurring could be arterial or venous. Arterial complications include PSA, active extravasation, arteritis, and arterial fistula. Venous complications include thrombosis of the splanchnic circulation with formation of collaterals. Arterial complications, seen in 4 to 10% of cases, present with hemorrhage, either into the lumen, when they present with hematemesis, melena, or hematochezia, or into the cavity, when they present with hypotension, shock, abdominal pain, anemia (hemoglobin drop), and bleeding in the drainage catheters.⁴⁻⁶ Occasionally, the patients may be asymptomatic, and the PSA may be detected incidentally on imaging done for other purposes. Venous thrombosis, seen in 16 to 18% cases of necrotizing pancreatitis, is usually asymptomatic.⁷⁻¹⁰ Some patients may present with abdominal distension due to ascites or hematemesis/melena due to the development of gastric or esophageal varices.¹⁰ Splenic infarcts which result from splenic vein thrombosis may manifest with left hypochondriac pain.¹¹ Clinically, it is important to differentiate between arterial and venous hemorrhagic complications as this determines the next line of investigation. Arterial hemorrhage usually presents with significant hemoglobin drop (>1–2 g/dL), bright blood in the drain, and shock.

A3. What is the clinical presentation of patients with bowel-related complications and other complications of AP?

The bowel complications present with diarrhea, GI bleed, or drainage of bilious fluid/fecal matter in the catheters placed in the infected collections. Mass effect of large collections may result in symptoms like jaundice, early satiety, vomiting (due to gastric outlet obstruction), or abdominal pain. Disconnected pancreatic duct syndrome (DPDS) presents with persistent pain abdomen, recurrent collection, or pancreatic fistula (*GRADE 1C*).

Remarks

Bowel perforation and GI fistulas occurs in 3 to 15% of the patients with AP usually in the late phase of the illness.¹² These bowel complications are the results of enzymatic action on the bowel wall and evolve from the stages of bowel inflammation, ischemia, and necrosis. Patients present with diarrhea, GI bleed, and prolonged sepsis. In patients with percutaneous catheters in place, there may be feculent drain output.¹³ Mass effect of collections in the upper abdomen may cause biliary obstruction, gastric outlet, or intestinal obstruction.² These symptoms depend on the strategic location of the collection. DPDS is an under-recognized complication of AP.² It is reported in 30 to 50% of patients with necrotizing pancreatitis. DPDS results complete transection of the pancreatic duct by pancreatic necrosis.² This most

Table 1 Summary of recommendations

<i>A. Clinical presentation</i>
1. Most of the PFCs are asymptomatic and resolve spontaneously. Persistent PFCs may be associated with persistent systematic inflammatory response, mass effect on adjacent organs, or development of infection. Patients having infected pancreatic necrosis present with fever, leukocytosis, persistent or new-onset organ failure, or nonimprovement in clinical condition (GRADE 1B).
2. Arterial complications present as hematemesis, melena, or hematochezia when bleeding occurs into the lumen of GI tract. When the hemorrhage occurs into the cavity, patients may present with hypotension, shock, abdominal pain, anemia (hemoglobin drop), and bleeding in the drainage catheters. Venous complications are mostly asymptomatic (GRADE 1C).
3. The bowel complications of acute pancreatitis (AP) commonly present with drainage of bilious fluid or fecal matter in the catheters placed in the infected collections. Mass effect of large collections may result in symptoms like jaundice, early satiety, vomiting (due to gastric outlet obstruction), or abdominal pain. Disconnected pancreatic duct syndrome (DPDS) presents with persistent pain abdomen or pancreatic fistula (GRADE 1C).
<i>B. Investigation required</i>
1. Contrast-enhanced CT scan is the investigation of choice for evaluation of patients with suspected pancreatic necrosis. Presence of air foci within the collection is diagnostic of infected pancreatic necrosis (1A). Fine-needle aspiration of the collection for diagnosis of infection is not routinely indicated (GRADE 1C).
2. CT angiography (CTA) is the investigation of choice for detection of the cause of bleeding. Upper gastrointestinal endoscopy (UGIE) should be performed in patients with mild bleeding or in patients in whom CTA is negative and there is no significant hemoglobin drop. Digital subtraction angiography (DSA) is mainly utilized for definitive management of arterial abnormality; however, in patients with strong clinical suspicion in whom other tests are nondiagnostic, DSA may be performed for diagnosis as well as treatment (GRADE 2C).
3. UGIE and colonoscopy allow direct visualization of bowel abnormality in relation to pancreatic necrosis. Contrast-enhanced CT scan with oral and intravenous contrast serves as an important adjunctive method for diagnosis of bowel complication as well as other intra-abdominal complications. Conventional or CT fistulogram or tubogram may be necessary to confirm fistula with small bowel or colon. Magnetic resonance imaging (MRI) and magnetic resonance cholangiopancreatography (MRCP) allow the evaluation of ductal abnormalities in patients with suspected DPDS; however, endoscopic retrograde pancreatography is required for confirmation of diagnosis (GRADE 1C).
<i>C. Management</i>
1. Drainage is indicated in majority of patients with infected pancreatic necrosis, the choice of drainage being minimally invasive methods like endoscopic drainage or percutaneous drainage (GRADE 2C).
2. Endovascular embolization is the treatment of choice in cases of arterial source of bleeding. Endoscopy and endoscopic therapy should be performed wherever a source is identified. Endoscopic ultrasonography (EUS) may be used in cases the lesion is not identified on angiography. Surgery is usually the option in patients who are hemodynamically very unstable or where other therapies have failed (GRADE 1C).
3. Gastroduodenal fistulae are managed conservatively. Fistulization at other sites of small or large bowel requires bowel resection or surgical diversion in the form of ileostomy with or without colectomy. Collections causing mass effect require drainage through percutaneous, endoscopic, or surgical methods depending on the chronicity, morphology, and location of the collections. Chronic DPDS usually requires surgical treatment (GRADE 1C).
<i>D. Interventional radiology management option</i>
1. The vascular IR procedure used in the management of pancreatitis is mainly embolization for hemorrhagic complications (GRADE 1C).
2. The nonvascular IR procedures include drainage of collections, upgrading of catheters, drainage of ascites and pleural effusions, percutaneous biliary drainage, and percutaneous cholecystostomy (GRADE 1C).
<i>E. Indications and contraindication</i>
1. The most common indication of percutaneous catheter drainage (PCD) is infected (suspected or confirmed) necrotic collection. In the absence of infection, nonresolving organ failure for several weeks may be considered for drainage, preferably at the stage of walled-off necrosis (GRADE 1C). Other less common indications of PCD are walled off necrotic collections causing compressive symptoms, persistent “unwellness,” intra-abdominal hypertension, or bowel complications (GRADE 2C).
2. Endovascular embolization should be offered to all patients with arterial complications of AP (GRADE 1C).
3. The relative contraindications to drainage of PFC and embolization of arterial abnormalities are uncorrectable coagulopathy (INR > 1.5) and platelet count < 50,000/ μ L. Contrast allergy and deranged renal function tests are the other relative contraindications for endovascular embolization. Lack of bowel-free approach is an absolute contraindication for catheter drainage.
<i>F. Procedure details</i>
1. Drainage of PFC should ideally be delayed (3–4 weeks after onset of pancreatitis). Earlier drainage is indicated in patients with infected collections, large collections causing pressure symptoms, intra-abdominal hypertension, or those with persistent sepsis (GRADE 1C).

(Continued)

Table 1 (Continued)

2. Percutaneous catheter placement may be performed under ultrasound or CT guidance based on interventional radiologists' preference and the location of collection (GRADE 2C).
3. There are no available data to support a particular size of initial drainage catheter; however, expert consensus suggests that a large bore catheter should preferably be used (GRADE 2C).
4. The preferred route for drainage of pancreatic collections is retroperitoneal via left posterolateral approach (GRADE 1C).
5. Catheter upsizing can be done in persistent collection with reduced output/clinical nonimprovement/deterioration (GRADE 2C).
6. Based on the available data, no single size limit may be suggested for catheter upsizing (GRADE 2C).
7. Although there is a consensus that percutaneous catheter should be irrigated with saline, there are no clear recommendations regarding the frequency of irrigation and amount of fluid (GRADE 2C).
8. There are little data to support routine use of local intracavitary antibiotics (GRADE 2C).
9. Based on the available literature, routine instillation of agents to facilitate the liquefaction and drainage of necrotic debris cannot be recommended (GRADE 2C).
10. The catheter should be removed once the collection has resolved and the drain output is less than 10–20 mL/day (GRADE 2C).
11. The standard technique for endovascular embolization is the “sandwich” technique that involves embolization of the arteries proximal and distal to the PSA (GRADE 1C).
12. The preferred embolization agent is coils (GRADE 1C).
13. Based on the limited data, embolization of PSA should be done prior to drainage (GRADE 2C).
14. There is a limited role for percutaneous embolization of PSA, when the endovascular embolization has failed or is not feasible and EUS-guided intervention is not available or is not feasible or has failed (GRADE 2C).
<i>G. Expected outcomes</i>
1. A significant proportion of patients with infected necrosis may be managed with percutaneous drainage alone (GRADE 1A).
2. Endovascular embolization has a high technical and clinical success (GRADE 1B).
<i>H. Complications</i>
1. The most important long-term complication is external pancreatic fistula (GRADE 1A).
2. The most significant complication related to endovascular embolization of PSA is non-target embolization (GRADE 1C).
<i>I. Follow-up</i>
1. There are no data to suggest a follow-up protocol specifically for patients treated with PCD. However, the follow-up evaluation of patients with AP includes a comprehensive evaluation by a team comprising medical gastroenterologist, surgeon, and interventional radiologist (GRADE 2C).
2. Following endovascular embolization, patients must be assessed clinically and by serial evaluation of hemoglobin levels to confirm the clinical success. There is no clear recommendation for follow-up CTA (GRADE 2C).

Abbreviations: CT, computed tomography; GI, gastrointestinal; INR, international normalized ratio; IR, interventional radiology; PFC, pancreatic fluid collection; PSA, pseudoaneurysm.

commonly occurs at the level of neck of pancreas. The immediate consequence is the persistent leakage of pancreatic enzymes, manifesting as nonresolving collection, pancreatic ascites, pancreaticopleural fistula, and external pancreatic fistula (EPF).¹⁴ Long-term sequelae include changes of chronic pancreatitis (CP) and recurrent AP.¹⁵

B1. How to investigate a patient with suspected infected pancreatic necrosis?

Contrast-enhanced computed tomography (CT) scan is the investigation of choice for evaluation of patients with suspected infected pancreatic necrosis. Presence of air foci within the collection is diagnostic of infected pancreatic necrosis (GRADE 1A). Fine-needle aspiration (FNA) of the collection for diagnosis of infection is not routinely indicated (GRADE 1C).

Remarks

Presence of gas in pancreatic or peripancreatic collection on CT is strongly suggestive of infection.¹⁶ However, gas is present in only half of the patients with infected necrosis. The sensitivity and specificity of gas within a necrotic collection in the setting of AP is 56 and 97%, respectively.¹⁷ Percutaneous FNA of peripancreatic collections to detect bacteria is not routinely indicated. The clinical features including persistent fever and elevated inflammatory markers in the later phase of the illness with or without presence of gas on CT are accurate predictors of infected necrosis in most of the patients. Although the sensitivity of FNA in the detection of organism is 79%, false-negative results are encountered in 12 to 25% of the patients and there is a risk of introduction of infection in a sterile collection.¹⁶ A reasonable indication of FNA for detection

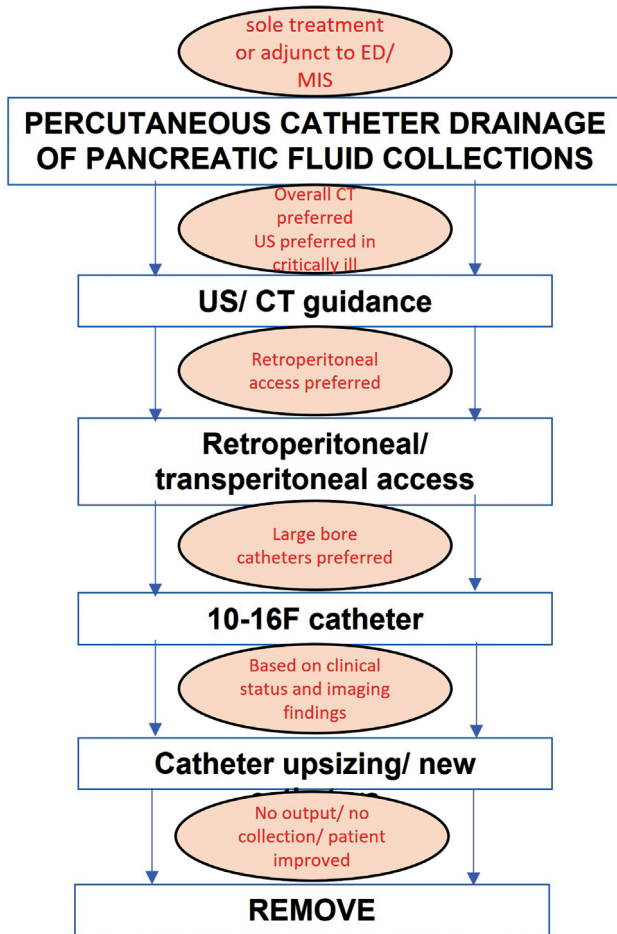


Fig. 1 Stepwise approach to percutaneous drainage of pancreatic fluid collections.

of infected necrosis in the current scenario is a patient without clear clinical and imaging features of infection but lack of clinical improvement for several weeks.¹⁸ Biochemical markers including blood urea nitrogen, C-reactive protein (CRP), and procalcitonin have been utilized in the prediction of infection in necrosis, however, have limited utility.^{19,20}

B2. Which investigations are required to evaluate a patient with hemorrhagic complications?

CT angiography (CTA) is the investigation of choice for detection of the cause of bleeding. Upper GI endoscopy (UGIE) should be performed in patients with mild bleeding or in patients in whom CTA is negative and there is no significant hemoglobin drop. Digital subtraction angiography (DSA) is mainly utilized for definitive management of arterial abnormality. However, in patients with strong clinical suspicion in whom other tests are nondiagnostic, DSA may be performed for diagnosis as well as treatment (GRADE 2C).

Remarks

All patients presenting with hemorrhagic complications should be investigated. The most important laboratory investigations are blood hemoglobin and hematocrit level. In patients with necrotizing pancreatitis, approximately 60% of acute hemorrhagic complications are caused by rupture of PSA.²¹ Of the remaining, approximately 20% is due to capillary, venous, or small vessel hemorrhage. Based on whether the hemorrhage is from an arterial or venous source, the next investigation is determined. If an arterial source is suspected, which is often the case, CTA is the investigation of choice.²²⁻²⁴ UGIE should be performed when the bleeding is not severe or when CTA is normal.²³ Further, if the patient

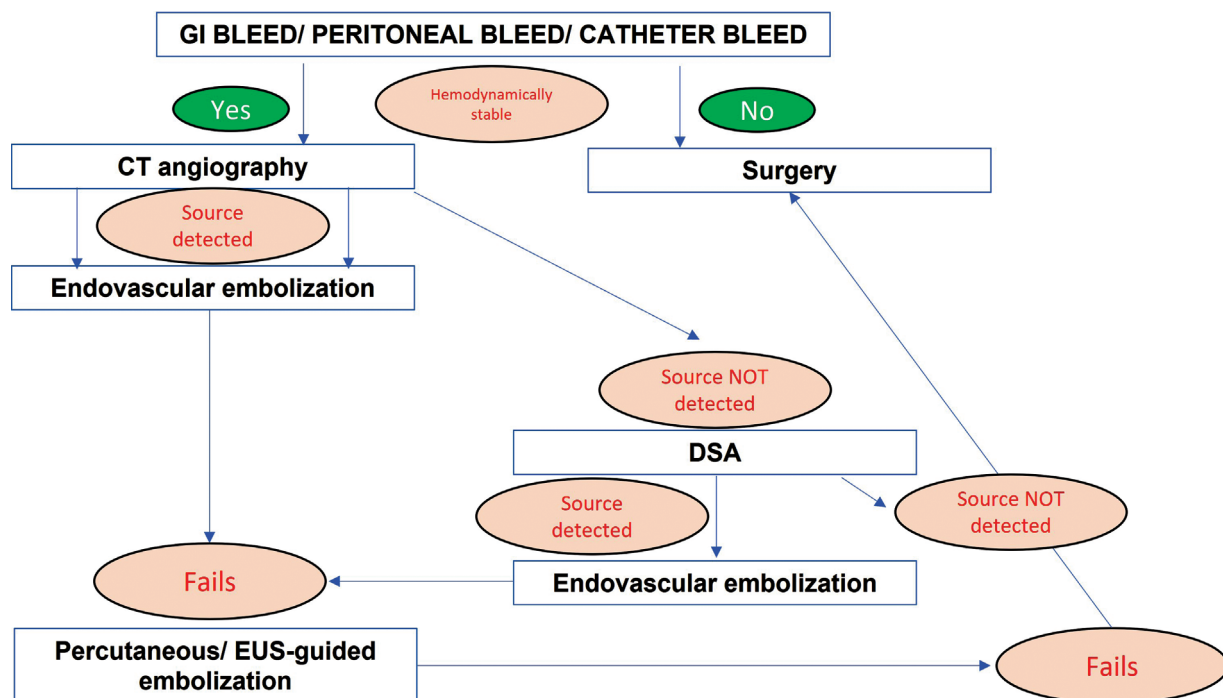


Fig. 2 Stepwise approach to management of arterial bleeding in pancreatitis.

continues to bleed despite normal CTA, DSA may be necessary to detect any small source of hemorrhage. There should be a low threshold to perform a CTA because of the high mortality (34–52%) associated with the rupture of PSA.⁴ Endoscopic ultrasonography (EUS) may be helpful in cases where UGIE, CTA, and DSA are normal and bleeding is persistent.²⁵ EUS may show small PSA in and around the pancreas, which is seen as a small anechoic lesion, showing color and pulsatile flow on color Doppler imaging.

B3. How are bowel and other complications of pancreatitis investigated?

UGIE and colonoscopy allow direct visualization of bowel abnormality in relation to pancreatic necrosis. Contrast-enhanced CT scan with oral and intravenous contrast serves as an important adjunctive method for the diagnosis of bowel complication as well as other intra-abdominal complications. Conventional or CT fistulogram or tubogram may be necessary to confirm fistula with small bowel or colon. Magnetic resonance imaging (MRI) and magnetic resonance cholangiopancreatography (MRCP) allow the evaluation of ductal abnormalities in patients with suspected DPDS; however, endoscopic retrograde pancreatography is required for confirmation of diagnosis in selected cases (*GRADE 2C*).

Remarks

Diagnosis of GI fistula is suggested on CT when there is extensive air in a necrotic collection, direct extension of peripancreatic inflammatory changes into a segment of GI tract, a defect in the wall of GI tract with adjacent inflammation or contrast leakage into pancreatic collection from the bowel loop, or contrast opacification of bowel loop via contrast injected through a catheter placed in a pancreatic collection.¹³ Colonic perforation appears as discontinuity of the bowel wall, contrast leak into the adjacent soft tissue, or pneumoperitoneum/localized air collection around the splenic flexure.¹² Confirmation is possible by imaging (contrast studies like tubogram, fistulogram, oral contrast study, or contrast enema) or endoscopy.²⁶ The diagnosis of DPDS requires a combination of noninvasive imaging findings and pancreatography (MRCP or endoscopic retrograde cholangiopancreatography [ERCP]).²⁷ The features of DPDS on CT/MRI are intrapancreatic collection or necrosis involving the entire thickness of the parenchyma and functioning upstream gland. In a study, all patients who were confirmed to have DPDS, the intraparenchymal abnormality, involved more than 2 cm of the parenchyma.²⁷

C1. What are the management options for infected pancreatic necrosis?

Drainage is indicated in majority of patients with infected pancreatic necrosis, the choice of drainage being minimally invasive methods like percutaneous drainage and/or endoscopic drainage. Necrosectomy (minimally invasive surgical or endoscopic) is required in patients not responding to drainage (*GRADE 1A*).

Remarks

Over the last several years, there has been a paradigm change in the approach to management of infected pancreatic necrosis. The surgical necrosectomy is now increasingly being replaced by a minimally invasive step-up approach which comprises an initial drainage (percutaneous or endoscopic) followed by minimally invasive necrosectomy (endoscopic or minimally invasive surgical).² The PANTER trial popularized the concept of step-up approach. In this multicenter randomized control trial (RCT) comprising 88 patients with (suspected) infected necrotizing pancreatitis, the step-up approach led to a reduction in major short-term complications such as new-onset multiorgan failure as well as long-term complications such as endocrine insufficiency.²⁸ If the drainage (endoscopic, or percutaneous, or both) fails, the options are endoscopic or surgical necrosectomy. Multiple trials have confirmed the efficacy, safety, and reduced cost of endoscopic necrosectomy.^{29–31} Endoscopic necrosectomy may be performed as direct endoscopic necrosectomy following EUS-guided transmuralcystogastrostomy (as a primary or secondary procedure) or through the transcatheter access after tract dilatation (percutaneous endoscopic necrosectomy). Minimally invasive surgical procedures include minimally invasive retroperitoneal pancreatic necrosectomy, video-assisted retroperitoneal debridement, and laparoscopic debridement. A meta-analysis comprising eight studies found that infected necrosis could be managed conservatively without surgical necrosectomy in 64% of the patients.³²

C2. What are the treatment methods for hemorrhagic complications?

Endovascular embolization is the treatment of choice in cases of arterial source of bleeding. Endoscopic therapy should be performed wherever a source is identified on UGIE. Transabdominal ultrasonography or EUS may be used to guide embolization in cases the lesion is not identified on angiography and visualized on these modalities. Surgery is reserved for patients who are hemodynamically unstable or where other therapies have failed (*GRADE 1C*).

Remarks

DSA and endovascular embolization are the treatment of choice for patients with arterial source of hemorrhage.^{23,24} Performing a CTA prior to DSA in cases wherever possible is beneficial as it identifies the causative artery, creates a roadmap for DSA, identifies any variations in the arterial anatomy, and reduces the radiation dose and time of the embolization procedure.³³ Occasionally, DSA may not identify the source artery although the PSA is visualized on CTA. In such cases, if the PSA could be seen on ultrasonography, percutaneous direct injection of thrombin or *N*-butyl cyanoacrylate (NBCA) can be done to treat the PSA successfully.^{22,33} Empirical embolization may be performed in cases where endoscopy localizes the bleeding site and DSA does not show any abnormality. Usually gelfoam slurry is used for this purpose. The endoscopic treatment options include clipping, sclerotherapy, and vasopressor injection.^{34,35}

Clipping is a common treatment where a through-the-scope clip is applied on the mucosal surface at the site of bleeding to seal it. Larger ulcers may require over-the-scope clips. Venous bleeds due to varices are treated with sclerotherapy using glue injection or with ligation of the varices. There are a few limitations of performing UGIE in these patients. Patients are often sick and unstable and doing UGIE may not be safe. Extensive hemorrhage in the stomach and duodenum may obscure the source of bleeding. Further, in patients with hemobilia or hemosuccus pancreaticus, endoscopic treatment is not possible. Another option is EUS-guided direct injection.^{25,36} In cases where the PSA seen on CTA is not identified on DSA, EUS could be performed to localize the PSA. Then, under the guidance of EUS, the PSA is punctured directly and either thrombin or glue is injected. This should however be reserved for very selective situations where the other methods have failed. Surgery is reserved for unstable patients or when the endoscopic or radiological interventions fail.²³ The surgical procedures include ligation or repair of the causative artery, Whipple's pancreatoduodenectomy, or oversewing the bleeding artery.

C3. How are bowel and other complications treated?

Gastroduodenal fistulas are managed conservatively. Fistulization at other sites of small or large bowel requires bowel resection or surgical diversion in the form of ileostomy with or without colectomy. Collections causing mass effect require drainage. Chronic DPDS usually requires surgical treatment (*GRADE 1C*).

Remarks

In a series of 119 patients with AP and GI fistula, all duodenal fistulas were managed successfully by nonsurgical management, while surgical management (in the form of ileostomy or colostomy) was required for 61.1% of the colonic fistulae.³⁷ Rest of the patients with colonic fistulae were successfully managed by prolonged percutaneous catheter drainage (PCD) or continuous negative pressure irrigation. In another series of 52 patients with GI fistulae, 42 patients showed resolution after PCD or control of infection.³⁸ Ten patients underwent ileostomy or colostomy. In a systemic review of colonic complications of AP in 97 patients, Mohamed et al concluded that a trial of conservative management may facilitate fistula closure in patients with stable disease.³⁹ Urgent surgery may be indicated in patients with bleeding secondary to GI involvement or those with bowel perforation. For patients with stable clinical course who fail trial of PCD and have contraindications to surgery, endoscopic treatment with over-the-scope clips has been reported. The management of choice for chronic DPDS is surgical.⁴⁰ This involves resection of the upstream gland, with or without islet cell auto-transplantation. If the upstream pancreatic duct is of adequate caliber, Roux-en-Y pancreatojejunostomy may be performed.⁴¹ The nonsurgical options include EUS-guided pancreaticogastrostomy and combined approach utilizing PCD for internalization of pancreatocutaneous fistula followed by endoscopic stenting.^{42,43} In the early stage of DPDS, when the aim is to prevent recurrent

collections, the most widely used approach is to leave cystoenterostomy stents in place indefinitely to maintain patency of the internal fistula and divert pancreatic secretions back into the GI lumen.⁴⁴

D1. What are the vascular IR procedures used in the management of complications of AP and CP?

The vascular IR procedure used in the management of pancreatitis is mainly embolization for hemorrhagic complications (*GRADE 1C*).

Remarks

As the majority of vascular complications in the setting of AP and CP are arterial in origin, DSA and endovascular embolization are the mainstay of treatment.²³ Various endovascular embolization agents and techniques have been described. For PSAs that are not accessible by endovascular route, percutaneous image-guided embolization may be performed.³³

D2. What are the nonvascular IR procedures used in the management of complications of AP and CP?

The nonvascular IR procedures include PCD of PFC, upsizing of catheters, drainage of ascites and pleural effusions, percutaneous biliary drainage, and percutaneous cholecystostomy (*GRADE 1C*).

Remarks

PCD plays an important role in the management of patients with pancreatic collections in the setting of AP. It is either done as a sole intervention or more commonly as a part of multidisciplinary management strategy comprising endoscopic drainage and minimally invasive necrosectomy.²⁸ The percutaneous catheters frequently need upsizing and revisions to maintain their patency.⁴⁵ Percutaneous drainage of ascites and pleural effusion may be indicated on case to case basis.² The biliary obstruction in patients with gallstone pancreatitis and less commonly secondary to biliary stricture or extrinsic compression by PFCs is usually managed endoscopically.⁴⁶ However, in rare situations where the ERCP fails or patient is clinically unstable, percutaneous biliary drainage may be performed.⁴⁷ In patients with severe acute cholecystitis, percutaneous cholecystostomy may be required if patient is deteriorating despite medical treatment.⁴⁸

E1. What are the indications of PCD of PFCs?

The most common indication of PCD is infected (suspected or confirmed) necrotic collection. In the absence of infection, nonresolving organ failure for several weeks may be considered for drainage, preferably at the stage of WON (*GRADE 1C*). Other less common indications of PCD are WON causing compressive symptoms, persistent "unwellness," intra-abdominal hypertension, or bowel complications (*GRADE 2C*).

Remarks

Sterile necrotic collections do not need drainage regardless of their size as most resolve without intervention.² In a study by Manrai et al, 76 patients with WON who survived, 24

patients were managed conservatively.⁴⁹ In another study by Rana et al, 30 (70%) of the 42 patients with WON did not develop any complications during expectant management.⁵⁰ There was complete resolution of WON in 30% of the patients. Suspected or confirmed infection in a necrotic collection is the most common indication for drainage. Although, infection usually occurs later in the course of AP usually 3 to 4 weeks after the onset in the WON, earlier infection may occur in one-fourth of the patients.² If the infected WON is adjacent to the stomach or duodenum, endoscopic drainage is usually performed. However, majority of patients have deeper extensions of the WON into the paracolic gutter and pelvis which requires PCD.^{51,52} Additionally, drainage may be required for symptomatic ANC, particularly, in the setting of infection.² In several recent series, PCD in the early phase of AP in patients with non-resolving organ failure has been shown to have a beneficial role.^{45,53,54} The compressive symptoms secondary to necrotic collections are rarely seen. In a study of 639 patients with necrotizing pancreatitis, biliary obstruction or gastric outlet obstruction necessitating intervention was reported in 1% of the patients.⁵⁵ Rare complications requiring PCD in the follow-up after sterile necrotizing pancreatitis are pancreaticopleural fistula (in combination with endoscopic treatment), pancreatic ascites, and symptomatic pseudocyst not amenable to endoscopic drainage.² Another cohort of patients with AP who may benefit from drainage of collections is one with “persistent unwellness.”² These patients are reported to undergo drainage 6 to 8 weeks after onset of symptoms. Invasive treatment of abdominal compartment syndrome is indicated in patients with persistent elevated intra-abdominal pressure (IAP) above 25 mm Hg with new-onset organ failure not responding to medical management and nasogastric and rectal decompression.⁵⁶ The World Society of Abdominal Compartment Syndrome recommends that PCD for abdominal fluid should precede surgical decompression.⁵⁷ The later should be performed only when patients fail to respond to PCD.⁵⁸ As discussed in the sections above, PCD is also useful in the trial of conservative management of GI fistulas.³⁷⁻³⁹

E2. What are the indications of endovascular embolization for pancreatitis-related arterial complications?

Endovascular embolization should be offered to all patients with arterial complications associated with pancreatitis (*GRADE 1C*).

Remarks

Rupture of arterial PSA is associated with a high mortality.⁴ All PSAs need treatment regardless of the size.⁵⁹ The preferred approach to manage the arterial complications is endovascular embolization as it has established safety and efficacy.³³ CTA prior to DSA is useful as it allows the recognition of the involved arterial territory and preprocedural planning of the embolization technique.

E3. What are the contraindications of PCD of PFCs/embolization procedures?

The relative contraindications to drainage of PFC and endovascular embolization of arterial abnormalities are uncorrectable coagulopathy (international normalized ratio [INR] > 1.5) and platelet count < 50,000/ μ L. Contrast allergy and deranged renal function tests are the other relative contraindications for endovascular embolization. Lack of bowel-free approach is an absolute contraindication for catheter drainage (*GRADE 2C*).

Remarks

The general contraindications for percutaneous and endovascular procedures also apply to PCD and endovascular embolization in patients with complications secondary to pancreatitis.⁶⁰ Abnormally prolonged INR should be corrected with fresh frozen plasma to achieve a value below 1.5. Platelet transfusion is required for patients with platelet counts < 50,000/ μ L. Patients with documented allergy to an iodinated contrast agent needs to be carefully assessed. These patients benefit from the change of contrast medium within the same class and premedication.^{61,62} Lack of a bowel-free (small bowel/large bowel) approach precludes PCD. In these situations, surgery is often required. In contrast, transgastric PCD is safe.⁶³

F1. What should be the timing of drainage of PFCs?

Drainage of infected PFCs should ideally be delayed (3–4 weeks after onset of pancreatitis). Earlier drainage is indicated in patients with infected collections, large collections causing pressure symptoms, intra-abdominal hypertension, or those with persistent sepsis (*GRADE 1C*).

Sterile ANCs seldom require drainage and are managed conservatively.² Similarly, ANCs in patients with clinical deterioration, organ failure, and SIRS with no features of infection are managed conservatively. Early interventions are associated with a risk of bleeding and perforation of adjacent hollow viscera.⁶⁴⁻⁶⁶ Infected ANCs, though less common, may require intervention early in the course of the disease. Abdominal compartment syndrome, pressure symptoms caused by compression on adjacent organs, and persistent sepsis are the other indications for early drainage.⁵⁶ The preferred method is PCD. Infected WON requires intervention. The current recommendation to postpone interventions until 4 weeks is based on the experience with primary open surgical necrosectomy.⁵⁵ As currently drainage is employed as the first intervention in the step-up approach, delaying PCD until encapsulation might not be necessary. However, robust clinical data are lacking in this context. van Grinsven et al did a systematic review of the timing of catheter drainage in patients with infected necrotic collections.⁶⁷ Early catheter drainage of the symptomatic PFCs was shown to decrease IAP and interrupt the inflammatory cascade. This has also been shown by a recent study.⁶⁸ A recent study by Mallick et al comprising 258 patients with ANC and 117 patients with WON reported that early PCD is as efficient and safe as delayed PCD.⁵³ Another recent study by Mukund et al comprising 78 patients with ANC showed that early drainage is associated with favorable outcomes.⁵⁴ The mean interval between symptom onset and PCD was 14.3 ± 2.4 days. More than half of the patients were successfully managed with

PCD alone. Postponed versus immediate drainage of infected necrotizing pancreatitis (POINTER trial) is a RCT being undertaken by the Dutch Pancreatitis group to investigate whether immediate catheter drainage in infected necrotizing pancreatitis reduces the risk of complications as compared with the current protocol of delaying intervention until the stage of WON.⁶⁹

F2. Which modality should be used for guidance of percutaneous catheter placement?

Percutaneous catheter placement may be performed under ultrasound or CT guidance based on interventional radiologists' preference, and visibility and the location of collection (*GRADE 2C*).

Remarks

PCD of pancreatic collections can be performed under ultrasound or CT guidance. Ultrasound is easily available and allows real-time needle placement. Besides, ultrasound-guided PCD may be performed even at the bedside in intensive care units. However, deeper collections are not well visualized and may not be amenable to drainage under ultrasound guidance. Deeper and retroperitoneal collections are better accessed with CT guidance. With CT fluoroscopy, real-time placement of the needle is feasible. Fusion techniques, including ultrasound/CT fusion achieve a higher technical success rate but may not be suitable in patients with AP.⁷⁰ Upgradation of the catheter can be done under ultrasound, CT, or fluoroscopic guidance. The feasibility of MRI-guided PCD of pancreatic collections has also been reported but it is not required in most of the patients.⁷¹

F3. What should be the size of drainage catheters?

There are no available data to support a particular size of initial drainage catheter; however, expert consensus suggests that a large bore catheter should preferably be used (*GRADE 2C*).

Remarks

Though there are no standard recommendations regarding the initial catheter size, most of the expert pancreatologists agree that a larger bore catheter should be used.⁵⁵ The initial catheter size is based on interventional radiologists' preference. However, a catheter size of 12 to 14 F is preferable. Following the initial PCD, upsizing of the catheter is required in most cases. The final catheter size may be as large as 30 to 48 Fr depending on the response of the patient to initial drainage.⁷² In a retrospective study by Bruennler et al there was no impact of initial catheter size on the mortality of patients with infected pancreatic necrosis.⁷³ A recent study showed that large sized catheters are associated with better outcomes.⁷⁴ However, prospective randomized studies are required for better evidence.

F4. What should be route for drainage?

The preferred route for drainage of pancreatic collections is retroperitoneal via left posterolateral approach (*GRADE 1C*).

Remarks

The direct and the shortest path for drainage should be used. Vital organs should be avoided. The route depends on the site, size, extent of the collection, and relationship with adjacent organs. The various routes for drainage are retroperitoneal, transperitoneal, transgastric, and transhepatic routes. The organs to be avoided are bowel loops, spleen, and gallbladder. Retroperitoneal access via the left posterolateral approach is preferred as the catheter can be placed along the long axis of the collection.⁷⁵ Additionally, this approach allows for minimally invasive surgical necrosectomy. The transperitoneal route should be used when there is no safe window for retroperitoneal drainage. The transgastric route for drainage of pancreatic collections is less commonly employed.^{76,77} However, in patients with ANC who are not candidates for retroperitoneal or transperitoneal, drainage may benefit from transgastric drainage. In a recent study by Sugimoto et al, transgastric PCD was performed in 54% of the patients. The transhepatic route has been described for inaccessible lesser sac PFCs. In the published studies on the transhepatic drainage of intra-abdominal abscesses and postoperative fluid collections, 100% technical success and no significant complications were reported.⁷⁸⁻⁸⁰

F5. When should the percutaneous catheters be upsized?

Catheter upsizing can be done in persistent collection with reduced output/clinical nonimprovement/deterioration (*GRADE 2C*).

Remarks

Some authors advocate upsizing the PCD on demand, while others upsize it routinely. The need for upsizing depends on various factors like size of the collection, extent of necrotic debris and liquefaction, patient's response to drainage, and clinical course. In a recent survey, two-thirds of the expert pancreatologists agreed that upsizing of the PCD is useful.⁵⁵ The recent series on proactive catheter drainage have also shown that frequent catheter upsizing improves the success rate of PCD and clinical outcomes.^{45,60,81,82} Although there is a lack of conclusive evidence, catheter upsizing should be considered in persistent collection with reduced output/clinical nonimprovement/deterioration.

F6. Till what size should the catheters be upsized?

Based on the available data, no single size limit may be recommended for catheter upsizing (*GRADE 2C*).

Remarks

Despite a consensus regarding the utility of catheter upsizing, there are no data to suggest a maximum size limit for percutaneous catheter. In a study on proactive PCD, patients in the proactive group had a significantly larger final catheter size (median, 16 F vs. 14 F). In the proactive group, 17 (42.5%) patients had a final catheter size of 20 F or larger compared with only 6 (8.8%) patients in the standard group.⁶³ In another study, the final catheter size was 18 F.⁸¹ The maximum size of catheter in the study by Gupta et al was 28 F.⁸² The maximum size depends on the extent of necrotic debris

within the collection and the protocol for management. Percutaneously, up to 28 F catheters can be placed for drainage, particularly for ANC with necrotic debris and when sinus tract endoscopic necrosectomy is needed.

F7. How frequently and what volume of saline irrigation should be done?

Although there is a consensus that percutaneous catheter should be irrigated with saline, there are no clear recommendations regarding the frequency of irrigation and amount of fluid (*GRADE 2C*).

Remarks

Percutaneous catheter is likely to be blocked by the necrotic debris. Irrigation of the catheter is critical to maintain its patency. Additionally, instillation of saline may be utilized for removal of necrotic debris proactively from the PFC. There is a lack of data reporting the use of saline irrigation in these two different contexts. In the PANTER trial, 50 mL of normal saline was instilled every 8 hours.²⁸ Observational studies reporting PCD of pancreatic collections have used volume of saline ranging from 10–20 mL to 1 L.^{45,63,81,82} A recent RCT compared outcomes in patients undergoing large volume lavage (2.5–3 L NS over 24 hours) with those undergoing gravity-dependent drainage.⁸³ Lavage treatment protocol led to a reversal of organ failure in a greater number of patients.

F8. Is antibiotic lavage of the collection via percutaneous catheters recommended?

There are little data to support the routine use of local intracavitary antibiotics (*GRADE 2C*).

Remarks

Studies have questioned the ability of intravenously administered antibiotics to penetrate PFC. However, there are few studies addressing this issue, with a limited number of patients, in the early phase of AP.^{84–86} In a retrospective cohort comprising patients with infected (suspected) WON treated with endoscopic transmural drainage and necrosectomy, 91 patients received concomitant intravenous and local antibiotics.⁸⁷ Local antibiotics were added to the irrigation fluid depending on microbiological findings. Among patients with bacterial infections ($n = 81$), neither systemic nor local antibiotics were associated with the eradication of microorganisms between first and second culture. However, the use of local antibiotics was associated with the eradication of microbes between the second and third culture.⁸⁷ In a study comprising 48 patients with infected pancreatic necrosis, 19 patients responded to systematic antibiotics and did not require any invasive intervention.⁸⁸ Endoscopic drainage and local antibiotic instillation were performed in 20 patients. Nine patients improved while a similar number underwent necrosectomy. Two patients in this group died. Another study demonstrated the safety and efficacy of local antibiotic instillation through the naso-cystic drain.⁸⁹ In this study, 58 patients received amphotericin B, vancomycin, or gentamycin based on the results of initial culture sensitivity.

No detectable blood levels of vancomycin and gentamycin were found. In total, 81% of the cultures responded to one of the antibiotics.

F9. Is there a role of intracavitary instillation of agents via percutaneous catheter to lyse the necrotic contents?

Based on the available literature, routine instillation of agents to facilitate the liquefaction and drainage of necrotic debris cannot be recommended (*GRADE 2C*).

Remarks

The use of hydrogen peroxide has been demonstrated to be beneficial in the endoscopic series. In a study comprising 19 patients with WON, extended cystogastrostomy and hydrogen peroxide irrigation was performed prior to endoscopic necrosectomy.⁹⁰ Technical success was achieved in all patients and clinical success was achieved in 18 out of 19 patients. Bleeding occurred in one patient and was controlled after epinephrine injection and placement of a covered stent. In another study comprising 64 patients, technical and clinical success was achieved in 100 and 90.6% of the patients, respectively, after EUS drainage and instillation of hydrogen peroxide.⁹¹ Life-threatening bleeding occurred in three patients. In a multicenter survey of hydrogen peroxide in endoscopic necrosectomy, 35% of the respondents routinely used hydrogen peroxide.⁹² There is limited utilization of intracavitary streptokinase for pancreatic collections. In a preliminary study, in vitro installation was found effective in achieving lysis of the necrotic contents. In vivo instillation was performed in two patients not responding to the step-up approach and being considered for surgery.⁹³

F10. When should the percutaneous catheter be removed?

The catheter should be removed once the collection has resolved, and the drain output is less than 10 to 20 mL/day for at least 2 to 3 days and there is no residual collection on imaging (*GRADE 2C*).

Remarks

The decision to remove the catheter and stop the drainage is multidisciplinary based on clinical improvement (control of sepsis, resolution of fever, hemodynamic stability, and relief of pressure symptoms), improvement of laboratory parameters (total leucocyte counts, CRP, and procalcitonin levels), and radiological improvement (resolution of collection) with drainage less than 20 mL/day at least for 2 or 3 consecutive days.⁴⁵

F11. Which technique should be used for endovascular embolization of PSA?

The standard technique for endovascular embolization is “sandwich” technique that involves embolization of the arteries proximal and distal to the PSA (*GRADE 1C*).

Remarks

The standard embolization method is sandwich technique, due to the extensive collateral vessels in the mesenteric circulation.³³ In this technique, arterial segments distal and proximal to the neck of the PA should be occluded,

thereby excluding the PSA from the circulation. This is typically done by using coils. If access to the distal segment is not possible, other agents like NBCA glue can be used.⁹⁴ Other embolic agents used include thrombin, gelfoam, and vascular plugs.³³ Uncommonly, when the PSA arises from a proximal segment of hepatic or splenic artery, stent graft may be used to exclude the PSA.

F12. What is the preferred endovascular embolization agent for treatment of pancreatitis-related arterial complications?

The preferred embolization agent is coil (*GRADE 1C*).

Remarks

The most commonly used embolic material for pancreatitis-related arterial complications are microcoils.⁹⁵ Once inside the vessel, the coils attain their inherent spring-like shape and cause occlusion of the artery due to their thrombogenicity. In cases where the parent artery needs to be preserved, the PSA sac may be carefully filled with coils or excluded by a stent graft. For a wide neck aneurysm in a critical artery, one may use either a covered stent or an uncovered stent with coils within the PSA for adequate occlusion.³³ Liquid embolic materials such as NBCA, glue, and ethylene vinyl alcohol copolymer [Onyx; ev3, Plymouth, Minnesota, United States] provide effective permanent embolization when the feeding artery or the PSA can be entered but not crossed to achieve proximal and distal occlusion with coils.⁹⁶ Onyx is a liquid-embolizing agent primarily used in neuro-interventions such as cerebral arteriovenous malformation and dural arteriovenous fistula embolization. It has been used in few studies for GI embolization with good results.^{97,98} Onyx has the advantages of being nonadhesive as well as having high radiopacity and longer solidification time.⁹⁶ However, the disadvantages are increased cost and vasospasm. The use of onyx in treatment of PSA has been described as a few case reports. In a series by Zabicki et al comprising 15 patients, onyx was successfully used in two patients.⁹⁹ Gelfoam can be used as a slurry to cause temporary embolization of tortuous vessels where the anatomy does not allow selective placement of a microcatheter. But its use carries the risk of causing tissue ischemia because of distal vessel blockage. The use of gelfoam alone has been described in a limited number of patients in published series on the endovascular embolization of PSA.^{100,101} Kulkarni et al reported gelfoam embolization in one patient in a series of 38 patients. In the same series, gelfoam was used in combination with coils in two patients.¹⁰⁰ The only series describing the use of gelfoam with or without coils in all patients comprised of 22 patients (27 bleeding sites).⁹⁹ The use of stent-grafts in PSA may be considered if it is involving the common hepatic artery or its main branches which need to be preserved. Kulkarni et al reported use of stent graft in one patient with a large PSA arising from the superior mesenteric artery (SMA).¹⁰⁰

F13. In patients with a PFC and associated PSA, should endovascular embolization be done prior to drainage?

Based on the limited data, embolization of PSA should be done prior to drainage (*GRADE 2C*).

Remarks

The data regarding the management of PFC in the setting of PSA are scarce. In a study by Rana et al, eight patients (seven with AP and one with CP; six WON and two pancreatic pseudocysts) with PSA were managed initially with endovascular embolization followed by transmural drainage of the PFC.¹⁰² All patients were managed successfully without any complications. The same group also described successful management of pancreatic pseudocyst in the setting of PSAs using angioembolization or percutaneous thrombin injection followed by transpapillary drainage in eight patients.¹⁰³

In a larger series, 58 patients with PSA with PFC developing as a complication of AP or CP after discharge from the hospital were evaluated.¹⁰⁴ A combination of angioembolization and endotherapy resulted in a successful management in majority of the patients. Only three patients required surgery. There were no major complications, and 30-day mortality was low. In this study, there was 2-week interval between embolization and endotherapy. This study comprised only pancreatic pseudocysts.

F14. What are the situations where percutaneous embolization of PSA may be considered?

There is a limited role for percutaneous embolization of PSA in situations where the endovascular embolization has failed or is not feasible and EUS-guided intervention is not available or is not feasible or has failed (*GRADE 2C*).

Remarks

There are only a few case reports describing percutaneous embolization of PSA in the setting of pancreatitis.¹⁰⁵⁻¹⁰⁹ This mode of embolization has been utilized for cases with failed endovascular embolization and the PSA is visible on USG. In a series of 19 patients with visceral artery PSAs, percutaneous thrombin injection was used.¹⁰⁸ Seven pancreatitis-related PSAs were embolized using thrombin. There was failure of aneurysmal occlusion in 5 (70%) patients. In another study reporting clinical profile and outcomes in patients with pancreatitis-related PSA, out of the 46 patients, 9 patients underwent percutaneous thrombin injection. Reintervention due to recanalization of PSA was required in only one patient.¹⁰⁹

G1. Do all patients treated with PCD for infected pancreatic necrosis require necrosectomy?

A significant proportion of patients with infected necrosis may be managed with PCD alone (*GRADE 1A*).

Remarks

A systematic review of 384 patients from 10 retrospective studies and 1 RCT evaluated the role of primary PCD for management of necrotizing pancreatitis.¹¹⁰ Infected necrosis was confirmed in 70.6% of the patients. It was found that no additional surgical necrosectomy was needed in 55.7% of patients. Mortality in the group of patients with infected necrosis undergoing PCD was 15.4%. The recent series on pro-active PCD have consistently shown a high success rate but the studies involve considerable heterogeneity in terms

of indications of drainage.^{45,63,80,81} PCD is being increasingly utilized to stabilize critical patients. Once the patients are stable, they may be considered for minimally invasive necrosectomy. These minimally invasive interventions may be performed through the same tract. In another systematic review, 15 studies comprising 577 patients were included. There was 1 RCT and 14 retrospective case series. Definitive treatment was achieved in 56.2% of patients with PCD alone. Additional surgical interventions were performed in 38.5% of patients. The overall mortality rate was 18%.¹¹¹

G2. What is the success rate of endovascular embolization of PSA?

Endovascular embolization has a high technical and clinical success (*GRADE 1C*).

Remarks

Endovascular embolization for PSAs due to pancreatitis has a success rate of 79 to 100% and rebleeding rates of 18 to 37%.^{96,112-116} In recent studies with patients recruited after year 2000, the success rate of endovascular embolization was 95 to 100%.^{112,113,115} Recurrence of bleeding is an outcome that must be suspected if patient develops deterioration of vital parameters after initial improvement.

H1. What are the complications of PCD for PFC?

The immediate procedure-related complications include bleeding and bowel injury. The long-term complications are internal and EPF (*GRADE 1C*).

Remarks

Although bleeding is a life-threatening complication, it is rare. It may be related to vascular injury secondary to catheter insertion or vascular damage induced by pancreatic enzymes in the course of severe ANP. A CTA is performed to investigate the cause of bleed from the percutaneous catheter. Arterial PSA or active contrast extravasation is managed effectively with endovascular embolization.¹⁰⁹ Fistulous communication with bowel loop can be iatrogenic. However, more commonly, it is the result of inflammation/ischemia of the bowel wall resulting from the effect of pancreatic secretion. The most common site for bowel fistulization is the colon.¹³ Other common sites are stomach and duodenum. The fistulization with upper GI tract may be managed conservatively while the colonic fistula requires surgical management.^{37,38} However, recent literature suggests that some colonic fistulae may be managed conservatively. Other methods described for the management of colonic fistulae are over the scope clips and stents. Slippage of catheter requires reinsertion if there is residual collection and patient is symptomatic. Catheter upsizing is frequently required to prevent/treat this event. Blockade of catheter can be prevented by regular saline flushing. EPF is defined as the drainage of clear pancreatic secretions of greater than 100 mL/day beyond 3 weeks of catheter insertion.¹¹⁷ A majority of EPFs can be managed conservatively. However, in the case of refractory EPF, pancreatic stenting may be required, if possible. In a multicenter study, 35 patients with EPF under-

went endoscopic transpapillary stenting ($n = 19$) or conservative management ($n = 16$). There was no significant difference in the rates of fistula closure (84 vs. 75%, $p = 0.18$). However, patients in the former group had shorter median time to closure (71 vs. 120 days, $p = 0.13$).¹¹⁸ In a systematic review, complications were reported in 21.2% of the patients undergoing PCD.³² Of all the complications, 51.5% of the complications were pancreatic fistulas. Significant bleeding was reported in two patients only. Colonic perforation and catheter dislodgement were reported in one patient each. Another systematic review reported a complication rate of 25.1%.¹¹¹ Like the previous meta-analysis, most common complication was fistulas accounting for 44.8% of the total complications.

H2. What are the complications of endovascular embolization of PSA and how will you manage these?

The most significant complication related to endovascular embolization of PSA is non-target embolization (*GRADE 1C*).

Remarks

The complications of endovascular embolization may be related to the technique including the type of embolic agent used and to the underlying clinical status of the patients. With improvement in hardware such as coil designs and deployment systems, super-selective microcatheter profile, the rate of complications is quite low.²⁵ However, organ ischemia such as splenic and liver infarction is possible especially with use of liquid-embolizing materials blocking intraparenchymal branches during non-target embolization. Intestinal infarction is a dreaded complication during embolization of a SMA branch. Other complications include vascular dissections, migration of coils and stents, and rupture of PSA. In a study by Vander Mijnsbrugge et al comprising 34 patients treated with endovascular embolization, there were no major complications.¹¹⁹ Minor complications occurred in 30% patients. The most common complication was partial splenic infarction that occurred in 10.8% of the patients and led to no significant change in the treatment. Postprocedure fever was the next most common complication in 5.4% of the patients and resolved with antibiotics. In another series by Zhang et al comprising 40 patients (AP 19, CP 12, and postpancreatectomy for pancreatic cancer 9), complications were observed in three patients with AP who were treated using NBCA.¹²⁰ This series did not evaluate the incidence of minor splenic infarctions. In a series of 12 patients with CP undergoing endovascular embolization of PSA, complications occurred in two patients.¹¹⁶ One patient had reversible hepatic ischemia due to migration of coil placed in the gastroduodenal artery to the right hepatic artery. The other patient had stent stenosis of the stent graft placed in the common hepatic artery. Series on NBCA have also reported relative safety of the procedure. In a series by Madhusudhan et al comprising 31 patients (including 24 patients with pancreatitis), minor complications (due to non-target embolization) occurred in two patients and major complication in the form of catheter fracture occurred in one patient.⁹⁵ Series by Izaki et al (nine patients) and Won et al (13 patients)

reported no major complications. In both the series, minor complications occurred in two patients and were related to non-target embolization.^{121,122}

11. What is the recommendation for follow-up of PFCs following successful management with PCD?

There are no data to suggest a follow-up protocol specifically for patients treated with PCD. However, the follow-up evaluation of patients with AP includes a comprehensive evaluation by a team comprising medical gastroenterologist, surgeon, and interventional radiologist (*GRADE 2C*).

Remarks

Follow-up evaluation must address three important areas including the prevention strategies based on etiology (cholecystectomy, abstinence from alcohol, management of hypertriglyceridemia, hypercalcemia, etc.), assess the local complications (PFCs), and systemic complications (diabetes mellitus, steatorrhea, and weight loss).¹²³ From the interventional radiologists' perspective, patients need to be evaluated for the status of PFC. There is no recommended protocol for follow-up.

12. How to evaluate patients with PSA treated with endovascular embolization on follow-up?

Following endovascular embolization, patients must be assessed clinically and by serial evaluation of hemoglobin levels to confirm the clinical success. USG may be done to follow up previously visible PSA. There is no clear recommendation for follow-up CTA in patients with resolution of bleeding (*GRADE 2C*).

Remarks

There is no clear recommendation for imaging follow-up of patients treated endovascularly for PSA. Although previous studies have reported the timing of recurrence of PSA, these data may not be enough to suggest a protocol for follow-up imaging. In a long-term follow-up study by Vander Mijnsbrugge et al (mean CT scan follow-up of 40.5 months and clinical follow-up of 80 months), all recurrences (4/34) occurred within first 5 months.¹¹⁹ However, three PSAs arose in different arteries and only one was a true recurrence. In another series comprising six patients who underwent primary endovascular embolization, rebleeding occurred in three patients at a mean interval of 61.3 days (range: 21–136 days).¹²² In a series of 12 patients who underwent endovascular embolization, all patients had an initial follow-up CT scan at a median of 8 days (range: 1–28 days) after the embolization.¹²⁴ Resolution of PSA was documented in all. Eleven patients underwent another follow-up using CT ($n=10$) and Doppler ($n=1$) and all had no recurrence of the PSA. The timing of this follow-up imaging was not mentioned.¹²⁵ In another series comprising 40 patients who underwent endovascular embolization of PSA in the setting of AP, CP, or pancreatic cancer following surgery, rebleeding was encountered in eight patients. All patients had rebleeding at a mean interval of 8 days (range: 0–15 days).¹²⁰

Financial Disclosure

None.

Conflict of Interest

None.

References

- Atkins D, Best D, Briss PA, et al; GRADE Working Group. Grading quality of evidence and strength of recommendations. *BMJ* 2004; 328(7454):1490
- Trikudanathan G, Wolbrink DRJ, van Santvoort HC, Mallery S, Freeman M, Besselink MG. Current concepts in severe acute and necrotizing pancreatitis: an evidence-based approach. *Gastroenterology* 2019;156(07):1994.e3–2007.e3
- Fung C, Svystun O, Fouladi DF, Kawamoto S. CT imaging, classification, and complications of acute pancreatitis. *Abdom Radiol (NY)* 2020;45(05):1243–1252
- Evans RP, Mourad MM, Pall G, Fisher SG, Bramhall SR. Pancreatitis: preventing catastrophic haemorrhage. *World J Gastroenterol* 2017;23(30):5460–5468
- Kim JH, Kim JS, Kim CD, et al. Clinical features of pseudoaneurysms complicating pancreatitis: single center experience and review of Korean literature [in Korean]. *Korean J Gastroenterol* 2007;50(02):108–115
- Bergert H, Hinterseher I, Kersting S, Leonhardt J, Bloomenthal A, Saeger HD. Management and outcome of hemorrhage due to arterial pseudoaneurysms in pancreatitis. *Surgery* 2005;137(03):323–328
- Ding L, Deng F, Yu C, et al. Portosplenomesenteric vein thrombosis in patients with early-stage severe acute pancreatitis. *World J Gastroenterol* 2018;24(35):4054–4060
- Easler J, Muddana V, Furlan A, et al. Portosplenomesenteric venous thrombosis in patients with acute pancreatitis is associated with pancreatic necrosis and usually has a benign course. *Clin Gastroenterol Hepatol* 2014;12(05):854–862
- Harris S, Nadkarni NA, Naina HV, Vege SS. Splanchnic vein thrombosis in acute pancreatitis: a single-center experience. *Pancreas* 2013;42(08):1251–1254
- Nadkarni NA, Khanna S, Vege SS. Splanchnic venous thrombosis and pancreatitis. *Pancreas* 2013;42(06):924–931
- Mortel  KJ, Mergo PJ, Taylor HM, et al. Peripancreatic vascular abnormalities complicating acute pancreatitis: contrast-enhanced helical CT findings. *Eur J Radiol* 2004;52(01):67–72
- Bansal A, Gupta P, Singh H, et al. Gastrointestinal complications in acute and chronic pancreatitis. *JGH Open* 2019;3(06):450–455
- Gupta P, Chayan Das G, Sharma V, et al. Role of computed tomography in prediction of gastrointestinal fistula in patients with acute pancreatitis. *Acta Gastroenterol Belg* 2019;82(04):495–500
- Bang JY, Wilcox CM, Navaneethan U, et al. Impact of disconnected pancreatic duct syndrome on the endoscopic management of pancreatic fluid collections. *Ann Surg* 2018;267(03):561–568
- Bhatia H, Yadav N, Gupta P. Radiological criteria for disconnected pancreatic duct syndrome: a targeted literature review. *Expert Rev Gastroenterol Hepatol* 2022;16(02):121–127
- van Baal MC, Bollen TL, Bakker OJ, et al; Dutch Pancreatitis Study Group. The role of routine fine-needle aspiration in the diagnosis of infected necrotizing pancreatitis. *Surgery* 2014;155(03):442–448
- van Grinsven J, van Brunschot S, van Baal MC, et al; Dutch Pancreatitis Study Group. Natural history of gas configurations and encapsulation in necrotic collections during necrotizing pancreatitis. *J Gastrointest Surg* 2018;22(09):1557–1564
- Rodríguez JR, Razo AO, Targarona J, et al. Debridement and closed packing for sterile or infected necrotizing pancreatitis: insights

- into indications and outcomes in 167 patients. *Ann Surg* 2008; 247(02):294–299
- 19 Chen HZ, Ji L, Li L, et al. Early prediction of infected pancreatic necrosis secondary to necrotizing pancreatitis. *Medicine (Baltimore)* 2017;96(30):e7487
 - 20 Mofidi R, Suttie SA, Patil PV, Ogston S, Parks RW. The value of procalcitonin at predicting the severity of acute pancreatitis and development of infected pancreatic necrosis: systematic review. *Surgery* 2009;146(01):72–81
 - 21 Balthazar EJ. Complications of acute pancreatitis: clinical and CT evaluation. *Radiol Clin North Am* 2002;40(06):1211–1227
 - 22 Saad NE, Saad WE, Davies MG, Waldman DL, Fultz PJ, Rubens DJ. Pseudoaneurysms and the role of minimally invasive techniques in their management. *Radiographics* 2005;25(Suppl 1):S173–S189
 - 23 Barge JU, Lopera JE. Vascular complications of pancreatitis: role of interventional therapy. *Korean J Radiol* 2012;13(Suppl 1):S45–S55
 - 24 Verde F, Fishman EK, Johnson PT. Arterial pseudoaneurysms complicating pancreatitis: literature review. *J Comput Assist Tomogr* 2015;39(01):7–12
 - 25 Jeffers K, Majumder S, Vege SS, Levy M. EUS-guided pancreatic pseudoaneurysm therapy: better to be lucky than good. *Gastrointest Endosc* 2018;87(04):1155–1156
 - 26 Kochhar R, Jain K, Gupta V, et al. Fistulization in the GI tract in acute pancreatitis. *Gastrointest Endosc* 2012;75(02):436–440
 - 27 Sandrasegaran K, Tann M, Jennings SG, et al. Disconnection of the pancreatic duct: an important but overlooked complication of severe acute pancreatitis. *Radiographics* 2007;27(05):1389–1400
 - 28 van Santvoort HC, Besselink MG, Bakker OJ, et al; Dutch Pancreatitis Study Group. A step-up approach or open necrosectomy for necrotizing pancreatitis. *N Engl J Med* 2010;362(16):1491–1502
 - 29 Carter CR, McKay CJ, Imrie CW. Percutaneous necrosectomy and sinus tract endoscopy in the management of infected pancreatic necrosis: an initial experience. *Ann Surg* 2000;232(02):175–180
 - 30 Horvath KD, Kao LS, Wherry KL, Pellegrini CA, Sinanan MN. A technique for laparoscopic-assisted percutaneous drainage of infected pancreatic necrosis and pancreatic abscess. *Surg Endosc* 2001;15(10):1221–1225
 - 31 Gibson SC, Robertson BF, Dickson EJ, McKay CJ, Carter CR. ‘Step-port’ laparoscopic cystgastrostomy for the management of organized solid predominant post-acute fluid collections after severe acute pancreatitis. *HPB (Oxford)* 2014;16(02):170–176
 - 32 Mouli VP, Sreenivas V, Garg PK. Efficacy of conservative treatment, without necrosectomy, for infected pancreatic necrosis: a systematic review and meta-analysis. *Gastroenterology* 2013;144(02):333–340.e2
 - 33 Madhusudhan KS, Venkatesh HA, Gamanagatti S, Garg P, Srivastava DN. Interventional radiology in the management of visceral artery pseudoaneurysms: a review of techniques and embolic materials. *Korean J Radiol* 2016;17(03):351–363
 - 34 Gralnek IM, Dumonceau JM, Kuipers EJ, et al. Diagnosis and management of nonvariceal upper gastrointestinal hemorrhage: European Society of Gastrointestinal Endoscopy (ESGE) Guideline. *Endoscopy* 2015;47(10):a1–a46
 - 35 Ramaswamy RS, Choi HW, Mouser HC, Narsinh KH, McCammack KC, Treesit T, Kinney TB. Role of interventional radiology in the management of acute gastrointestinal bleeding. *World J Radiol* 2014;6(04):82–92
 - 36 Roach H, Roberts SA, Salter R, Williams IM, Wood AM. Endoscopic ultrasound-guided thrombin injection for the treatment of pancreatic pseudoaneurysm. *Endoscopy* 2005;37(09):876–878
 - 37 Jiang W, Tong Z, Yang D, et al. Gastrointestinal fistulas in acute pancreatitis with infected pancreatic or peripancreatic necrosis: a 4-year single-center experience. *Medicine (Baltimore)* 2016;95(14):e3318
 - 38 Hua Z, Su Y, Huang X, et al. Analysis of risk factors related to gastrointestinal fistula in patients with severe acute pancreatitis: a retrospective study of 344 cases in a single Chinese center. *BMC Gastroenterol* 2017;17(01):29
 - 39 Mohamed SR, Siriwardena AK. Understanding the colonic complications of pancreatitis. *Pancreatol* 2008;8(02):153–158
 - 40 Bellin MD, Freeman ML, Gelrud A, et al; PancreasFest Recommendation Conference Participants. Total pancreatectomy and islet autotransplantation in chronic pancreatitis: recommendations from PancreasFest. *Pancreatol* 2014;14(01):27–35
 - 41 Pearson EG, Scaife CL, Mulvihill SJ, Glasgow RE. Roux-en-Y drainage of a pancreatic fistula for disconnected pancreatic duct syndrome after acute necrotizing pancreatitis. *HPB (Oxford)* 2012;14(01):26–31
 - 42 François E, Kahaleh M, Giovannini M, Matos C, Devière J. EUS-guided pancreaticogastrostomy. *Gastrointest Endosc* 2002;56(01):128–133
 - 43 Irani S, Gluck M, Ross A, et al. Resolving external pancreatic fistulas in patients with disconnected pancreatic duct syndrome: using rendezvous techniques to avoid surgery (with video). *Gastrointest Endosc* 2012;76:586–593.e1–e3
 - 44 Arvanitakis M, Delhaye M, Bali MA, et al. Pancreatic-fluid collections: a randomized controlled trial regarding stent removal after endoscopic transmural drainage. *Gastrointest Endosc* 2007;65(04):609–619
 - 45 Gupta P, Gupta J, Kumar C, et al. Aggressive percutaneous catheter drainage protocol for necrotic pancreatic collections. *Dig Dis Sci* 2020;65(12):3696–3701
 - 46 Kapetanos DJ. ERCP in acute biliary pancreatitis. *World J Gastrointest Endosc* 2010;2(01):25–28
 - 47 Mukai S, Itoi T, Baron TH, et al. Indications and techniques of biliary drainage for acute cholangitis in updated Tokyo Guidelines 2018. *J Hepatobiliary Pancreat Sci* 2017;24(10):537–549
 - 48 Blanco PA, Do Pico JJ. Ultrasound-guided percutaneous cholecystostomy in acute cholecystitis: case vignette and review of the technique. *J Ultrasound* 2015;18(04):311–315
 - 49 Manrai M, Kochhar R, Gupta V, et al. Outcome of acute pancreatic and peripancreatic collections occurring in patients with acute pancreatitis. *Ann Surg* 2018;267(02):357–363
 - 50 Rana SS, Sharma RK, Gupta P, Gupta R. Natural course of asymptomatic walled off pancreatic necrosis. *Dig Liver Dis* 2019;51(05):730–734
 - 51 Gupta P, Rana P, Bellam BL, et al. Site and size of extrapancreatic necrosis are associated with clinical outcomes in patients with acute necrotizing pancreatitis. *Pancreatol* 2020;20(01):9–15
 - 52 Gupta P. Percutaneous catheter drainage of walled-off necrosis in acute pancreatitis: “Not so inferior” to endoscopic or surgical drainage. *Pancreatol* 2020;20(05):1023
 - 53 Mallick B, Dhaka N, Gupta P, et al. An audit of percutaneous drainage for acute necrotic collections and walled off necrosis in patients with acute pancreatitis. *Pancreatol* 2018;18(07):727–733
 - 54 Mukund A, Singla N, Bhatia V, Arora A, Patidar Y, Sarin SK. Safety and efficacy of early image-guided percutaneous interventions in acute severe necrotizing pancreatitis: A single-center retrospective study. *Indian J Gastroenterol* 2019;38(06):480–487
 - 55 van Santvoort HC, Bakker OJ, Bollen TL, et al; Dutch Pancreatitis Study Group. A conservative and minimally invasive approach to necrotizing pancreatitis improves outcome. *Gastroenterology* 2011;141(04):1254–1263
 - 56 Working Group IAP/APA Acute Pancreatitis Guidelines. IAP/APA evidence-based guidelines for the management of acute pancreatitis. *Pancreatol* 2013;13(4, Suppl 2):e1–e15
 - 57 Kirkpatrick AW, Roberts DJ, De Waele J, et al; Pediatric Guidelines Sub-Committee for the World Society of the Abdominal Compartment Syndrome. Intra-abdominal hypertension and the abdominal compartment syndrome: updated consensus definitions and clinical practice guidelines from the World Society of

- the Abdominal Compartment Syndrome. *Intensive Care Med* 2013;39(07):1190–1206
- 58 Mentula P, Hienonen P, Kemppainen E, Puolakkainen P, Leppäniemi A. Surgical decompression for abdominal compartment syndrome in severe acute pancreatitis. *Arch Surg* 2010;145(08):764–769
 - 59 Jana M, Gamanagatti S, Mukund A, et al. Endovascular management in abdominal visceral arterial aneurysms: a pictorial essay. *World J Radiol* 2011;3(07):182–187
 - 60 Patel IJ, Davidson JC, Nikolich B, et al; Standards of Practice Committee, with Cardiovascular and Interventional Radiological Society of Europe (CIRSE) Endorsement. Consensus guidelines for periprocedural management of coagulation status and hemostasis risk in percutaneous image-guided interventions. *J Vasc Interv Radiol* 2012;23(06):727–736
 - 61 Abe S, Fukuda H, Tobe K, Ibukuro K. Protective effect against repeat adverse reactions to iodinated contrast medium: pre-medication vs. changing the contrast medium. *Eur Radiol* 2016;26(07):2148–2154
 - 62 Park HJ, Park JW, Yang MS, et al. Re-exposure to low osmolar iodinated contrast media in patients with prior moderate-to-severe hypersensitivity reactions: a multicentre retrospective cohort study. *Eur Radiol* 2017;27(07):2886–2893
 - 63 Sugimoto M, Sonntag D-P, Flint G-S, et al. Better outcomes if percutaneous drainage is used early and proactively in the course of necrotizing pancreatitis. *J Vasc Interv Radiol* 2016;27(03):418–425
 - 64 Fernández-del Castillo C, Rattner DW, Makary MA, Mostafavi A, McGrath D, Warshaw AL. Débridement and closed packing for the treatment of necrotizing pancreatitis. *Ann Surg* 1998;228(05):676–684
 - 65 Besselink MG, Verwer TJ, Schoenmaeckers EJ, et al. Timing of surgical intervention in necrotizing pancreatitis. *Arch Surg* 2007;142(12):1194–1201
 - 66 Mier J, León EL, Castillo A, Robledo F, Blanco R. Early versus late necrosectomy in severe necrotizing pancreatitis. *Am J Surg* 1997;173(02):71–75
 - 67 van Grinsven J, van Santvoort HC, Boermeester MA, et al; Dutch Pancreatitis Study Group. Timing of catheter drainage in infected necrotizing pancreatitis. *Nat Rev Gastroenterol Hepatol* 2016;13(05):306–312
 - 68 Singh AK, Samanta J, Dawra S, et al. Reduction of intra-abdominal pressure after percutaneous catheter drainage of pancreatic fluid collection predicts survival. *Pancreatol* 2020;20(04):772–777
 - 69 van Grinsven J, van Dijk SM, Dijkgraaf MG, et al; Dutch Pancreatitis Study Group. Postponed or immediate drainage of infected necrotizing pancreatitis (PONTER trial): study protocol for a randomized controlled trial. *Trials* 2019;20(01):239
 - 70 Zhang H, Chen GY, Xiao L, et al. Ultrasonic/CT image fusion guidance facilitating percutaneous catheter drainage in treatment of acute pancreatitis complicated with infected walled-off necrosis. *Pancreatol* 2018;18(06):635–641
 - 71 Kariniemi J, Sequeiros RB, Ojala R, Tervonen O. Feasibility of MR imaging-guided percutaneous drainage of pancreatic fluid collections. *J Vasc Interv Radiol* 2006;17(08):1321–1326
 - 72 Gupta P, Koshi S, Samanta J, et al. Kissing catheter technique for percutaneous catheter drainage of necrotic pancreatic collections in acute pancreatitis. *Exp Ther Med* 2020;20(03):2311–2316
 - 73 Gupta P, Bansal A, Samanta J, et al. Larger bore percutaneous catheter in necrotic pancreatic fluid collection is associated with better outcomes. *Eur Radiol* 2021;31(05):3439–3446
 - 74 Bruennler T, Langgartner J, Lang S, et al. Outcome of patients with acute, necrotizing pancreatitis requiring drainage-does drainage size matter? *World J Gastroenterol* 2008;14(05):725–730
 - 75 Makris GC, See T, Winterbottom A, Jah A, Shaida N. Minimally invasive pancreatic necrosectomy; a technical pictorial review. *Br J Radiol* 2018;91(1082):20170435
 - 76 Nuñez D Jr, Yrizarry JM, Russell E, et al. Transgastric drainage of pancreatic fluid collections. *AJR Am J Roentgenol* 1985;145(04):815–818
 - 77 Amundson GM, Towbin RB, Mueller DL, Seagram CG. Percutaneous transgastric drainage of the lesser sac in children. *Pediatr Radiol* 1990;20(08):590–593
 - 78 Yamakado K, Takaki H, Nakatsuka A, et al. Percutaneous transhepatic drainage of inaccessible abdominal abscesses following abdominal surgery under real-time CT-fluoroscopic guidance. *Cardiovasc Intervent Radiol* 2010;33(01):161–163
 - 79 Ciftci TT, Akinci D, Akhan O. Percutaneous transhepatic drainage of inaccessible postoperative abdominal abscesses. *AJR Am J Radiol* 2012;198:477–481
 - 80 Zhao N, Li Q, Cui J, Yang Z, Peng T. CT-guided special approaches of drainage for intraabdominal and pelvic abscesses: one single center's experience and review of literature. *Medicine (Baltimore)* 2018;97(42):e12905
 - 81 van Grinsven J, Timmerman P, van Lienden K-P, et al; Dutch Pancreatitis Study Group. Proactive versus standard percutaneous catheter drainage for infected necrotizing pancreatitis. *Pancreas* 2017;46(04):518–523
 - 82 Sugimoto M, Sonntag D-P, Flint G-S, et al. A percutaneous drainage protocol for severe and moderately severe acute pancreatitis. *Surg Endosc* 2015;29(11):3282–3291
 - 83 Kohli P, Gupta V, Kochhar R, Yadav TD, Sinha SK, Lal A. Lavage through percutaneous catheter drains in severe acute pancreatitis: does it help? A randomized control trial. *Pancreatol* 2019;19(07):929–934
 - 84 Adam U, Herms S, Werner U, et al. The penetration of ciprofloxacin into human pancreatic and peripancreatic necroses in acute necrotizing pancreatitis. *Infection* 2001;29(06):326–331
 - 85 Bassi C, Pederzoli P, Vesentini S, et al. Behavior of antibiotics during human necrotizing pancreatitis. *Antimicrob Agents Chemother* 1994;38(04):830–836
 - 86 Sağlamkaya U, Mas MR, Yaşar M, Simşek I, Mas NN, Kocabalkan F. Penetration of meropenem and cefepim into pancreatic tissue during the course of experimental acute pancreatitis. *Pancreas* 2002;24(03):264–268
 - 87 Werge M, Novovic S, Roug S, et al. Evaluation of local instillation of antibiotics in infected walled-off pancreatic necrosis. *Pancreatol* 2018;18(06):642–646
 - 88 Lariño-Noia J, de la Iglesia-García D, González-Lopez J, et al. Endoscopic drainage with local infusion of antibiotics to avoid necrosectomy of infected walled-off necrosis. *Surg Endosc* 2021;35(02):644–651
 - 89 Schmidt PN, Roug S, Werge M, et al. Local instillation of antibiotics through naso-cystic catheter is safe and provides broad coverage of microorganisms found in infected pancreatic necrosis. *Gastroenterology* 2014;146:S-621
 - 90 Othman MO, Elhanafi S, Saadi M, Yu C, Davis BR. Extended cystogastrostomy with hydrogen peroxide irrigation facilitates endoscopic pancreatic necrosectomy. *Diagn Ther Endosc* 2017;2017:7145803
 - 91 Bansal RK, Puri R, Choudhary NS, et al. Endoscopic pancreatic necrosectomy: why scuff when you can flush the muck - make it an easy row to hoe. *Endosc Int Open* 2017;5(09):E847–E853
 - 92 Messallam AA, Adler DG, Papachristou GI, et al. Hydrogen peroxide lavage in endoscopic necrosectomy: a multicenter survey of techniques. *Gastrointest Endosc* 2019;89(06):AB413–AB414
 - 93 Gupta R, Shenvi SD, Nada R, et al. Streptokinase may play role in expanding non-operative management of infected walled off pancreatic necrosis: preliminary results. *Pancreatol* 2014;14(05):415–418

- 94 Falsarella PM, Rocha RD, Rahal Junior A, Mendes GF, Garcia RG. Minimally invasive treatment of complex collections: safety and efficacy of recombinant tissue plasminogen activator as an adjuvant to percutaneous drainage. *Radiol Bras* 2018;51(04):231–235
- 95 Madhusudhan KS, Gamanagatti S, Garg P, et al. Endovascular embolization of visceral artery pseudoaneurysms using modified injection technique with N-butyl cyanoacrylate glue. *J Vasc Interv Radiol* 2015;26(11):1718–1725
- 96 Nicholson AA, Patel J, McPherson S, Shaw DR, Kessel D. Endovascular treatment of visceral aneurysms associated with pancreatitis and a suggested classification with therapeutic implications. *J Vasc Interv Radiol* 2006;17(08):1279–1285
- 97 Lenhart M, Paetzel C, Sackmann M, et al. Superselective arterial embolisation with a liquid polyvinyl alcohol copolymer in patients with acute gastrointestinal haemorrhage. *Eur Radiol* 2010;20(08):1994–1999
- 98 Urbano J, Manuel Cabrera J, Franco A, Alonso-Burgos A. Selective arterial embolization with ethylene-vinyl alcohol copolymer for control of massive lower gastrointestinal bleeding: feasibility and initial experience. *J Vasc Interv Radiol* 2014;25(06):839–846
- 99 Zabicki B, Limphaibool N, Holstad MJV, Juszkat R. Endovascular management of pancreatitis-related pseudoaneurysms: a review of techniques. *PLoS One* 2018;13(01):e0191998
- 100 Kulkarni CB, Moorthy S, Pullara SK, Prabhu NK, Kannan RR, Nazar PK. Endovascular management of pancreatitis related pseudoaneurysms – a single center experience. *Gastrointest Interv* 2014;3(01):46–53
- 101 Ai M, Lu G, Xu J. Endovascular embolization of arterial bleeding in patients with severe acute pancreatitis. *WideochirInne Tech MaloInwazyjne* 2019;14(03):401–407
- 102 Rana SS, Kumar A, Lal A, et al. Safety and efficacy of angioembolisation followed by endoscopic ultrasound guided transmural drainage for pancreatic fluid collections associated with arterial pseudoaneurysm. *Pancreatol* 2017;17(05):658–662
- 103 Bhasin DK, Rana SS, Sharma V, et al. Non-surgical management of pancreatic pseudocysts associated with arterial pseudoaneurysm. *Pancreatol* 2013;13(03):250–253
- 104 Nykänen T, Udd M, Peltola EK, Leppäniemi A, Kylänpää L. Bleeding pancreatic pseudoaneurysms: management by angioembolization combined with therapeutic endoscopy. *Surg Endosc* 2017;31(02):692–703
- 105 Garg PK, Khera PS, Rajagopal R, Mehta N, Tarafdar S. Primary management of large pancreatic pseudoaneurysm by ultrasound-guided percutaneous thrombin injection after failure of transarterial pseudoaneurysm embolization. *J Clin Interv Radiol ISVIR* 2017;01(02):130–133
- 106 Chauhan U, Puri SK, Jain N, et al. Percutaneous thrombin injection under sonographic guidance for exclusion of non-catheterizable post-pancreatitis pseudoaneurysm of the superior mesenteric artery: a minimally invasive and expeditious treatment option. *J Med Ultrason* 2016;43(02):295–299
- 107 Michimoto K, Higuchi T, Enoki K, Matsui Y, Takenaga S, Saeki C. Percutaneous puncture and embolisation for pancreatitis-related pseudoaneurysm: the feasibility of thrombin injection even in collection of fluid surrounding the pseudoaneurysm. *Pol J Radiol* 2018;83(83):e510–e513
- 108 Sagar S, Soundarajan R, Gupta P, et al. Efficacy of endovascular embolization of arterial pseudoaneurysms in pancreatitis: a systematic review and meta-analysis. *Pancreatol* 2021;21(01):46–58
- 109 Mallick B, Malik S, Gupta P, et al. Arterial pseudoaneurysms in acute and chronic pancreatitis: clinical profile and outcome. *JGH Open* 2018;3(02):126–132
- 110 van Baal MC, van Santvoort HC, Bollen TL, Bakker OJ, Besselink MG, Gooszen HGDutch Pancreatitis Study Group. Systematic review of percutaneous catheter drainage as primary treatment for necrotizing pancreatitis. *Br J Surg* 2011;98(01):18–27
- 111 Ke L, Li J, Hu P, Wang L, Chen H, Zhu Y. Percutaneous catheter drainage in infected pancreatitis necrosis: a systematic review. *Indian J Surg* 2016;78(03):221–228
- 112 Zhang ZH, Ding YX, Wu YD, Gao CC, Li F. A meta-analysis and systematic review of percutaneous catheter drainage in treating infected pancreatitis necrosis. *Medicine (Baltimore)* 2018;97(47):e12999
- 113 Chiang KC, Chen TH, Hsu JT. Management of chronic pancreatitis complicated with a bleeding pseudoaneurysm. *World J Gastroenterol* 2014;20(43):16132–16137
- 114 Hsu JT, Yeh CN, Hung CF, et al. Management and outcome of bleeding pseudoaneurysm associated with chronic pancreatitis. *BMC Gastroenterol* 2006;6:3
- 115 Zyromski NJ, Vieira C, Stecker M, et al. Improved outcomes in postoperative and pancreatitis-related visceral pseudoaneurysms. *J Gastrointest Surg* 2007;11(01):50–55
- 116 Gabrielli D, Tagliatalata F, Mantini C, Giammarino A, Modestino F, Cotroneo AR. Endovascular treatment of visceral artery pseudoaneurysms in patients with chronic pancreatitis: our single-center experience. *Ann Vasc Surg* 2017;45:112–116
- 117 Bassi C, Marchegiani G, Dervenis C, et al; International Study Group on Pancreatic Surgery (ISGPS) The 2016 update of the International Study Group (ISGPS) definition and grading of postoperative pancreatic fistula: 11 years after. *Surgery* 2017;161(03):584–591
- 118 Bakker OJ, van Baal MC, van Santvoort HC, et al; Dutch Pancreatitis Study Group. Endoscopic transpapillary stenting or conservative treatment for pancreatic fistulas in necrotizing pancreatitis: multicenter series and literature review. *Ann Surg* 2011;253(05):961–967
- 119 Vander Mijnsbrugge W, Laleman W, Van Steenberghe W, Heye S, Verslype C, Maleux G. Long-term clinical and radiological outcome of endovascular embolization of pancreatitis-related pseudoaneurysms. *Acta Radiol* 2017;58(03):316–322
- 120 Zhang C, Li A, Luo T, et al. Strategy and management of severe hemorrhage complicating pancreatitis and post-pancreatectomy. *Diagn Interv Radiol* 2019;25(01):81–89
- 121 Izaki K, Yamaguchi M, Kawasaki R, Okada T, Sugimura K, Sugimoto K. N-butyl cyanoacrylate embolization for pseudoaneurysms complicating pancreatitis or pancreatectomy. *J Vasc Interv Radiol* 2011;22(03):302–308
- 122 Won Y, Lee SL, Kim Y, Ku YM. Clinical efficacy of transcatheter embolization of visceral artery pseudoaneurysms using N-butyl cyanoacrylate (NBCA). *Diagn Interv Imaging* 2015;96(06):563–569
- 123 Wu BU, Conwell DL. Acute pancreatitis part I: approach to early management. *Clin Gastroenterol Hepatol* 2010;8(05):410–416, quiz e56–e58
- 124 Fitzpatrick J, Bhat R, Young JA. Angiographic embolization is an effective treatment of severe hemorrhage in pancreatitis. *Pancreas* 2014;43(03):436–439
- 125 De Rosa A, Gomez D, Pollock JG, et al. The radiological management of pseudoaneurysms complicating pancreatitis. *JOP* 2012;13(06):660–666