Article published online: 2022-08-15

Multicentric Fibrolamellar Hepatocellular Carcinoma: A Rare Case Report

Mayank Goyal[1] Komerisetty Rozaih [1] Salil Bhargava[1] Swapnil Sheth[1] Samarjit Singh Ghuman[2] Tarvinder B. S. Buxi[2]

[1] Department of Radiology, Sir Ganga Ram Hospital, New Delhi, India
[2] Department of CT and MRI, Sir Ganga Ram Hospital, New Delhi, India

J Gastrointestinal Abdominal Radiol ISGAR 2023;6:42–46.

Address for correspondence Mayank Goyal, Department of Radiology, Sir Ganga Ram Hospital, New Delhi 110049, India (e-mail: mayankgoyal0936@gmail.com).

Abstract

Multicentric fibrolamellar hepatocellular carcinoma has not been reported yet in the world as of our knowledge. A Medline search for the term "multicentric fibrolamellar HCC" did not return any results. To our knowledge, this is the first case report of multicentric fibrolamellar hepatocellular carcinoma (HCC). We present the case of a 22-year-old male patient who had complaints of epigastric pain for 1 month. His general physical examinations were normal. Computed tomography of the abdomen revealed multiple hyper-enhancing space-occupying lesions, one of which showed a central scar. The final diagnosis of the case was multicentric fibrolamellar HCC, which was biopsy proven.

Keywords
- fibrolamellar HCC
- metastasis
- multicenteric

Introduction

Fibrolamellar hepatocellular carcinoma (HCC) is a rare primary hepatic neoplasm that occurs predominantly in young individuals, between 5 and 35 years of age. It does not show any sex predilection. Patients usually complain of abdominal pain, malaise, weight loss, and sometimes a palpable abdominal mass. On imaging, it usually presents as a solitary, lobulated, well-defined large tumor containing central fibrous scar with calcification in more than 50% of cases. On contrast imaging, it shows heterogeneous enhancement on arterial phase and maybe hypo, iso, or hyperattenuating on subsequent phases while conventional HCC shows hyperenhancement on arterial phase with washout in subsequent phases. Unlike conventional HCC, the fibrolamellar variant is alpha fetoprotein (AFP) negative and patients have no evidence of underlying hepatitis or cirrhosis.[1] No causative factors for this tumor have been identified; however, it may rarely co-exist with other hepatic tumors, such as HCC, focal nodular hyperplasia, and cholangiocarcinoma. Molecular diagnosis suggests overexpression of anterior gradient-2 with moderate-to-intense expression of CD133 and CD44.[2] Histologically, it shows the presence of clusters of large polygonal or spindle-shaped tumor cells with abundant granular eosinophilic cytoplasm and prominent nuclei with fibrous stroma arranged in thin parallel lamellae around tumor cells.[3] Imaging is crucial in the diagnosis of fibrolamellar HCC. Multiphase CT abdomen is done for diagnosis and characterization of the lesion. MRI abdomen may be used as an alternative imaging modality. A biopsy is usually necessary to confirm the diagnosis.[1]

Case Description

A 22-year-old male patient with a history of epigastric pain for 1 month was admitted to our hospital. He was conscious, oriented, and had no pallor or icterus on general examination. On physical examination, the abdomen was soft and non-tender. A palpable mass was noted in the epigastric region. AFP was normal. Computed tomography angiography

article published online
August 15, 2022

DOI https://doi.org/10.1055/s-0042-1753535.
ISSN 2581-9933.

© 2022. Indian Society of Gastrointestinal and Abdominal Radiology. All rights reserved.
This is an open access article published by Thieme under the terms of the Creative Commons Attribution-NonDerivative-NonCommercial-License, permitting copying and reproduction so long as the original work is given appropriate credit. Contents may not be used for commercial purposes, or adapted, remixed, transformed or built upon. (https://creativecommons.org/licenses/by-nc-nd/4.0/)
Thieme Medical and Scientific Publishers Pvt. Ltd., A-12, 2nd Floor, Sector 2, Noida-201301 UP, India

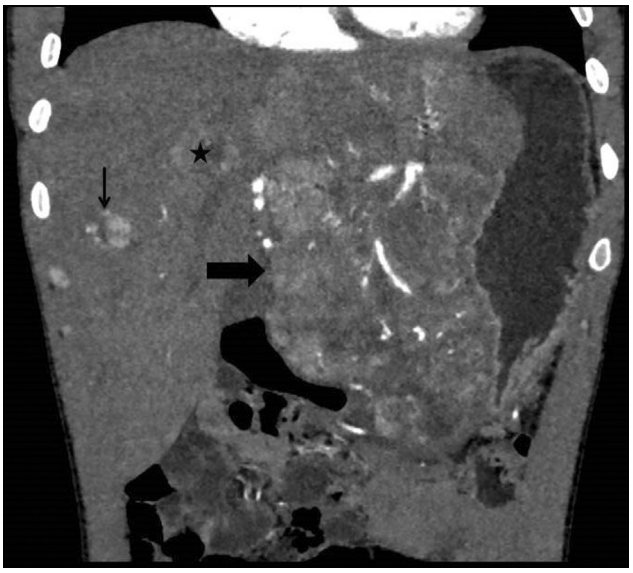

Fig. 1 Coronal CT image in arterial phase shows a large *(thick arrow)* exophytic hypervascular enhancing lesion showing entire involvement of the left lobe with two small round hypervascular enhancing lesions in the right lobe of liver segment 4a(*) and 5/8 (*linear small arrow*).

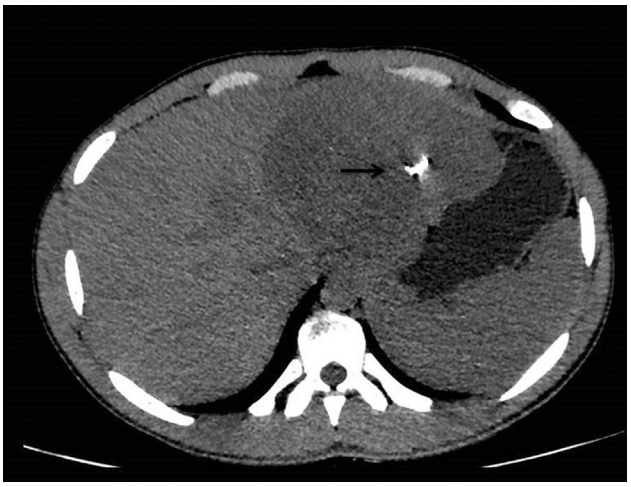

Fig. 2 Axial unenhanced CT showing a large hypodense lesion in segment 2/3 of the liver with central foci of calcification (*linear thin arrow*).

(CTA) of the abdomen was performed on 02/06/2021 revealed a large lobulated exophytic mass (►**Fig. 1**) with a central calcified scar (►**Fig. 2**) in segment 2/3 of the left lobe of the liver. The lesion showed arterial phase enhancement with washout in the venous phase (►**Fig. 3**). The scar showed no enhancement on any phase. Three smaller, rounded lesions with similar characteristics were seen separate from this large lesion in segments 4a/8, 5/8, and 6 (►**Figs. 1** and **4**). There was no imaging appearance suggestive of CLD. No significant lymphadenopathy was seen. In the view of multiple arterial phase enhancing lesions, in a young, non-cirrhotic patient, the first possibility considered was hypervascular metastases, possibly from a neuroendocrine lesion. Other possibilities included multiple hepatic adenomas. In view of multicentricity and lack of a surgical option, the patient was advised biopsy, which was performed under USG guidance.

Sections from lesion biopsy showed effaced parent hepatic lobular architecture by atypical epithelial cells arranged in two to three cell thick trabeculae and pseudo glandular structures. The tumor cells appeared polygonal, having eosinophilic abundant granular cytoplasm, moderately pleomorphic vesicular nuclei with prominent inclusion such as nucleoli. Focal areas of fibrosis were seen. On Immunohistochemistry (IHC), the tumor cells were positive for CK7, glypican, and focally for CD44 (►**Fig. 5**). These findings were compatible with a well-differentiated HCC favoring the fibrolamellar variant.

As per the clinical-radio-pathological profile, findings were suggestive of multicentric fibrolamellar HCC.

Discussion

Fibrolamellar carcinoma was first described by Edmondson in 1956 as a separate entity from HCC.[4] The demographics of conventional HCC are different as it usually affects the elderly patients with underlying liver cirrhosis or hepatitis and shows elevated α-fetoprotein levels unlike in fibrolamellar variant that affects younger people with no underlying liver disease and no elevation of α-fetoprotein.[3] The distribution of the disease is usually seen starting from late adolescence to a peak incidence at 24.8 ± 13 years with a mild predilection for Caucasians; however, no sex predilection is noted.[5] Common presentations of patients are abdominal pain, malaise, weight loss, and other non-specific symptoms including gynecomastia, elevated levels of estrogen.[6]

Imaging plays an important role in pre-operative lesion characterization and reach an appropriate decision for further management. Even though ultrasound is not an imaging modality of choice, lesions may be detected on initial screening. On USG, fibrolamellar HCC is seen as well-defined mixed echogenicity mass lesion with hyperechoic central scar due to calcific foci.[7]

On CT, fibrolamellar carcinomas appear as solitary masses with lobulated surfaces. Approximately 35 to 68% of lesions may show central small calcifications (less than 5 mm). A stellate or amorphous central scar is seen in 20 to 71%. Enlarged lymph nodes are seen in more than 50% of cases, mostly in the region of the hepatic hilum.[8] On giving IV contrast, the lesion shows heterogeneous enhancement on arterial phase due to central fibrous scar. On portal and delayed phases of imaging, the lesion shows variable appearances. It can be hypo, iso, or hyperattenuating to liver parenchyma. Recent studies have suggested that central scar shows delayed enhancement in 25 to 65% of cases.[3] The MRI signal characteristics of the lesion are T1 hypointense, T2 isointense to slightly hyperintense with a central T2 hypointense scar. Fibrolamellar HCC does not retain hepatobiliary-specific contrast agents, such as gadoxetate disodium and gadobenate dimeglumine, on the delayed phase (1–3 hours).[9] On nuclear imaging, fibrolamellar HCC does not show any uptake of technetium 99m-labeled sulfur colloid

 © 2022. Indian Society of Gastrointestinal and Abdominal Radiology. All rights reserved.

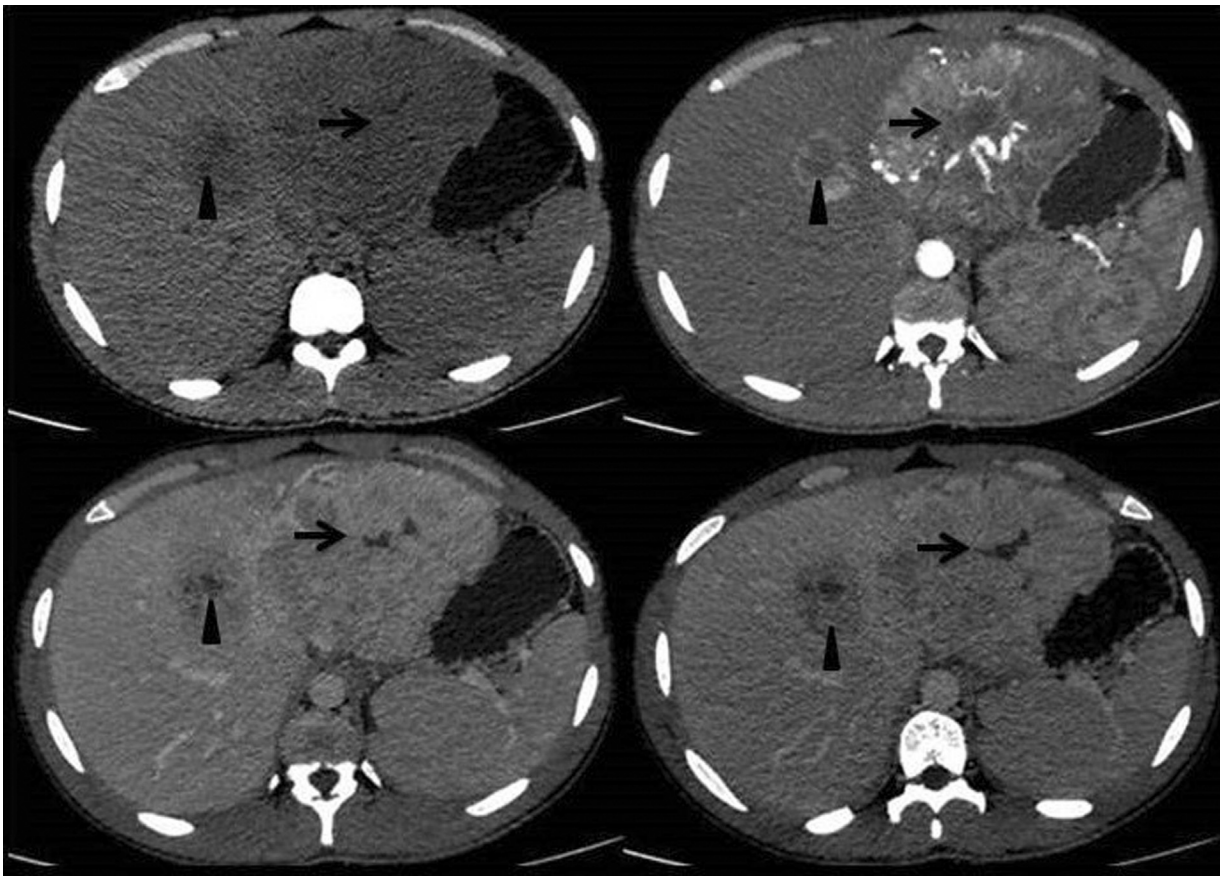

Fig. 3 (**A**) Axial unenhanced CT images show large and small hypoattenuating masses in the liver. (**B**) Axial contrast-enhanced CT (arterial phase) image shows hypervascular enhancing lesions (large and small) with central hypoenhancing scar (*linear arrow and arrowhead*) area within. (**C**) Axial contrast-enhanced CT (venous phase) image shows almost isoattenuating lesions (large and small) compared with the liver with central hypoattenuating scar (*linear arrow and arrowhead*) area within. (**D**) Axial CT delayed phase reveals washout with mild hypoattenuating lesions (large and small) compared with the liver.

Fig. 4 Coronal CT reconstruction in the arterial phase shows another small hyperenhancing lesion in segment 6 (*linear arrow*) of the right lobe of the liver.

because Kupffer cells are neither present nor metabolically active in this neoplasm.[7]

On gross examination, the lesion appears pale tan to yellow with a central scar in most of the lesions. On histological study, fibrolamellar HCC typically shows sheets of polygonal cells with eosinophilic cytoplasm, vesiculated nuclei with large nucleoli against a background of lamellar fibrosis. On immunohistochemistry, the lesion shows positive for hepatocyte paraffin; cytokeratin 8,18, and 7; metalloproteinase 2; chromogranin and neurotensin; however, it was negative for α-fetoprotein.[5]

Differentials

Hypervascular metastasis: Hypervascular metastasis in the liver usually arise from neuroendocrine tumors, renal cell carcinoma, thyroid cancer, insulinoma, etc. These lesions show hyperenhancement on the arterial phase with early washout and becoming isodense or hypodense to surrounding liver parenchyma in the delayed phase. In addition, on serial delayed contrast-enhanced images, centripetal filling with peripheral washout giving target appearance is highly

 © 2022. Indian Society of Gastrointestinal and Abdominal Radiology. All rights reserved.

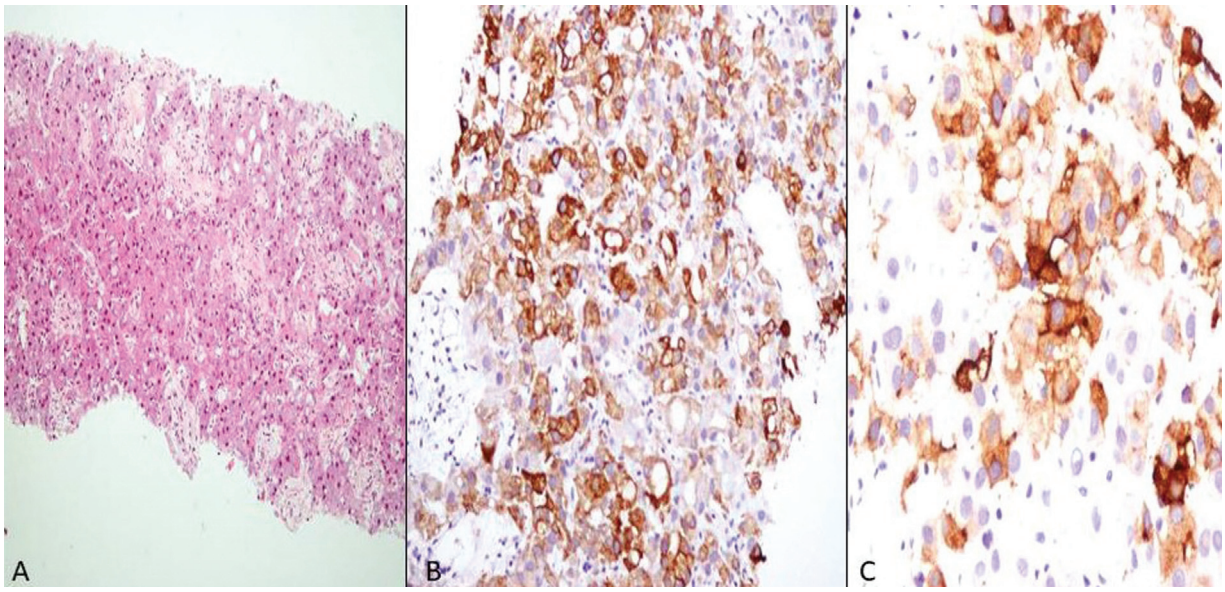

Fig. 5 (**A**) Effaced hepatic lobular architecture by atypical epithelial cells arranged in two or three cell thick trabeculae and pseudoglandular structures. (**B**) Tumor cells are positive for CK7. (**C**) Tumor cells are positive for glypican 3.

specific for hypervascular metastasis, which is not seen in fibrolamellar HCC.[10] There is no evidence of central scar and calcifications in hypervascular metastases, which is seen in FLC. Large metastases may show hemorrhagic and cystic changes within.[11]

Fibronodular hyperplasia (FNH): FNH usually presents as a solitary lesion, less than 5 cm in diameter. Atypically, FNH can present as a large lesion, maybe multiple as in Klippel–Trenaunay–Weber syndrome. Calcification is rarely seen in FNH but it is more frequent in fibrolamellar HCC. On the arterial phase of enhancement, it shows intense contrast enhancement in 96% of cases except for the central scar, which shows gradual filling in on subsequent phases. During the portal phase, the lesion becomes isointense to the liver parenchyma. The delayed phase shows a hypoattenuating lesion with a central enhancing scar. On nuclear imaging, FNH shows uptake of technetium 99m-labeled sulfur colloid, which is not seen in FL-HCC due to lack of Kupffer cells. On MRI, FNH presents as a T2W hyperintense lesion with a central hyperintense scar. FNH retains hepatobiliary-specific contrast agents, such as gadoxetate disodium and gadobenate dimeglumine (Gd bopta) and appears hyperintense on delayed phase (1–3 hours), whereas FL-HCC do not retain the contrast, which potentially may be useful in differentiating fibrolamellar HCC from FNH.[12]

Hepatic adenoma: It typically occurs in young female patients who are taking oral contraceptive pills. Adenomas are sharply marginated (85% of cases), non-lobulated (95%), sometimes encapsulated (30%), and rarely show calcifications (10%) unlike fibrolamellar HCC, which is a large heterogeneous, and lobulated mass with a large central, or eccentric scar and radiating fibrous septa. Calcifications are present in 40 to 68% of FLC. On imaging, most adenomas show homogenous enhancement on the arterial phase, which is usually heterogeneous in FLC. On MRI, adenomas usually show T1W and T2W hyperintense signals; however, variability in the signal can be present depending upon their contents while FLC usually shows a hypointense signal on the T1W sequence. In addition, abdominal lymphadenopathy is noted in 65% of patients with fibrolamellar HCC, which is not seen with hepatic adenomas.[13]

Conventional HCC: It usually present in elderly patients with background cirrhosis or viral hepatitis. Calcification is rare in conventional HCC, which is a common finding in fibrolamellar HCC. On CT and MRI, conventional HCC shows enhancement on the arterial phase and washout on subsequent phases, whereas fibrolamellar HCC shows heterogeneous enhancement on the arterial phase and maybe hypoattenuating, isoattenuating, or even hyperattenuating on subsequent phases. Elevated α-fetoprotein levels are mostly encountered in conventional types.[14] HCCs can also be encountered in non-cirrhotics in ~20% of cases. HCC in non-cirrhotics presents as a single well-circumscribed encapsulated hypoattenuating lesion on plain CT, with areas of fat, foci of hemorrhage, and necrotic areas that are more commonly encountered in this variety as compared with HCC in cirrhotics; however, contrast enhancement features are similar as in HCC of cirrhotics. The FLC variant may show more or less similar post-contrast characteristics as HCC in non-cirrhotics but often demonstrates internal calcifications, central scar, and a discontinuous capsule.[15]

Conclusion

Fibrolamellar carcinoma is a rare type of liver tumor mostly seen in young adults. Clinical, epidemiologic, cytogenetic, and histopathologic features of fibrolamellar HCC significantly differ from conventional HCC.

Fibrolamellar HCC were thus far considered as solitary lesions. This case shows that it may be multicentric and has to be differentiated from hypervascular metastases, hepatic adenomas, etc. We could not find any other lesions in the

 © 2022. Indian Society of Gastrointestinal and Abdominal Radiology. All rights reserved.

abdominal cavity to consider these lesions to be metastatic, so the smaller lesions in the liver were considered to be multicentric FLHCC rather than solitary FLHCC with metastasis.

Conflict of Interest
None declared.

References

1 Craig JR, Peters RL, Edmondson HA, Omata M. Fibrolamellar carcinoma of the liver: a tumor of adolescents and young adults with distinctive clinico-pathologic features. Cancer 1980;46(02): 372–379
2 Vivekanandan P, Micchelli ST, Torbenson M. Anterior gradient-2 is overexpressed by fibrolamellar carcinomas. Hum Pathol 2009;40 (03):293–299
3 Ichikawa T, Federle MP, Grazioli L, Madariaga J, Nalesnik M, Marsh W. Fibrolamellar hepatocellular carcinoma: imaging and pathologic findings in 31 recent cases. Radiology 1999;213(02):352–361
4 Edmondson HA. Differential diagnosis of tumors and tumor-like lesions of liver in infancy and childhood. AMA J Dis Child 1956;91 (02):168–186
5 Torbenson M. Review of the clinicopathologic features of fibrolamellar carcinoma. Adv Anat Pathol 2007;14(03):217–223
6 Saab S, Yao F. Fibrolamellar hepatocellular carcinoma. Case reports and a review of the literature. Dig Dis Sci 1996;41(10): 1981–1985
7 McLarney JK, Rucker PT, Bender GN, Goodman ZD, Kashitani N, Ros PR. Fibrolamellar carcinoma of the liver: radiologic-pathologic correlation. Radiographics 1999;19(02):453–471
8 Friedman AC, Lichtenstein JE, Goodman Z, Fishman EK, Siegelman SS, Dachman AH. Fibrolamellar hepatocellular carcinoma. Radiology 1985;157(03):583–587
9 Brandt DJ, Johnson CD, Stephens DH, Weiland LH. Imaging of fibrolamellar hepatocellular carcinoma. AJR Am J Roentgenol 1988;151(02):295–299
10 Quillin SP, Atilla S, Brown JJ, Borrello JA, Yu CY, Pilgram TK. Characterization of focal hepatic masses by dynamic contrast-enhanced MR imaging: findings in 311 lesions. Magn Reson Imaging 1997;15(03):275–285
11 Oliver JH III, Baron RL. Helical biphasic contrast-enhanced CT of the liver: technique, indications, interpretation, and pitfalls. Radiology 1996;201(01):1–14
12 Vilgrain V, Fléjou JF, Arrivé L, et al. Focal nodular hyperplasia of the liver: MR imaging and pathologic correlation in 37 patients. Radiology 1992;184(03):699–703
13 Grazioli L, Federle MP, Brancatelli G, Ichikawa T, Olivetti L, Blachar A. Hepatic adenomas: imaging and pathologic findings. Radiographics 2001;21(04):877–892, discussion 892–894
14 Winston CB, Schwartz LH, Fong Y, Blumgart LH, Panicek DM. Hepatocellular carcinoma: MR imaging findings in cirrhotic livers and noncirrhotic livers. Radiology 1999;210(01):75–79
15 Shriki JE, Seyal AR, Dighe MK, et al. CT of atypical and uncommon presentations of hepatocellular carcinoma. Am J Roentgenol 2015;205(04):W411-23

 © 2022. Indian Society of Gastrointestinal and Abdominal Radiology. All rights reserved.