



Impact of a Retained Instrument on Treatment Outcome: A Systematic Review

Lakshmi Nidhi Rao¹ Sembaga Lakshmi Thirunarayanan¹ Aditya Shetty¹

¹Department of Conservative Dentistry and Endodontics, ABSMIDS, Nitte (Deemed to be University), Mangalore, Karnataka, India

Address for correspondence Lakshmi Nidhi Rao, MDS, Department of Conservative Dentistry and Endodontics, ABSMIDS, Nitte (Deemed to be University), Mangalore 575018, Karnataka, India (e-mail: dimpirao@rediffmail.com).

J Health Allied Sci^{NU} 2023;13:168–171.

Abstract

Instrument separation during endodontic therapy is a frequent accident with rotary instruments being more likely to separate than manual ones. There are various treatment options when the instrument separates in a canal depending on the location, complexity of the canal anatomy, and the operators' ability. The success of the tooth that has a retained fragment of instrument in the canal has been assessed in various studies but no clear conclusion has been drawn. The goal of this systematic review is to answer as many questions as possible. Does the retention of a separated instrument, compared with no retained separated instrument, result in a worse clinical outcome in adult patients who have received nonsurgical root canal treatment?

Materials and Methodology The search was conducted with the boolean terms in various database following the PRISMA guidelines. The inclusion and exclusion criteria were set for the inclusion of the study for the systematic review.

Results Out of the 330 articles that were obtained, 28 were duplicates. After screening for eligibility, only 7 articles were retrieved for full text. When inclusion and exclusion criteria were applied, none of the studies could be included.

Conclusion There is still a lack of consensus on the treatment option for a separated instrument and there is no clear evidence to suggest whether the prognosis of the tooth with retained instrument is reduced or not.

Keywords

- ▶ separated instruments
- ▶ outcome assessment
- ▶ endodontics
- ▶ systematic review
- ▶ retained instrument

Introduction

Successful root canal treatment is determined on proper root canal shaping, disinfection, and three-dimensional obturation. Practically, at any stage of treatment, practitioners in the field of endodontics may meet a range of procedural errors and roadblocks to ordinarily routine therapy.¹ One of the procedural errors include intracanal instrument fracture. Endodontic files, Gates Glidden burs, lateral or finger spreaders, and paste fillers are examples of fractured root canal instruments. They can be constructed of nickel-titanium (NiTi), stainless steel, or carbon steel. The canal curvature, anatomic differences, practitioner expertise, patient partici-

pation, frequency of usage, torque, and rotation speed are variables that contribute to rotary file breaking.²

NiTi alloys are shape memory alloys due to their excellent biocompatibility and corrosion resistance they are used in varied aspects of dentistry.³ Because of their super-elasticity, shape memory effect, and corrosion resistance, the alloy has a wide range of dental, medicinal, and commercial uses.⁴ Sometimes they fail due to cyclic flexural fatigue, torsional failure, or a combination of both and have been categorized accordingly.⁵ The fracture rate among discarded rotary NiTi files after clinical usage was found to be between 0.4 and 3.7%. Although there is a perspective that rotary NiTi instruments can fracture without warning, recent research

article published online
August 8, 2022

DOI <https://doi.org/10.1055/s-0042-1753492>.
ISSN 2582-4287.

© 2022. The Author(s).

This is an open access article published by Thieme under the terms of the Creative Commons Attribution License, permitting unrestricted use, distribution, and reproduction so long as the original work is properly cited. (<https://creativecommons.org/licenses/by/4.0/>)

Thieme Medical and Scientific Publishers Pvt. Ltd., A-12, 2nd Floor, Sector 2, Noida-201301 UP, India

suggests that fracture is caused by several factors, the most important of which appears to be the clinician's conscious decision to use the instruments for a certain number of times or until defects (unwinding, torsional fracture, or flexural fracture) became apparent, whereas stainless steel file fracture is preceded by instrument distortion, which serves as a warning of impending fracturing.⁶ However without magnification, the distortion of rotational NiTi devices is generally undetectable.⁷⁻⁹

There have been various studies in the past that have assessed the outcome of root canal-treated tooth with a separated instrument in the canal. The success rate varies from 67% to a 100% according to Engstrom et al in 1964 and Engstrom and Lundberg in 1965. The success rates were reduced if the tooth had necrotic pulp at the beginning of the treatment as separated instrument hampers the ability to disinfect the canal.^{10,11}

The purpose of this review is to assess the impact of a retained instrument on treatment outcome over the past 10 years and the PICO question was framed as in adult patients who have had nonsurgical root canal treatment. Does the retention of a separated instrument, compared with no retained separated instrument, result in a poorer clinical outcome?

Materials and Methodology

Online databases such as PubMed, Wiley Online Library, SAGE journals, Cochrane library were used for boolean search with MeSH terms. Search Strategy was developed to identify articles related to retained instrument fragments.

Search strategy

Broken instrument OR fractured instrument OR separated instrument AND ("Endodontics" [MeSH] OR "Root Canal Filling Materials" [MeSH] OR "Dental Pulp Test" [MeSH] OR "Dental Pulp Diseases" [MeSH] OR "Periapical Abscess" [MeSH] OR endodontics [Text Word] OR root canal filling materials [Text Word] OR dental pulp test [Text Word] OR dental pulp diseases [Text Word] OR periapical abscess [Text Word] OR apicoectomy [Text Word] OR pulpectomy [Text Word] OR pulpotomy [Text Word] OR root canal therapy [Text Word] OR dental pulp devitalization [Text Word] OR root canal obturation [Text Word] OR root canal preparation [Text Word] OR retrograde obturation [Text Word] NOT (("Dental Implantation, Endosseous, Endodontic" [MeSH] OR "Dental Pulp Capping" [MeSH] OR "Tooth Replantation" [MeSH]) NOT ("Apicoectomy" [MeSH] OR "Pulpectomy" [MeSH] OR "Pulpotomy" [MeSH] OR "Root Canal Therapy" [MeSH])) NOT ("animals" [MeSH: noexp] NOT humans [MeSH]).

A thorough search was conducted to find all clinical papers that documented postoperative healing following endodontic instrument separation. The results obtained were transferred to the citation manager and duplicates were removed.

INCLUSION CRITERIA: Non-contributory medical history, mature teeth with radiographic evidence of separated instruments, follow-up of at least 1 year, outcome assess-

Table 1 Reason for exclusion of studies

Author	Reason for exclusion
Tordai et al ¹²	Retrospective study analyzing the effect of ultrasonics on instrument removal: not relevant
Farid et al ¹³	Technique commonly associated with instrument separation: not relevant
Shahabinejad et al ¹⁴	In vitro study
Madarati et al ¹⁵	In vitro study
Mohammadi et al ¹⁶	Not within the past 10 years
Cunha et al ¹⁷	Prospective clinical study
Tygesen et al ¹⁸	Not within the past 10 years

ment based on clearly defined criteria, case-control study, studies in the past 10 years.

EXCLUSION CRITERIA: No results in terms of healing, no specified observational period, follow-up less than a year, no specific criteria for evaluating outcome, not a case-control study, studies older than 10 years.

Results

The PRISMA guidelines were followed and the PRISMA flow chart is listed below. A total of 330 articles were obtained from the initial search. After removal of duplicates, 302 articles were identified. Upon screening by reading the title, seven full-text articles were retrieved. However, on evaluating the full-text articles for inclusion, none of the article met the inclusion and exclusion criteria. The reasons for the rejection of the seven full-text articles are listed in **Table 1** (**Fig. 1**).

Discussion

Clinicians may be misled by the false notion that endodontic errors, such as broken tools, perforations, and overfilling, are involved directly in endodontic failures. Although not all endodontic errors result in a poor prognosis, every mistake that affects microbial control raises the likelihood of failure. One of the most unpleasant situations in endodontic therapy is separation of root canal tools, particularly if the tooth is non-vital and the fragment cannot be extracted. Unless a concurrent infection is present, the procedure error does not immediately impact the prognosis in the majority of instances.¹⁹ As a result, it is critical to evaluate the influence of a retained broken instrument on prognosis to compare it to the danger of injury during removal. The therapeutic importance of retained fractured tools has been a point of contention among researchers.

For the management of broken tools in root canals, the literature suggests four treatment strategies:

Allowing the detached instrument to remain in the canal while treating the rest of the canal.

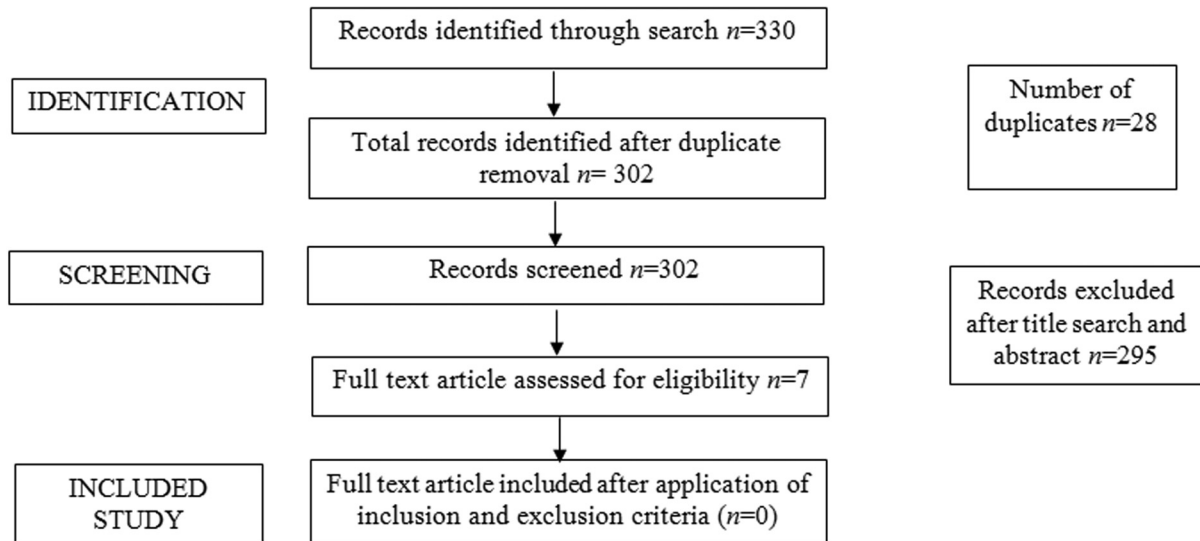


Fig. 1 PRISMA flow chart for search strategy.

The detached component is bypassed, and the canal is treated.

The detached portion must be retrieved and the canal must be treated.

Surgical procedure for retrieving the detached component, followed by appropriate therapy.⁶

The present systematic review has taken into consideration only the past 10 years as the last systematic review on this topic was conducted in 2010 by Panitvisaiet. It was concluded that there was no effect of retention of instrument on the canal to the outcome of the root canal treatment. However, the systematic review and meta-analysis took into consideration only two studies conducted by Crump and Natkin in 1970 and Spili et al in 2006. They are 36 years apart and the endodontic treatment protocols have evolved over those years. The separated instruments were predominantly stainless steel in 1970, whereas it was both stainless steel and Ni Ti in 2006. Irrigation protocols have changed over the years, which are the main aspects of disinfection of the canal.²⁰ Hence, it was decided to keep a time frame of 10 years to assess the effect of treatment outcome in cases of retained separated instruments in the canal.

Evidence from the past 10 years did not have any case-control studies that can only be the highest form of evidence in case of instrument separation. Case reports with over 2 years of follow-ups have been published over the past decade. Clear conclusions cannot be drawn from case reports or case serious as it is difficult to compare due to lack of standardization.²¹

Various instrument retrieval systems have been introduced but they involve the sacrifice of some amount of radicular dentin, which has shown to weaken the tooth structure. At present, there is a lack of consensus on the treatment option of the separated instrument in the canal.^{20,22}

Conclusion

Despite the fact that endodontic treatments are rather an intensive and demanding technique, especially in complicated anatomies, they have a very high success rate. Lack of awareness of the anatomy and also iatrogenic mistakes particularly during instrumentation, might lead to errors during or after a root canal procedure. While some of these issues may be foreseen, many others are impossible to predict. Short-term endodontic failures are most commonly caused by recurrent infection, and a fractured tool can be a source of reinfection or chronic infection. Within the limitation of this systematic review, it can be concluded that there are not enough evidence to draw a conclusion on the effect of retained instrument in the root canal system. Future research should be directed in answer if they have any effect on the outcome of a root canal treatment.

Conflict of Interest

None declared.

References

- 1 Torabinejad M, Lemon RR. Procedural accidents. In: Walton R, Torabinejad M, eds. Principles and practice of endodontics. Philadelphia: W.B. Saunders Company; 2002:310-330
- 2 Rambabu T. Management of fractured endodontic instruments in root canal: a review. J Sci Dent. 2014;4(02):40-48
- 3 Serene TP, Adams JD, Saxena A. Nickel-titanium instruments. Applications in endodontics. St. Louis, MO: Ishiyaku EuroAmerica, Inc.; 1995
- 4 Otsuka K, Wayman CM. Shape Memory Alloys. Cambridge: Cambridge University Press; 1998
- 5 Sattapan B, Nervo GJ, Palamara JEA, Messer HH. Defects in rotary nickel-titanium files after clinical use. J Endod 2000;26(03): 161-165
- 6 Simon S, Machtou P, Tomson P, Adams N, Lumley P. Influence of fractured instruments on the success rate of endodontic treatment. Dent Update 2008;35(03):172-174, 176, 178-179

- 7 Gabel WP, Hoen M, Steiman HR, Pink FE, Dietz R. Effect of rotational speed on nickel-titanium file distortion. *J Endod* 1999;25(11):752-754
- 8 Yared GM, Bou Dagher FE, Machtou P. Cyclic fatigue of ProFile rotary instruments after clinical use. *Int Endod J* 2000;33(03):204-207
- 9 Parashos P, Gordon I, Messer HH. Factors influencing defects of rotary nickel-titanium endodontic instruments after clinical use. *J Endod* 2004;30(10):722-725
- 10 Engström B, Hård L, Segerstad AF, Ramström G, Frostell G. Correlation of positive cultures with the prognosis for root canal treatment. *Odontol Revy* 1964;15:257-270
- 11 Engström B, Lundberg M. The correlation between positive culture and the prognosis of root canal therapy after pulpectomy. *Odontol Revy* 1965;16(03):193-203
- 12 Tordai B, Schreindorfer K, Lempel E, Krajczár K. Factors affecting ultrasonic removal of separated endodontic instruments: A retrospective clinical study. *Quintessence Int* 2018;49(04):257-266
- 13 Farid H, Khan FR, Rahman M. ProTaper rotary instrument fracture during root canal preparation: a comparison between rotary and hybrid techniques. *Oral Health Dent Manag* 2013;12(01):50-55
- 14 Shahabinejad H, Ghassemi A, Pishbin L, Shahravan A. Success of ultrasonic technique in removing fractured rotary nickel-titanium endodontic instruments from root canals and its effect on the required force for root fracture. *J Endod* 2013;39(06):824-828
- 15 Madarati AA, Qualtrough AJ, Watts DC. Effect of retained fractured instruments on tooth resistance to vertical fracture with or without attempt at removal. *Int Endod J* 2010;43(11):1047-1053
- 16 Mohammadi Z, Khademi AA. Effect of a separated rotary instrument on bacterial penetration of obturated root canals. *J Clin Dent* 2006;17(05):131-133
- 17 Cunha RS, Junaid A, Ensinas P, Nudera W, Bueno CE. Assessment of the separation incidence of reciprocating WaveOne files: a prospective clinical study. *J Endod* 2014;40(07):922-924
- 18 Tygesen YA, Steiman HR, Ciavarrro C. Comparison of distortion and separation utilizing profile and Pow-R nickel-titanium rotary files. *J Endod* 2001;27(12):762-764
- 19 Siqueira JF Jr. Aetiology of root canal treatment failure: why well-treated teeth can fail. *Int Endod J* 2001;34(01):1-10
- 20 Vouzara T, el Chares M, Lyroudia K. Separated instrument in endodontics: frequency, treatment and prognosis. *Balkan Journal of Dental Medicine*. 2018;22(03):123-132
- 21 Murad M, Murray C. Impact of retained separated endodontic instruments during root canal treatment on clinical outcomes remains uncertain. *J Evid Based Dent Pract* 2011;11(02):87-88
- 22 Miccoli G, Seracchiani M, Zanza A, Giudice AD, Testarelli L. Possible Complications of Endodontic Treatments. *J Contemp Dent Pract* 2020;21(05):473-474