

Evaluation and Management of Indeterminate Pulmonary Nodules on Chest Computed Tomography in Asymptomatic Subjects: The Principles of Nodule Guidelines

Ju G. Nam, MD, PhD¹ Jin Mo Goo, MD, PhD^{1,2,3}

¹ Department of Radiology, Seoul National University Hospital and College of Medicine, Seoul, Republic of Korea

² Institute of Radiation Medicine, Seoul National University Medical Research Center, Seoul, Republic of Korea

³ Cancer Research Institute, Seoul National University, Seoul, Republic of Korea

Address for correspondence Jin Mo Goo, MD, PhD, Department of Radiology and Institute of Radiation Medicine, Seoul National University College of Medicine, 101 Daehak-ro, Jongno-gu, Seoul 03080, Korea (e-mail: jmgoo@snu.ac.kr).

Semin Respir Crit Care Med 2022;43:851–861.

Abstract

With the rapidly increasing number of chest computed tomography (CT) examinations, the question of how to manage lung nodules found in asymptomatic patients has become increasingly important. Several nodule management guidelines have been developed that can be applied to incidentally found lung nodules (the Fleischner Society guideline), nodules found during lung cancer screening (International Early Lung Cancer Action Program protocol [I-ELCAP] and Lung CT Screening Reporting and Data System [Lung-RADS]), or both (American College of Chest Physicians guideline [ACCP], British Thoracic Society guideline [BTS], and National Comprehensive Cancer Network guideline [NCCN]). As the radiologic nodule type (solid, part-solid, and pure ground glass) and size are significant predictors of a nodule's nature, most guidelines categorize nodules in terms of these characteristics. Various methods exist for measuring the size of nodules, and the method recommended in each guideline should be followed. The diameter can be manually measured as a single maximal diameter or as an average of two-dimensional diameters, and software can be used to obtain volumetric measurements. It is important to properly evaluate and measure nodules and familiarize ourselves with the relevant guidelines to appropriately utilize medical resources and minimize unnecessary radiation exposure to patients.

Keywords

- ▶ lung nodule
- ▶ lung cancer screening
- ▶ lung nodule management
- ▶ CT

Lung nodules are undoubtedly the most common presentation of lung cancer. With the substantial increase in number of chest computed tomography (CT) scans being performed for various clinical indications, including lung cancer screening, advances in CT technology have enabled the detection of small nodules. As a result, physicians are encountering many cases of incidental small lung nodules, and the management of these nodules has become an important issue in terms of

the efficient use of health care resources and reduction of unnecessary radiation exposure.

Fortunately, data have emerged from various large-scale trials, including the National Lung Screening Trial (NLST), Dutch-Belgian Randomized Lung Cancer CT Screening Trial (NELSON), International Early Lung Cancer Action Program (I-ELCAP), Pan-Canadian Early Detection of Lung Cancer Study (PanCan), and British Columbia Cancer Agency

published online
July 8, 2022

Issue Theme Chest Imaging; Guest
Editors: Martine Remy-Jardin, MD, PhD,
Ann N.C. Leung, MD, and David A. Lynch,
MB BCH

© 2022. Thieme. All rights reserved.
Thieme Medical Publishers, Inc.,
333 Seventh Avenue, 18th Floor,
New York, NY 10001, USA

DOI <https://doi.org/10.1055/s-0042-1753474>.
ISSN 1069-3424.

(BCCA) cancer screening trials,^{1–4} making it feasible to establish evidence-based management guidelines for lung nodules. Various guidelines have been proposed by different organizations, including the Fleischner Society guideline,⁵ the I-ELCAP protocol,⁶ the Lung CT Screening Reporting and Data System (Lung-RADS),⁷ American College of Chest Physicians (ACCP) guideline,⁸ the British Thoracic Society (BTS) guideline,⁹ and the National Comprehensive Cancer Network (NCCN) guideline.¹⁰ It is important for clinicians to be familiar with these guidelines and understand their underlying rationale.

In this article, we introduce the current guidelines and discuss their recommended evaluation and management plan for lung nodules found on chest CT of asymptomatic, adult patients. It is important to keep in mind that the guidelines apply specifically to nodules found incidentally or during lung cancer screening, and thus are inappropriate for patients who have respiratory symptoms, are immunocompromised, are at risk for infection or metastases, or are children.

Evaluation of Lung Nodules

On chest CT, a nodule is defined as a rounded opacity, well or poorly defined, measuring up to 3 cm in diameter.¹¹ To optimally evaluate lung nodules, CT scans should be reconstructed with contiguous thin sections (≤ 1.5 mm in thickness) and include off-axis reconstructions (coronal and sagittal).^{5,12,13} Nodules are better evaluated and measured by using a lung window setting and a sharp filter, as nodules could be rendered partially invisible when viewed using the mediastinal window setting.^{14,15} Most guidelines recommend using the averaged bidimensional diameter for management purposes. To reduce interscan variability, it is recommended to use similar CT parameters and reconstruction techniques during follow-up examinations, including dose reduction techniques, section thickness, and the reconstruction filter. The descriptions of nodule evaluation and management presented in this study are focused on indeterminate nodules.

Pretest Lung Cancer Risk Estimation

Estimation of the risk of lung cancer for any individual is important to select high-risk individuals eligible for lung cancer screening and to predict the probability of malignancy of incidentally detected lung nodules.

The two most important factors associated with an increased risk of developing lung cancer are age and smoking history. Most patients diagnosed with lung cancer are 65 years old or older in the United States, with the average age at diagnosis being 70 years. More than 80% of lung cancer cases in Western countries are attributable to smoking. Therefore, the U.S. Preventive Services Task Force recommends CT screening in adults aged 50 to 80 years who have a 20 pack-year smoking history and currently smoke or have quit within the past 15 years.¹⁶

In addition to age and smoking history, sex, race/ethnicity, personal and family history of cancer, and history of emphysema or chronic obstructive pulmonary disease are used in numerous risk prediction models. The PLCO_{M2012} risk prediction model, which was derived from the Prostate, Lung, Colorectal, and Ovarian Cancer (PLCO) study, estimates 6-year lung cancer risk.¹⁷ At a threshold of $\geq 1.51\%$, PLCO_{M2012} showed better sensitivity, specificity, and positive predictive value for lung cancer detection than the NLST criteria.¹⁸ The Liverpool Lung Project model (LLPv2) was used in the United Kingdom Lung Cancer Screening Trial, and individuals with a 5-year lung cancer risk of $\geq 5\%$ were eligible for screening.¹⁹

Nodule Type Based on Consistency

Lung nodules are categorized as solid or subsolid according to the presence of ground-glass components; solid nodules are of homogeneous soft-tissue attenuation, while subsolid nodules contain a component of ground-glass opacity. Ground-glass opacity refers to an area of hazy increased attenuation in the lung that does not obliterate the underlying bronchial and vascular margins.¹¹ Subsolid nodules are subdivided into part-solid nodules and pure ground-glass nodules (GGNs). A part-solid nodule consists of both ground-glass and solid attenuation, while a pure GGN only contains a ground-glass component. Examples are presented in ►Fig. 1.

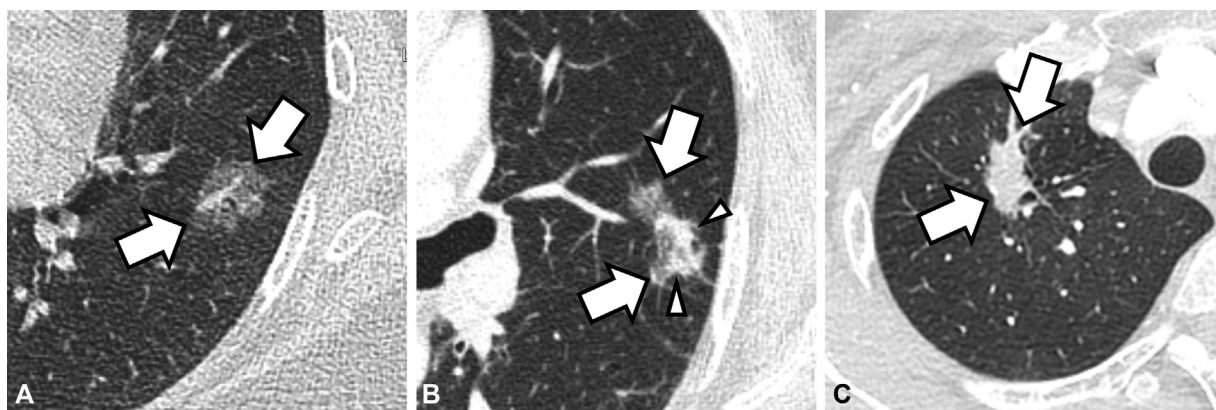


Fig. 1 Examples of lung nodules with varying morphology. (A) A pure ground-glass nodule (arrow) contains only a ground-glass component, which refers to hazy increased attenuation in the lung that does not obliterate the bronchial or vascular margins. (B) A part-solid nodule (arrow) consists of both ground-glass and solid (arrowhead) components. (C) A solid nodule (arrow) does not contain a ground-glass component.

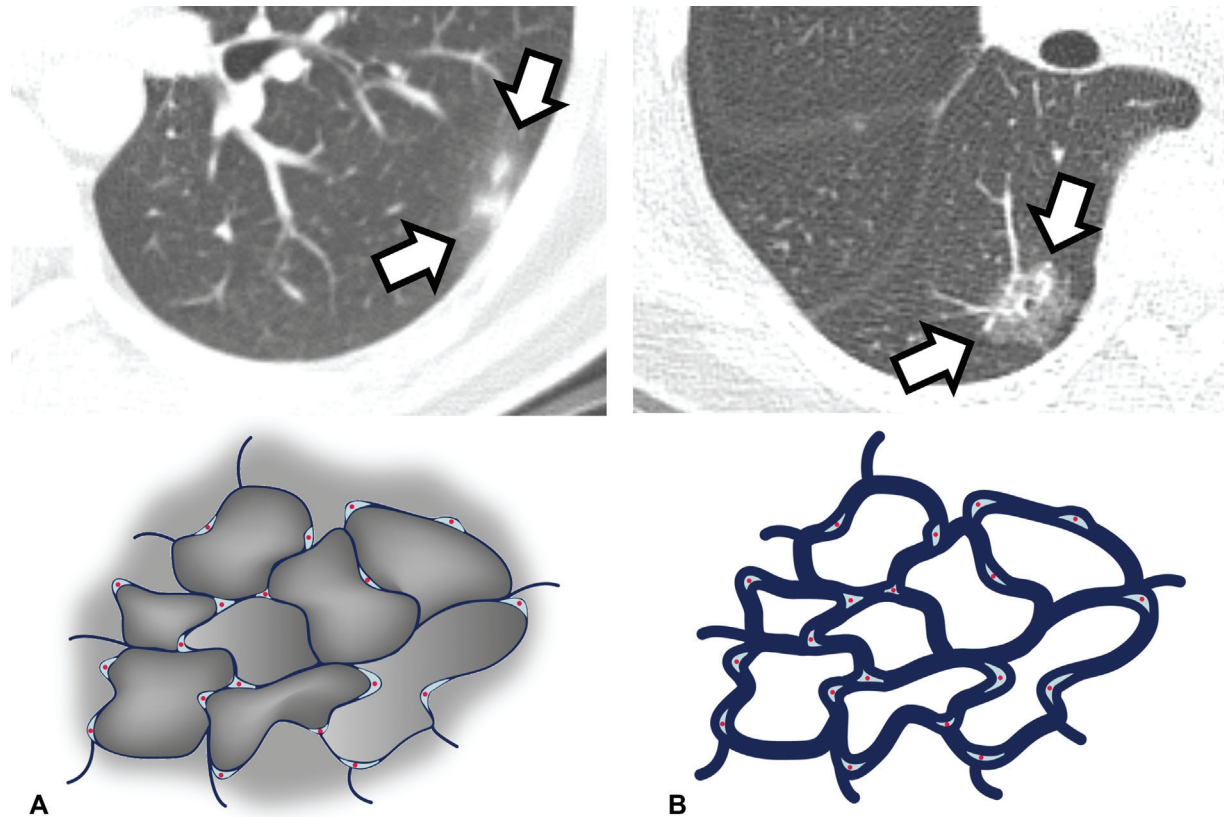


Fig. 2 Examples of transient and persistent part-solid nodules. (A) Transient part solid nodules (arrow) tend to have ill-defined borders because these nodules usually represent air-space filling diseases. As inflammation or hemorrhage (gray shades in the diagram) spreads into adjacent air-space through a collateral pathway, resulting in ill-defined borders. Additionally, detection of the nodule at follow-up, blood eosinophilia, lesion multiplicity, and a large solid portion have been reported to be associated with transient part-solid nodules. (B) In comparison, persistent part-solid nodules (arrow) typically represent invasive adenocarcinoma or minimally invasive adenocarcinoma in histopathologic analysis. These nodules are known to have relatively well-defined borders because tumor cells grow along the alveolar wall (lepidic growth pattern), resulting in the interstitial thickening as indicated in the diagram.

The nodule type based on consistency is a major feature indicating the nature of nodules. Most incidentally found subsolid nodules are transient, but persistent subsolid nodules have an approximately 30% probability of malignancy, higher than that of solid nodules.^{20–22} In a study by Lee et al, approximately 70% of part-solid nodules were transient.²³ Young patient age, detection of the nodule at follow-up, blood eosinophilia, lesion multiplicity, a large solid portion, and an ill-defined border were reported to be independent predictors of transient subsolid nodules (►Fig. 2).²³ However, lung cancers that present as subsolid nodules show a better prognosis than those presenting as solid nodules.²⁴ The solid component of persistent subsolid nodules represents the invasive component of the tumor, and therefore pure GGNs or part-solid nodules with a small solid component (<6 mm) are known to have an indolent clinical course, representing atypical adenomatous hyperplasia, adenocarcinoma in situ, or minimally invasive adenocarcinoma on histopathologic analysis.^{25–27}

Morphologic Assessment of Nodules

The presence of internal, shape, or border characteristics may be helpful in determining whether a nodule is benign or malignant and can help guide management. However, most

small nodules lack these distinguishing morphologic characteristics.

Nodules with benign features consisting of internal areas of fat attenuation or complete, central, popcorn, or concentric ring-like calcification do not require further follow-up (►Fig. 3). A small nodule of less than 5 mm that uniformly shows higher attenuation than the ribs can be considered to be calcified.²⁸ Air-bronchograms, cavitation, or pseudocavitation (bubble-like lucency) are seen more commonly in lung cancers than in benign nodules (►Fig. 4A).^{29,30}

A polygonal (concave surfaces on all sides) or flat (ratio of axial diameter/cranial-caudal diameter >1.78) shape indicates benignity.³¹ Meanwhile, a spiculated margin usually indicates malignancy, and an irregular or lobulated contour also raises suspicion of malignancy (►Fig. 4B).

Nodule Measurement: Manual Diameter Measurement and the Volumetric Approach

Nodule size is strongly associated with the risk of malignancy, and therefore is a dominant factor in determining the management plan. There are two main methods of measuring the size of nodules: manual diameter measurement and the volumetric approach. Currently, robustly validated volumetric nodule measurement software has not been widely

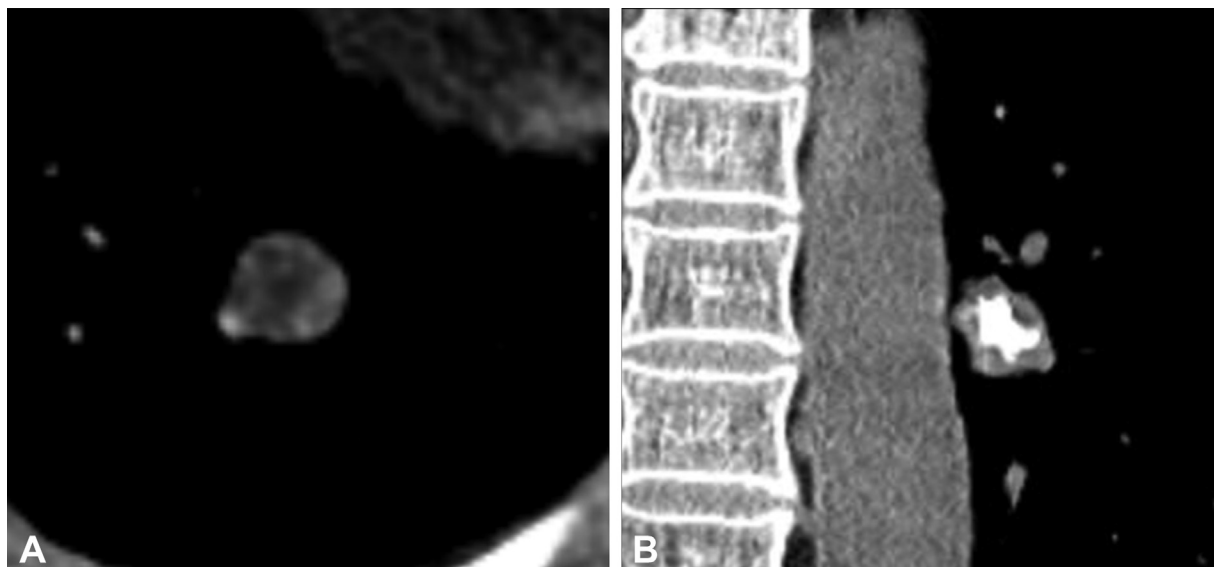


Fig. 3 Nodules with benign features. (A) A fat-containing nodule (mean attenuation in the fatty portion was about 90 HU). (B) A nodule with central calcification. Complete, central, popcorn, and concentric ring calcifications are suggestive of a benign nature of the nodule.

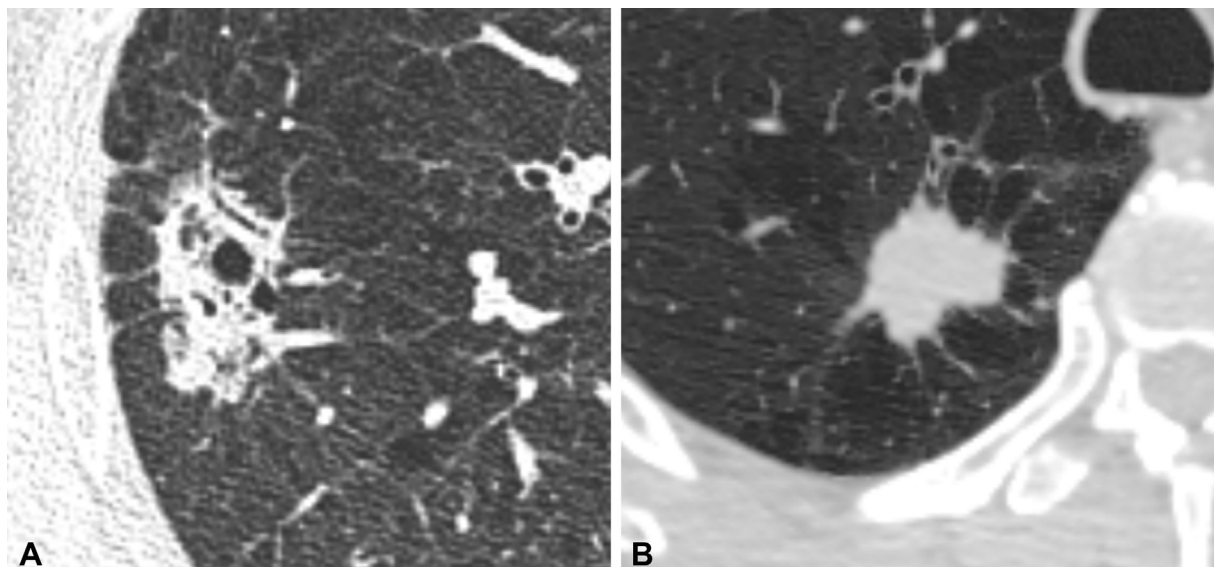


Fig. 4 Examples of nodules with suspected findings of malignancy. (A) A nodule with a bubble-like lucency and (B) another nodule with a spiculated margin. Both nodules were confirmed to be lung adenocarcinoma on histopathologic analysis after surgical resection.

adopted. However, volumetric measurements are expected to play an expanding role in the future, and most recently published guidelines provide reference values for both manually measured diameters and the volumetric approach.

When manually measuring the diameter of nodules, one should follow the method each guideline suggests. Most guidelines, including the Fleischner Society, I-ELCAP, Lung-RADS, NCCN, and ACCP guidelines, recommend using the average diameter which can be calculated by the average of the maximal long-axis diameter measurements (in transverse, coronal, or sagittal reconstructed images) and its perpendicular maximal short-axis measurement. Instead, the BTS guideline uses the maximal diameter. For part-solid nodules, the diameter of both the whole nodule and its solid component should be measured and reported (► Fig. 5).

The volumetric approach, which utilizes automatic or semiautomatic software packages, is expected to more accurately represent a nodule's size and is associated with lower interreader variability. However, there is significant variability among different software packages (► Fig. 6).^{32–34} Different volumetry software should not be used interchangeably to evaluate nodules on serial follow-up scans. The use of thick sections, intravenous contrast, or a soft kernel may lead to overestimation of nodule volume.^{35–37} However, several studies have reported that differences in the reconstruction technique, CT manufacturer, and radiation dose do not increase volumetric measurement variability beyond the expected level of 25%.^{38–40} When a volumetric assessment is used, the volume doubling time has been regarded as a surrogate marker of the probability of malignancy. A volume

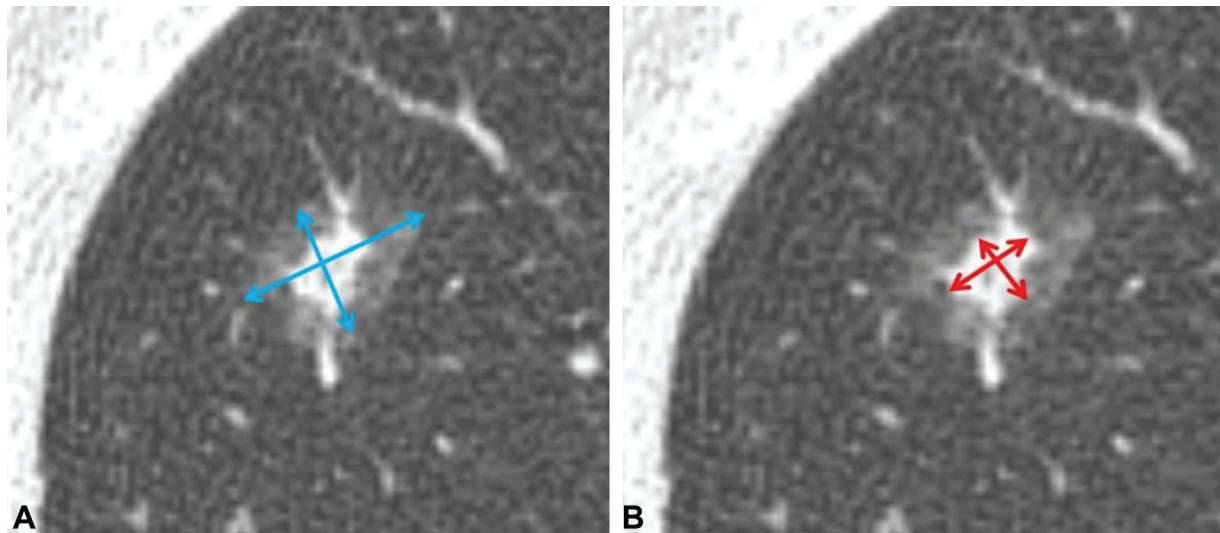


Fig. 5 For part-solid nodules, the diameters of both (A) the whole nodule and (B) the solid component should be measured independently (arrows).

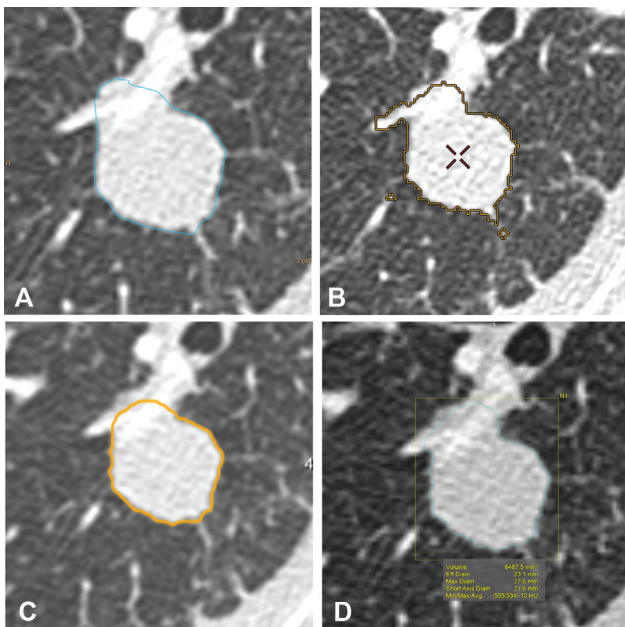


Fig. 6 Measurement of the nodule size using the volumetric approach with various software. The volume of the nodule was measured variably as 8,683, 6,836, 5,829, and 6,488 mm³, when using (A) IntelliSpace Portal (Philips Healthcare, Best, the Netherlands), (B) Advantage workstation (GE Healthcare, Milwaukee, WI), (C) Veolity (MeVis, Berlin, Germany), and (D) Vitrea (Canon Medical Systems, Otawara-shi, Japan), respectively.

doubling time of less than 400 days is the most frequently used threshold that triggers a further workup for indeterminate nodules.³²

Variability in Nodule Evaluation

Inconsistencies in nodule classification and measurement are a major hurdle in lung nodule evaluation. The morphology and size of nodules may be evaluated differently among readers or inconsistently even by the same reader, and this could affect the management plan for patients. Van Riel et al reported that when eight radiologists evaluated nodules

included in the NELSON cohort, the morphologic categorization of lung nodules showed moderate inter- and intraobserver agreement (mean κ : 0.51 and 0.57, each).⁴¹ Discordant nodule classifications were found in 36.4% (1,630 of 4,480) of reading pairs, and two-thirds of these discordant pairs (1,061 of 1,630) would potentially lead to different management plans.⁴¹ The size of nodules also varies between measurements. Revel et al reported that when nodules were manually measured by three radiologists using the single maximal diameter, intrareader agreement (size variability) ranged from 1.32 to 1.70 mm, and the 95% limits of agreement for the interreader difference was 1.73 mm for lung nodules 3 to 18 mm in size.⁴² These results can be explained by the fact that the typical pixel size of chest CT is approximately 0.6 to 0.8 mm, and, generally, at least two pixels are required to recognize a change. In this context, most guidelines consider a minor measured size difference between two examinations to be clinically insignificant. The Lung-RADS guideline defines growth based on an increase in size of greater than 1.5 mm, while the Fleischner Society guideline requires a measured change of 2 mm. The I-ELCAP and NCCN guidelines also disregard minor size differences depending on the nodule size. When the volumetric approach was used, the volume of the nodule measured on two CT scans taken on the same day by the same software showed approximately 25% interscan variability.^{43,44} The BTS guideline neglects interscan volume changes of less than 25%.

Guidelines for Nodule Management

There are several guidelines for lung nodule management published by various societies, including the Fleischner Society, I-ELCAP, Lung-RADS, ACCP, BTS, and NCCN guidelines.^{5–10} These guidelines can be applied to individuals in several different settings: (1) those who were eligible for and received chest CT for lung cancer screening (I-ELCAP, Lung-RADS), (2) those whose nodules were incidentally found (Fleischner Society guideline), or (3) both (1) and (2) (ACCP,

BTS, or NCCN guidelines). The basic difference between the protocols of incidental nodule and screening is that no further workup or follow-up is required for incidental nodules smaller than a minimum threshold, while CT scans at repeated intervals are recommended in the screening setting. In this review, we briefly introduce the Fleischner Society guidelines for incidental lung nodules and Lung-RADS for lung cancer screening.

Fleischner Society Guideline for Incidental Lung Nodules

The latest guideline from the Fleischner Society was released in 2017 (► **Table 1**).⁵ The guideline suggests different follow-up plans for incidentally found lung nodules in accordance with the radiologic nodule type (solid, part-solid, or pure GGN), the number of nodules, and the patient's pretest risk. For solid nodules, no additional follow-up is recommended for low-risk patients for nodules smaller than 6 mm, while 1-year follow-up is optional for high-risk patients. Solid nodules of 6 to 8 mm in size need 6- to 12-month (if single) or 3- to 6-month (if multiple) follow-up. For patients with solid nodules larger than 8 mm, 3- to 6-month follow-up or an additional workup including positron emission tomography (PET)/CT or tissue sampling is recommended. For part-solid

nodules smaller than 6 mm, no routine CT follow-up is recommended unless there are multiple nodules which necessitate 3- to 6-month follow-up. For part-solid nodules larger than or equal to 6 mm, CT at 3 to 6 months is required. For single pure GGNs, those smaller than 6 mm require no routine follow-up, while those larger or equal to 6 mm may need CT follow-up at 6 to 12 months. The guideline recommends follow-up for nodules larger than or equal to 6 mm until 2 years for solid nodules and 5 years for subsolid nodules to confirm their stability.

Lung Computed Tomography Screening Reporting and Data System

Lung-RADS was proposed by the American College of Radiology to manage nodules detected during lung cancer screening (► **Table 2**).⁶ This guideline assumes that eligible patients who are entered into a lung cancer screening program will continue to receive annual low-dose CT scans. Lung-RADS classifies nodules into four categories according to the risk of malignancy: benign (category 2), probably benign (category 3), suspicious (category 4A), and very suspicious (category 4B or 4X). Similar to the Fleischner Society guideline, the main factors are the size and radiologic type of the nodules. Solid or part-solid nodules smaller than 6 mm and pure GGNs smaller than

Table 1 Summary of the Fleischner Society Guideline for the management of incidentally found lung nodules

Solid nodules			
	Diameter (volume)		
	<6 mm (<10 mm ³)	6–8 mm (100–250 mm ³)	>8 mm (>250 mm ³)
Single nodule			
Low risk	No follow-up	CT at 6–12 months then consider CT at 18–24 months	Consider CT at 3 months, PET/CT, or tissue sampling
High risk	Optional CT at 12 months	CT at 6–12 months then CT at 18–24 months	Consider CT at 3 months, PET/CT, or tissue sampling
Multiple nodules ^a			
Low risk	No follow-up	CT at 3–6 months then consider CT at 18–24 months	CT at 3–6 months, then consider CT at 18–24 months
High risk	Optional CT at 12 months	CT at 3–6 months then at 18–24 months	CT at 3–6 months, then at 18–24 months
Subsolid nodules			
	Diameter (volume)		
	<6 mm (<10 mm ³)	≥6–8 mm (>100 mm ³)	
Single nodule			
Pure ground-glass nodule	No follow-up	CT at 6–12 months to confirm persistence then CT every 2 years until 5 years	
Part solid nodule	No follow-up	CT at 3–6 months to confirm persistence If unchanged and solid component remains <6 mm, annual CT should be performed for 5 years	
Multiple nodules ^a	CT at 3–6 months If stable, consider CT at 2 and 4 years.	CT at 3–6 months Subsequent management based on the most suspicious nodule	

Abbreviations: CT, computed tomography; PET, positron emission tomography.

Note: Adapted from MacMahon et al.⁵

^aFor the individuals with multiple lung nodules, use the most suspicious nodule as a guide to management.

Table 2 Summary of Lung-RADS for the management of lung nodules found during lung cancer screening

Lung-RADS category	Nodule morphology and diameter (volume)	Management	Risk of malignancy
Category 0	Part or all of lungs cannot be evaluated	Additional lung cancer screening CT	N/A
Category 1	No lung nodules Nodules with specific calcifications and fat containing nodules	Continue annual screening CT at 12 months	<1%
Category 2	Perifissural nodules <10 mm Solid nodules <6 mm (<113 mm ³) Part-solid nodules <6 mm (<113 mm ³) Pure GGNs <30 mm (14137 mm ³)	Continue annual screening CT at 12 months	<1%
Category 3	Solid nodules ≥6 to 8 mm (113 to 268 mm ³) Part-solid nodules ≥6 mm (113 mm ³) with solid component <6 mm (113 mm ³) Pure GGNs ≥30 mm (14137 mm ³)	CT at 6 months	1–2%
Category 4A	Solid nodules ≥8 to <15 mm (268 to 1767 mm ³) Part-solid nodules ≥6 mm (113 mm ³) with solid component ≥6 to <8 mm (113 to 268 mm ³) Endobronchial nodules	CT at 3 months PET/CT may be used	5–15%
Category 4B	Solid nodules ≥15 mm (1767 mm ³) Part-solid nodules with solid component ≥8 (268 mm ³)	CT with contrast, PET/CT and/or tissue sampling	>15%
Category 4X	Category 3 or 4 nodules with suspected findings of malignancy, such as spiculation, GGN that doubles in 1 year, enlarged lymph nodes etc.		>15%

Abbreviations: CT, computed tomography; GGN, ground-glass nodule; Lung-RADS, Lung CT Screening Reporting and Data System; PET, positron emission tomography; .

30 mm are categorized as benign (category 2). Even though pure GGNs smaller than 30 mm can be malignant, malignant GGNs typically show indolent behavior, and therefore they are considered as category 2. Solid nodules larger than or equal to 15 mm and part-solid nodules with solid components larger than or equal to 8 mm are categorized as very suspicious (category 4B). Nodules could be up- or downcategorized during follow-up scans according to their interval change. The management plan is decided according to the nodule category. Continuation of annual screening is recommended for category-2 nodules, CT at 6 months and 3 months is recommended for category 3 and 4A nodules, respectively, and workup for malignancy, including PET/CT or tissue sampling, is recommended for category 4B or 4X nodules. The specific location of nodules also matters, such as perifissural (category 2 when smaller than 10 mm) and endobronchial nodule (category 4A). In addition, physicians may up-categorize category-3 or -4 nodules as very suspicious (category 4X) if there are additional imaging features increasing suspicion of malignancy such as a spiculated margin or lymph node enlargement.

Nodules that Do Not Require Follow-up

It could be helpful to know which nodules need to be followed-up and which nodules we may regard as clinically

insignificant. After the Fleischner Society recommended not to follow-up small nodules in low-risk patients in 2005, most guidelines developed since then have suggested a minimum threshold size for nodules, such that nodules smaller than that size could be interpreted as not requiring follow-up (► Fig. 7). For solid nodules, most guidelines usually set a threshold of 6 mm. Likewise, most guidelines adopt 6 mm as a threshold for part-solid nodules, while ACCP guideline recommend CT follow-up for all part-solid nodules. Various threshold sizes have been proposed for pure GGNs (► Fig. 7).

Malignancy Risk Estimation of Lung Nodules

In addition to the conventional nodule guidelines, which employ a categorical approach, some risk stratification methods assess the malignancy risk for individual cases.

Statistical Models

These models estimate the malignancy risk by combining clinical and imaging features known to be significant predictors of lung cancer. Well-known models include the Mayo Clinic model⁴⁵ and the Brock University model.³ Both models use logistic regression-based methods and have been validated in multiple external cohorts. When applying these

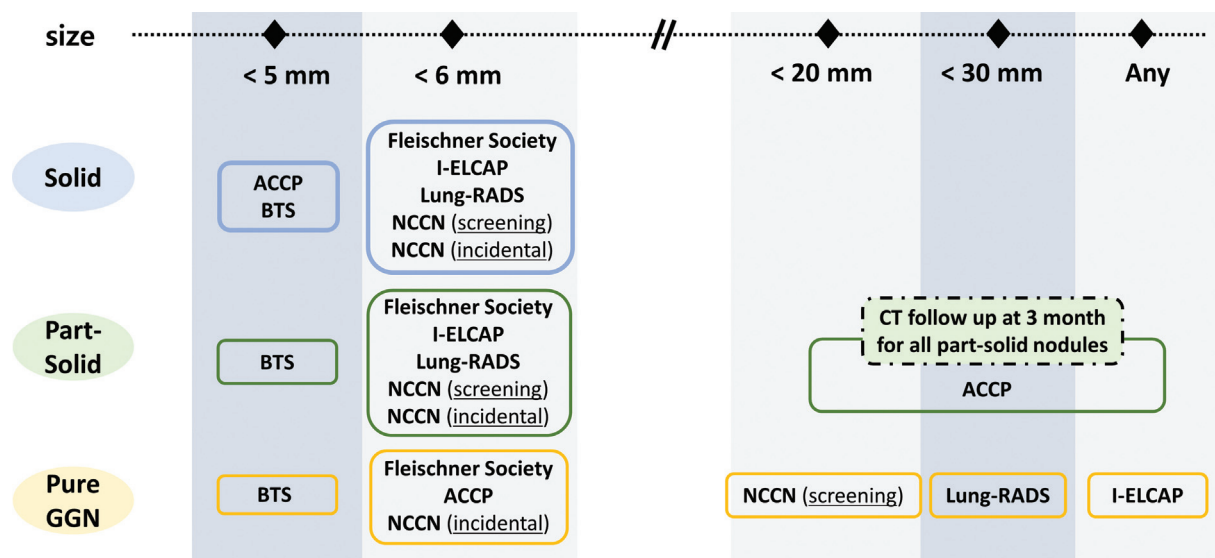


Fig. 7 Most recent nodule management guidelines suggest a minimum threshold size for nodules, such that nodules smaller than that could be interpreted as negative findings. The minimum thresholds of various guidelines are visualized according to the radiologic nodule type. ACCP, American College of Chest Physicians guideline; BTS, British Thoracic Society guideline; CT, computed tomography; I-ELCAP, International Early Lung Cancer Action Program protocol; lung-RADS, Lung CT Screening Reporting and Data System; NCCN, National Comprehensive Cancer Network guideline.

models, it is necessary to understand the population from which the models were derived.

Machine Learning Approaches

Nodule morphology is traditionally assessed and categorized visually but machine learning, including radiomics, is expected to extract extensive morphologic information. Several studies have explored the role of radiomics in the classification of indeterminate nodules.^{46,47} However, changes in CT parameters, especially reconstruction algorithms, may yield significant variability in radiomic features.

Deep learning has been applied to various chest imaging applications, and several studies have shown its potential for malignancy risk estimation. Using only image voxels, deep learning algorithms were reported to show better performance than logistic regression-based methods.^{48,49}

Additional Considerations

Although extensive studies have been performed and several guidelines have been published for lung nodule management, there are some remaining uncertainties. Among these, we will briefly discuss recent publications about juxtapleural nodules and stable subsolid nodules.

Juxtapleural Nodules

Perifissural nodules refer to fissure-attached solid nodules with a typical appearance, (i.e., a lentiform, triangular, or polygonal shape). These nodules account for approximately 20% of screening-detected pulmonary nodules and are generally regarded as benign lesions, such as intrapulmonary lymph nodes. Several publications have shown the benign nature of perifissural nodules.^{50–53} De Hoop et al reviewed 794 juxtapleural nodules out of 4,026 nodules detected in

the NELSON trial, and found out that none of them developed into lung cancer, including those who increased in size on follow-up imaging.⁵⁰ In this context, the revised Lung-RADS applies more generous criteria for perifissural nodules, with those smaller than 10 mm considered to be benign (category 2).⁷ However, in a study by Schreuder et al that evaluated the NLST data, 19% (13/70) of cancers were misclassified as a perifissural nodule at least by one of six readers, and 84% (11/13) of misclassified nodules were located in the upper lobes.⁵⁴

Although a similar nature could be expected for nodules attached to the costal, mediastinal, and diaphragmatic pleura, limited evidence has been reported in the literature. Zhu et al recently identified 943 noncalcified nodules attached to the costal pleura from 569 out of 8,730 screening participants, and found that 934 (99%) were benign, while only nine nodules (1%) were confirmed to be malignant.⁵⁵ Specifically, all juxtapleural nodules less than 10 mm in diameter with lentiform, oval, semicircular, or triangular shapes and smooth margins were benign.

Based on previous studies, juxtapleural nodules with benign features can be defined similarly to perifissural nodules, as smooth solid nodules of ≤ 10 mm in diameter with a lentiform, triangular, or polygonal shape, located on or within 10 mm of the fissure or the pleural surface, and frequently with a fine linear extension (► Fig. 8).⁵⁶ However, juxtapleurally located nodules with a spiculated border, distortion of the adjacent fissure or pleura, a location in the upper lobes, or a size of ≥ 6 mm in patients with a history of cancer need to be followed-up.

Stable Subsolid Nodules

As described earlier, persistent subsolid nodules have a considerable probability of malignancy,^{20,21} but pure GGNs

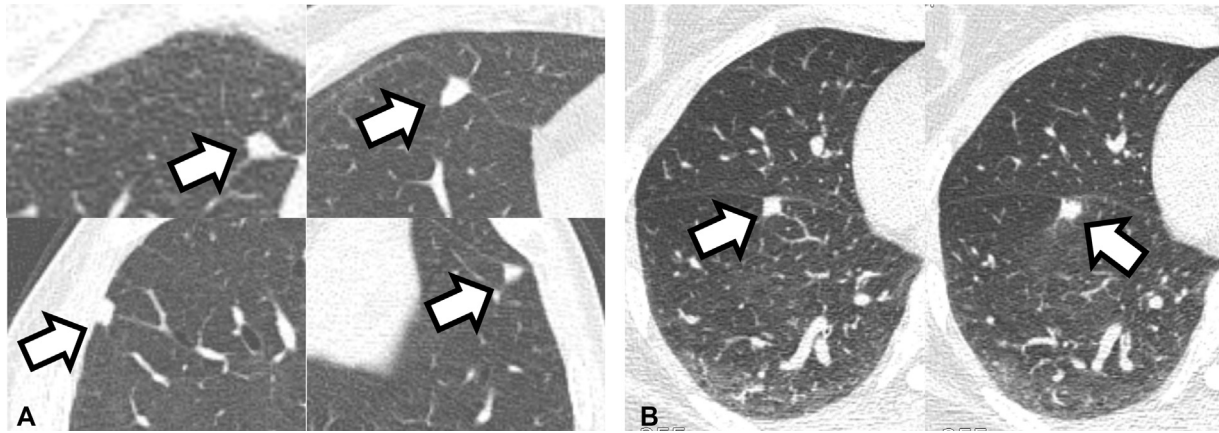


Fig. 8 Examples of juxtaleural nodules with benign features and an atypical perifissural nodule. (A) Juxtaleural nodules (arrow) with a lentiform, triangular, or polygonal shape. These nodules remained unchanged during more than 8 years of follow-up. (B) A fissure-attached nodule (arrow) that newly developed during postoperative surveillance for cervical cancer. This nodule was round shaped and had a bulging border. The nodule was confirmed to be metastasis after wedge resection.

or part-solid nodules with a solid component smaller than 6 mm are known to have an indolent clinical course.^{25,26} Therefore, most guidelines recommend no follow-up for small incidental subsolid nodules smaller than 6 mm. In addition, the Fleischner Society and BTS guidelines recommend follow-up for up to 5 years for low-risk subsolid nodules, based on publications reporting that growth of pure GGNs could be identified within 2 to 4 years in most cases.^{57–59} However, there is a lack of evidence proving whether 5-year stability is sufficient to determine conclusively that a nodule is benign and to discontinue subsequent follow-up.

Two studies investigating subsolid nodules were stable for the first 5 years but reported inconsistent results.^{60,61} Lee et al collected 208 subsolid nodules that remained stable for 5 years and reported that growth was identified in 13% (27/208) of those nodules.⁶⁰ Meanwhile, Lee et al reported that only 2% of 235 subsolid stable nodules showed growth at a median follow-up of 9 years.⁶¹ However, both studies showed no death, recurrence, or metastasis in subsolid nodules with interval growth.

Conclusion

Owing to large-scale clinical trials and various publications, many well-developed guidelines for lung nodule management have been proposed by different organizations. It is important to familiarize ourselves with these guidelines and properly manage patients to avoid wasting medical resources and subjecting patients to unnecessary radiation exposure. However, we need to properly measure nodules using the method stipulated by each guideline and apply the corresponding management algorithm appropriate for the given clinical context.

Conflict of Interest

J.G.N. received research grants from VUNO and J.M.G. received research grants from INFINITT Healthcare, Dongkook Lifescience, and LG electronics.

References

- Wiener RS, Gould MK, Woloshin S, Schwartz LM, Clark JA. What do you mean, a spot?: a qualitative analysis of patients' reactions to discussions with their physicians about pulmonary nodules *Chest* 2013;143(03):672–677
- Horeweg N, van Rosmalen J, Heuvelmans MA, et al. Lung cancer probability in patients with CT-detected pulmonary nodules: a prespecified analysis of data from the NELSON trial of low-dose CT screening. *Lancet Oncol* 2014;15(12):1332–1341
- McWilliams A, Tammemagi MC, Mayo JR, et al. Probability of cancer in pulmonary nodules detected on first screening CT. *N Engl J Med* 2013;369(10):910–919
- Henschke CI, Yip R, Yankelevitz DF, Smith JPI International Early Lung Cancer Action Program Investigators' Definition of a positive test result in computed tomography screening for lung cancer: a cohort study. *Ann Intern Med* 2013;158(04):246–252
- MacMahon H, Naidich DP, Goo JM, et al. Guidelines for management of incidental pulmonary nodules detected on CT images: from the Fleischner Society 2017. *Radiology* 2017;284(01):228–243
- Henschke CI. International Early Lung Cancer Action Program: screening protocol. Accessed February 3, 2022 at: <https://www.ielcap.org/sites/default/files/I-ELCAP-protocol.pdf>
- Lung CT. Screening Reporting & Data System (Lung-RADS) 2019. Version 1.1. Accessed February 3, 2022 at: <https://www.acr.org/Clinical-Resources/Reporting-and-Data-Systems/Lung-Rads>
- Gould MK, Donington J, Lynch WR, et al. Evaluation of individuals with pulmonary nodules: when is it lung cancer? Diagnosis and management of lung cancer, 3rd ed: American College of Chest Physicians evidence-based clinical practice guidelines. *Chest* 2013;143(5, suppl):e935–e1205
- Baldwin DR, Callister MEGuideline Development Group. The British Thoracic Society guidelines on the investigation and management of pulmonary nodules. *Thorax* 2015;70(08):794–798
- NCCN guidelines: lung cancer screening. 2020. Version 1. Accessed February 3, 2022 at: https://www.nccn.org/patients/guidelines/content/PDF/lung_screening-patient.pdf
- Hansell DM, Bankier AA, MacMahon H, McLoud TC, Müller NL, Remy J. Fleischner Society: glossary of terms for thoracic imaging. *Radiology* 2008;246(03):697–722
- Erasmus JJ, Connolly JE, McAdams HP, Roggli VL. Solitary pulmonary nodules: Part I. Morphologic evaluation for differentiation of benign and malignant lesions. *Radiographics* 2000;20(01):43–58

- 13 Gaerte SC, Meyer CA, Winer-Muram HT, Tarver RD, Conces DJ Jr. Fat-containing lesions of the chest. *Radiographics* 2002;22(Spec No):S61–S78
- 14 Matsuguma H, Oki I, Nakahara R, et al. Comparison of three measurements on computed tomography for the prediction of less invasiveness in patients with clinical stage I non-small cell lung cancer. *Ann Thorac Surg* 2013;95(06):1878–1884
- 15 Yoo R-E, Goo JM, Hwang EJ, et al. Retrospective assessment of interobserver agreement and accuracy in classifications and measurements in subsolid nodules with solid components less than 8mm: which window setting is better? *Eur Radiol* 2017;27(04):1369–1376
- 16 Krist AH, Davidson KW, Mangione CM, et al; US Preventive Services Task Force. Screening for lung cancer: US Preventive Services Task Force recommendation statement. *JAMA* 2021;325(10):962–970
- 17 Tammemägi MC, Katki HA, Hocking WG, et al. Selection criteria for lung-cancer screening. *N Engl J Med* 2013;368(08):728–736
- 18 Tammemägi MC, Church TR, Hocking WG, et al. Evaluation of the lung cancer risks at which to screen ever- and never-smokers: screening rules applied to the PLCO and NLST cohorts. *PLoS Med* 2014;11(12):e1001764
- 19 Field JK, Duffy SW, Baldwin DR, et al. The UK Lung Cancer Screening Trial: a pilot randomised controlled trial of low-dose computed tomography screening for the early detection of lung cancer. *Health Technol Assess* 2016;20(40):1–146
- 20 Kakinuma R, Noguchi M, Ashizawa K, et al. Natural history of pulmonary subsolid nodules: a prospective multicenter study. *J Thorac Oncol* 2016;11(07):1012–1028
- 21 Henschke CI, Yankelevitz DF, Mirtcheva R, McGuinness G, McCauley D, Miettinen OSELCAP Group. CT screening for lung cancer: frequency and significance of part-solid and nonsolid nodules. *AJR Am J Roentgenol* 2002;178(05):1053–1057
- 22 Oh J-Y, Kwon S-Y, Yoon H-I, et al. Clinical significance of a solitary ground-glass opacity (GGO) lesion of the lung detected by chest CT. *Lung Cancer* 2007;55(01):67–73
- 23 Lee SM, Park CM, Goo JM, et al. Transient part-solid nodules detected at screening thin-section CT for lung cancer: comparison with persistent part-solid nodules. *Radiology* 2010;255(01):242–251
- 24 Fu F, Zhang Y, Wen Z, et al. Distinct prognostic factors in patients with stage I non-small cell lung cancer with radiologic part-solid or solid lesions. *J Thorac Oncol* 2019;14(12):2133–2142
- 25 Kakinuma R, Muramatsu Y, Kusumoto M, et al. Solitary pure ground-glass nodules 5 mm or smaller: frequency of growth. *Radiology* 2015;276(03):873–882
- 26 Cohen JG, Reymond E, Lederlin M, et al. Differentiating pre- and minimally invasive from invasive adenocarcinoma using CT-features in persistent pulmonary part-solid nodules in Caucasian patients. *Eur J Radiol* 2015;84(04):738–744
- 27 Travis WD, Asamura H, Bankier AA, et al; International Association for the Study of Lung Cancer Staging and Prognostic Factors Committee and Advisory Board Members. The IASLC lung cancer staging project: proposals for coding T categories for subsolid nodules and assessment of tumor size in part-solid tumors in the forthcoming eighth edition of the TNM classification of lung cancer. *J Thorac Oncol* 2016;11(08):1204–1223
- 28 Henschke CI, Yankelevitz DF, Smith JP, Miettinen OSELCAP Group. Screening for lung cancer: the early lung cancer action approach. *Lung Cancer* 2002;35(02):143–148
- 29 Zwirewich CV, Vedal S, Miller RR, Müller NL. Solitary pulmonary nodule: high-resolution CT and radiologic-pathologic correlation. *Radiology* 1991;179(02):469–476
- 30 Lee KS, Kim Y, Han J, Ko EJ, Park C-K, Primack SL. Bronchioloalveolar carcinoma: clinical, histopathologic, and radiologic findings. *Radiographics* 1997;17(06):1345–1357
- 31 Takashima S, Sone S, Li F, et al. Small solitary pulmonary nodules (< or =1 cm) detected at population-based CT screening for lung cancer: Reliable high-resolution CT features of benign lesions. *AJR Am J Roentgenol* 2003;180(04):955–964
- 32 Devaraj A, van Ginneken B, Nair A, Baldwin D. Use of volumetry for lung nodule management: theory and practice. *Radiology* 2017;284(03):630–644
- 33 Ashraf H, de Hoop B, Shaker SB, et al. Lung nodule volumetry: segmentation algorithms within the same software package cannot be used interchangeably. *Eur Radiol* 2010;20(08):1878–1885
- 34 Zhao YR, van Ooijen PM, Dorrius MD, et al. Comparison of three software systems for semi-automatic volumetry of pulmonary nodules on baseline and follow-up CT examinations. *Acta Radiol* 2014;55(06):691–698
- 35 Petrou M, Quint LE, Nan B, Baker LH. Pulmonary nodule volumetric measurement variability as a function of CT slice thickness and nodule morphology. *AJR Am J Roentgenol* 2007;188(02):306–312
- 36 Honda O, Johkoh T, Sumikawa H, et al. Pulmonary nodules: 3D volumetric measurement with multidetector CT—effect of intravenous contrast medium. *Radiology* 2007;245(03):881–887
- 37 Christe A, Brönnimann A, Vock P. Volumetric analysis of lung nodules in computed tomography (CT): comparison of two different segmentation algorithm softwares and two different reconstruction filters on automated volume calculation. *Acta Radiol* 2014;55(01):54–61
- 38 Cohen JG, Kim H, Park SB, et al. Comparison of the effects of model-based iterative reconstruction and filtered back projection algorithms on software measurements in pulmonary subsolid nodules. *Eur Radiol* 2017;27(08):3266–3274
- 39 Kim H, Park CM, Chae H-D, Lee SM, Goo JM. Impact of radiation dose and iterative reconstruction on pulmonary nodule measurements at chest CT: a phantom study. *Diagn Interv Radiol* 2015;21(06):459–465
- 40 Ohno Y, Yaguchi A, Okazaki T, et al. Comparative evaluation of newly developed model-based and commercially available hybrid-type iterative reconstruction methods and filter back projection method in terms of accuracy of computer-aided volumetry (CADv) for low-dose CT protocols in phantom study. *Eur J Radiol* 2016;85(08):1375–1382
- 41 van Riel SJ, Sánchez CI, Bankier AA, et al. Observer variability for classification of pulmonary nodules on low-dose CT images and its effect on nodule management. *Radiology* 2015;277(03):863–871
- 42 Revel M-P, Bissery A, Bienvenu M, Aycard L, Lefort C, Fria G. Are two-dimensional CT measurements of small noncalcified pulmonary nodules reliable? *Radiology* 2004;231(02):453–458
- 43 Wormanns D, Kohl G, Klotz E, et al. Volumetric measurements of pulmonary nodules at multi-row detector CT: in vivo reproducibility. *Eur Radiol* 2004;14(01):86–92
- 44 Gietema HA, Schaefer-Prokop CM, Mali WP, Groenewegen G, Prokop M. Pulmonary nodules: Interscan variability of semiautomated volume measurements with multisection CT— influence of inspiration level, nodule size, and segmentation performance. *Radiology* 2007;245(03):888–894
- 45 Swensen SJ, Silverstein MD, Ilstrup DM, Schleck CD, Edell ES. The probability of malignancy in solitary pulmonary nodules. Application to small radiologically indeterminate nodules. *Arch Intern Med* 1997;157(08):849–855
- 46 Xu Y, Lu L, e LN, et al. Application of radiomics in predicting the malignancy of pulmonary nodules in different sizes. *AJR Am J Roentgenol* 2019;213(06):1213–1220
- 47 Zhang R, Sun H, Chen B, Xu R, Li W. Developing of risk models for small solid and subsolid pulmonary nodules based on clinical and quantitative radiomics features. *J Thorac Dis* 2021;13(07):4156–4168
- 48 Massion PP, Antic S, Ather S, et al. Assessing the accuracy of a deep learning method to risk stratify indeterminate pulmonary nodules. *Am J Respir Crit Care Med* 2020;202(02):241–249

- 49 Venkadesh KV, Setio AAA, Schreuder A, et al. Deep learning for malignancy risk estimation of pulmonary nodules detected at low-dose screening CT. *Radiology* 2021;300(02):438–447
- 50 de Hoop B, van Ginneken B, Gietema H, Prokop M. Pulmonary perifissural nodules on CT scans: rapid growth is not a predictor of malignancy. *Radiology* 2012;265(02):611–616
- 51 Ahn MI, Gleeson TG, Chan IH, et al. Perifissural nodules seen at CT screening for lung cancer. *Radiology* 2010;254(03):949–956
- 52 Mets OM, Chung K, Scholten ET, et al. Incidental perifissural nodules on routine chest computed tomography: lung cancer or not? *Eur Radiol* 2018;28(03):1095–1101
- 53 Godoy MCB. Conservative management of juxtaleural nodules at low-dose ct lung cancer screening: Is this prudent? *Radiology* 2020;297(03):719–720
- 54 Schreuder A, van Ginneken B, Scholten ET, et al. Classification of CT pulmonary opacities as perifissural nodules: reader variability. *Radiology* 2018;288(03):867–875
- 55 Zhu Y, Yip R, You N, Henschke CI, Yankelevitz DF. Management of nodules attached to the costal pleura at low-dose CT screening for lung cancer. *Radiology* 2020;297(03):710–718
- 56 Goo JM. Juxtaleural (perifissural) nodules: does location mean a benign lesion? *Radiology* 2018;288(03):876–877
- 57 Kobayashi Y, Fukui T, Ito S, et al. How long should small lung lesions of ground-glass opacity be followed? *J Thorac Oncol* 2013; 8(03):309–314
- 58 Hiramatsu M, Inagaki T, Inagaki T, et al. Pulmonary ground-glass opacity (GGO) lesions-large size and a history of lung cancer are risk factors for growth. *J Thorac Oncol* 2008;3(11): 1245–1250
- 59 Cho J, Kim ES, Kim SJ, et al. Long-term follow-up of small pulmonary ground-glass nodules stable for 3 years: implications of the proper follow-up period and risk factors for subsequent growth. *J Thorac Oncol* 2016;11(09): 1453–1459
- 60 Lee HW, Jin K-N, Lee J-K, et al. Long-term follow-up of ground-glass nodules after 5 years of stability. *J Thorac Oncol* 2019;14 (08):1370–1377
- 61 Lee JH, Lim WH, Hong JH, et al. Growth and clinical impact of 6-mm or larger subsolid nodules after 5 years of stability at chest CT. *Radiology* 2020;295(02):448–455