Article published online: 2022-07-31

Correlation of Trigeminopontine Angle with Severity of Trigeminal Neuralgia due to Neurovascular Conflict over Medial Aspect of Nerve: Can We Prognosticate the Reduction in Pain in Patients on Medical Management?

Pundalik Umalappa Lamani[1] Abhishek J. Arora[2] Kiran Kumar Reddy Kona[1] Jyotsna Yarlagadda[1]

[1] Department of Radiology and Imageology, Nizam's Institute Of Medical Sciences, Hyderabad, Telangana, India
[2] Department of Radio-Diagnosis, All India Institute of Medical Sciences, Bibinagar, Hyderabad, Telangana, India

Address for correspondence Abhishek J. Arora, MD, FRCR, Department of Radio-Diagnosis, All India Institute of Medical Sciences, Hyderabad 508126, Telangana, India (e-mail: dr.abhiarora@gmail.com).

Indian J Radiol Imaging 2022;32:308–313.

Abstract

Background Neurovascular conflicts (NVCs) are one of the major causative factors in patients presenting with trigeminal neuralgia (TN). We found a wide range of variation in degrees of acute angle formed between medial border of trigeminal nerve and anterior border of pons in patients with TN, i.e., medial trigeminopontine angle (mTPA), and tried to find its correlation with pain severity due to NVC over the medial aspect of nerve (mNVC).

Aims and Objectives To correlate mTPA measurement with severity of TN due to mNVC. To calculate the reduction in pain in patients kept on medical management and its correlation with mTPA.

Materials and Methods This was a retrospective observational study conducted between May 2018 and October 2020. A total of 41 patients presenting with TN and showing corresponding NVC were included in the study. Out of the total cases with NVC, 30 cases showed NVC over the medial surface of the nerve. All the patients were evaluated on MAGNETOM Skyra 3T magnetic resonance imaging (MRI; Siemens). Using the two-line Cobb angle method, the trigeminopontine angle was calculated. Pretreatment pain intensity and posttreatment pain relief of each patients were assessed by using the numeric rating scale (NRS) with numbers from 0 to 10 ("no pain" to "worst pain imaginable"). Relevant clinical details regarding pre- and posttreatment pain score, after a standard treatment plan of 600 mg of oxcarbazepine for 2 weeks, were collected.

Results Patients showing response of more than or equal to 50% ($\geq$50%) are considered as "good response" and those with response of less than 50% ($<$50%) are considered as "poor response." In our study with trigeminopontine angle threshold of 45 degrees, 7 out of 8 (87.5%) patients with $>45^\circ$ mTPA showed poor response and

Keywords
- trigeminal neuralgia
- trigeminopontine angle
- neurovascular conflict

published online
July 31, 2022

DOI https://doi.org/10.1055/s-0042-1753468.
ISSN 0971-3026.

© 2022. Indian Radiological Association. All rights reserved.
This is an open access article published by Thieme under the terms of the Creative Commons Attribution-NonDerivative-NonCommercial-License, permitting copying and reproduction so long as the original work is given appropriate credit. Contents may not be used for commercial purposes, or adapted, remixed, transformed or built upon. (https://creativecommons.org/licenses/by-nc-nd/4.0/)
Thieme Medical and Scientific Publishers Pvt. Ltd., A-12, 2nd Floor, Sector 2, Noida-201301 UP, India

15/22 (68.2%) patients with ≤45° showed good response to medical management for TN with statistical significance difference with a *p*-valve of 0.007.

Conclusion We found a negative correlation between the mTPA and percentage pain relief in patients kept on medical management and realized that mTPA measurement could become an important tool for prognosticating pain relief for patients of TN on medical therapy; however, more evidence and multicentric studies are required for the same.

Introduction

A wide variety of abnormalities can lead to trigeminal neuropathy, which include lesions involving the trigeminal nerve itself (primary lesions) and lesions that secondarily involve the nerve or any one of its three branches. Anatomically, trigeminal nerve is divided into four segments, based on its course through the brain stem, prepontine cistern, Meckel cave, and cavernous sinus, as it finally exits cranium.[1,2]

Trigeminal neuralgia (TN) is described as a sudden onset of severe, unilateral, paroxysmal, and lancinating pain in one or more of the distributions of the trigeminal nerve. Vascular compression, also known as neurovascular conflict (NVC), of the trigeminal nerve is one of the commonest secondary known cause, as suggested by Dandy in 1932. In his series, he reported that the superior cerebellar artery caused NVC in 30.7% of patients.[2–5] In another series, it was found that only 0 to 8.5% of cases of TN were secondary to tumors.[6] Studies have already been published correlating compression, displacement, and cross-sectional area of trigeminal nerve with the severity of pain. We were not able to find any study correlating mTPA with pain severity in a review of the literature. NVC of nerve could be on either side of the nerve; however, since the trigeminopontine angle (TPA) forms an acute angle over the medial aspect, we tried to find the correlation of mTPA with mNVC (NVC over the medial aspect of nerve) pain responsiveness.

Aims and Objectives

The aim of this study was to correlate mTPA measurement with severity of TN due to mNVC and to evaluate the reduction in pain in patients kept on medical management and its correlation with medial TPA (mTPA).

Materials and Methods

This was a retrospective observational study conducted between May 2018 and October 2020.

Study Population

A total of 42 cases with suspected TNs referred to the Department of Radiology for MRI scan were evaluated. Out of these patients, a total of 30 cases of TN had NVC over medial aspect of trigeminal nerve and were included in our study, with age ranging between 22 and 82 years, and these included 19 males and 11 females. An informed consent was taken from each patient for their inclusion in the study. The above method of enrolment is shown in ►**Fig. 1**.

Inclusion Criteria

Cases with TN with instigating vessel abutting/compressing over medial aspect of trigeminal nerve and those managed conservatively on standard medical management given in our institute constituting 600 mg of oxcarbazepine (Tablet Oxetol 300 mg [Sun Pharmaceuticals] twice a day) for 2 weeks and evaluated on follow-up visit were included.

Exclusion Criteria

Patients who underwent prior surgical microvascular decompression, NVC over lateral aspect of trigeminal nerve, or patients presenting with TN due to any other etiology were excluded.

Imaging Protocol

All the patients were evaluated on MAGNETOM Skyra 3T MRI (Siemens). Sequences acquired for evaluation were (1) T1-axial sections of whole brain; (2) T2-axial sections of whole brain and posterior fossa (medulla to upper pons) with (3) thin slices 3D T2-SPACE Sequence; and (4) FLAIR-axial sections of whole brain. Bilaterally, trigeminal nerves were examined for vascular compression/contact. In multiplanar windows, point of contact between the instigating vessel and the nerve was identified and only cases with medial point/area of contact with the nerve and vessel were included. Later, MPA was calculated. Relevant clinical details regarding pre- and posttreatment pain score as well as other laboratory investigations performed for the cases were collected. Microsoft Excel software was used to analyze the data. Charts and tables were prepared for representation and comparison of data.

Trigeminopontine Angle Calculation

Using the two-line Cobb angle method, MPA was calculated on symptomatic side in T2 3D SPACE-axial sections of MRI brain at the level of trigeminal nerve. A line is drawn along

 © 2022. Indian Radiological Association. All rights reserved.

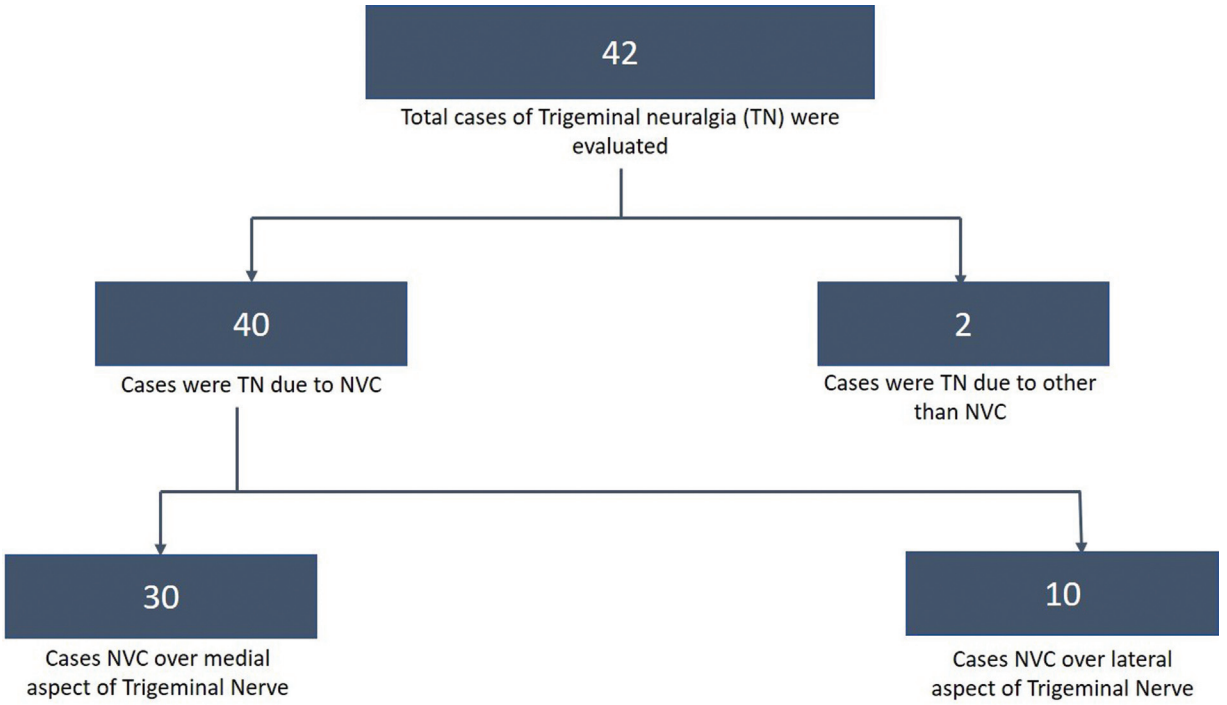

Fig. 1 Flow chart showing total number of cases included and excluded in our study.

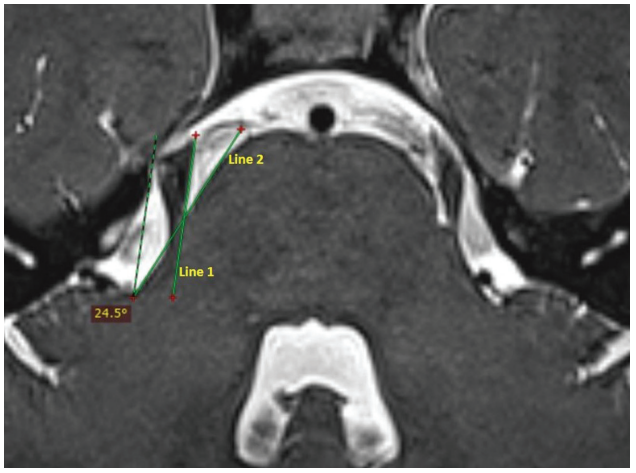

Fig. 2 T2 3D SPACE axial sections of MRI brain showing the two-line Cobb angle method for calculation of the trigeminopontine angle. 3D, three-dimensional; MRI, magnetic resonance imaging.

the medial aspect of cisternal segment of trigeminal nerve and a second line is drawn along the anterior aspect of pons medially, and the resultant angle is taken as mTPA (►**Fig. 2**).

Pain Scale

Assessment of pretreatment pain intensity and posttreatment pain relief was done using the numeric rating scale (NRS); NRS with numbers from 0 to 10 ("no pain" to "worst pain imaginable") were evaluated for all the patients at the time of MRI and at the time of follow-up visit after 2 weeks of course of medical therapy. Pre- and posttreatment pain relief response scores (0 to 10) were converted into percentages (0–100%) and then the patients were divided into two groups. Patients with posttreatment response of equal or more than 50%, i.e., significant response, were considered showing "good response" and those with less than 50% of posttreatment pain relief were considered as showing "poor response" to medical management.

Statistical Analysis

Receiver operating characteristic (ROC) curve analysis was performed to determine and reach an optimum cut-off value for the mTPA for the response to therapy. The optimum value was thus reached to be 45 degrees. Later, Pearson's Chi-square test was performed considering the selected angle, which was found to be statistically significant with a *p*-value of 0.007, between patients with posttreatment pain relief good response (≥50%) and poor/bad response (<50%) groups. Pearson's correlation coefficient test was also done for two variables using posttreatment pain relief in percentage and MPA in degrees, and the resultant *R*-value was −0.3366, which showed negative correlation. Thus, patients with more acute mTPA showed better response to medical management.

Results

A total 30 cases of TN due to NVC over medial aspect of trigeminal nerve were evaluated. Presenting age of patients varied between 22 and 82 years, including 19 males and 11 females. Majority of our patients were in 41 to 50 years (30%) and 51 to 60 years (23.3%) age groups.

Pretreatment pain intensity and posttreatment pain relief of each patient were assessed by using NRS. NRS with

 © 2022. Indian Radiological Association. All rights reserved.

		TRIGEMINOPONTINE ANGLE >45 DEGREE	TRIGEMINOPONTINE ANGLE ≤45 DEGREE	TOTAL
BAD/POOR RESPONSE GROUP	Count	7	7	14
	% within group	87.5%	31.8%	46.7%
GOOD RESPONSE GROUP	Count	1	15	16
	% within group	12.5%	68.2%	53.3%
TOTAL	Count	8	22	30
	% within group	100.0%	100.0%	100.0%

	Value	df	P value
Pearson Chi-Square Test	7.308*	1	0.007

Fig. 3 Statistical analytic table showing comparison data between patients with posttreatment pain relief good response and poor/bad response groups with a trigeminopontine angle threshold of 45 degrees, showing statistically significant correlation of the trigeminopontine angle with the percentage reduction of pain relief, after standard medical therapy.

numbers from 0 to 10 ("no pain" to "worst pain imaginable") was used in subjective assessment of pain. As described, the posttreatment pain relief response score (0–10) was converted into percentages (0–100%) and then patients divided into two groups, of those showing significant or "good response" and those showing "poor response." These pain relief findings were correlated with the mTPA. ROC curve analysis was performed to determine and reach an optimum cut-off value for the mTPA for the response to therapy. The optimum value was thus reached to be 45 degrees, and considering the same, 7 out of 8 (87.5%) patients >45° mTPA showed bad/poor response and 15/22 (68.2%) patients ≤45° mTPA showed good response to medical management, and found statistical significance with a *p*-value of 0.007. The Pearson correlation coefficient test was done for posttreatment pain relief in percentage and mTPA, which showed a resultant *R*-value of −0.3366, suggesting negative correlation (►**Fig. 3**).

Discussion

A wide variety of abnormalities can lead to TN, including pathologies involving the trigeminal nerve itself (primary) and etiologies that secondarily involve the nerve or any one of its three branches.[1,2] NVC is one of the commonest causes of TN involving the cisternal portion of the nerve. Other resultant pathologies causing TN include demyelinating diseases like multiple sclerosis, vascular insults leading to infarcts, and tumors like glioma involving the trigeminal nerve at any level. Trigeminal neuropathy involving the canalicular (Meckel cave and cavernous sinus) segment are frequently due to meningiomas, trigeminal schwannomas, epidermoid cysts, metastases, pituitary adenomas, and aneurysms. The most common extracranial cause of TN is perineural spread of malignant tumors.[1,2]

The clinical findings do not permit accurate localization of pathologies; therefore, MRI is the modality of choice to visualize the entire course of the fifth cranial nerve and localize the pathology.[1,4,6,7] Commonly recognized NVC syndromes encountered in clinical practice are TN, hemifacial spasm, and glossopharyngeal neuralgia. The first-line treatment of patients with the aforementioned symptoms is based on conservative medical management. Patients refractory to conservative treatment later undergo microvascular decompression with good success rates. A long-term study of the results on TN after microsurgical vascular decompression (Kaplan–Meier curves at 20 years) showed that cure was achieved in 88.1% of the patients with a NVC producing a large groove on the nerve (Grade III), 78.3% of the patients with a NVC with nerve distortion or displacement (Grade II), and 58.3% of the patients with a NVC with simple contact on the nerve (Grade I). Therefore, preoperative visualization of the NVC by MRI and determination of its grading are important for the therapeutic decision.[8,9] There are few studies evaluating these above parameters with patient outcome on medical management.

In our study, we correlated the degree of mTPA with posttreatment pain reduction in medically managed patients of TN due to NVC.

The well-known visual analogue scale (VAS) and NRS for assessment of pain intensity agree well and are equally sensitive in assessing acute pain after surgery, and they are both superior to a four-point verbal categorical rating scale. An NRS with numbers from 0 to 10 ("no pain" to "worst pain imaginable") is more practical than a VAS, easier to understand for most people, and does not need clear vision, dexterity, paper, and pen. One can even determine the intensity of pain accurately using telephone interview, a computerized telephone interview, and recording of NRS data by the patient directly into the database of a computer via the telephone keyboard.[10] In our study we have used the NRS method for assessment of pretreatment pain intensity and posttreatment pain relief in each patient separately. Posttreatment pain relief response score (0–10) was converted into percentages (0–100%) and then divided into two groups as described.

In our study, the Pearson correlation coefficient test was done for two variables using posttreatment pain relief in percentages and MPA in degrees, which resulted in an *R*-value of −0.3366, thus confirming negative correlation of mTPA with percentage of pain relief. This finding is helpful in predicting the pain relief that could be expected in patients with TN, by studying the mTPA. By keeping the MPA threshold of 45 degrees, patients with more than >45° mTPA showed bad/poor response, while those with less than or equal ≤45° mTPA showed good response to medical management for TN, which was statistically significant at *p*-value of 0.007 ($p < 0.01$) (►**Figs. 4** and **5**). Possible hypothesis of better medical management response in patients with more acute mTPA could be attributed to shorter course of the nerve in the cistern or parallel course of vessels along the nerve; however, this needs further research and multicenter studies.

Limitations of our study were single institutional evaluation of patients, small sample size, and subjective variation in pain relief scoring.

 © 2022. Indian Radiological Association. All rights reserved.

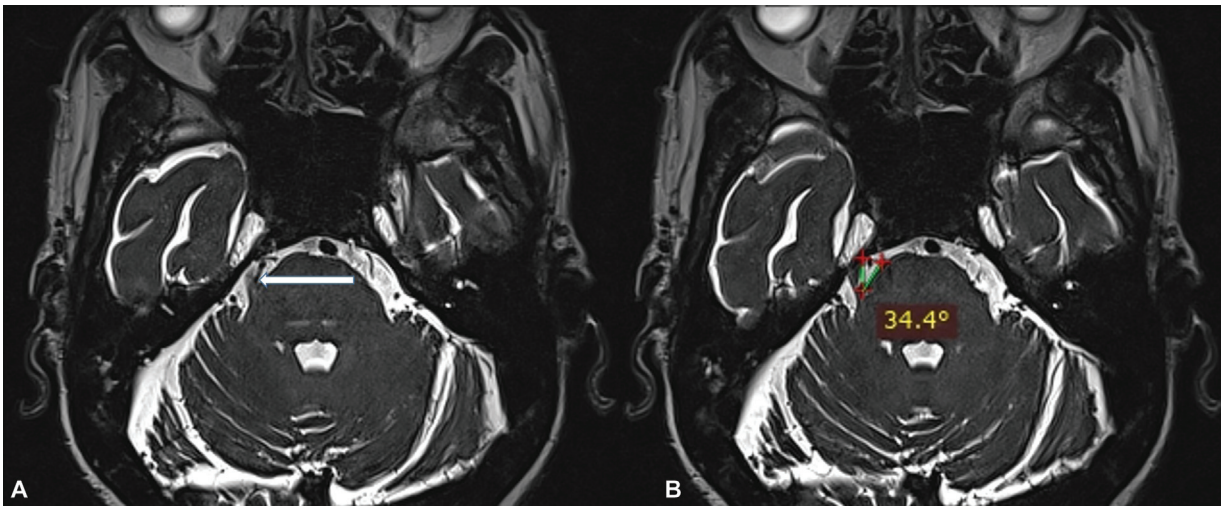

Fig. 4 A 46 year-old female came with complaint of electric shock like sensation on the right side of face. (**A**) Vascular loop seen compression over medial aspect of left trigeminal nerve (*white arrow*). (**B**) Left trigeminopontine angle 34.4°. Pretreatment pain scale: 7; posttreatment scale: 2; and posttreatment pain reduction scale: 5 (71.4%).

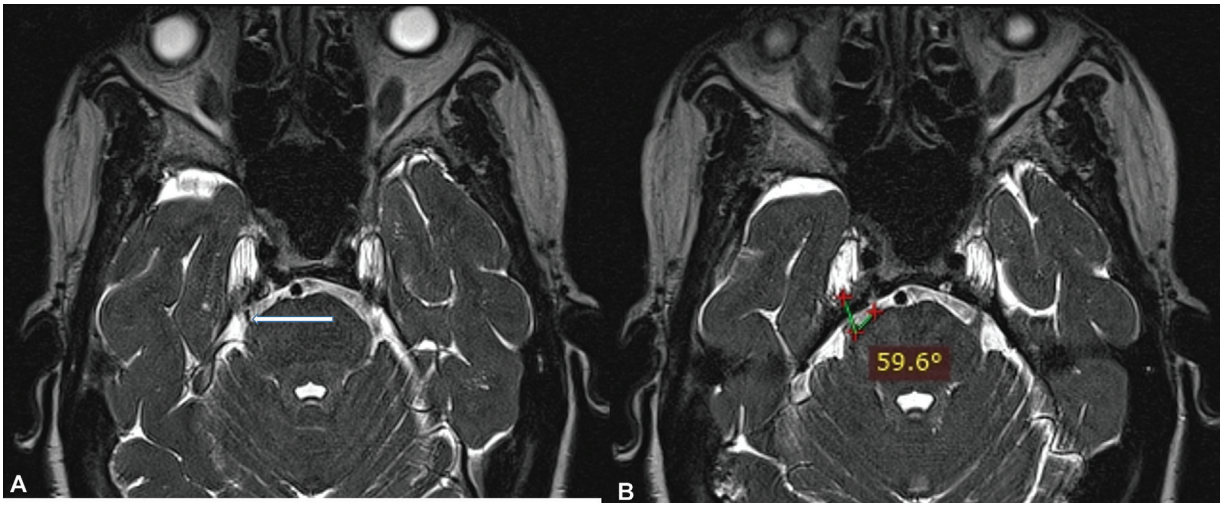

Fig. 5 A 39 year-old male came with complaint of electric shock like sensation on the right side of face, very severe in intensity even with blow of air, inability to speak. (**A**) Vascular loop seen compression over medial aspect of right trigeminal nerve (*arrow*). (**B**) Right trigeminopontine angle 59.6°. Pretreatment pain scale: 6; posttreatment scale: 4; and posttreatment pain reduction scale: 2 (33.3%).

Conclusion

The high-resolution MRI directs the physicians to decision making in the plan of action for management of TN due to NVC. Our study is a step-in direction of predicting the outcome of medical management in patients presenting with TN, based on the mTPA. We found a negative correlation between the mTPA and percentage pain relief in patients kept on medical management. We realized that by keeping an angle threshold of 45 degrees, statistically significant correlation was achieved in predicting pain relief in patients kept on medical management, hence mTPA becoming an important parameter to be considered for the same.

Conflict of Interest
None.

References

1 Majoie CB, Verbeeten B Jr, Dol JA, Peeters FL. Trigeminal neuropathy: evaluation with MR imaging. Radiographics 1995;15(04): 795–811
2 Ko AL, Lee A, Raslan AM, Ozpinar A, McCartney S, Burchiel KJ. Trigeminal neuralgia without neurovascular compression presents earlier than trigeminal neuralgia with neurovascular compression. J Neurosurg 2015;123(06):1519–1527
3 Hughes MA, Frederickson AM, Branstetter BF, Zhu X, Sekula RF Jr. MRI of the trigeminal nerve in patients with trigeminal neuralgia secondary to vascular compression. AJR Am J Roentgenol 2016;206(03):595–600
4 Tanrikulu L, Scholz T, Nikoubashman O, Wiesmann M, Clusmann H. Preoperative MRI in neurovascular compression syndromes and its role for microsurgical considerations. Clin Neurol Neurosurg 2015;129:17–20
5 Blitz AM, Northcutt B, Shin J, et al. Contrast-enhanced CISS imaging for evaluation of neurovascular compression in trigeminal neuralgia: improved correlation with symptoms and

 © 2022. Indian Radiological Association. All rights reserved.

prediction of surgical outcomes. AJNR Am J Neuroradiol 2018;39 (09):1724–1732
6 Jamjoom AB, Jamjoom ZA, al-Fehaily M, el-Watidy S, al-Moallem M, Nain-Ur-Rahman . Trigeminal neuralgia related to cerebello-pontine angle tumors. Neurosurg Rev 1996;19(04):237–241
7 Tanrikulu L, Hastreiter P, Bassemir T, et al. New clinical and morphologic aspects in trigeminal neuralgia. World Neurosurg 2016;92:189–196
8 Leal PR, Froment JC, Sindou M. MRI sequences for detection of neurovascular conflicts in patients with trigeminal neuralgia and predictive value for characterization of the conflict (particularly degree of vascular compression) [in French]. Neurochirurgie 2010;56(01):43–49
9 Hardaway FA, Holste K, Ozturk G, et al. Sex-dependent posterior fossa anatomical differences in trigeminal neuralgia patients with and without neurovascular compression: a volumetric MRI age- and sex-matched case-control study. J Neurosurg 2019;132(02): 631–638
10 Breivik H, Borchgrevink PC, Allen SM, et al. Assessment of pain. Br J Anaesth 2008;101(01):17–24

 © 2022. Indian Radiological Association. All rights reserved.