Article published online: 2022-08-02

Platelets–Leucocyte Satellitism: Love Is in the EDTA!

Bashundhara Lata[1] Tirumala Sripathi[1] Mona Lisa[2]

[1] Department of Pathology, Mahavir Cancer Sansthan, Patna, India
[2] Department of Pathology/Lab Medicine, All India Institute of Medical Sciences, Deoghar, Ramsagar, Jharkhand, India

J Lab Physicians 2023;15:173–174.

Address for correspondence Mona Lisa, MBBS, MD, Department of Pathology/lab medicine, All India Institute of Medical Sciences, Deoghar, PTI campus, Daburgram, Jasidih, Deoghar 814142, Jharkhand, India (e-mail: monaloud@gmail.com).

In what may be called the roller-coaster ride profession of pathologists, there are many landscapes passing by that we see but do not look at! However, once in a while, a rare sighting forces us to pull the breaks. Platelet satellitism is one such uncommon, peculiar phenomenon that shows platelets rosetting around neutrophils and sometimes monocytes.[1,2]

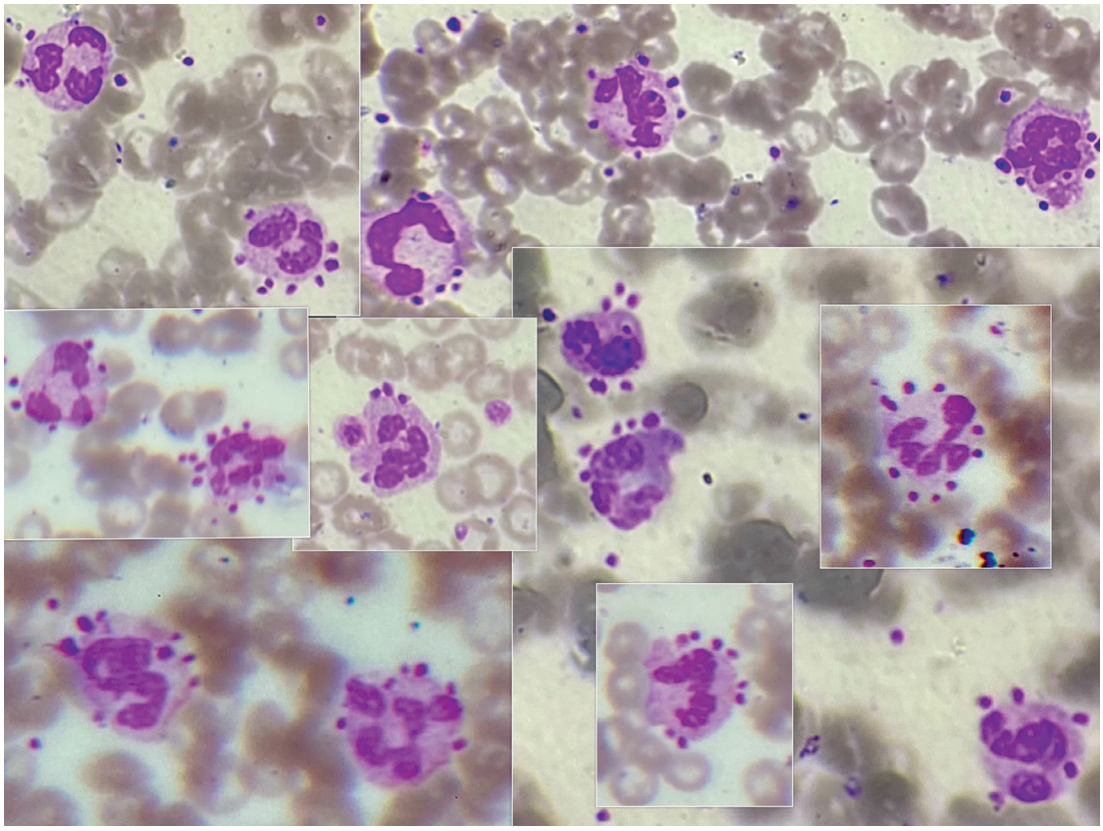

Fig. 1 Leishman stained peripheral blood smear of the patient with neutrophils surrounded by platelets (100x oil immersion).

article published online
August 2, 2022

DOI https://doi.org/10.1055/s-0042-1751316.
ISSN 0974-2727.

© 2022. The Indian Association of Laboratory Physicians. All rights reserved.
This is an open access article published by Thieme under the terms of the Creative Commons Attribution-NonDerivative-NonCommercial-License, permitting copying and reproduction so long as the original work is given appropriate credit. Contents may not be used for commercial purposes, or adapted, remixed, transformed or built upon. (https://creativecommons.org/licenses/by-nc-nd/4.0/)
Thieme Medical and Scientific Publishers Pvt. Ltd., A-12, 2nd Floor, Sector 2, Noida-201301 UP, India

Exposure of a cryptic antigen on the platelets treated with ethylenediaminetetraacetic acid (EDTA) may be responsible for this phenomenon, giving a spurious thrombocytopenic picture on a complete blood count.[3]

We came across this alluring finding recently in the peripheral blood smear of a 16-year-old patient of BCR-ABL-positive acute lymphoblastic leukemia (ALL), who was in remission.

Approximately 60% of neutrophils showed at least four or more platelets sticking to their surface (►**Fig. 1**). Occasional monocytes were also seen covered with platelets.

Platelet satellitism is a rare cause of spurious thrombocytopenia. On PubMed search, we could find only 72 articles in the English language on the subject, of which only 3 were from India.

The postulated mechanism for this picturesque phenomenon is the presence of IgG autoantibodies in the patient's serum, directed against a cryptic domain of the αIIbβ3 integrin of platelets, that is unmasked in the presence of EDTA. The Fcγ receptor (CD16) of neutrophils or monocytes react to this autoantibody causing rosetting. The reason for the presence of such autoantibodies in some individuals is still obscure.[3,4]

Platelet satellitism has been described in texts,[5,6] to be seen usually in healthy individuals. It has also been reported in diseases such as lymphoma[7] and autoimmune hemolytic anemia.[8]

Apart from pseudo-thrombocytopenia, platelet satellitism does not have profound clinical implications. However, a distinctive morphology with platelets apparently defying the laws of entropy, arranging themselves in an orderly manner, around polymorphs, is rare and should not be missed.

Conflict of Interest
None declared.

References

1 Djaldetti M, Fishman P. Satellitism of platelets to monocytes in a patient with hypogammaglobulinaemia. Scand J Haematol 1978; 21(04):305–308
2 Cohen AM, Lewinski UH, Klein B, Djaldetti M. Satellitism of platelets to monocytes. Acta Haematol 1980;64(02):61–64
3 Bizzaro N, Goldschmeding R, von dem Borne AE. Platelet satellitism is Fc gamma RIII (CD16) receptor-mediated. Am J Clin Pathol 1995;103(06):740–744
4 Ryo R, Sugano W, Goto M, et al. Platelet release reaction during EDTA-induced platelet agglutinations and inhibition of EDTA-induced platelet agglutination by anti-glycoprotein II b/III a complex monoclonal antibody. Thromb Res 1994;74(03): 265–272
5 Lewis SM, Bain BJ. Bates, Laffan MA. Dacie and Lewis practical haematology. 12th ed. Philadelphia: Churchill Livingstone/Elsevier; 2017
6 Greer JP, Rodgers GM, Glader B, Arber DA, Means RT, List AF. Wintrobe's clinical hematology. 14th ed. Philadelphia: Wolters Kluwer Health/Lippincott Williams & Wilkins; 2019
7 Bain BJ, Czako B. Monocyte adhesion with platelet satellitism and phagocytosis in Hodgkin lymphoma. Am J Hematol 2018;93(12): 1561
8 Ghariani I, Braham N, Hamzaoui S, Bekir L. Platelet satellitism in autoimmune hemolytic anemia. Curr Res Transl Med 2017;65 (02):61–64

 © 2022. The Indian Association of Laboratory Physicians. All rights reserved.