Article published online: 2022-08-31

Pleurovenous Shunt Placement for the Management of Nonmalignant Pleural Effusion

Andy Awwad, MD[1] Zach Berman, MD[1] Jeet Minocha, MD[1]

[1] Division of Interventional Radiology, University of California San Diego School of Medicine, San Diego, California

Address for correspondence Andy Awwad, MD, 9300 Campus Point Drive, MC 7756, San Diego, CA 92037 (e-mail: anawwad@health.ucsd.edu).

Semin Intervent Radiol 2022;39:248–252

Abstract

Therapeutic thoracentesis is a first-line therapy in the management of patients with medically refractory, nonmalignant pleural effusion. However, when required in short intervals, serial thoracenteses can lead to increased procedure-related complications and negatively impact quality of life. Alternative treatment options vary depending on the etiology of fluid accumulation. Hepatic hydrothorax secondary to cirrhosis is a common cause of medically refractory pleural effusion encountered by interventional radiologists. In select patients in whom surgical pleurodesis, transjugular intrahepatic portosystemic shunt placement, and/or tunneled pleural catheter placement cannot be performed or provide inadequate relief, implantation of a pleurovenous (Denver) shunt may assist in palliation. The Denver shunt system allows decompression of pleural fluid into the central venous circulation by utilizing unidirectional valves and a manually operated subcutaneous pump. Though limited reports have described favorable technical and clinical success, more research is required to determine the safety and efficacy of this procedure. This article discusses pleurovenous shunt placement, postprocedure shunt evaluation, and potential associated complications.

Keywords
- Denver shunt
- pleurovenous shunt
- hepatic hydrothorax
- nonmalignant pleural effusion
- interventional radiology

The LeVeen shunt was introduced in 1974 as a device to shunt ascitic fluid into central venous circulation through a unidirectional valve by exploiting elevated pressures in the peritoneal cavity with respect to the superior vena cava.[1] Years later in 1979, the Denver shunt was introduced, which incorporated a subcutaneous pump that could be manually compressed to facilitate passage of fluid against higher pressures. The first described use of the Denver shunt for managing symptomatic pleural effusion was published in 1980.[2] Currently, single-valve and bi-valve Denver shunt systems are commercially available (BD CareFusion, San Diego, CA). The shunt system consists of the pump chamber, a 15.5-Fr multi side-hole drainage catheter, and a single end-hole venous catheter. A smaller 11.5-Fr venous limb is also available and recommended for use if the subclavian vein is accessed rather than the internal jugular.[3] The single-valve system is marketed as being more favorable for the drainage of viscous fluid due to decreased obstruction to flow.[3] The bi-valve system allows patients to pump the shunt repeatedly without having to compress the venous limb between pumps while the chamber refills.

Patient Selection

In the United States, pleural effusions affect over a million patients annually, with many experiencing debilitating symptoms and poor quality of life.[4] Causes of recurrent, nonmalignant pleural effusion include congestive heart failure, hepatic hydrothorax, chylothorax, hypoalbuminemia, nephrotic syndrome, and idiopathic recurrent effusion, among others.[4,5] Cirrhotic patients with portal hypertension, ascites, and hepatic hydrothorax are frequently encountered by interventional radiologists. Approximately 85% of hepatic hydrothorax cases are right-sided and are thought to occur due to transgression of ascitic fluid through small defects in the diaphragm, although other hypotheses have also been postulated.[6] When refractory to medical therapy with dietary salt restriction and diuretic use, therapeutic thoracentesis can

Issue Theme Thoracic Interventions; Guest Editors, Claire S. Kaufman, MD and Charles E. Ray, Jr., MD, PhD, FSIR

© 2022. Thieme. All rights reserved.
Thieme Medical Publishers, Inc., 333 Seventh Avenue, 18th Floor, New York, NY 10001, USA

DOI https://doi.org/10.1055/s-0042-1751296.
ISSN 0739-9529.

This document was downloaded for personal use only. Unauthorized distribution is strictly prohibited.

be performed. Unfortunately, for many patients, this only offers short-term benefit and must be repeated with variable frequency, with risk of procedure-related complications at each visit. Transjugular intrahepatic portosystemic shunt (TIPS) placement is often performed in cirrhotic patients with refractory ascites or hydrothorax, although ultimately may be unsuccessful for a minority of patients.[7] While liver transplantation remains the only definitive treatment, surgical pleurodesis, diaphragmatic repair, and pleuroperitoneal shunt placement have also been described in the management of hepatic hydrothorax.[6–10]

For patients with medically refractory pleural effusion unrelated to cirrhosis, thoracentesis, surgical pleurodesis, and pleurovenous shunt placement remain in the treatment paradigm. If life expectancy is limited, consideration should be given to placement of a tunneled, valved pleural drainage catheter (PleurX, BD, Chicago, IL) for noncirrhotic patients requiring frequent thoracentesis. These tunneled catheters provide the capability to perform intermittent drainage, and function well for weeks to months following placement.[11–13] Occasionally, placement can lead to spontaneous pleurodesis for some patients.[11–13] If the anticipated duration of therapy is greater than 6 months, indwelling tunneled pleural catheters are less favored.[11–13] For the small subset of patients with good overall prognosis, but who are poor surgical candidates, have failed or are not being considered for pleurodesis and/or TIPS placement, or who are unable to maintain visits for frequent thoracenteses, pleurovenous Denver shunt placement can be considered for palliation.

Potential candidates for pleurovenous shunt placement first undergo formal clinical evaluation in the ambulatory setting. Absolute contraindications to the procedure include uncorrectable bleeding diathesis, sepsis, bacteremia, end-stage renal disease requiring dialysis, and active pulmonary or pleural infection.[14–23] Severe chronic kidney disease, central venous stenoses, congestive heart failure, and septated pleural effusions are relative contraindications to shunt placement.[14–23]

Shunt Placement

Appropriately selected patients are brought to the fluoroscopy suite and positioned in a 30-degree anterior oblique position corresponding to the symptomatic side (usually right). Preprocedural antibiotic prophylaxis is routinely administered. The procedure is commonly performed under moderate sedation. The skin is prepped and draped from the neck to below the costal margin. Initial ultrasound images are obtained to delineate a safe window for percutaneous access of the pleural effusion, ideally along the mid-axillary line directed slightly caudally and posteriorly. Percutaneous pleural access is established with a 5-Fr needle-mounted catheter, and a stiff 0.035-inch working wire is advanced into the pleural cavity. The tract is then sequentially dilated over the wire to accept a 16-Fr peel-away sheath. A 3-cm incision is then made at the costal margin cephalad to the pleurotomy site and a subcutaneous pocket is created to receive the pump chamber. It is important that the chamber be well-seated over the ribs to provide an appropriate backstop for pumping. The pleural limb is tunneled to the pleurotomy site and the catheter is placed with some redundancy positioned in the posterobasal hemithorax. Using ultrasound guidance, the ipsilateral internal jugular vein is then accessed and the tract sequentially dilated over a wire to a 16-Fr peel-away sheath. The venous limb of the catheter is then tunneled subcutaneously from the pocket to the venotomy site and cut to length for final position with the tip at the superior cavoatrial junction. A second incision below the clavicle may be required to complete the tunneling process. After priming the system by repeatedly compressing the pump chamber, the venous limb is placed, and the incisions are closed (►**Fig. 1**).

Shunt Evaluation

It is common to see patients in consultation for shunt evaluation after placement (►**Fig. 2**). Poor shunt function is suggested by persistent or worsening symptomatic pleural effusion. To be evaluated fluoroscopically, the shunt system can safely be accessed via cannulating the pump or either catheter limb using a non-coring needle (e.g., Huber needle), which should not result in any damage to the system that would inhibit further use. After accessing the shunt, dilute contrast material is injected by hand under digital subtraction angiography. A patent venous limb should opacify

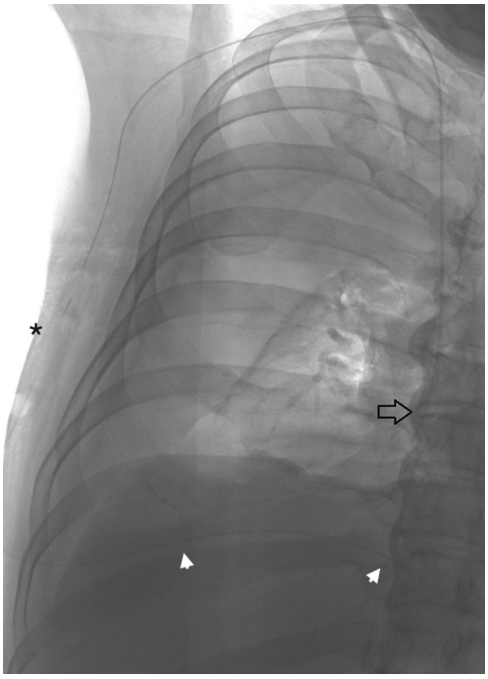

Fig. 1 Single fluoroscopic image following right-sided pleurovenous Denver shunt placement demonstrating the pleural access site at the 8th intercostal space, and the pleural limb of the catheter terminating in the basal hemithorax (arrowheads). The subcutaneous pump is seen just cephalad to the pleural access site (asterisk), and the venous limb of the catheter can be followed to the superior cavoatrial junction (arrow). A thin radiopaque stripe is present along the entirety of the catheter; no contrast was injected. A massive right pleural effusion is present, compressing the right lung.

 © 2022. Thieme. All rights reserved.

This document was downloaded for personal use only. Unauthorized distribution is strictly prohibited.

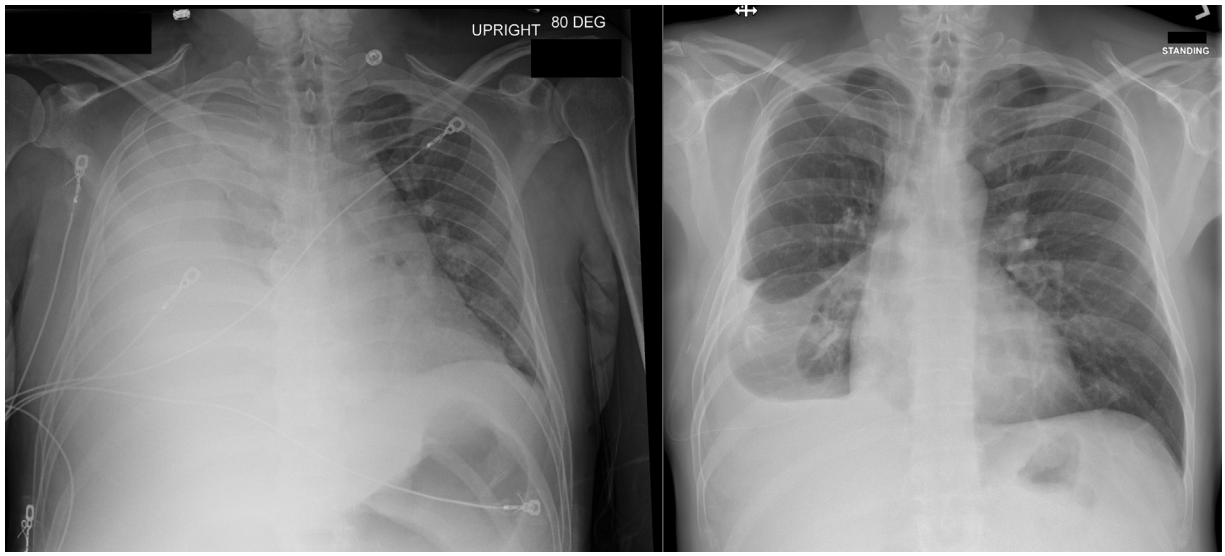

Fig. 2 Frontal chest radiograph of a 44-year-old man with refractory right-sided hepatic hydrothorax with near-total white out of the right hemithorax (left). Six months following right-sided pleurovenous Denver shunt placement, frontal chest radiograph demonstrates significant improvement in the right pleural effusion and right lung expansion (right). No shunt revision or replacement occurred in the interval.

readily with contrast and demonstrate rapid emptying into the right atrium (►**Fig. 3**). The entire venous limb should be evaluated, although, when present, filling defects may be seen in the dependent portion of the shunt adjacent to the pump. Any reflux of contrast following injection indicates a malfunctioning unidirectional valve. The pleural limb of the shunt system can be evaluated similarly by accessing the catheter just caudal to the pump and injecting while manual pressure is held over the venous limb.

Outcomes and Complications

The safety and efficacy of pleurovenous shunting for refractory effusion is poorly studied, with few reports describing favorable technical and clinical success of the procedure.[17–20] In the authors' experience, inadequate drainage of pleural fluid may be encountered following shunt placement. The Denver shunt system is designed to allow flow through the unidirectional valves with pressure gradients as little as 3 to 5 cm H_2O. When managing ascites with a peritoneovenous shunt, generation of negative intrathoracic pressure during inspiration can be sufficient to facilitate flow of ascites into the central venous circulation while supine. Following pleurovenous shunt placement, the pressure differential is not as sufficient, as the entire system is implanted within the thoracic cavity. Due to this, patients are almost entirely dependent on the pumping mechanism. It is imperative that patients are counseled adequately both pre- and postprocedure regarding the importance of shunt pumping, and together with their caregivers should be shown how to operate the pump after it has been placed. Marking the skin overlying the pump chamber may be beneficial for some patients. The shunt system should be pumped several times per day while lying supine. Each pump may physically move 1 to 2 cc through the chamber and catheter. It is feasible that some patients may experience buildup of pleural fluid more rapidly than can be drained via the shunt system despite adequate pumping.

Consideration should be carefully given to size and location of the subcutaneous pocket created for the pump chamber. The chamber must be well situated over the ribs and stable enough to accommodate repeated pumping

Fig. 3 Single digital subtraction angiography image during pleurovenous Denver shunt evaluation in a 51-year-old cirrhotic patient with right hepatic hydrothorax and persistent shortness of breath. Contrast injection demonstrates uniform opacification of the venous limb and rapid emptying into the right atrium (arrow) consistent with a patent shunt. The patient was counseled on pumping instructions.

 © 2022. Thieme. All rights reserved.

This document was downloaded for personal use only. Unauthorized distribution is strictly prohibited.

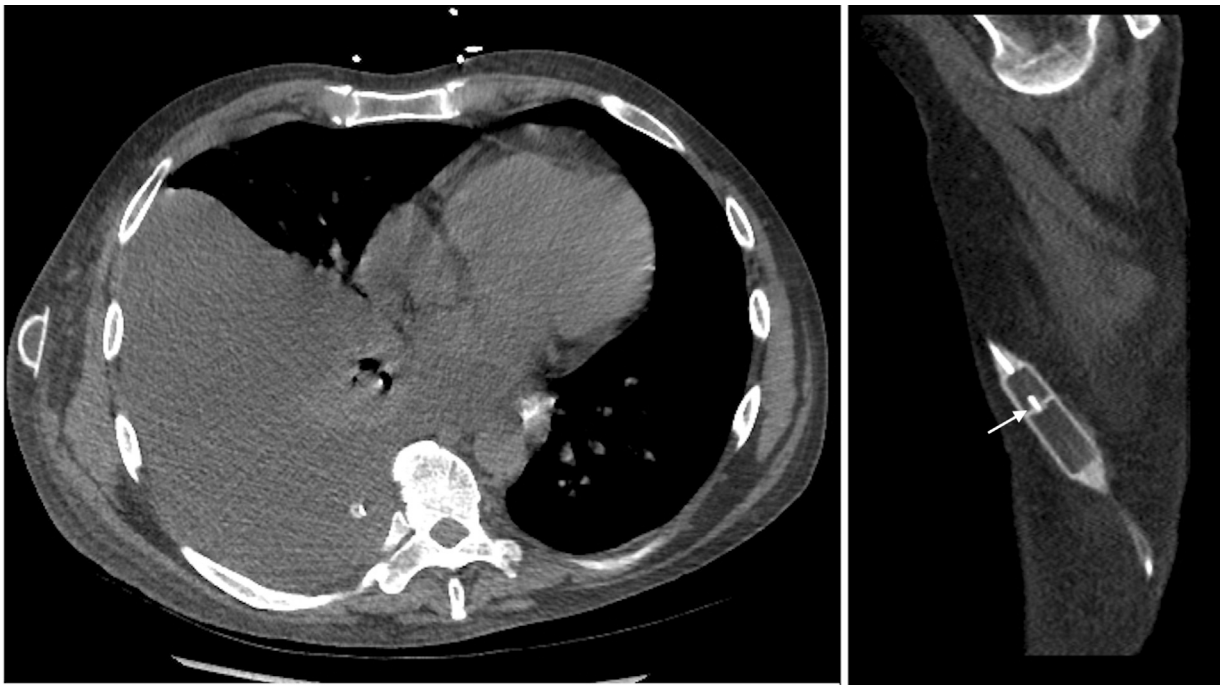

Fig. 4 Axial and sagittal CT images of different patients demonstrating the Denver shunt pump chamber. On the sagittal image, the one-way "check" valve is evident (arrow), which prevents reflux of material from the venous limb while the chamber refills between sequential pumps.

(►**Fig. 4**). Attention should be paid to not create too large a pocket, as it is feasible for the pump to flip subcutaneously (►**Fig. 5**). In this setting, it is possible for the pump to remain functional by compression against the ribs, but unfortunately is no longer easily accessible percutaneously for evaluation without first repositioning the system.

Peritoneovenous Denver shunt placement has been reportedly associated with the development of postprocedure consumptive coagulopathy and circulating fibrin split products.[21–23] Though no clear data exist on the rate of adverse events associated with pleurovenous Denver shunt placement, baseline assessment of renal function should be performed at the time of initial clinical evaluation, and coagulation parameters should be obtained in the preprocedural setting.[17–20] Postprocedure care requires observation for the development of fluid overload and post-shunt coagulopathy. Repeat laboratory evaluation, to include a disseminated intravascular coagulation (DIC) profile, can be performed as needed.

Fig. 5 Axial CT image of a 56-year-old man with cirrhosis and right hepatic hydrothorax who previously underwent right-sided pleurovenous Denver shunt placement. The shunt pump can be seen flipped 180 degrees within the subcutaneous pocket (arrow). This patient was still able to operate the pump with clinical benefit.

Additional potential complications related to pleural access during the procedure include pneumothorax, hemothorax, and leakage of pleural fluid via the skin incision with or without wound dehiscence.[14–23] Less common complications associated with the indwelling shunt system include catheter malposition, catheter obstruction, and infection.[14–23]

Conclusion

Pleurovenous Denver shunt placement may be considered as part of the treatment paradigm for patients with medically refractory, nonmalignant pleural effusion who have failed or are not being considered for surgical management, and for whom frequent thoracentesis is not tolerated or provides inadequate palliation. Complications include inadequate drainage, catheter or pump malposition, and shunt malfunction or obstruction. There is a potential association with the development of DIC postprocedure; however, more data are needed to assess the safety profile and efficacy of pleurovenous shunt placement in this patient population.

Conflict of Interest
The authors of this report have no conflicts of interest to disclose. No financial support was received for the production of this original manuscript.

 © 2022. Thieme. All rights reserved.

This document was downloaded for personal use only. Unauthorized distribution is strictly prohibited.

References

1 Leveen HH, Christoudias G, Ip M, Luft R, Falk G, Grosberg S. Peritoneo-venous shunting for ascites. Ann Surg 1974;180(04): 580–591
2 Oosterlee J. Peritoneovenous shunting for ascites in cancer patients. Br J Surg 1980;67(09):663–666
3 CareFusion Corporation. Denver ascites shunts for patients with refractory ascites. 2012 product brochure. . Accessed September 13, 2021 at: https://www.bd.com/en-in/our-products/ interventional-procedures/drainage/denver-shunts
4 Light RW. Pleural diseases. Dis Mon 1992;38(05):266–331
5 Walker SP, Morley AJ, Stadon L, et al. Nonmalignant pleural effusions: a prospective study of 265 consecutive unselected patients. Chest 2017;151(05):1099–1105
6 Milanez de Campos JR, Andrade Filho LO, de Campos Werebe E, Pandulo FL, Filomeno LT, Jatene FB. Hepatic hydrothorax. Semin Respir Crit Care Med 2001;22(06):665–674
7 Ditah IC, Al Bawardy BF, Saberi B, Ditah C, Kamath PS. Transjugular intrahepatic portosystemic stent shunt for medically refractory hepatic hydrothorax: a systematic review and cumulative meta-analysis. World J Hepatol 2015;7(13):1797–1806
8 Falchuk KR, Jacoby I, Colucci WS, Rybak ME. Tetracycline-induced pleural symphysis for recurrent hydrothorax complicating cirrhosis. A new approach to treatment. Gastroenterology 1977;72 (02):319–321
9 Huang PM, Kuo SW, Lee JM. Thoracoscopic diaphragmatic repair for refractory hepatic hydrothorax: application of pleural flap and mesh onlay reinforcement. Thorac Cardiovasc Surg 2006;54(01): 47–50
10 Alba D, Molina F, Ripoll MM, Castillo P, Lizasoain J, Vázquez JJ. [Pleuroperitoneal shunt in the treatment of pleural effusion associated with cirrhosis]. Med Interna 1993;10(12):604–606
11 Iyer NP, Reddy CB, Wahidi MM, et al. Indwelling pleural catheter versus pleurodesis for malignant pleural effusions. A systematic review and meta-analysis. Ann Am Thorac Soc 2019;16(01): 124–131
12 Bhatnagar R, Reid ED, Corcoran JP, et al. Indwelling pleural catheters for non-malignant effusions: a multicentre review of practice. Thorax 2014;69(10):959–961
13 Chalhoub M, Harris K, Castellano M, Maroun R, Bourjeily G. The use of the PleurX catheter in the management of non-malignant pleural effusions. Chron Respir Dis 2011;8(03):185–191
14 Martin LG. Percutaneous placement and management of peritoneovenous shunts. Semin Intervent Radiol 2012;29(02):129–134
15 Orsi F, Grasso RF, Bonomo G, Monti C, Marinucci I, Bellomi M. Percutaneous peritoneovenous shunt positioning: technique and preliminary results. Eur Radiol 2002;12(05):1188–1192
16 White MA, Agle SC, Padia RK, Zervos EE. Denver peritoneovenous shunts for the management of malignant ascites: a review of the literature in the post LeVeen Era. Am Surg 2011;77(08):1070–1075
17 Oizumi H, Inui K, Tatebe S, Ishihara R, Washio M. [A case of intractable hepatic hydrothorax treated by pleuro-venous shunt]. Nihon Kyobu Geka Gakkai Zasshi 1989;37(04):751–754
18 Artemiou O, Marta GM, Klepetko W, Wolner E, Müller MR. Pleurovenous shunting in the treatment of nonmalignant pleural effusion. Ann Thorac Surg 2003;76(01):231–233
19 Bayram AS, Köprücüoğlu M, Aygün M, Gebitekin C. Pleurovenous shunt for treating refractory benign pleural effusion. Eur J Cardiothorac Surg 2008;33(05):942–943
20 Hadsaitong D, Suttithawil W. Pleurovenous shunt in treating refractory nonmalignant hepatic hydrothorax: a case report. Respir Med 2005;99(12):1603–1605
21 Segawa T, Kato K, Kawashima K, Suzuki T, Ehara S. The influence of a peritoneovenous shunt for cirrhotic and malignant intractable ascites on renal function. Acta Radiol Open 2018;7(03): 2058460118764208
22 Bernhoft RA, Pellegrini CA, Way LW. Peritoneovenous shunt for refractory ascites: operative complications and long-term results. Arch Surg 1982;117(05):631–635
23 Reinhold RB, Lokich JJ, Tomashefski J, Costello P. Management of malignant ascites with peritoneovenous shunting. Am J Surg 1983;145(04):455–457

This document was downloaded for personal use only. Unauthorized distribution is strictly prohibited.

 © 2022. Thieme. All rights reserved.