Bronchial Artery Embolization

Claire S. Kaufman, MD[1] Sharon W. Kwan, MD, MS[1]

[1] Dotter Department of Interventional Radiology, Oregon Health & Sciences University, Portland, Oregon

Semin Intervent Radiol 2022;39:210–217

Address for correspondence Claire S. Kaufman, MD, Dotter Department of Interventional Radiology, Oregon Health & Sciences University, Portland, Oregon, 3181 SW Sam Jackson Park Road, Portland, OR 97239-3011 (e-mail: Claire.Kaufman@gmail.com).

Abstract

Massive hemoptysis is a highly morbid medical condition with up to 75% mortality with conservative treatment. Bronchial artery embolization has emerged as the common treatment for both acute massive hemoptysis and chronic hemoptysis. This article will review the clinical presentation, bronchial artery anatomy, embolization procedure, complications, and expected outcomes.

Keywords
- bronchial artery embolization
- embolization
- hemoptysis
- interventional radiology

Massive hemoptysis is a medical condition associated with high morbidity and mortality. Historically there was greater than 75% mortality reported with conservative therapy,[1] with the cause of death usually from asphyxiation, not exsanguination. However, outcomes have improved with advances in bronchoscopy; advances in surgical and endovascular techniques; with mortality rates now ranging from 13 to 17.8%.[2–4]

There is no consensus on the definition of massive hemoptysis, with authors using criteria ranging from 100 to 1,000 mL of expectorated blood in 24 hours.[5–9] The volume of the conducting dead space in the lungs (from trachea to terminal bronchioles) is approximately 150 mL.[10] Therefore, seemingly small volumes of blood can be deadly if not cleared sufficiently. Given the nature of hemoptysis, it can be difficult to quantify the expectorant volume. Recently, there has been a shift to define massive hemoptysis by considering the clinical picture: rate of bleeding, underlying physiologic/respiratory reserve, and ability of the patient to protect their airways.[11]

Bronchial artery embolization (BAE) for the treatment of massive hemoptysis, first described in 1973,[12] has now become common therapy for massive hemoptysis or ongoing chronic hemoptysis.[13] Although BAE is not without risk, it has been shown to be a safe and effective treatment for massive hemoptysis. A recent systematic review found that BAE was successful in 70 to 99% of cases with major complication rates of 0 to 6.6%.[14] Surgery remains a treatment option, but it is associated with high morbidity and mortality. Therefore, surgery is often reserved for specific etiologies: hydatid cyst, bronchial adenoma, and aspergilloma which has failed prior treatment.[15]

Clinical Presentation

Hemoptysis is not uncommon, presenting in 0.1% of ambulatory patients and 0.2% of inpatients; however, most (90%) is minor and self-limited.[16–18] Hemoptysis is seen in approximately 20% of patients with lung cancer. While malignancy can present with massive hemoptysis, it is more commonly persistent, defined as ongoing for more than 2 weeks.[19] Despite thorough clinical workup and evaluation, approximately 7 to 25% of patients have no known etiology for hemoptysis, termed cryptogenic hemoptysis.[20]

Massive hemoptysis has a different clinical trajectory and often requires emergent intervention. Common etiologies of massive hemoptysis vary depending on geographic region but include tuberculosis (TB), fungal infections, pneumonia, malignancy, bronchiectasis, cystic fibrosis, and vascular etiologies such as Rasmussen aneurysm.[1,9] Worldwide, TB is the most common cause of massive hemoptysis.[21]

Patients presenting with massive hemoptysis should first be stabilized, including hemodynamic support, airway protection and intubation, and escalation of level of care as needed. Patient workup should include history with evaluation for an etiology: infection, TB exposure or history, and underlying pulmonary disease. Surgical history and the uses of anticoagulants or antiplatelet medications should be

Issue Theme Thoracic Interventions; Guest Editors, Claire S. Kaufman, MD and Charles E. Ray, Jr., MD, PhD, FSIR

Thieme Medical Publishers, Inc., 333 Seventh Avenue, 18th Floor, New York, NY 10001, USA

DOI https://doi.org/10.1055/s-0042-1751293.
ISSN 0739-9529.

Table 1 Common bronchial artery origins

Type	Percentage	Right	Left
1	40.6	Single vessel originating from the common intercostobronchial trunk	Two vessels originating directly from the aorta
2	21.3	Single vessel originating from the common intercostobronchial trunk	Single vessel originating directly from the aorta
3	20.6	One vessel originating from the common intercostobronchial trunk One vessel originating directly from the aorta	Two vessels originating directly from the aorta
4	9.7	One vessel originating from the common intercostobronchial trunk One vessel originating directly from the aorta	Single vessel originating directly from the aorta

elicited. Blood originating from the nasopharynx or upper gastrointestinal tract should be excluded, as these causes of pseudohemoptysis require a different treatment algorithm altogether.

If possible, the bleeding should be localized. This can be done via computed tomography angiography (CTA) or bronchoscopy, depending on the acuity of the patient and available resources. In the setting of outpatient pulmonology clinics, CTA has been shown to be more efficacious for the localization of bleeding, obviating the need for bronchoscopy in some stable patients or patients with chronic hemoptysis.[19] CTA can also be helpful for delineating the bronchial artery anatomy or origins.

In unstable patients with massive hemoptysis, urgent intubation and bronchoscopy are prudent. The patient should be positioned in the lateral decubitus position with the side of bleeding down to allow for better aeration of the unaffected side. Intubation should be done with a large bore endotracheal tube to allow for bronchoscopy with evacuation of clot and/or balloon occlusion.[22] Selective intubation in the left or right mainstem bronchus can also be performed to aid in the protection of the unaffected side. Additional therapeutic procedures can be performed during bronchoscopy, such as cryoprobe clot extraction, iced saline lavage, epinephrine or norepinephrine administration, endobronchial stent placement, electrocautery, glue, thrombin, or Nd-YAG laser ablation.[1,23–25] While endobronchial therapies can be durable, they are often used as a bridge to stabilize the patient for BAE.

BAE can be performed effectively to treat bleeding in the setting of not only acute massive hemoptysis but also chronic recurrent hemoptysis. The latter are commonly due to cystic fibrosis, bronchiectasis, malignancy, or TB.[26–29]

Anatomy

Conventional

The lungs have dual blood supply from the bronchial arteries and the pulmonary artery. The bronchial arteries traditionally originate directly from the aorta, usually from the level of T3 to T8 with the majority between T5 and T6. On fluoroscopy, this is approximately 1 cm above or below the left main stem bronchus.[30] These vessels are small, receiving approximately 1% of cardiac output. They supply the bronchi, posterior mediastinum, vagus nerve, visceral pleura, aortic and pulmonary artery vasa vasorum, and the middle third of the esophagus.[31–33] There is great variation to bronchial artery anatomy. There are four main configurations described in cadavers by Cauldwell and Siekert (►**Table 1**).[34] Bronchial arteries often arise from a common intercostal artery trunk. These vessels tend to arise more dorsal laterally off the aorta. Alternatively, the bronchial artery can arise alone directly from the aorta, often with a more ventral origin.[35]

Variant Anatomy

Ectopic bronchial arteries, defined as a vessel originating outside of the aortic level of T5 to T6, are very common, with studies reporting up to 56% prevalence (►**Figs. 1** and **2**).[36] The most common site for ectopic bronchial artery is from the underside of the aortic arch.[37,38] Other possible origins include the descending aorta, internal mammary artery, thyrocervical trunk, brachiocephalic artery, subclavian artery, phrenic artery, gastric artery, carotid artery, and even coronary artery.[36,39,40]

Embolization

If available, the interventionalist should review the CTA as part of preprocedural planning to evaluate for location and size of the bronchial arteries. BAE should be performed with sedation, either nurse-administered moderate sedation or with monitored anesthesia support, depending on the clinical scenario. The patient may arrive already intubated from prior bronchoscopy, or to protect the airway. Whether the patient is intubated or not, it is important to have the ability to suspend respirations or have the patients hold their breath to obtain good angiographic imaging in the thorax. Most interventionalists perform BAE utilizing a common femoral artery access. In select cases of anomalous bronchial arteries, such as an origin from the subclavian, thyrocervical trunk, or internal mammary, it may be easier to access the bronchial arteries via a radial artery approach (►**Fig. 2**).

There is controversy in the literature on the need for a flush thoracic aortogram.[9,14] While this can be helpful for identifying the origins of the bronchial arteries, it is less necessary in patients with a preprocedural CTA (►**Figs. 3**

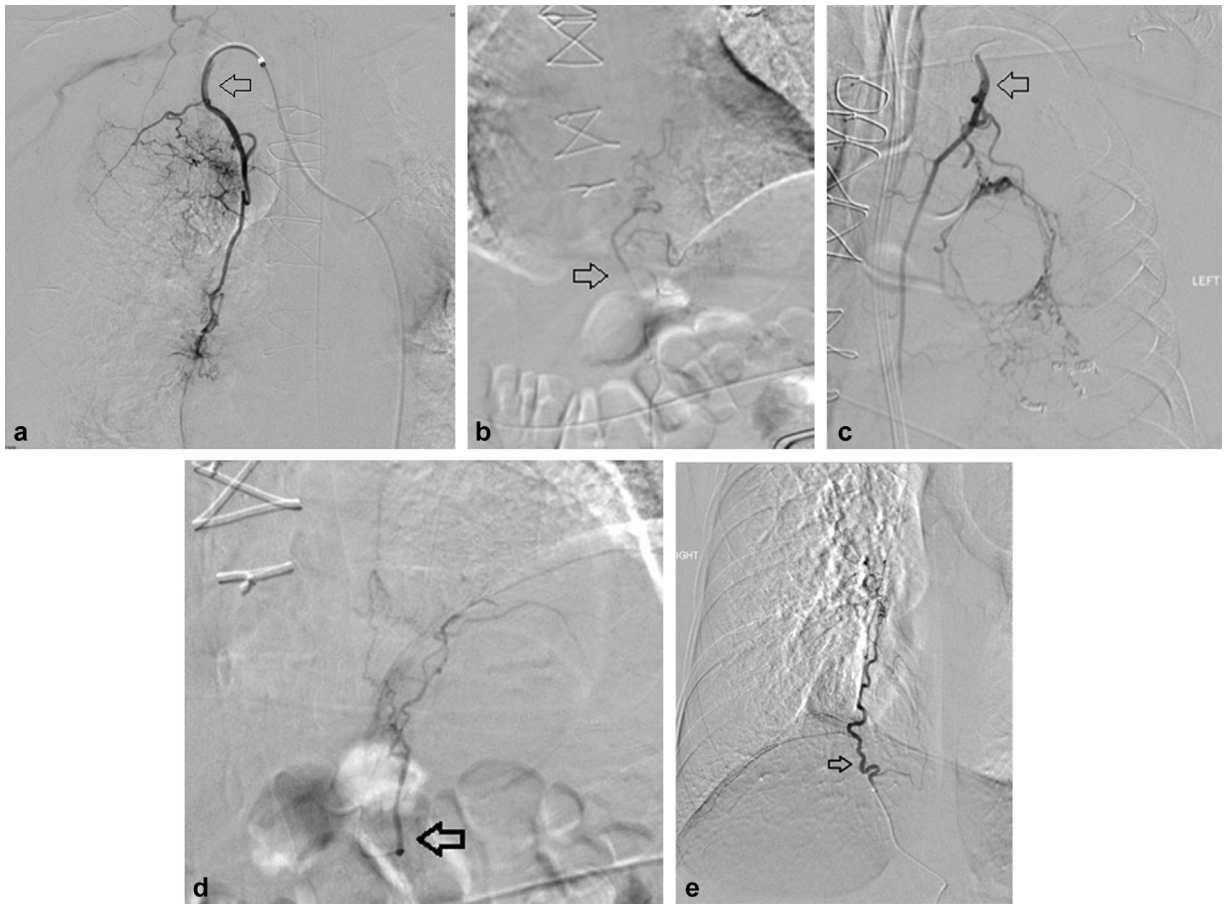

Fig. 1 Ectopic bronchial arteries. (**a**) A 59-year-old man with massive hemoptysis in the setting of recent pulmonary thromboendarterectomy for chronic thromboembolic pulmonary hypertension was found to have multiple ectopic bronchial arteries (shown originating from the right internal mammary artery—arrow). (**b**) An ectopic left bronchial artery originating from the left gastric artery in the same patient. (**c**) The ectopic left bronchial originating from the left internal mammary artery in the same patient. (**d**) An ectopic left bronchial artery from the left phrenic in the same patient (arrow). (**e**) A 26-year-old woman with cystic fibrosis found to have an ectopic right bronchial artery from the right phrenic artery (arrow).

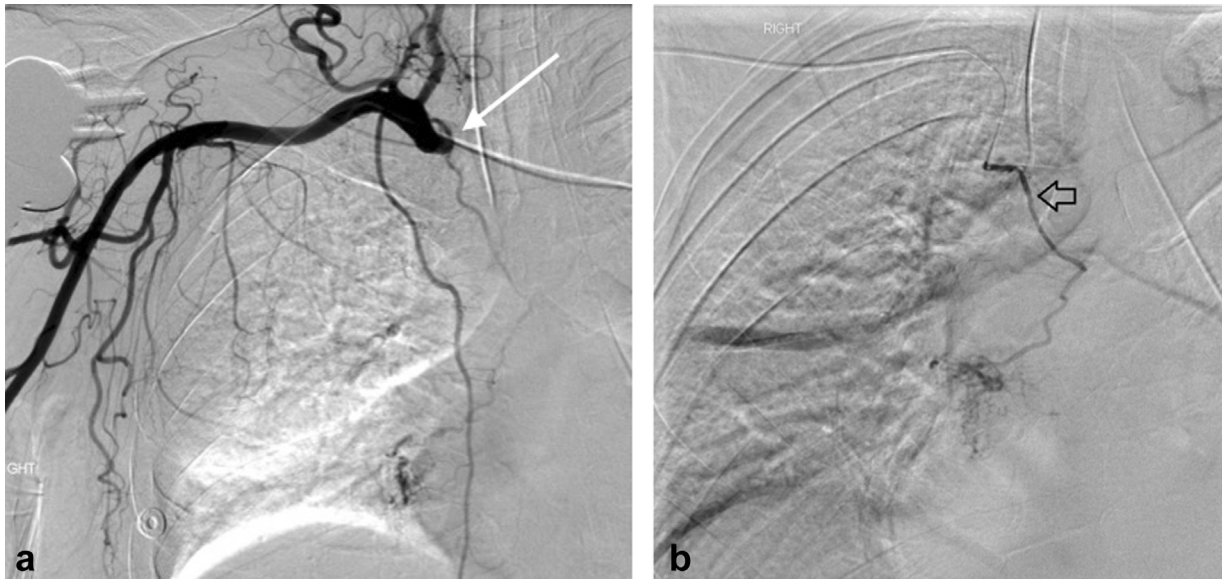

Fig. 2 A 59-year-old man with massive hemoptysis from the right lung. (**a**) The patient was found to have an ectopic right bronchial artery originating from the brachiocephalic artery (arrow). (**b**) Right radial access was subsequently utilized to successfully select and embolize the ectopic bronchial artery (arrow).

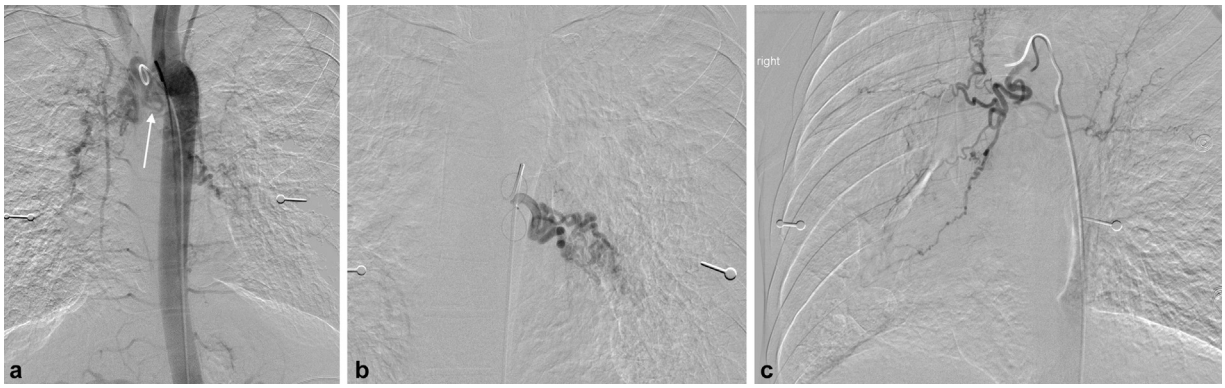

Fig. 3 (**a**) Flush thoracic aortogram demonstrates bilateral hypertrophied bronchial arteries in a 25-year-old man with cystic fibrosis and massive hemoptysis. Note the right bronchial artery has an ectopic origin from the underside of the aortic arch (arrow). (**b**) Selective angiogram of the abnormal, hypertrophied left bronchial artery. (**c**) Selective angiogram of the ectopic right bronchial artery shows a dilated, ectatic vessel with hyperemia.

Fig. 4 Flush aortogram prior to bronchial artery embolization shows bilateral intercostal arteries and an abnormal right bronchial artery with conventional anatomy (arrow).

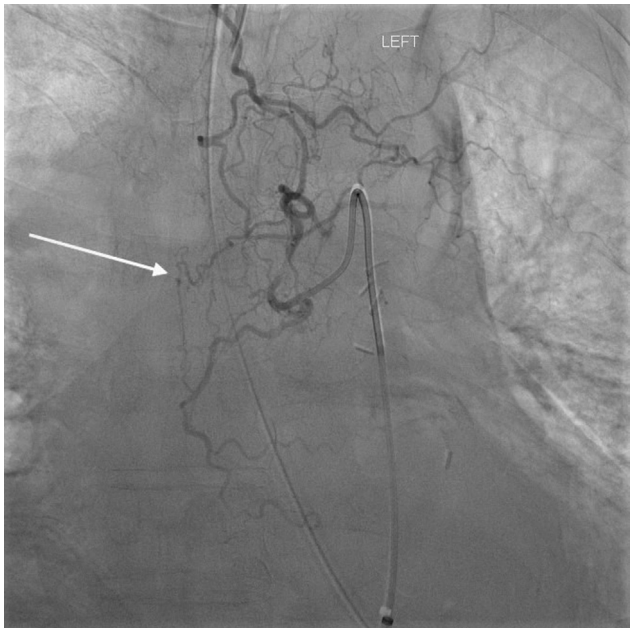

Fig. 5 A 61-year-old man presented with massive hemoptysis with angiogram of the left superior bronchial artery showing opacification of the anterior spinal artery with the characteristic hairpin turn (arrow). No embolization was performed of this vessel.

and **4**). The bronchial artery should then be selected. This is often done using a 4- or 5-Fr Cobra 2-shaped catheter or a reverse curve catheter such as a Simmons 1, Mickelson, or Headhunter. Selective digital subtraction angiography should be performed with special care taken to look for the anterior spinal artery. This vessel has a characteristic hairpin appearance (►**Fig. 5**) and can arise from the common intercostal bronchial trunk.[9] The bronchial artery should subsequently be more selectively catheterized with a microcatheter and wire. Imaging findings on selective angiography for hemoptysis include enlarged hypertrophied arteries, bronchial artery aneurysm, neovascularity, hyperemia, or active extravasation (►**Fig. 6**). It should be noted that active extravasation is not frequently seen and its absence should not preclude embolization.

Numerous embolics have been used for BAE. Gelatin sponge has several benefits including being widely available, easy to use, and inexpensive. However, gelatin sponge embolization will recanalize which can lead to recurrent hemoptysis. A recent study out of Japan comparing BAE with gelatin sponge found recurrence of hemoptysis after 1 year in 62% of pulmonary aspergillosis patients and 28% of patients

Fig. 6 A 41-year-old woman with history of cystic fibrosis presenting with massive hemoptysis. (**a**) CT angiogram reveals enlarged, ectatic bronchial arteries with one origin from the ventral thoracic aorta at the level of the carina (arrow). (**b**) Selective angiogram demonstrates enlarged right and left bronchial arteries with a common origin from the aorta. (**c**) Selective angiogram of the right bronchial artery post-embolization shows pruning of the vasculature.

who underwent BAE for other etiologies.[41] Cases of recanalization and recurrent hemoptysis may necessitate repeat embolization.[42]

Particles are commonly used for BAE. Particles greater than 300 µm in size should be selected to prevent passage of particles through the bronchopulmonary anastomosis, which have a mean diameter of 325 µm. This will decrease the risk of pulmonary infarct and systemic embolization.[9,33] Additionally, larger particles decrease the risk of distal occlusion, which could lead to necrosis of numerous structures fed by the bronchial arteries. Polyvinyl alcohol (PVA) has traditionally been the particle embolic of choice for BAE. The recommended size is at least 300 to 500 µm. If prominent shunting is seen to the pulmonary arterial system, the size of the embolic should be increased (►**Fig. 7**). This is believed to decrease the risk of infarction of the anterior spinal artery as well.[43] Due to its irregular size and shapes, PVA tends to behave similarly with larger sized spherical embolics and can clump in the catheters and vessels, potentially making it difficult to complete embolization. Several studies have shown the more uniform tris-acryl microspheres (Embosphere) to be safe and effective for BAE. Reported sizes ranged from 500 to 700 and 700 to 900 µm with high rates of technical success.[44,45] There are reports of other hydrogel microspheres, such as Embozene, being utilized successfully for BAE.[46] The interventionalist should choose whatever particle embolic they have available and are comfortable using, keeping in mind size parameters to mitigate the risk of ischemic complications or shunting into the pulmonary system.

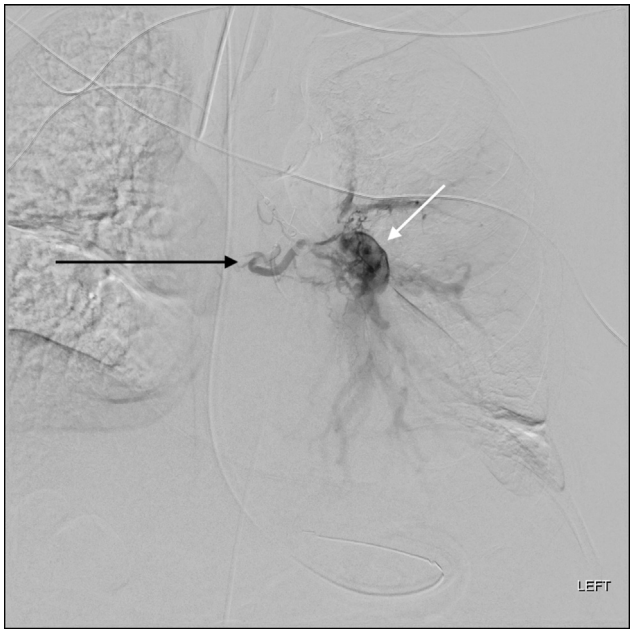

Fig. 7 An 87-year-old man with a history of pulmonary embolism presenting with hemoptysis with angiogram showing significant left bronchial artery (black arrow) to pulmonary artery shunting (white arrow).

The use of liquid embolics has also been described in the BAE literature. A study by Woo et al demonstrated the safety and efficacy of N-butyl-2-cyanoacrylate (NBCA) when compared with PVA. They showed that NBCA embolization resulted in fewer cases of recurrent hemoptysis and found no significant difference in technical success, short-term clinical success, or complications.[47] Similarly, ethylene vinyl alcohol has also been shown to be safe and effective for BAE, with high technical success and low rates of recurrence.[48] Liquid embolics can be technically challenging to use, so should only be used in the bronchial arteries by operators with experience with the agent, given the possible devastating complications of non-target embolization in this location.

Coils are rarely indicated for BAE as proximal embolization will preclude further access to the bronchial arteries if the patient has recurrence of bleeding. However, in the setting of a bronchial artery aneurysm, coils are often the embolic agent of choice and allows for successful occlusion of the aneurysm.[49] Coils have also been used in combination with other embolic agents in the setting of nonbronchial systemic collaterals or shunting.

Complications

While BAE can be a life-saving procedure, it is not without risk of complications. The most common complications are temporary back pain, chest pain, dysphagia, and post-embolic syndrome (fever, leukocytosis, and pain). Vascular

Fig. 8 A 57-year-old man status post-BAE for massive hemoptysis with paralysis. MRI demonstrates the classic high T2 signal "owl-eye appearance" on axial T2-weighted imaging (circle) seen with infarction of the anterior spinal artery. (Image courtesy of Keith Quencer, MD.)

injury can occur at the access site, or at the bronchial artery, resulting in pseudoaneurysm, dissection, or vessel perforation.

The most dreaded complication of BAE is non-target embolization. There are reports of claudication resulting from non-target embolization of particles to the lower extremities.[50,51] Also reported are cases of bronchoesophageal fistula and ischemic colitis.[9] Strokes are very rare but have been reported after BAE.[52–54] This can result from shunting from bronchial arteries to pulmonary veins, or backflow of embolic. While also extremely rare, cortical blindness can also occur via similar mechanisms. While most cases are transient, there is a report of permanent cortical blindness after BAE.[55,56]

Spinal cord ischemia is a well-documented serious complication of BAE and results from inadvertent embolization of the anterior spinal artery (►**Fig. 8**). This can lead to temporary or permanent paralysis with rates reported ranging from 0.19 to 6.5%.[35,57] Given the seriousness of these sequelae, some authors consider visualization of the anterior spinal artery an absolute contraindication to BAE, while others advocate for subselective embolization in this setting. However, just because the interventionalist does not visualize the anterior spinal artery does not mean that the patient is safe; there are reports of paralysis after BAE where the anterior spinal artery cannot be visualized even on retrospective review of imaging.[35,58]

Outcomes

Overall reported technical success rates for BAE range from 81 to 100%.[14] BAE has been shown to be efficacious in specific patient populations. BAE can aid patients with lung cancer and hemoptysis; one study showed a complete clinical success rate of 63.1% and partial clinical success in 19%.[59] It should be noted, however, that patients with lung cancer and hemoptysis have poor overall survival and will often have recurrent hemoptysis. Studies have also shown BAE to be safe and effective in patients with cystic fibrosis. One study showed a 3-year clinical success rate of 75%.[60]

Recurrence can occur even after a technically successful BAE. This can be due to incomplete embolization, recanalization, or recruitment of new collateral vessels. In the setting of malignancy or cystic fibrosis, recurrence can also be due to progression of the underlying disease processes. Several factors have been associated with increased rates of recurrence: lung cancer, non-bronchial systemic collaterals, aspergilloma, reactivation or multidrug-resistant TB, and prominent vascular shunting.[26,58,59,61,62]

Conclusion

Bronchial artery embolization has become mainstay therapy for many patients with both acute massive hemoptysis and chronic hemoptysis from a variety of etiologies. While this procedure can be lifesaving, with high rates of clinical and technical success, recurrence and complications can occur. The interventionalist needs to be familiar with classic and variant anatomy of the bronchial arteries, technical aspects of the procedure, and possible pitfalls and complications.

Conflict of Interest
None declared.

References

1 Davidson K, Shojaee S. Managing massive hemoptysis. Chest 2020;157(01):77–88
2 Lee BR, Yu JY, Ban HJ, et al. Analysis of patients with hemoptysis in a tertiary referral hospital. Tuberc Respir Dis (Seoul) 2012;73(02): 107–114
3 Ong TH, Eng P. Massive hemoptysis requiring intensive care. Intensive Care Med 2003;29(02):317–320
4 Reechaipichitkul W, Latong S. Etiology and treatment outcomes of massive hemoptysis. Southeast Asian J Trop Med Public Health 2005;36(02):474–480
5 Najarian KE, Morris CS. Arterial embolization in the chest. J Thorac Imaging 1998;13(02):93–104
6 Fernando HC, Stein M, Benfield JR, Link DP. Role of bronchial artery embolization in the management of hemoptysis. Arch Surg 1998;133(08):862–866
7 Corey R, Hla KM. Major and massive hemoptysis: reassessment of conservative management. Am J Med Sci 1987;294(05):301–309
8 Amirana M, Frater R, Tirschwell P, Janis M, Bloomberg A, State D. An aggressive surgical approach to significant hemoptysis in patients with pulmonary tuberculosis. Am Rev Respir Dis 1968; 97(02):187–192
9 Yoon W, Kim JK, Kim YH, Chung TW, Kang HK. Bronchial and nonbronchial systemic artery embolization for life-threatening hemoptysis: a comprehensive review. Radiographics 2002;22 (06):1395–1409
10 Patwa A, Shah A. Anatomy and physiology of respiratory system relevant to anaesthesia. Indian J Anaesth 2015;59(09):533–541
11 Radchenko C, Alraiyes AH, Shojaee S. A systematic approach to the management of massive hemoptysis. J Thorac Dis 2017;9 (Suppl 10):S1069–S1086

12 Remy J, Voisin C, Ribet M, et al. [Treatment, by embolization, of severe or repeated hemoptysis associated with systemic hypervascularization]. Nouv Presse Med 1973;2(31):2060
13 Kalva SP. Bronchial artery embolization. Tech Vasc Interv Radiol 2009;12(02):130–138
14 Panda A, Bhalla AS, Goyal A. Bronchial artery embolization in hemoptysis: a systematic review. Diagn Interv Radiol 2017;23 (04):307–317
15 Jean-Baptiste E. Clinical assessment and management of massive hemoptysis. Crit Care Med 2000;28(05):1642–1647
16 Earwood JS, Thompson TD. Hemoptysis: evaluation and management. Am Fam Physician 2015;91(04):243–249
17 Abdulmalak C, Cottenet J, Beltramo G, et al. Haemoptysis in adults: a 5-year study using the French nationwide hospital administrative database. Eur Respir J 2015;46(02):503–511
18 Ittrich H, Bockhorn M, Klose H, Simon M. The diagnosis and treatment of hemoptysis. Dtsch Arztebl Int 2017;114(21): 371–381
19 Arooj P, Bredin E, Henry MT, et al. Bronchoscopy in the investigation of outpatients with hemoptysis at a lung cancer clinic. Respir Med 2018;139:1–5
20 Savale L, Parrot A, Khalil A, et al. Cryptogenic hemoptysis: from a benign to a life-threatening pathologic vascular condition. Am J Respir Crit Care Med 2007;175(11):1181–1185
21 Singh SK, Tiwari KK. Etiology of hemoptysis: a retrospective study from a tertiary care hospital from northern Madhya Pradesh, India. Indian J Tuberc 2016;63(01):44–47
22 Gagnon S, Quigley N, Dutau H, Delage A, Fortin M. Approach to hemoptysis in the modern era. Can Respir J 2017;2017:1565030
23 Sehgal IS, Dhooria S, Agarwal R, Behera D. Use of a flexible cryoprobe for removal of tracheobronchial blood clots. Respir Care 2015;60(07):e128–e131
24 Conlan AA, Hurwitz SS. Management of massive haemoptysis with the rigid bronchoscope and cold saline lavage. Thorax 1980; 35(12):901–904
25 Sakr L, Dutau H. Massive hemoptysis: an update on the role of bronchoscopy in diagnosis and management. Respiration 2010; 80(01):38–58
26 Lee S, Chan JW, Chan SC, et al. Bronchial artery embolisation can be equally safe and effective in the management of chronic recurrent haemoptysis. Hong Kong Med J 2008;14(01):14–20
27 Swanson KL, Johnson CM, Prakash UB, McKusick MA, Andrews JC, Stanson AW. Bronchial artery embolization: experience with 54 patients. Chest 2002;121(03):789–795
28 Dabó H, Gomes R, Marinho A, Madureira M, Paquete J, Morgado P. Bronchial artery embolisation in management of hemoptysis – a retrospective analysis in a tertiary university hospital. Rev Port Pneumol (2006) 2016;22(01):34–38
29 Loiudice G, Catelli A, Corvino A, Quarantelli M, Venetucci P. Endovascular treatment of chronic hemoptysis in patients with pulmonary tuberculosis. Acta Biomed 2021;92(03):e2021201
30 Tanomkiat W, Tanisaro K. Radiographic relationship of the origin of the bronchial arteries to the left main bronchus. J Thorac Imaging 2003;18(01):27–33
31 McCullagh A, Rosenthal M, Wanner A, Hurtado A, Padley S, Bush A. The bronchial circulation – worth a closer look: a review of the relationship between the bronchial vasculature and airway inflammation. Pediatr Pulmonol 2010;45(01):1–13
32 Burke CT, Mauro MA. Bronchial artery embolization. Semin Intervent Radiol 2004;21(01):43–48
33 Sopko DR, Smith TP. Bronchial artery embolization for hemoptysis. Semin Intervent Radiol 2011;28(01):48–62
34 Cauldwell EW, Siekert RG, et al. The bronchial arteries; an anatomic study of 150 human cadavers. Surg Gynecol Obstet 1948;86(04):395–412
35 Brown AC, Ray CE. Anterior spinal cord infarction following bronchial artery embolization. Semin Intervent Radiol 2012;29 (03):241–244
36 Walker CM, Rosado-de-Christenson ML, Martínez-Jiménez S, Kunin JR, Wible BC. Bronchial arteries: anatomy, function, hypertrophy, and anomalies. Radiographics 2015;35(01):32–49
37 Sancho C, Escalante E, Domínguez J, et al. Embolization of bronchial arteries of anomalous origin. Cardiovasc Intervent Radiol 1998;21(04):300–304
38 Hartmann IJ, Remy-Jardin M, Menchini L, Teisseire A, Khalil C, Remy J. Ectopic origin of bronchial arteries: assessment with multidetector helical CT angiography. Eur Radiol 2007;17(08): 1943–1953
39 Loukas M, Hanna M, Chen J, Tubbs RS, Anderson RH. Extracardiac coronary arterial anastomoses. Clin Anat 2011;24(02):137–142
40 Choi WS, Kim MU, Kim HC, Yoon CJ, Lee JH. Variations of bronchial artery origin in 600 patients: systematic analysis with multidetector computed tomography and digital subtraction angiography. Medicine (Baltimore) 2021;100(22):e26001
41 Shimohira M, Ohta K, Nagai K, et al. Bronchial arterial embolization using a gelatin sponge for hemoptysis from pulmonary aspergilloma: comparison with other pulmonary diseases. Emerg Radiol 2019;26(05):501–506
42 Tanaka N, Yamakado K, Murashima S, et al. Superselective bronchial artery embolization for hemoptysis with a coaxial microcatheter system. J Vasc Interv Radiol 1997;8(1, Pt 1):65–70
43 Lorenz J, Sheth D, Patel J. Bronchial artery embolization. Semin Intervent Radiol 2012;29(03):155–160
44 Kucukay F, Topcuoglu OM, Alpar A, Altay CM, Kucukay MB, Ozbulbul NI. Bronchial artery embolization with large sized (700-900 µm) tris-acryl microspheres (Embosphere) for massive hemoptysis: long-term results (clinical research). Cardiovasc Intervent Radiol 2018;41(02):225–230
45 Corr PD. Bronchial artery embolization for life-threatening hemoptysis using tris-acryl microspheres: short-term result. Cardiovasc Intervent Radiol 2005;28(04):439–441
46 Fruchter O, Schneer S, Rusanov V, Belenky A, Kramer MR. Bronchial artery embolization for massive hemoptysis: long-term follow-up. Asian Cardiovasc Thorac Ann 2015;23(01):55–60
47 Woo S, Yoon CJ, Chung JW, et al. Bronchial artery embolization to control hemoptysis: comparison of N-butyl-2-cyanoacrylate and polyvinyl alcohol particles. Radiology 2013;269(02): 594–602
48 Ayx I, Müller-Wille R, Wohlgemuth WA, et al. Treatment of acute hemoptysis by bronchial artery embolization with the liquid embolic agent ethylene vinyl alcohol copolymer. J Vasc Interv Radiol 2017;28(06):825–831
49 San Norberto EM, Urbano García J, Montes JM, Vaquero C. Endovascular treatment of bronchial aneurysms. J Thorac Cardiovasc Surg 2018;156(02):e109–e117
50 Uflacker R, Kaemmerer A, Picon PD, et al. Bronchial artery embolization in the management of hemoptysis: technical aspects and long-term results. Radiology 1985;157(03):637–644
51 Tayal M, Chauhan U, Sharma P, Dev R, Dua R, Kumar S. Bronchial artery embolization. What further we can offer? Wideochir Inne Tech Malo Inwazyjne 2020;15(03):478–487
52 Park JH, Kim DS, Kwon JS, Hwang DH. Posterior circulation stroke after bronchial artery embolization. Neurol Sci 2012;33(04): 923–926
53 Laborda A, Tejero C, Fredes A, Cebrian L, Guelbenzu S, de Gregorio MA. Posterior circulation stroke after bronchial artery embolization. A rare but serious complication. Cardiovasc Intervent Radiol 2013;36(03):860–863
54 Nisar T. A rare case of posterior circulation stroke caused by bronchial artery embolization. J Stroke Cerebrovasc Dis 2018;27 (08):e153–e155
55 Liu SF, Lee TY, Wong SL, Lai YF, Lin AS. Transient cortical blindness: a complication of bronchial artery embolization. Respir Med 1998;92(07):983–986
56 van Doorn CS, De Boo DW, Weersink EJM, van Delden OM, Reekers JA, van Lienden KP. Permanent cortical blindness after bronchial

artery embolization. Cardiovasc Intervent Radiol 2013;36(06): 1686–1689

57 Ishikawa H, Ohbe H, Omachi N, Morita K, Yasunaga H. Spinal cord infarction after bronchial artery embolization for hemoptysis: a nationwide observational study in Japan. Radiology 2021;298 (03):673–679

58 van den Heuvel MM, Els Z, Koegelenberg CF, Naidu KM, Bolliger CT, Diacon AH. Risk factors for recurrence of haemoptysis following bronchial artery embolisation for life-threatening haemoptysis. Int J Tuberc Lung Dis 2007;11(08):909–914

59 Han K, Yoon KW, Kim JH, Kim GM. bronchial artery embolization for hemoptysis in primary lung cancer: a retrospective review of 84 patients. J Vasc Interv Radiol 2019;30(03):428–434

60 Martin LN, Higgins L, Mohabir P, Sze DY, Hofmann LV. Bronchial artery embolization for hemoptysis in cystic fibrosis patients: a 17-year review. J Vasc Interv Radiol 2020;31(02): 331–335

61 Tom LM, Palevsky HI, Holsclaw DS, et al. Recurrent bleeding, survival, and longitudinal pulmonary function following bronchial artery embolization for hemoptysis in a U.S. adult population. J Vasc Interv Radiol 2015;26(12):1806–13.e1

62 Hwang HG, Lee HS, Choi JS, Seo KH, Kim YH, Na JO. Risk factors influencing rebleeding after bronchial artery embolization on the management of hemoptysis associated with pulmonary tuberculosis. Tuberc Respir Dis (Seoul) 2013;74 (03):111–119