



PAIR as a Treatment Option for Isolated Intramuscular Cysticercosis: A Case Report

Shailendra Singh Naik¹  Nisha Das¹ Shraddha Modi² Tirou Aroul²

¹Department of Radiodiagnosis, Mahatma Gandhi Medical College and Research Institute, Puducherry, India

²Department of General Surgery, Mahatma Gandhi Medical College and Research Institute, Puducherry, India

Address for correspondence Shailendra Singh Naik, MBBS, MD, DNB, MNAMS, FVIR, Department of Radiodiagnosis, Mahatma Gandhi Medical College and Research Institute, Puducherry, India (e-mail: Drnayak1388@gmail.com).

J Clin Interv Radiol ISVIR 2023;7:126–130.

Abstract

Keywords

- ▶ *Taenia solium*
- ▶ intramuscular cysticercosis
- ▶ PAIR
- ▶ cysticercus cellulosae

Cysticercosis is a parasitic disease caused by *Taenia solium*. Central nervous system is the most common site of infestation. Other organs infested are subcutaneous tissue, eye, muscle, liver, and lung. Cysticercosis in muscle can occur in three forms: myalgic type, mass-like pseudotumor, and rarely pseudohypertrophic type. Solitary cysticercosis of muscle without involvement of the central nervous system is rare. In this case report, percutaneous-aspiration-injection-reaspiration (PAIR) has been used as a treatment option for isolated intramuscular cysticercosis of the anterior abdominal wall. Interventional radiological management along with medical management was done to observe complete resolution of the cyst.

Introduction

Cysticercosis is a parasitic infection caused by dissemination of the larval form of the pork tapeworm *Taenia solium*.¹ Tapeworm infections are common in developing countries with poor sanitation facilities and close interaction between humans and animals.

Cysts may lodge anywhere in the body but brain, eyes, subcutaneous tissue, and muscles, are more commonly affected.² However, solitary cysticercosis of muscle without involvement of the central nervous system is rare. In contrast to neurocysticercosis, isolated muscle involvement is generally not fatal. In the muscular form, three types of clinical manifestations have been described: the myalgic type; the mass-like, pseudotumor, or abscess-like type; and the rare pseudohypertrophic type.³

Usual management of cysticercosis involves medical management with antihelminthics with steroids as per response assessment. Surgical option is considered whenever medical

management fails, especially in cases of intramuscular cysticercosis.^{4,5}

In our case we are describing about a young female who presented with a painful swelling of the anterior abdominal wall. Clinical, radiological, and laboratory findings were suggestive of an isolated intramuscular cysticercosis. After failure of 6-week medical therapy, we decided to attempt percutaneous-aspiration-injection-reaspiration (PAIR) as an experimental procedure. Fortunately, after 6 weeks post-therapy, the patient's symptoms were relieved with gross reduction in pain and swelling of lesion.

Case Report

A 29-year-old female presented in the surgical outpatient department with a painful swelling in the right lower abdomen complaining for past 2 weeks. There was no constitutional symptom during this period. On physical examination, in the right lumbar region a firm, tender swelling was noted

article published online
July 14, 2022

DOI <https://doi.org/10.1055/s-0042-1751033>.
ISSN 2457-0214.

© 2022. Indian Society of Vascular and Interventional Radiology. All rights reserved.

This is an open access article published by Thieme under the terms of the Creative Commons Attribution-NonDerivative-NonCommercial-License, permitting copying and reproduction so long as the original work is given appropriate credit. Contents may not be used for commercial purposes, or adapted, remixed, transformed or built upon. (<https://creativecommons.org/licenses/by-nc-nd/4.0/>)

Thieme Medical and Scientific Publishers Pvt. Ltd., A-12, 2nd Floor, Sector 2, Noida-201301 UP, India

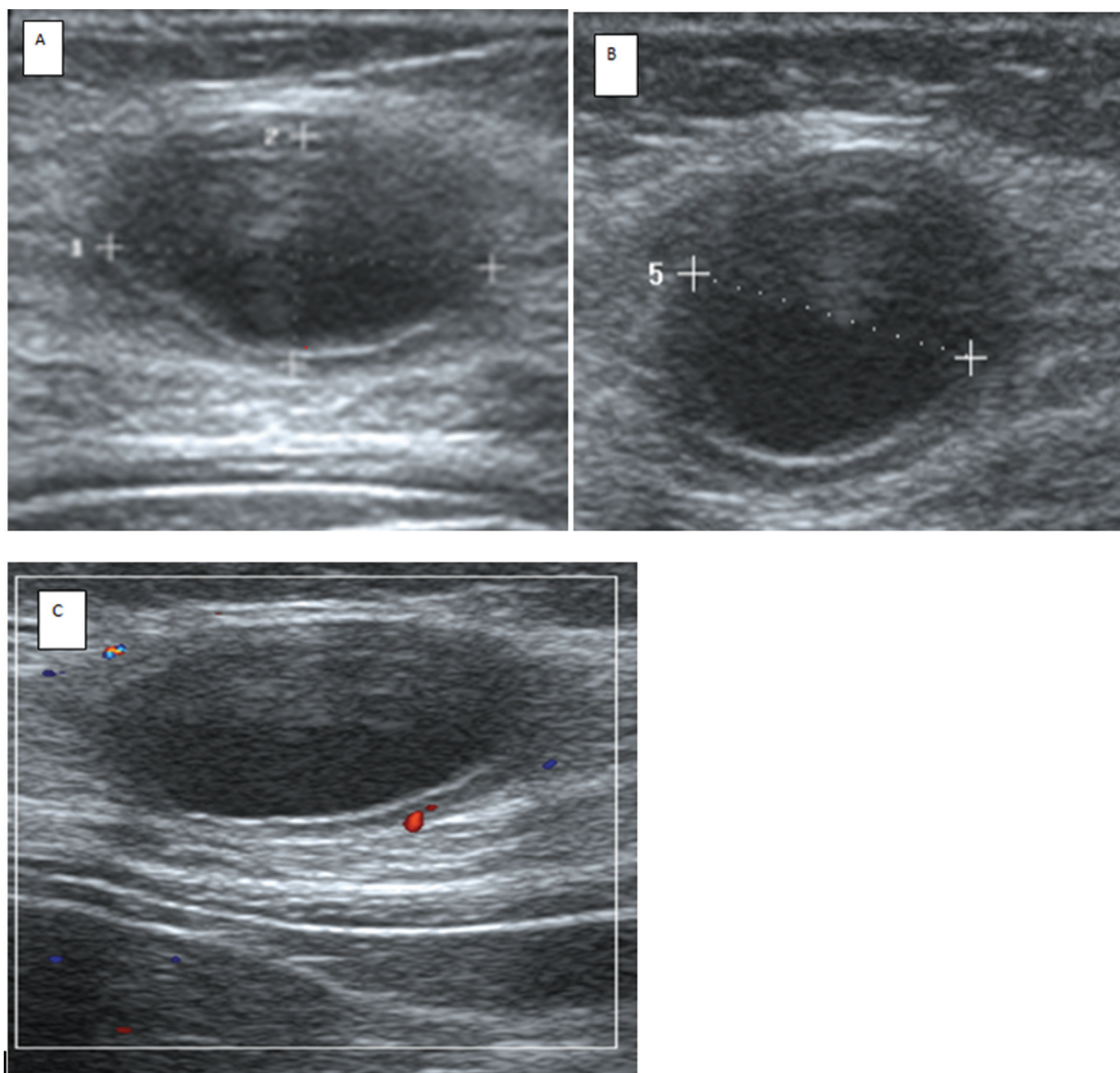


Fig. 1 (A) Longitudinal view on ultrasound reveals a well-defined cystic lesion measuring $\sim 2.6 \times 1.5 \times 1.6$ cm with perceptible wall noted in the intramuscular plane of the right upper quadrant of the anterior abdominal wall. There is no evidence of internal vascularity/echogenic content/calcification within the lesion. (B) Axial section of the same lesion. (C) On color Doppler there is minimal peripheral vascularity.

in the right lumbar quadrant. Ultrasound abdomen revealed a well-defined anechoic lesion in the right anterior abdominal wall with posterior acoustic enhancement, no evidence of calcification within the cyst wall, and no internal vascularity (\rightarrow Fig. 1A–C) or membranes/septae seen. Screening T2-weighted and spectral adiabatic inversion recovery sequence of magnetic resonance imaging abdomen revealed a hyperintense well-defined lesion within the right external oblique muscle (\rightarrow Fig. 2A and B).

Routine laboratory investigations like hemogram, blood counts, and liver function testes were normal. Diagnosis of cysticercosis was confirmed using enzyme-linked immunosorbent assay and serum cysticercosis antibody (immunoglobulin G type): 1.86 titer (normal 0.9).

The patient was managed with oral anthelmintic drug (albendazole [ABZ] 15 mg/kg/day, two doses daily for 4 weeks). There was no apparent reduction in size of the lesion

and patient complaints still persisted. As the patient refused to go ahead with surgery due to financial constraints, subsequently PAIR therapy was offered to her using a 16G needle and 3% hypertonic saline as a scolicial agent under ultrasound (\rightarrow Fig. 3A and B) and fluoroscopic guidance (\rightarrow Fig. 4A and B). The volume of the cyst was calculated (~ 5 –10 mL) and the same volume of hypertonic saline was injected into the cavity. The patient was followed up for 8 weeks after PAIR therapy. The symptoms were relieved by the end of 6 weeks with complete resolution of the swelling both clinically and radiologically (\rightarrow Figs. 5 and 6). No further symptoms recurred till date.

Discussion

PAIR is a noninvasive technique traditionally used only to treat visceral hydatid cysts. It is considered as an alternative

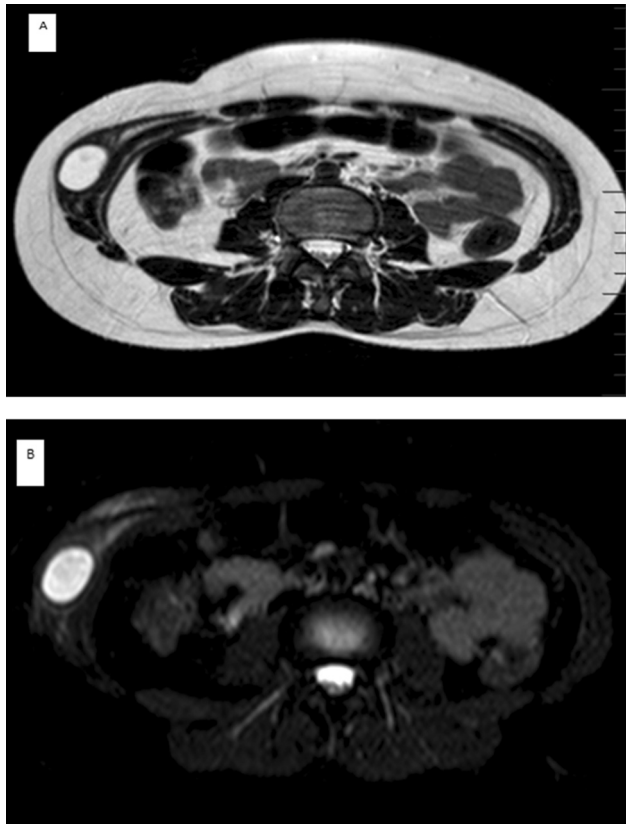


Fig. 2 (A) Axial T2 weighted (T2W) magnetic resonance imaging (MRI) and (B) spectral adiabatic inversion recovery (SPAIR) sequence of the abdomen reveals a well-defined T2 hyperintense lesion measuring $\sim 2.4 \times 1.8$ cm in the right external oblique muscle.

treatment for hydatid disease and is often indicated for patients who do not respond to surgery or medical therapy.^{6,7}

The PAIR procedure can be performed as follows:

1. Ultrasound-guided percutaneous puncture of the cyst.
2. Aspiration of cystic fluid.
3. Injection of a scolicidal solution.
4. Reaspiration of the solution.

To date, many scolicidal agents including some plant extracts, mannitol, ABZ, chlorhexidine gluconate, honey, hypertonic saline, silver nitrate, cetrimide, ethyl alcohol, H₂O₂, and povidone-iodine have been used for inactivation of the hydatid cyst content. Finding a scolicidal agent with fewer side effects, low cost, and higher efficacy are within the discretion of interventional radiologists.⁸

In our study, for a case of isolated intramuscular cysticercosis, we have initiated PAIR therapy as an experimental procedure after the failure of medical management with antihelminthics.⁹ Since both are parasitic infections with a cystic morphology, we tried to initiate PAIR for this case. Fortunately, the patient's symptoms resolved 3 weeks post-therapy with no evidence of any lesion on imaging. The complications involved with the procedure were explained to the patient and consent was obtained. Complications

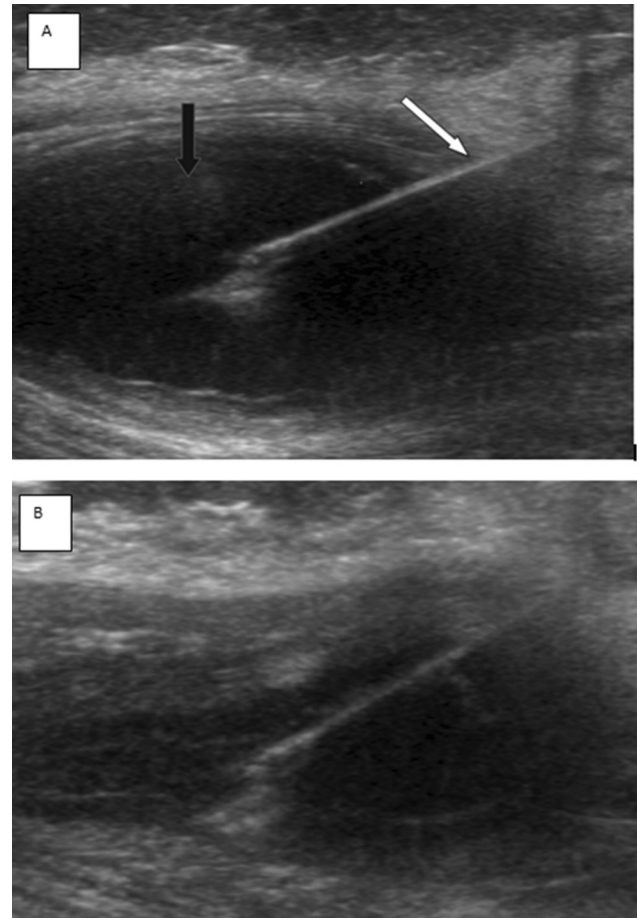


Fig. 3 Needle (white arrow) inside the cyst (black arrow) during the percutaneous-aspiration-injection-reaspiration (PAIR) technique, before aspiration (A) and after aspiration (B).

include anaphylactic shock (rash, bronchial/laryngeal spasm) and spillage of cystic fluid resulting in secondary infection.¹⁰ Precautionary measures in the form of intravenous epinephrine, oxygen, intravenous antihistamines, cortisone, and β agonists like albuterol were arranged in case of emergency.

There are various other treatment modalities for this disease based on location, number, stage, and size of cysts. The most common and well-known treatment for localized intramuscular cysticercosis is surgery. It is also highly recommended to opt for surgical management of disease with there is neurovascular compromise due to growth of cyst. However, surgery is associated with significant morbidity and long hospital stay. Surgical removal may also be associated with rupture of cyst wall causing leakage of antigens and evoking inflammatory response. Minimally invasive methods of treatment such as laparoscopic surgery and percutaneous therapy have the advantage of less morbidity, low cost, and shorter hospital stay. There have been no previous studies where PAIR has been utilized for treatment of cysticercosis. Hence, we have tried to incorporate PAIR with hypertonic saline for our patient, which turned out to be successful.

Medicine has many facets and includes making inventions and discoveries, conducting randomized clinical

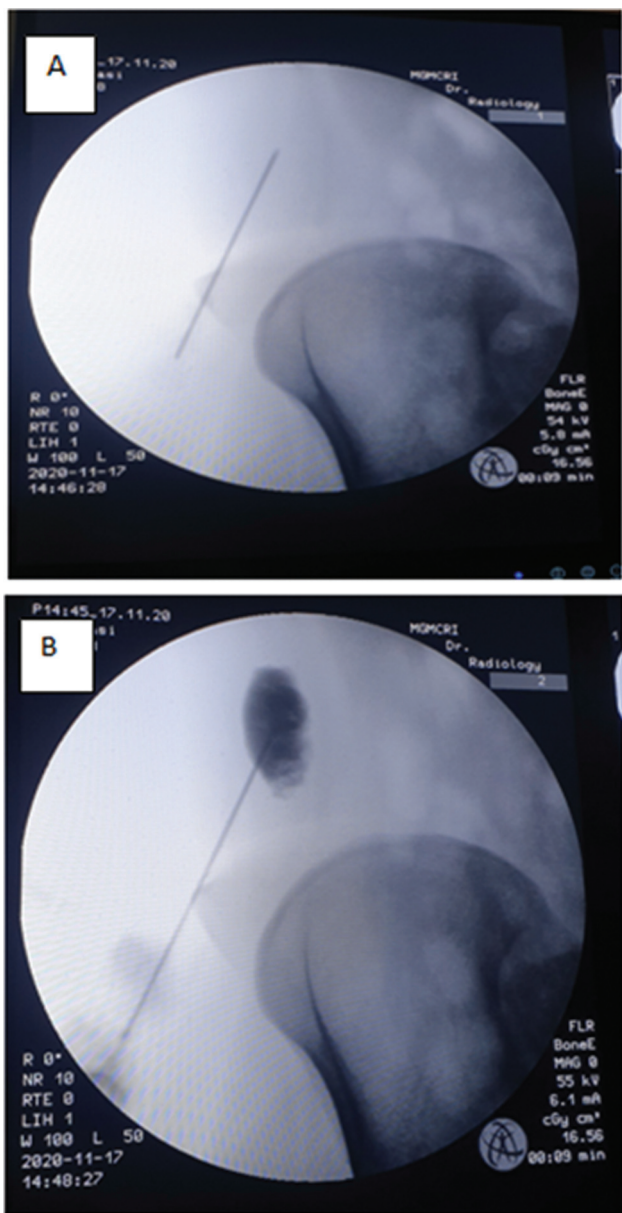


Fig. 4 Fluoroscopic-guided images of percutaneous-aspiration-injection-reaspiration (PAIR) technique before injection of hypertonic saline (A) and after injection (B).

trials, and doing case studies. However, the most difficult studies are those done to break the age-old established dogmas in clinical medicine. For ages, PAIR has been used as a treatment option for hydatid disease. There were no serious allergic reactions, there was no dissemination of disease, all cysts disappeared, and patients became asymptomatic and were cured of disease. Patients were treated without any sedation, stayed in hospital only for 3 hours, and experienced only a single needle prick. In contrast, surgery needed general or local anesthesia and longer hospital stay.⁷ Furthermore, hypertonic saline is one such agent that is easily available and affordable to every patient and hence, we have tried to incorporate the same in our case.

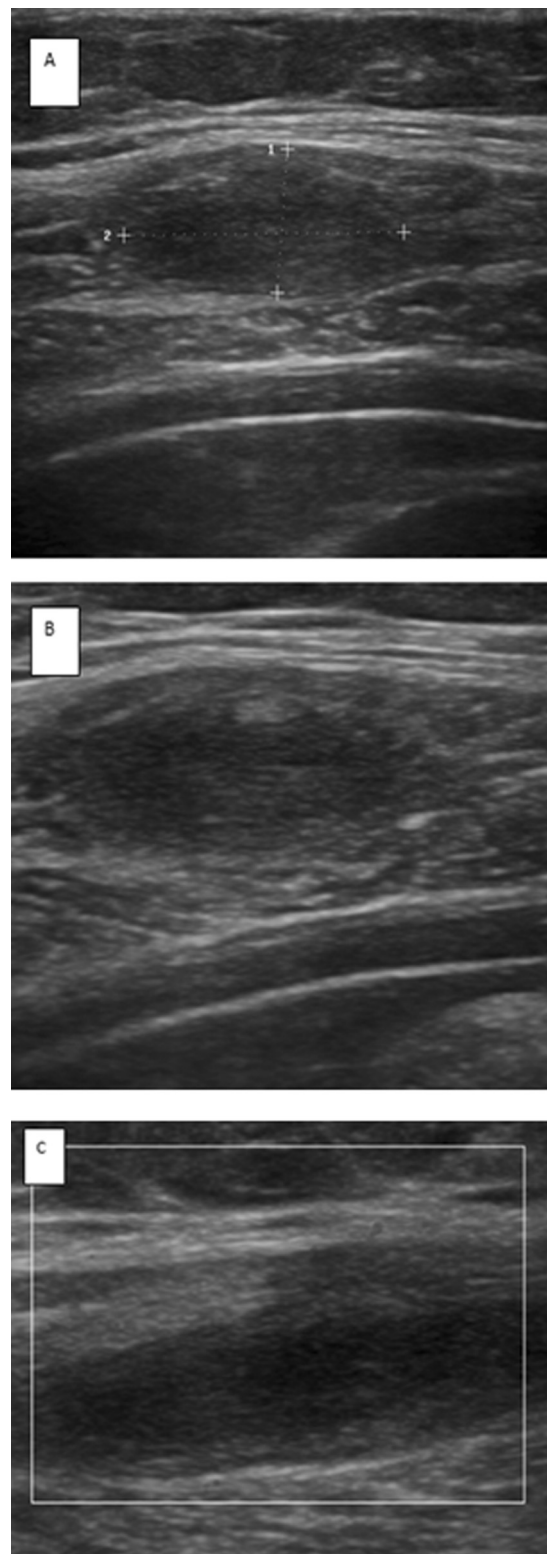


Fig. 5 Ultrasound follow-up image 1 month post-percutaneous-aspiration-injection-reaspiration (PAIR) reveals reduction in size on the lesion, measuring $\sim 1.6 \times 0.7 \times 0.9$ cm on (A) longitudinal section, (B) transverse section, and (C) lesion shows no evidence of vascularity on color Doppler.

Conclusion

Isolated muscular cysticercosis is a rare entity. The essential treatment is medical management with antihelminthic

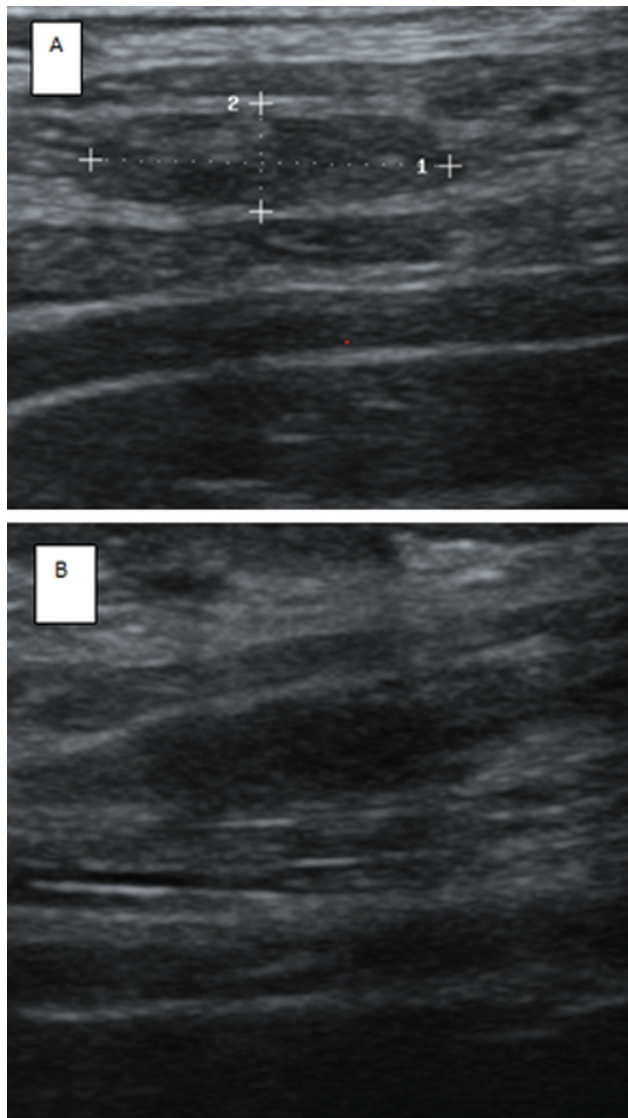


Fig. 6 Ultrasound follow-up image 2 months post-percutaneous-aspiration-injection-reaspiration (PAIR) reveals near-complete resolution of the lesion. Residual lesion measuring $\sim 1.2 \times 0.4 \times 0.3$ cm on (A) longitudinal section and (B) transverse section.

agents. New treatment strategies like PAIR can be used as an option, and surgical excision of the lesion is warranted if no

response is seen after failure of medical management or PAIR. However, in our study, PAIR was successful and complete resolution of the cyst was achieved.

Prior Presentation

Organization: Department of Radiodiagnosis and Department of General Surgery; Place: Mahatma Gandhi Medical College and Research Institute; Date: 11-09-2021.

Conflict of Interest

None declared.

References

- 1 Kanhere S, Bhagat M, Phadke V, George R. Isolated intramuscular cysticercosis: a case report. *Malays J Med Sci* 2015;22(02): 65-68
- 2 Meena D, Gupta M, Jain VK, Arya RK. Isolated intramuscular cysticercosis: Clinicopathological features, diagnosis and management - a review. *J Clin Orthop Trauma* 2016;7(Suppl 2): 243-249
- 3 Singal R, Mittal A, Gupta S, Gupta R, Sahu P, Gupta A. Intramuscular cysticercosis diagnosed on ultrasonography in thigh: a rare case report. *N Am J Med Sci* 2010;2(03):162-164
- 4 Ramraje S, Bhatia V, Goel A. Solitary intramuscular cysticercosis-a report of two cases. *Australas Med J* 2011;4(01):58-60
- 5 Mittal A, Das D, Iyer N, Nagaraj J, Gupta M. Masseter cysticercosis - a rare case diagnosed on ultrasound. *Dentomaxillofac Radiol* 2008;37(02):113-116
- 6 Chopra JS, Nand N, Jain K, Mittal R, Abrol L. Generalized muscular pseudohypertrophy in cysticercosis. *Postgrad Med J* 1986;62 (726):299-300
- 7 Sharafi SM, Sefiddashti RR, Sanei B, Yousefi M, Darani HY. Scolicidal agents for protoscolices of *Echinococcus granulosus* hydatid cyst: review of literature. *J Res Med Sci* 2017;22: 92
- 8 Brunetti E, Kern P, Vuitton DAWriting Panel for the WHO-IWGE. Expert consensus for the diagnosis and treatment of cystic and alveolar echinococcosis in humans. *Acta Trop* 2010;114(01): 1-16
- 9 Smego RA Jr, Bhatti S, Khaliq AA, Beg MA. Percutaneous aspiration-injection-reaspiration drainage plus albendazole or mebendazole for hepatic cystic echinococcosis: a meta-analysis. *Clin Infect Dis* 2003;37(08):1073-1083
- 10 Golemanov B, Grigorov N, Mitova R, et al. Efficacy and safety of PAIR for cystic echinococcosis: experience on a large series of patients from Bulgaria. *Am J Trop Med Hyg* 2011;84(01): 48-51