





# The Current Role of Arthroscopy in Traumatic Wrist Injuries: An Expert Survey

Philip N. d'Ailly, MD<sup>1</sup>  Marjolein A.M. Mulders, MD, PhD<sup>2</sup>  J. Henk Coert, MD, PhD<sup>3</sup>   
Niels W.L. Schep, MD, PhD<sup>1</sup>  Members of IWAS\*

<sup>1</sup> Department of Hand and Trauma Surgery, Maasstad Hospital, Rotterdam, The Netherlands

<sup>2</sup> Department of Trauma Surgery, Amsterdam University Medical Center, Amsterdam, The Netherlands

<sup>3</sup> Department of Plastic and Reconstructive Surgery, University Medical Center Utrecht, Utrecht, The Netherlands

Address for correspondence Philip N. d'Ailly, MD, Maasstad Hospital, Maasstadweg 21, 3079 DZ Rotterdam, The Netherlands (e-mail: philip.dailly@gmail.com; DaillyP@maasstadziekenhuis.nl).

J Wrist Surg 2023;12:192–198.

## Abstract

**Background** Wrist arthroscopy has become increasingly popular for diagnosing and treating traumatic wrist injuries. How wrist arthroscopy has influenced the daily practice of wrist surgeons remains unclear. The objective of this study was to evaluate the role of wrist arthroscopy for the diagnosis and treatment of traumatic wrist injuries among members of the International Wrist Arthroscopy Society (IWAS).

**Methods** An online survey was conducted among IWAS members between August and November 2021 with questions regarding the diagnostic and therapeutic importance of wrist arthroscopy. Questions focused on traumatic injuries of the triangular fibrocartilage complex (TFCC) and scapholunate ligament (SLL). Multiple-choice questions were presented in the form of a Likert scale. The primary outcome was respondent agreement, defined as 80% answering similarly.

**Results** The survey was completed by 211 respondents (39% response rate). The majority (81%) were certified or fellowship-trained wrist surgeons. Most respondents (74%) had performed over 100 wrist arthroscopies. Agreement was reached on 4 of the 22 questions. It was agreed that the outcomes of wrist arthroscopy strongly depend on surgeons' experience, that there is sufficient evidence for the diagnostic purposes of wrist arthroscopy, and that wrist arthroscopy is better than magnetic resonance imaging (MRI) for diagnosing TFCC and SLL injuries. No agreement was reached on the preferred treatment of any type of TFCC or SLL injury.

**Conclusion** There is agreement that wrist arthroscopy is superior to MRI for diagnosing traumatic TFCC and SLL injuries, yet experts remain divided on the optimal management. Guidelines need to be developed for the standardization of indications and procedures.

**Level of Evidence** This is a Level III study.

## Keywords

- ▶ wrist arthroscopy
- ▶ survey
- ▶ IWAS
- ▶ ligaments
- ▶ traumatic wrist injuries
- ▶ TFCC
- ▶ scapholunate

\* For Members of IWAS, please refer ▶ **Supplementary Appendix A.**

received  
May 12, 2022  
accepted  
May 12, 2022  
article published online  
August 1, 2022

© 2022. Thieme. All rights reserved.  
Thieme Medical Publishers, Inc.,  
333 Seventh Avenue, 18th Floor,  
New York, NY 10001, USA

DOI <https://doi.org/10.1055/s-0042-1750875>.  
ISSN 2163-3916.

Following arthroscopy of the knee, shoulder, and elbow, arthroscopy of the wrist was introduced primarily as a diagnostic tool in the mid-1980s.<sup>1</sup> Over recent years, the procedure has become increasingly popular among hand and wrist surgeons for the diagnosis and treatment of traumatic wrist injuries and has found its way to the standard medical care.

Arthroscopy allows for visualization and probing of soft tissue structures of the wrist and has shown higher sensitivity and specificity than magnetic resonance imaging (MRI) or MRI arthrography for diagnosing ligament injuries.<sup>2,3</sup> An advantage of wrist arthroscopy over conventional radiologic imaging is its dynamic nature and the possibility to directly perform therapeutic interventions. Furthermore, wrist arthroscopy has boosted the understanding of carpal anatomy and dynamics.<sup>4-6</sup>

Commonly injured ligamentous structures of the wrist are the triangular fibrocartilage complex (TFCC) and the scapholunate ligament (SLL).<sup>5,7,8</sup> Treatment of these injuries continues to be challenging. Recent studies have shown that arthroscopic repair of TFCC injuries leads to good clinical and patient-related outcomes.<sup>9,10</sup> Likewise, improvement of wrist function has been demonstrated following reconstruction of SLL injuries,<sup>11</sup> for which several arthroscopic suturing and anchoring techniques have been described.<sup>6,12,13</sup>

The number of published papers in PubMed on the topic of wrist arthroscopy has doubled since 2010 and is now well over 2,000. This surge in scientific literature includes reports of arthroscopic techniques, new indications, and clinical outcomes. Large comparative trials on arthroscopic diagnosis and treatment are, however, still lacking. It remains unclear to what extent previous studies have influenced the daily practice of hand and wrist surgeons. Obdeijn et al conducted a survey among members of the European Wrist Arthroscopy Society (EWAS) in 2009 to assess trends in wrist arthroscopy.<sup>14</sup> Respondents had varying qualifications and experience with wrist arthroscopy and reported both advantages and disadvantages. Although their study did not quantify results, it provided a valuable insight into the opinions of experts at that time.

The objective of this study was to evaluate the current opinions and clinical recommendations of members of the International Wrist Arthroscopy Society (IWAS) regarding wrist arthroscopy for the diagnosis and treatment of specific traumatic wrist injuries.

## Methods

### Participants and Survey

Between August 2021 and November 2021, an online survey was conducted among all members of the IWAS per email. The survey was created and distributed using an online survey platform (www.enalyzer.com). Email addresses of IWAS members were obtained from the public official IWAS Web site (www.wristarthroscopy.eu). The invitation was sent on August 23, 2021. Reminders were sent on September 6 and October 28, 2021. The survey closed 80 days after the first invitation.

The survey consisted of 26 questions divided into four sections. The first section explored the respondents' characteristics: highest qualification, year of qualification, country of current employment, total number of wrist arthroscopies performed, number of wrist arthroscopies performed in the last 12 months, and the main purpose for wrist arthroscopy (diagnostic or therapeutic). The second section consisted of seven statements relating to wrist arthroscopy in general. Multiple-choice questions were presented in the form of a 5-choice Likert scale, ranging from "strongly agree" to "strongly disagree." Additionally, respondents could select different topics for future research on wrist arthroscopy. The third section consisted of six statements relating to the diagnostic value of wrist arthroscopy. The fourth section addressed the optimal treatment for nine types of traumatic TFCC and SLL injuries. TFCC injuries were classified according to Palmer.<sup>15</sup> Degenerative TFCC injuries (Palmer 2A-2D) were not included. For peripheral TFCC injuries (Palmer 1B), a distinction was made between a stable or unstable distal radioulnar joint (DRUJ). SLL injuries were classified according to Geissler.<sup>5</sup> The final question of the fourth section was how often wrist arthroscopy was used to confirm fracture reduction after internal fixation of intra-articular distal radius fractures. At the end of each section, there was an open text field for respondents to elaborate on their answers. For the complete questionnaire, please see **► Supplementary Appendix 1** (available in the online version only).

### Outcomes and Statistical Analysis

The primary outcome was agreement on the statements and injury-related questions, which was defined as at least 80% of respondents answering similarly (e.g., "agree" or "strongly agree"). General information of the respondents and multiple choice answers of the respondents were reported using frequencies and proportions. The number of years since certification by the European Board of Hand Surgery (EBHS) or since completion of a fellowship in hand and wrist surgery was reported as a median with an interquartile range (IQR) or a mean with a standard deviation depending on the normal distribution of the data. The country of current employment was categorized into continents. Subgroup analyses were performed between respondents having performed more and less than 100 wrist arthroscopies in their career and between EBHS-certified and non-EBHS-certified respondents. The chi-square exact test was used to compare answers between groups. Values of  $p < 0.05$  were considered significant.

## Results

### Respondents

In total, 544 IWAS members were invited to participate and 211 (39%) completed the survey within the 80-day limit. Twenty-eight respondents (5%) partially completed the survey and were excluded from the analysis. At the time of completion of the survey, most respondents were employed in Europe (79%), followed by France (13%), Spain (11%), and Germany (10%) (**► Table 1**).

**Table 1** Respondents demographics

| Currently working                         |       |
|---|-------|
| Europe                                    | 78.7% |
| South-America                             | 8.5%  |
| Asia                                      | 3.8%  |
| North and Central America                 | 3.8%  |
| Middle East                               | 0.9%  |
| Other                                     | 4.3%  |
| Highest qualification                     |       |
| EBHS-certified hand surgeon               | 36.0% |
| Hand-surgery fellowship                   | 34.6% |
| Non-certified hand surgeon                | 14.7% |
| Orthopaedic surgeon                       | 7.6%  |
| Plastic surgeon                           | 2.8%  |
| Trauma surgeon                            | 2.4%  |
| Resident                                  | 0.5%  |
| Other                                     | 1.4%  |
| Number of WAs performed in career         |       |
| < 20                                      | 3.3%  |
| 20–50                                     | 8.5%  |
| 50–100                                    | 14.7% |
| 100–200                                   | 14.7% |
| > 200                                     | 58.8% |
| Number of WAs performed in past 12 months |       |
| 0   | 0.9%  |
| < 5                                       | 3.8%  |
| 5–10                                      | 9.0%  |
| 10–20                                     | 22.3% |
| 20–50                                     | 33.6% |
| > 50                                      | 30.3% |
| Use of wrist arthroscopy                  |       |
| Mostly diagnostic                         | 10.9% |
| Mostly therapeutic                        | 71.6% |
| Equal                                     | 17.5% |

Abbreviations: EBHS, European Board of Hand Surgery; WA, wrist arthroscopy.

The majority of respondents were certified by the EBHS (36%) or had completed a fellowship in hand and wrist surgery (35%). The median number of years since EBHS certification was 9 (IQR: 4.25–16), and the median number of years since completion of the fellowship was 10 (IQR:5–18). In terms of experience with wrist arthroscopy, a majority had performed over 50 arthroscopies in their career and over 20 in the previous 12 months (►Table 1).

Responses to the survey's general questions (section 2) are shown in ►Fig. 1. Agreement was reached on the statements: "Diagnostic and therapeutic outcomes of wrist arthroscopy following trauma strongly depend on the experience of the

surgeon" and "There is enough evidence regarding wrist arthroscopies for the diagnosis of traumatic injuries." The selected topics of future research on wrist arthroscopy are shown in ►Table 2.

Responses related to the diagnostic value of wrist arthroscopy (section 3) are illustrated in ►Fig. 2. Agreement was reached on the statements: "Wrist arthroscopy is better for diagnosing TFCC injuries than MRI of the wrist" and "Wrist arthroscopy is better for diagnosing SLL injuries than MRI of the wrist." Additional suggestions from the respondents can be found in ►Supplementary Appendix 2 (available in the online version only). Many respondents noted that despite the superiority of wrist arthroscopy for the diagnosis of traumatic ligament injuries, clinical examination and imaging modalities should always be optimized first because surgery can often be averted. Contrarily, several respondents noted that MRI and computed tomography often provide false-negative results and wrist arthroscopy should therefore be considered the gold standard.

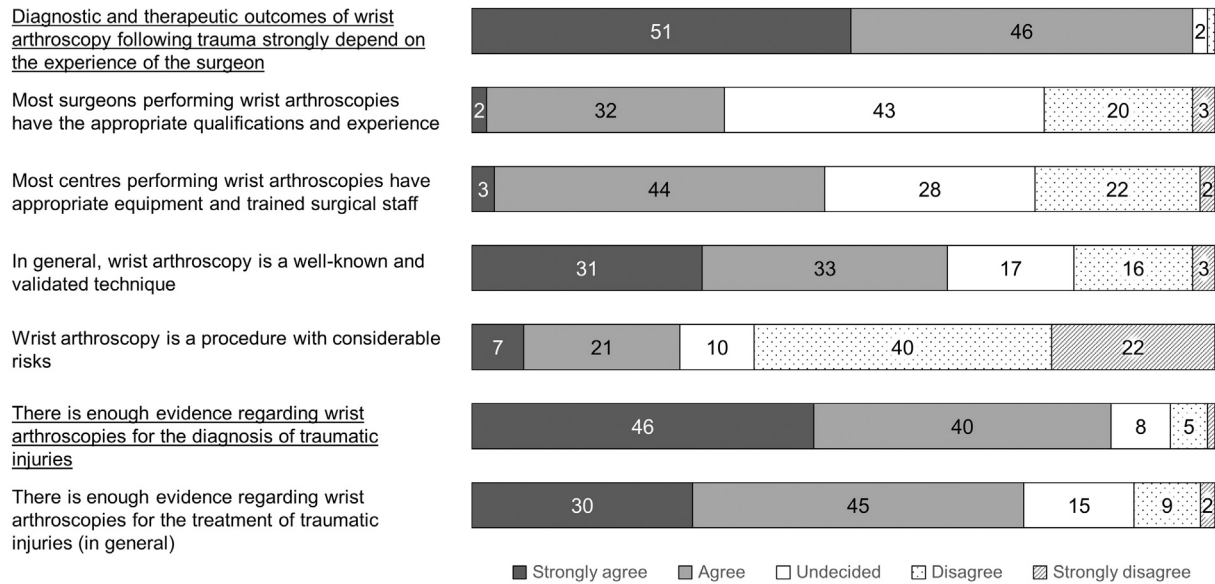
Responses related to the therapeutic value (section 4) are shown in ►Fig. 3. No agreement was reached on the treatment of any of the ligament injuries. For all types of TFCC injuries, arthroscopic treatment (either debridement or repair) was the first choice for most respondents. For grade 3 and 4 SLL lesions, over 80% opted for ligament repair. However, there was no agreement on whether open or arthroscopic repair is superior. In the open field comments, respondents noted that for many injuries wrist arthroscopy is only chosen if the patient remains symptomatic after optimal conservative therapy (►Supplementary Appendix 2, available in the online version only). The number of times wrist arthroscopy is used for confirmation of reduction of distal radius fractures by respondents is illustrated in ►Table 3.

Comparison between surgeons who performed more and surgeons who performed less than 100 wrist arthroscopies in their career showed statistically significant differences for two questions. First, experienced surgeons (with more than 100 arthroscopies) were more likely to choose wrist arthroscopy for the diagnosis of acute, posttraumatic wrist pain. And second, for TFCC lesions with unstable DRUJ, experienced surgeons were more likely to choose arthroscopic repair compared to less experienced surgeons, who had more divided opinions. Responses from EBHS-certified and non-EBHS-certified respondents did not show any statistically significant differences.

## Discussion

This study shows that, while wrist arthroscopies are performed frequently by members of the IWAS, there is still considerable variation in practice and little agreement on the diagnostic and therapeutic values of wrist arthroscopy for traumatic injuries. This variation seems to exist among different levels of experience and qualification.

A previous survey among EWAS members demonstrated a relationship between surgeons' experience and complications of wrist arthroscopy.<sup>16</sup> The threshold for a lower risk of



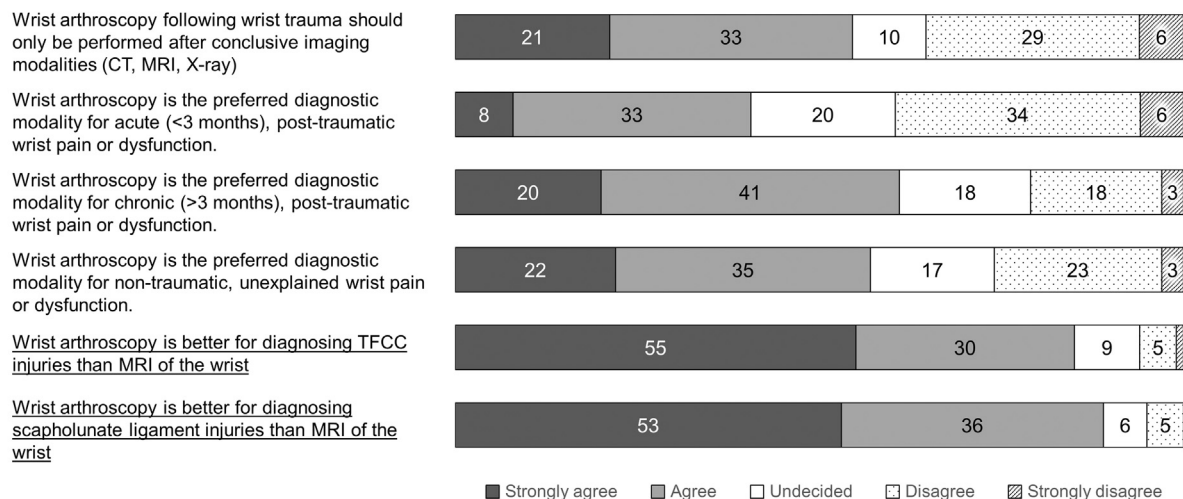
**Fig. 1** General statements regarding wrist arthroscopy. Values in bars are percentages. Underscored: statements with agreement (≥ 80% similar responses).

**Table 2** Suggested topics for future research on wrist arthroscopy

|                                      |       |
|--------------------------------------|-------|
| Ligament injuries                    | 82.5% |
| Chronic wrist pain                   | 66.4% |
| Distal radius fractures              | 45.0% |
| Inflammatory arthritis (synovectomy) | 28.9% |
| Carpsectomies                        | 23.7% |
| Other                                | 6.2%  |

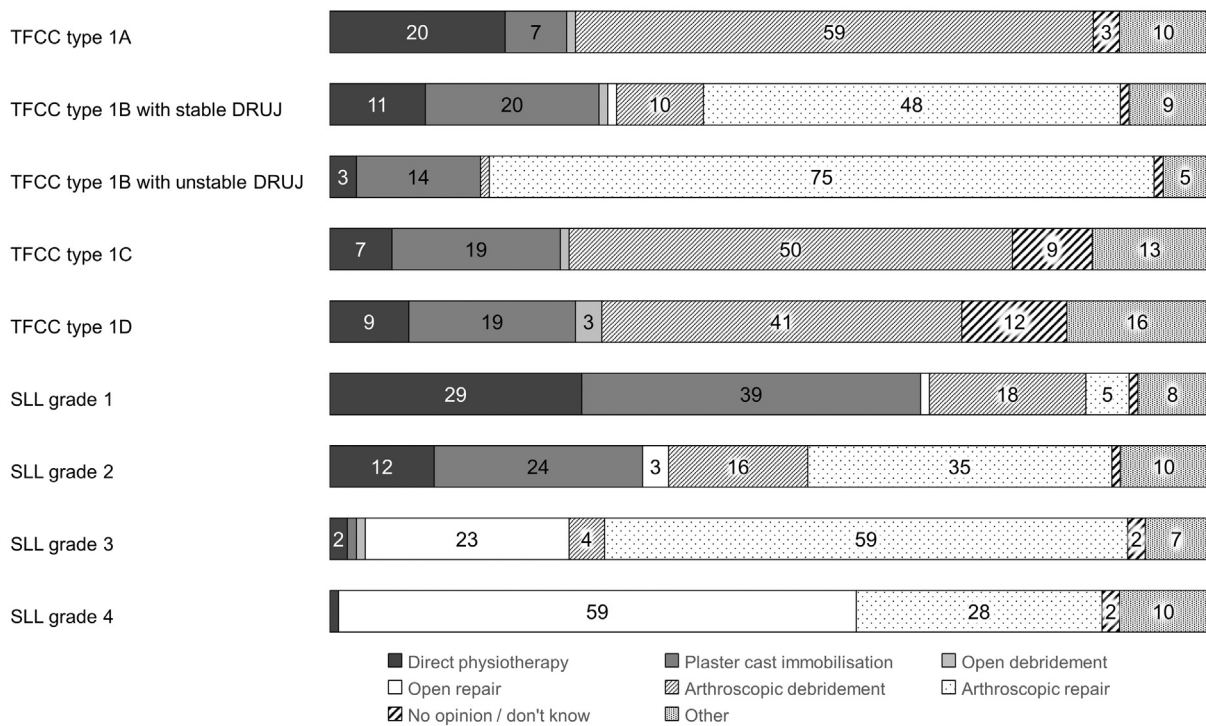
complications was found at approximately 25 wrist arthroscopies per year or more than 5 years of experience with the procedure. Although this was a large study, involving 10,107 wrist arthroscopies, it mainly focused on complications.

Another survey evaluated trends in wrist arthroscopy among EWAS members and members of nine national hand surgery societies.<sup>14</sup> They illustrated a growing popularity for wrist arthroscopies, despite different pros and cons that were mentioned by respondents. In their survey, a minority of respondents considered wrist arthroscopy to be the first choice for diagnostic purposes and a majority regarded it as an adjunct to radiology. In our survey, it was agreed that wrist arthroscopy is better than MRI for diagnosing traumatic TFCC and SLL injuries. Studies have, in fact, demonstrated that the sensitivity of wrist MRI for diagnosing TFCC and SLL injuries lies between 71 and 91% compared with arthroscopy, with little to no advantage for 3.0-T MRI or MR arthrography.<sup>2,3,17</sup> Additionally, a majority of respondents in our survey also preferred wrist arthroscopy for diagnosing



**Fig. 2** Statements regarding the diagnostic value of wrist arthroscopy. Values in bars are percentages. Underscored: statements with agreement (≥80% similar responses). CT, computed tomography; MRI, magnetic resonance imaging; TFCC, triangular fibrocartilage complex.





**Fig. 3** Best treatment option per ligament injury. Values in bars are percentages. Underscored: injuries with agreement (>80% similar responses). TFCC injuries are classified according to Palmer,<sup>15</sup> SLL injuries are classified according to Geissler.<sup>5</sup> DRUJ, distal radioulnar joint; SLL, scapholunate ligament; TFCC, triangular fibrocartilage complex.

chronic posttraumatic wrist pain and unexplained nontraumatic wrist pain. These findings indicate that diagnostic arthroscopy has gained acceptance over the past decade and is regarded as reliable and safe.

There are several factors that can influence the adoption of wrist arthroscopy by surgeons, which include equipment availability, local treatment guidelines, financial limitations, and lack of experience. These factors are crucial in the development of a worldwide consensus. In other words, as long as there are differences in clinical settings, these surveys will always show disagreement to some degree. Nonetheless, there seems to be a growing popularity for wrist arthroscopy, which is also reflected by the increasing number of members of wrist arthroscopy societies and scientific publications.

**Table 3** How often do you perform wrist arthroscopy to confirm fracture reduction of intra-articular distal radius fractures?

|                |       |
|----------------|-------|
| Never          | 16.1% |
| <10% of DRFs   | 31.3% |
| 10–20% of DRFs | 15.2% |
| 20–50% of DRFs | 7.6%  |
| >50% of DRFs   | 10.9% |
| Always         | 10.9% |
| Other          | 8.1%  |

Abbreviation: DRF, distal radius fracture.

### Triangular Fibrocartilage Complex Injuries

Arthroscopic repair was selected most often as the preferred treatment of peripheral TFCC lesions (Palmer type 1B), both for stable and unstable DRUJ (48 and 75%, respectively). DRUJ laxity during clinical examination indicates a lesion of the foveal component of the TFCC. According to the classification by Atzei, these injuries require reattachment of the fovea using transosseous sutures or bone anchors.<sup>4</sup> Earlier studies emphasized that this is best performed with open surgery.<sup>18–21</sup> However, advances in wrist arthroscopy have allowed for all-arthroscopic repair, with good functional outcomes.<sup>9,10</sup> In line with these results, open repair of TFCC 1B lesions was selected by only 1% of respondents in this survey. Different methods for performing TFCC repair were not included in this survey because of the large number and rapid development of new techniques.

### Scapholunate Ligament Injuries

Geissler et al introduced a classification for SLL injuries based on the displacement of the scaphoid and lunate when arthroscopically palpating with a probe.<sup>5</sup> Authors have stated that stage I (i.e., no insertion of the probe is possible) can be treated conservatively, while stage II (i.e., partial insertion is possible) and stage III (i.e., complete insertion is possible) require capsuloligamentous repair, which can be achieved through different arthroscopic techniques.<sup>12,13,22,23</sup> Stage IV (i.e., rotation of the probe is possible), on the contrary, generally requires extensive open fixation by means of pinning, suture anchoring, or ligamentoplasty.<sup>22,24–26</sup> These treatment concepts are reflected by the responses in this survey, although no agreement was reached on the

treatment of any SLL injury type (► Fig. 3). This illustrates the ongoing debate on the management of SLL injuries. Other classifications for SLL injuries have been proposed, which specify on carpal stability, site of the ligament tear, reparability of the SLL, reducibility of the carpal malalignment, and cartilage condition.<sup>24,27,28</sup> For simplification, we decided to use the original classification by Geissler for this survey, which is well understood and implemented.

### Limitations

The limited number of questions in this survey prevented us from exploring other treatment choices. Other indications for wrist arthroscopy such as lunotriquetral ligament injuries, rheumatic synovitis, and scapholunate advanced collapse were also left out of this survey. As the survey was conducted among IWAS members, responses may have been biased toward the use of wrist arthroscopy. Nevertheless, our goal was to evaluate recommendations from hand and wrist surgeons frequently performing wrist arthroscopies. Surveys including non-IWAS surgeons will have to be conducted to investigate differences in opinions. Finally, the predominance of respondents from Europe (78.8%) could be viewed as a limitation because of the possibility of overlap in opinions. The preference for arthroscopy of European hand and wrist surgeons in the treatment of TFCC injuries compared with non-European colleagues has previously been illustrated.<sup>29</sup>

### Conclusion

We conclude that, overall, there is high variability in opinions of IWAS members regarding the value of wrist arthroscopy. There is agreement that wrist arthroscopy is superior to MRI for diagnosing traumatic lesions to the TFCC and SLL, and yet experts remain divided on the optimal management of these injuries. Treatment guidelines, justified by comparative studies, should be developed for the standardization of indications and procedures of wrist arthroscopy.

#### Note

The study was designed and conducted from the Maasstad Hospital in Rotterdam.

#### Ethical Review Approval

Since this study did not involve patients, no approval was necessary from the ethics review board.

#### Funding

None.

#### Conflict of Interest

None declared.

#### Acknowledgments

The authors would like to thank all the members of the International Wrist Arthroscopy Society (IWAS) who participated in this survey.

### References

- 1 Viswanath A, Talwalkar S. Recent advances and future trends in wrist arthroscopy. *J Arthrosc Surg Sport Med* 2020;1(01):65–72
- 2 Magee T. Comparison of 3-T MRI and arthroscopy of intrinsic wrist ligament and TFCC tears. *AJR Am J Roentgenol* 2009;192(01):80–85
- 3 Mahmood A, Fountain J, Vasireddy N, Waseem M. Wrist MRI arthrogram v wrist arthroscopy: what are we finding? *Open Orthop J* 2012;6:194–198
- 4 Atzei A. New trends in arthroscopic management of type 1-B TFCC injuries with DRUJ instability. *J Hand Surg Eur Vol* 2009;34(05):582–591
- 5 Geissler WB, Freeland AE, Savoie FH, McIntyre LW, Whipple TL. Intracarpal soft-tissue lesions associated with an intra-articular fracture of the distal end of the radius. *J Bone Joint Surg Am* 1996;78(03):357–365
- 6 Mathoulin C, Gras M. Role of wrist arthroscopy in scapholunate dissociation. *Orthop Traumatol Surg Res* 2020;106(15):S89–S99
- 7 Yan B, Xu Z, Chen Y, Yin W. Prevalence of triangular fibrocartilage complex injuries in patients with distal radius fractures: a 3.0T magnetic resonance imaging study. *J Int Med Res* 2019;47(08):3648–3655
- 8 Lans J, Lasa A, Chen NC, Jupiter JB. Incidence and functional outcomes of scapholunate diastases associated distal radius fractures: a 2-year follow-up scapholunate dissociation. *Open Orthop J* 2018;12:33–40
- 9 Liu EH, Suen K, Tham SK, Ek ET. Surgical repair of triangular fibrocartilage complex tears: a systematic review. *J Wrist Surg* 2021;10(01):70–83
- 10 Selles CA, d'Ailly PN, Schep NWL. Patient-reported outcomes following arthroscopic triangular fibrocartilage complex repair. *J Wrist Surg* 2020;9(01):58–62
- 11 Wahegaonkar AL, Mathoulin CL. Arthroscopic dorsal capsulo-ligamentous repair in the treatment of chronic scapho-lunate ligament tears. *J Wrist Surg* 2013;2(02):141–148
- 12 Del Piñal F. Arthroscopic volar capsuloligamentous repair. *J Wrist Surg* 2013;2(02):126–128
- 13 Carratalá V, Lucas FJ, Miranda I, Sánchez Alepuz E, González Jofré C. Arthroscopic scapholunate capsuloligamentous repair: suture with dorsal capsular reinforcement for scapholunate ligament lesion. *Arthrosc Tech* 2017;6(01):e113–e120
- 14 Obdeijn MC, Tuijthof GJ, van der Horst CM, Mathoulin C, Liverneaux P. Trends in wrist arthroscopy. *J Wrist Surg* 2013;2(03):239–246
- 15 Palmer AK. Triangular fibrocartilage complex lesions: a classification. *J Hand Surg Am* 1989;14(04):594–606
- 16 Leclercq C, Mathoulin C. Members of EWAS. Complications of wrist arthroscopy: a multicenter study based on 10,107 arthroscopies. *J Wrist Surg* 2016;5(04):320–326
- 17 Boer BC, Vestering M, van Raak SM, van Kooten EO, Huis In 't Veld R, Vochteloo AJH. MR arthrography is slightly more accurate than conventional MRI in detecting TFCC lesions of the wrist. *Eur J Orthop Surg Traumatol* 2018;28(08):1549–1553
- 18 Adams BD, Berger RA. An anatomic reconstruction of the distal radioulnar ligaments for posttraumatic distal radioulnar joint instability. *J Hand Surg Am* 2002;27(02):243–251
- 19 Garcia-Elias M, Smith DE, Llusá M. Surgical approach to the triangular fibrocartilage complex. *Tech Hand Up Extrem Surg* 2003;7(04):134–140
- 20 Kleinman WB. Stability of the distal radioulnar joint: biomechanics, pathophysiology, physical diagnosis, and restoration of function what we have learned in 25 years. *J Hand Surg Am* 2007;32(07):1086–1106
- 21 Murray D, Javed S, Hayton M. Mini dorsal incision to the triangular fibrocartilage complex: a new surgical approach. *Hand (N Y)* 2015;10(04):717–720

- 22 Geissler WB. Arthroscopic management of scapholunate instability. *J Wrist Surg* 2013;2(02):129–135
- 23 Mathoulin CL. Indications, techniques, and outcomes of arthroscopic repair of scapholunate ligament and triangular fibrocartilage complex. *J Hand Surg Eur Vol* 2017;42(06):551–566
- 24 Garcia-Elias M, Lluch AL, Stanley JK. Three-ligament tenodesis for the treatment of scapholunate dissociation: indications and surgical technique. *J Hand Surg Am* 2006;31(01):125–134
- 25 Ho PC, Wong CW, Tse WL. Arthroscopic-assisted combined dorsal and volar scapholunate ligament reconstruction with tendon graft for chronic SL instability. *J Wrist Surg* 2015;4(04):252–263
- 26 Brunelli GA, Brunelli GR. [A new surgical technique for carpal instability with scapho-lunar dislocation. (Eleven cases)]. *Ann Chir Main Memb Super* 1995;14(4-5):207–213
- 27 Dreant N, Dautel G. [Development of a arthroscopic severity score for scapholunate instability]. *Chir Main* 2003;22(02):90–94
- 28 Messina JC, Van Overstraeten L, Luchetti R, Fairplay T, Mathoulin CL. The EWAS classification of scapholunate tears: an anatomical arthroscopic study. *J Wrist Surg* 2013;2(02):105–109
- 29 Saito T, Sterbenz JM, Chung KC. Chronologic and geographic trends of triangular fibrocartilage complex repair. *Hand Clin* 2017;33(04):593–605