



# A Case of Plasma Cell Myeloma with Multilobated and Monocytoid Morphology

Sneha Kakoty<sup>1</sup> Anurag Saha<sup>1</sup> Torsha Jana<sup>1</sup> Jyoti Sawhney<sup>1</sup>

<sup>1</sup>Department of Oncopathology, The Gujarat Cancer & Research Institute, Ahmedabad, Gujarat, India

Asian J Oncol 2022;8:172–174.

Address for correspondence Jyoti Sawhney, MD, DM, Department of Oncopathology, The Gujarat Cancer & Research Institute, Ahmedabad, Gujarat, 380016, India (e-mail: jyoti.sawhney@gcriindia.org).

## Abstract

Plasma cell myeloma (PCM) accounts for approximately 1% of malignant tumors and 10 to 15% of hematological neoplasms. It is a malignant disease characterized by abnormal proliferation of plasma cells and monoclonal immunoglobulins or free light chains (FLCs). There are many morphological variations of the myeloma plasma cells which include mature, immature, plasmablastic, and pleomorphic types. Here, we report a rare presentation of PCM with normal serum protein electrophoresis but elevated serum FLCs and having convoluted, multilobated, and monocytoid morphology. This type of morphology is related to an aggressive clinical course and resistance to conventional chemotherapy. Moreover, absence of M protein in serum/urine electrophoresis does not rule out the diagnosis of PCM and serum FLC assays plays an important role in this kind of scenarios.

## Keywords

- ▶ light chain myeloma
- ▶ monocytoid
- ▶ multilobated

## Introduction

Plasma cell myeloma (PCM) accounts for approximately 1% of malignant tumors and 10 to 15% of hematological neoplasms.<sup>1</sup> Bone marrow studies are performed for confirmation of diagnosis, even when the clinical, laboratory, and radiological findings are evident. There are many morphological variations of the myeloma plasma cells which include mature, immature, plasmablastic, and pleomorphic types. Approximately 2% of myelomas are distinguished by marked nuclear lobation and convolutions.<sup>2</sup> We report a case of PCM, that presented with convoluted, multilobated, and monocytoid nuclei, without detectable myeloma protein in the serum or urine and had a very aggressive clinical course.

## Case Presentation

A 43-year-old lady presented with back pain and generalized weakness. Physical examination revealed pallor. Laboratory

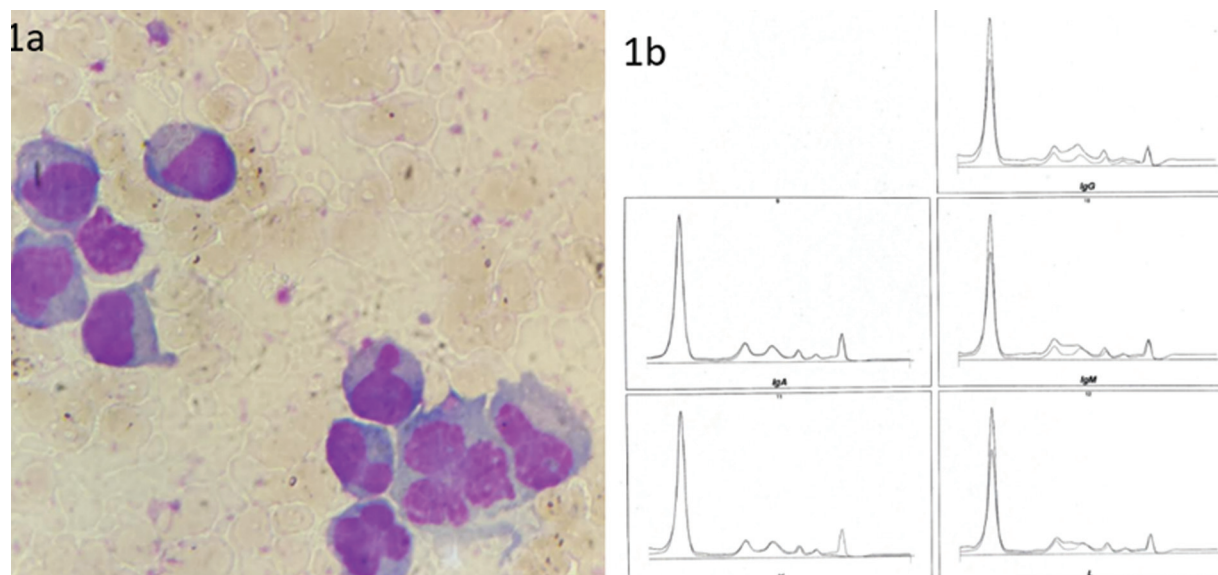
results are shown in ▶Table 1. X-ray pelvis with both hips showed few well-defined lytic lesions with nonsclerotic margins in bilateral innominate bones and upper end of both femurs. Bone marrow aspiration was done and it showed increased plasma cells (20%) showing mature and immature plasma cells with convolution and multilobation (▶Fig. 1A). Bone marrow biopsy also showed features of PCM. Following which the myeloma workup was done and results are shown in ▶Table 1. No M band was detected on serum protein electrophoresis. Serum immunofixation showed only kappa light chain (▶Fig. 1B). Free light chain assay showed increased free kappa light chain and free kappa-to-lambda chain ratio. Hence, a diagnosis of light chain multiple myeloma (LCMM) was made and the patient received combined chemotherapy of bortezomib, lenalidomide, and dexamethasone. After completion of chemotherapy at the end of 4 months, laboratory tests and other relevant investigations were repeated and the findings are shown in ▶Table 1. Bone marrow aspiration and biopsy

DOI <https://doi.org/10.1055/s-0042-1750793>.  
ISSN 2454-6798.

© 2022. Spring Hope Cancer Foundation & Young Oncologist Group of Asia. All rights reserved.

This is an open access article published by Thieme under the terms of the Creative Commons Attribution-NonDerivative-NonCommercial-License, permitting copying and reproduction so long as the original work is given appropriate credit. Contents may not be used for commercial purposes, or adapted, remixed, transformed or built upon. (<https://creativecommons.org/licenses/by-nc-nd/4.0/>)

Thieme Medical and Scientific Publishers Pvt. Ltd., A-12, 2nd Floor, Sector 2, Noida-201301 UP, India



**Fig. 1** (A) Bone marrow aspirate showing convoluted, multilobulated, and monocytoid plasma cells. May-Grunwald-Giemsa stain (MGG)  $\times 100$ . (B) Serum immunofixation showing kappa light chain only.

showed 90% plasma cells with marked pleomorphism showing convoluted and multilobulated morphology and diffuse sheets of highly pleomorphic plasma cells, respectively. She was given the option for bone marrow trans-

plantation but due to monetary issues she opted for combined chemotherapy (pomalidomide, carfilzomib, and dexamethasone). She was followed up to 7 months and was alive till last follow-up.

**Table 1** Basic laboratory and myeloma workup results

	First visit	After 4 months
HB	9.4 g/dL	7 g/dL
WBC	$5.2 \times 10^3/\mu\text{L}$	$4.59 \times 10^3/\mu\text{L}$
Platelet	$30 \times 10^3/\mu\text{L}$	$14 \times 10^3/\mu\text{L}$
Serum calcium	7.89 mg/dL	6.8 mg/dL
Serum creatinine	0.77 mg/dL	0.7 mg/dL
Beta-2 microglobulin	4.32 mg/dL	3.49 mg/L
Serum total protein	5.52 g/dL	5.49 g/dL
Serum albumin	3.10 g/dL	2.4 g/dL
Serum globulin	2.42 g/dL	3.09 g/dL
Alpha 1 globulin	0.43 g/dL	0.7 g/dL
Alpha 2 globulin	1.04 g/dL	1.6 g/dL
Beta 1 globulin	0.49 g/dL	0.4 g/dL
Beta 2 globulin	0.21 g/dL	0.2 g/dL
Gamma globulin	0.25 g/dL	0.2 g/dL
Albumin:Globulin ratio	1.28	0.76
M band on serum electrophoresis	Not detected.	Not detected
Serum immunofixation	Kappa chain detected	Kappa chain detected
Serum IgA level, by nephelometry	32 mg/dL	43 mg/dL
Serum IgG level, by nephelometry	300 mg/dL	597 mg/dL
Serum IgM level, by nephelometry	7 mg/dL	15 mg/dL
Free kappa (light chain)	144 mg/dL	196 mg/dL
Free lambda (light chain)	1.5 mg/dL	44 mg/dL
Free kappa/lambda light chain ratio	96	4.45

Abbreviations: HB, hemoglobin; Ig, immunoglobulin; WBC, white blood cell.

## Discussion

PCM is a bone marrow-based, multifocal plasma cell neoplasm associated with a M protein in serum or urine.<sup>3</sup> Various morphological subtypes are present. In the current case, bone marrow showed cleaved and multilobulated plasma cells; however, the lady did not show any M protein on immunoelectrophoresis. Nonsecretory myeloma is a rare subgroup of PCM which accounts for 3% of all PCM.<sup>3</sup> In these cases, the plasma cells fail to secrete immunoglobulin and no serum/urine M protein was found. In two-thirds of these cases, elevated serum free light chains or an abnormal free light chain ratio is observed.<sup>4</sup> Serum free light chain assays in our case revealed elevated free light chains and she was diagnosed with LCMM. LCMM is the third most common type of PCM and carries a grim prognosis.<sup>5</sup> Moreover, plasma cells from PCM patients showing irregular nuclei indicate more advanced stage of the disease and worse prognosis.<sup>6</sup> PCM with multinucleated plasma cells is a rare morphological variant, which usually presents with light chain expression and is characterized by an aggressive course and resistance to conventional chemotherapy.<sup>7</sup> The lady in our case had relapsed myeloma activity after six cycles of combined bortezomib-based chemotherapy. Patients with active myeloma are often given a combination of two or three drugs. Often, a combined drug therapy containing bortezomib, lenalidomide, and dexamethasone is used. There are also many regimes for previously treated PCM according to the National Comprehensive Cancer Network guidelines, version 7, 2021. Molecular diagnostics play an important role to predict the prognosis. The negative prognostic impact of specific immunoglobulin heavy chain (IgH) translocations such as t(4;14), t(14;16), chromosome 13 deletion by conventional cytogenetics, and loss of 17p13 by interphase fluorescence in situ hybridization are now established.<sup>8</sup>

## Conclusion

This case was presented due to its unique morphology which was found in the context of LCMM. Further genetic studies are required to show the association of IgH or p53 mutation with this sort of morphology, aggressive clinical course, and resistance to conventional chemotherapy.

### Conflict of Interest

None declared.

## References

- 1 Sheik N, Variganji SK, Inugati VR, et al. Clinico-hematological profile of multiple myeloma in a teaching hospital - a 2 year study. *IP Arch Cytol Histopathol Res* 2019;4(04):305-309
- 2 Elkins BN. Neoplasia. In: Kaplan LA, Pesce AJ, eds. *Clinical Chemistry: Theory, Analysis, Correlation*. 5th ed. Missouri: Mosby Elsevier; 2010:1051-1067
- 3 Swerdlow SH, Campo E, Harris NL, et al. *WHO Classification of Tumours of Haematopoietic and Lymphoid Tissues*. Revised 4th ed. Lyon, France: IARC Press; 2017
- 4 Drayson M, Tang LX, Drew R, Mead GP, Carr-Smith H, Bradwell AR. Serum free light-chain measurements for identifying and monitoring patients with nonsecretory multiple myeloma. *Blood* 2001;97(09):2900-2902
- 5 Zhang JJ, Sun WJ, Huang ZX, et al. Light chain multiple myeloma, clinic features, responses to therapy and survival in a long-term study. *World J Surg Oncol* 2014;12:234
- 6 Seili-Bekafigo I, Valković T, Babarović E, Duletić-Naćinović A, Jonjić N. Myeloma cell morphology and morphometry in correlation with clinical stages and survival. *Diagn Cytopathol* 2013;41(11):947-954
- 7 Erkut N, Çobanoğlu Ü, Sönmez M. Multiple myeloma with multilobated plasma cell nuclei. *Turk J Haematol* 2011;28(02):158-159
- 8 Stewart AK, Fonseca R. Prognostic and therapeutic significance of myeloma genetics and gene expression profiling. *J Clin Oncol* 2005;23(26):6339-6344