




# Radiology Technologists Performing Peritoneal Drainage, Local Experience

Ibraheem Aljediea<sup>1</sup> Mustafa Fleet<sup>1</sup> Mohammed Alshehri<sup>1</sup> Khaled Alenazi<sup>1</sup> Amr Memesh<sup>1</sup>

<sup>1</sup>Department of Interventional Radiology, Johns Hopkins Aramco Healthcare, Dhahran, Saudi Arabia

Address for correspondence Ibraheem Aljediea, BSc, MHA, Department of Interventional Radiology, Johns Hopkins Aramco Healthcare, Dhahran, Saudi Arabia (e-mail: ksaibraheem@yahoo.com).

Arab J Intervent Radiol 2022;6:37–40.

## Abstract

### Keywords

- ▶ ascites
- ▶ interventional radiology technologist
- ▶ interventional radiology technologists prevailing
- ▶ paracentesis
- ▶ peritoneal drainage
- ▶ sonography
- ▶ ultrasound

**Purpose** We conducted this study to review our experience of peritoneal drainages (paracentesis) performed by interventional radiology technologists.

**Materials and Methods** This is a retrospective study of peritoneal drainages performed by interventional radiology technologists.

**Results** We reviewed all peritoneal drainages performed in interventional radiology between November 2018 and November 2021. The review process included success rate, volume drained, catheter duration, and complications.

**Conclusion** Interventional radiology technologists can safely perform ultrasound-guided peritoneal drainages. Extending Interventional radiology technologists' role to perform ultrasound-guided peritoneal drainages allows interventional radiologists to do more complex procedures, enhances the workflow, and increases the efficiency of the interventional radiology team.

## Introduction

One of the early nonguided peritoneal drainage techniques used a 14-gauge 2-part needle to obtain access to the peritoneal cavity, then inserted a polyethylene catheter through the needle after removing the inner part of the needle. Later on, smaller gauge needles were used.<sup>1,2</sup> The drainage catheter can be inserted over a guidewire with angled and Z-technique access.<sup>3</sup>

Nonultrasound-guided peritoneal drainages can lead to significant complications such as hemorrhage and bowel perforation.<sup>4</sup> The ultrasound-guided technique has a significantly low hemorrhage rate.<sup>5</sup> Nonphysicians can perform large volume peritoneal drainage safely in outpatient set-

ting.<sup>6</sup> Interventional radiology can be enhanced and become more efficient by extending the interventional radiology technologists' roles to perform peritoneal drainages after completing training and proctorship. The training programs should include practical training supplemented by simulator-based training.<sup>7–10</sup>

In Saudi Arabia, there are no academic programs offering physician/radiologist assistants training and qualifications.<sup>11</sup> Local training programs similar to the radiologist assistants' programs in the United States can be established. This study evaluates our experience with local training and performance of interventional radiology technologists in ultrasound-guided peritoneal drainages.

published online  
June 14, 2022

DOI <https://doi.org/10.1055/s-0042-1750107>.  
ISSN 2542-7075.

© 2022. The Pan Arab Interventional Radiology Society. All rights reserved.

This is an open access article published by Thieme under the terms of the Creative Commons Attribution-NonDerivative-NonCommercial-License, permitting copying and reproduction so long as the original work is given appropriate credit. Contents may not be used for commercial purposes, or adapted, remixed, transformed or built upon. (<https://creativecommons.org/licenses/by-nc-nd/4.0/>)

Thieme Medical and Scientific Publishers Pvt. Ltd., A-12, 2nd Floor, Sector 2, Noida-201301 UP, India

### Materials and Method

Following hospital ethical committee approval, we started a training program for interventional technologists to perform ultrasound-guided peritoneal drainages. Three Interventional Radiologists supervised the training and proctorship program. Four interventional radiology technologists enrolled in the program, they had 5, 9, 19, and 22 years of experience in the field. Each technologist was proctored in the first 30 procedures. The procedures were performed in the interventional radiology ultrasound procedure room. The technologists check the procedure request in the electronic medical record, do the preprocedure checklist, consent the patient and perform the procedure. The interventional radiologist checks the postprocedure ultrasound images and reports the study in the electronic medical record.

The procedures were performed using the ultrasound machine (General Electric LOGIQ E9, Diagnostx, Benjamin center, Florida, United States). Access was performed using Seldinger technique with 18-gauge, 7-cm long needle (Cook Medical, Bloomington, Indiana, United States). Standard 0.035 inches diameter, 80-cm long guidewires were used (Merit, 1600 West Merit Parkway South Jordan, Utah, United States). The catheters used are 6-French (BARD Navarre catheters, Becton Drive Franklin Lakes, New Jersey, United States). In patients with viscous fluid, 8- or 10-French catheters were used (Cook Medical, Bloomington, Indiana, United States).

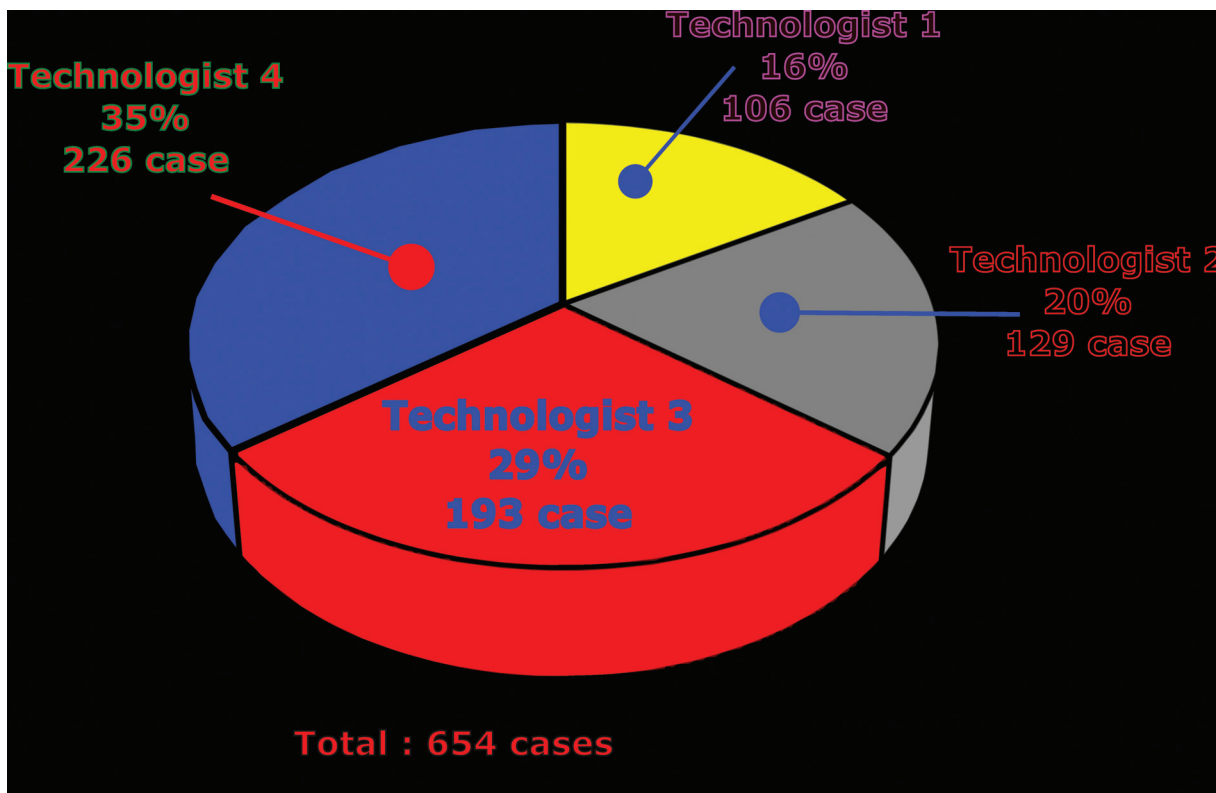
An initial ultrasound scan was performed to check the fluid volume/distribution within the peritoneal cavity and select the catheter insertion site. It also evaluates the abdominal wall for any blood vessels, masses, or hernias at the access site. The skin is prepared and draped. Under ultrasound guidance, local anesthetic (xylocaine 1%) is used, and a small skin incision is made. The puncture needle is advanced under real-time ultrasound guidance. After confirming the needle tip position within the fluid, the guidewire is introduced, and the needle is removed. The drainage catheter is advanced over the guidewire. An ultrasound image showing the catheter within the fluid is captured and sent to the Picture Archiving and Communication system (PACS). The catheters are removed after draining the fluid. The amount of fluid drained and the time of catheter removal is documented in the patient chart.

### Results

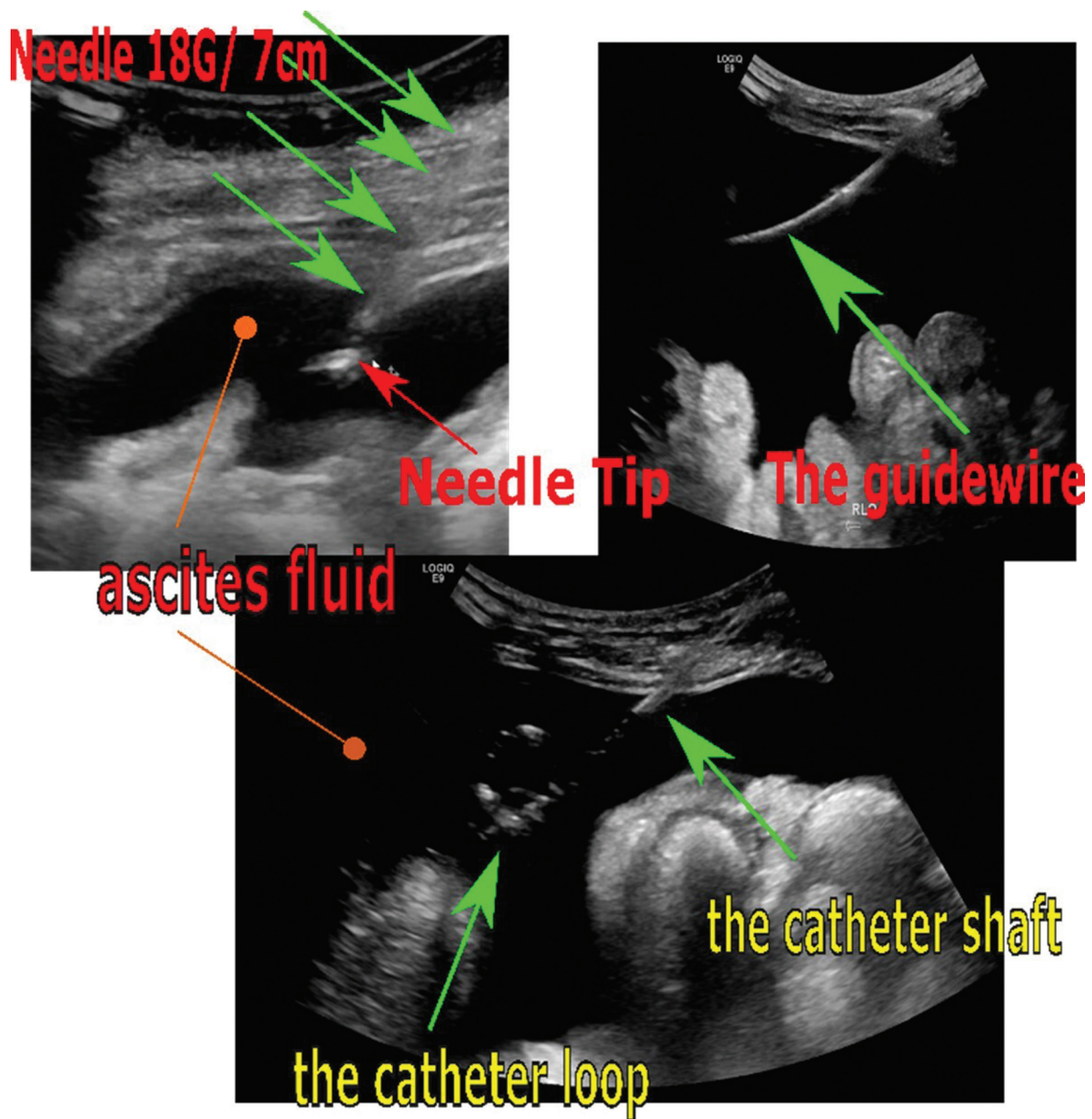
Between November 2018 and November 2021, 654 peritoneal drainage procedures were performed in 204 patients (114 females and 90 males). The age distribution is between 1.6 and 92 years. The number of procedures performed by each technologist is presented in **Fig. 1**. The fluid volume drained ranges between 10 cc (diagnostic peritoneal tap) to 43 L. No complications occurred.

### Discussion

The Advantages of ultrasound guidance for peritoneal drainages include localization of fluid, estimating the fluid



**Fig. 1** The number of procedures performed by each technologist.



**Fig. 2** The ultrasound real-time to visualize the needle and the catheter during peritoneal drainage.

volume, determining the access site, and evaluates the abdominal wall for any blood vessels, masses, or hernias. Ultrasound-guided peritoneal drainages have fewer complications and lower costs.<sup>12,13</sup> It reduces complications by avoiding organs such as the liver, spleen, and bowels during insertion. Real-time ultrasound can visualize the entire procedure from needle puncture until positioning the catheter within the fluid (→ Fig. 2). Visualizing the access needle in real-time can be challenging and requires practice and experience.<sup>14</sup> The linear transducer can be helpful if the needle is not visualized using the curvilinear probe.<sup>15</sup>

Interventional radiology faces challenges such as providing services in rural hospitals.<sup>16,17</sup> Extending the role of interventional technologists will help provide some interventional procedures, such as Peripherally Inserted Central

Catheter (PICC) line insertion and peritoneal drainages in hospitals, that have no interventional radiologists. It also allows the interventional radiologists to do more nonprocedural activities such as interventional radiology clinics and consultations. This will help reverse the misconception that radiologists are highly specialized technologists.<sup>18,19</sup> In the United States, between 1993 and 2008, there was a significant increase in the nonprocedural claims for interventional radiologists.<sup>20</sup> The utilization of advanced practice providers, nurse practitioners, and physician assistants improves patient satisfaction, as they can offer more time to patients' education and answer their concerns.<sup>21,22</sup>

The cost saving can be up to 57% when nonphysician performs peritoneal drainage mainly because of less physician time spent in those cases.<sup>23</sup> Radiologist's assistants

reduce interruptions that maximize the radiologist's efficiency and increase the economic benefit for hospitals and radiology departments.<sup>24</sup>

## Conclusion

Our experience suggests that interventional radiology technologists can be locally trained and safely perform ultrasound-guided peritoneal drainages. This extended role enhances team efficiency and improves access to care.

### Conflict of Interest

None declared.

## References

- 1 Strickler JH, Erwin PD, Rice CO. Diagnostic paracentesis. *AMA Arch Surg* 1958;77(06):859–863
- 2 Runyon BA. Paracentesis of ascitic fluid. A safe procedure. *Arch Intern Med* 1986;146(11):2259–2261
- 3 Lee SY, Pormento JG, Koong HN. Abdominal paracentesis and thoracocentesis. *Surg Laparosc Endosc Percutan Tech* 2009;19(02):e32–e35
- 4 Mallory A, Schaefer JW. Complications of diagnostic paracentesis in patients with liver disease. *JAMA* 1978;239(07):628–630
- 5 Rowley MW, Agarwal S, Seetharam AB, Hirsch KS. Real-time ultrasound-guided paracentesis by radiologists: near zero risk of hemorrhage without correction of coagulopathy. *J Vasc Interv Radiol* 2019;30(02):259–264
- 6 Grabau CM, Crago SF, Hoff LK, et al. Performance standards for therapeutic abdominal paracentesis. *Hepatology* 2004;40(02):484–488
- 7 Barsuk JH, Cohen ER, Vozenilek JA, O'Connor LM, McGaghie WC, Wayne DB. Simulation-based education with mastery learning improves paracentesis skills. *J Grad Med Educ* 2012;4(01):23–27
- 8 Echenique A, Wempe EP. Simulation-based training of the nurse practitioner in interventional radiology. *Tech Vasc Interv Radiol* 2019;22(01):26–31
- 9 Sall D, Wigger GW, Kinnear B, Kelleher M, Warm E, O'Toole JK. Paracentesis simulation: a comprehensive approach to procedural education. *MedEdPORTAL* 2018;14:10747
- 10 Tejos R, Chahuán J, Uslar T, et al. Simulated training program in abdominal paracentesis for undergraduate medical students. *Gastroenterol Hepatol* 2019;42(04):239–247
- 11 Saudi Commission For Health Specialties. Accessed April 22, 2022 at: <https://www.scfhs.org.sa/en/Pages/default.aspx>
- 12 Bard C, Lafortune M, Breton G. Ascites: ultrasound guidance or blind paracentesis? *CMAJ* 1986;135(03):209–210
- 13 Patel PA, Ernst FR, Gunnarsson CL. Evaluation of hospital complications and costs associated with using ultrasound guidance during abdominal paracentesis procedures. *J Med Econ* 2012;15(01):1–7
- 14 Millington SJ, Koenig S. Better with ultrasound: paracentesis. *Chest* 2018;154(01):177–184
- 15 Ennis J, et al. Ultrasound for detection of ascites and for guidance of the paracentesis procedure: technique and review of the literature. *Int J Clin Med* 2014;5:1277
- 16 Cook PS. The challenges of providing interventional radiology services to rural and smaller community hospitals. *Am J Roentgenol* 2018;211(04):744–747
- 17 Al Zahrani YA, Arabi M, Almoaiqeel M. The status of vascular and interventional radiology training: the Saudi experience. *Arab J Interv Radiol* 2019;3:42–43
- 18 Shlomovitz E, Amaral JG, Chait PG. Image-guided therapy and minimally invasive surgery in children: a merging future. *Pediatr Radiol* 2006;36(05):398–404
- 19 Esteves SC, Cho C-L, Majzoub A, Agarwal A. *Varicocele and Male Infertility. A Complete Guide*. Switzerland, AG: Springer International Publishing; 2019
- 20 Duszak R Jr, Borst RF. Clinical services by interventional radiologists: perspectives from Medicare claims over 15 years. *J Am Coll Radiol* 2010;7(12):931–936
- 21 Smith WL Jr, Applegate KE. The likely effects of radiologist extenders on radiology training. *J Am Coll Radiol* 2004;1(06):402–404
- 22 Chivinge A, et al. Implementing a nurse-led paracentesis service to improve patient care and experience in a day case unit. *Gastrointest Nurs* 2015;13:S11–S15
- 23 Gilani N, Patel N, Gerkin RD, Ramirez FC, Tharalson EE, Patel K. The safety and feasibility of large volume paracentesis performed by an experienced nurse practitioner. *Ann Hepatol* 2009;8(04):359–363
- 24 Ellenbogen PH. The radiologist assistant: best new thing since sliced bread or Trojan horse? *Radiology* 2008;248(01):4–7