Article published online: 2022-06-14

Lipiodol Lymphangiography and Glue Embolization for Vulvar and Vaginal Lymphorrhea

Meshari Alali[1,*] Rohee Park[2,*] Ji H. Shin[2] Chengshi Chen[3] Jeoung I. Shin[2]

[1] Department of Radiology, Majmaah University, Almajmaah, Saudi Arabia
[2] Department of Radiology and Research Institute of Radiology, University of Ulsan, College of Medicine, Asan Medical Center, Seoul, Korea
[3] Department of Radiology, The Affiliated Cancer Hospital of Zhengzhou University, Zhengzhou, China

Address for correspondence Ji H. Shin, MD, Department of Radiology and Research Institute of Radiology, University of Ulsan, College of Medicine, Asan Medical Center, Olympic-ro 43-gil, Songpa-gu, Seoul 05505, Korea (e-mail: jhshin@amc.seoul.kr).

Arab J Intervent Radiol 2022;6:47–49.

Abstract

A 26-year-old woman patient had an 18-year long history of vulvar and vaginal lymphorrhea and multiple millet-like lesions on her vulva. On magnetic resonance image, multiple T2 high signal intensities were noted at the bilateral vulvar areas and pelvic cavity. Conventional lipiodol lymphangiography showed lymphatic reflux to the vulvar areas, possibly originating from prominent tubular lymphatics in the right lower abdominal wall. After percutaneous puncture of this tubular lymphatic structure, its distal portion was embolized using microcoils to prevent upward glue propagation; this was followed by glue embolization of the tubular lymphatic structure. The patient was without skin lesions or symptoms at follow-up of 1 year after the procedure.

Keywords
- vaginal discharge
- lymphangiography
- therapeutic embolization

Introduction

Lymphorrhea is an uncommon but potentially serious complication that occurs after surgical lymphatic injury or in chronic lymphedema. It is usually associated with abnormalities of lymphatic circulation with backflow, rupture, and extravasation of the lymphatic fluid,[1] and its clinical presentation and severity varies according to the size and site of the lymphatic flow abnormality. Among the many types of lymphorrhea, vulvar and/or vaginal lymphorrhea is a rare event of lymphatic reflux.[1,2]

For conservative management of refractory lymphorrhea, interventional techniques, such as lymphangiography and adjunctive embolization, have been shown to be safe and effective.[3,4] Most reported lymphorrhea, treated with interventional techniques, includes chylothorax or chylous ascites, and vulvar and/or vaginal lymphorrhea have not been reported so far. Here, we reported the successful results of conventional lipiodol lymphangiography and adjunctive embolization for a patient with vulvar and vaginal lymphorrhea.

Case Report

A 26-year-old female patient was referred for the evaluation of vulvar and vaginal lymphorrhea. She had an 18-year

[*] *M.A. and R.P. contributed equally to this work.*

published online
June 14, 2022

DOI https://doi.org/10.1055/s-0042-1750106.
ISSN 2542-7075.

© 2022. The Pan Arab Interventional Radiology Society. All rights reserved.
This is an open access article published by Thieme under the terms of the Creative Commons Attribution-NonDerivative-NonCommercial-License, permitting copying and reproduction so long as the original work is given appropriate credit. Contents may not be used for commercial purposes, or adapted, remixed, transformed or built upon. (https://creativecommons.org/licenses/by-nc-nd/4.0/)
Thieme Medical and Scientific Publishers Pvt. Ltd., A-12, 2nd Floor, Sector 2, Noida-201301 UP, India

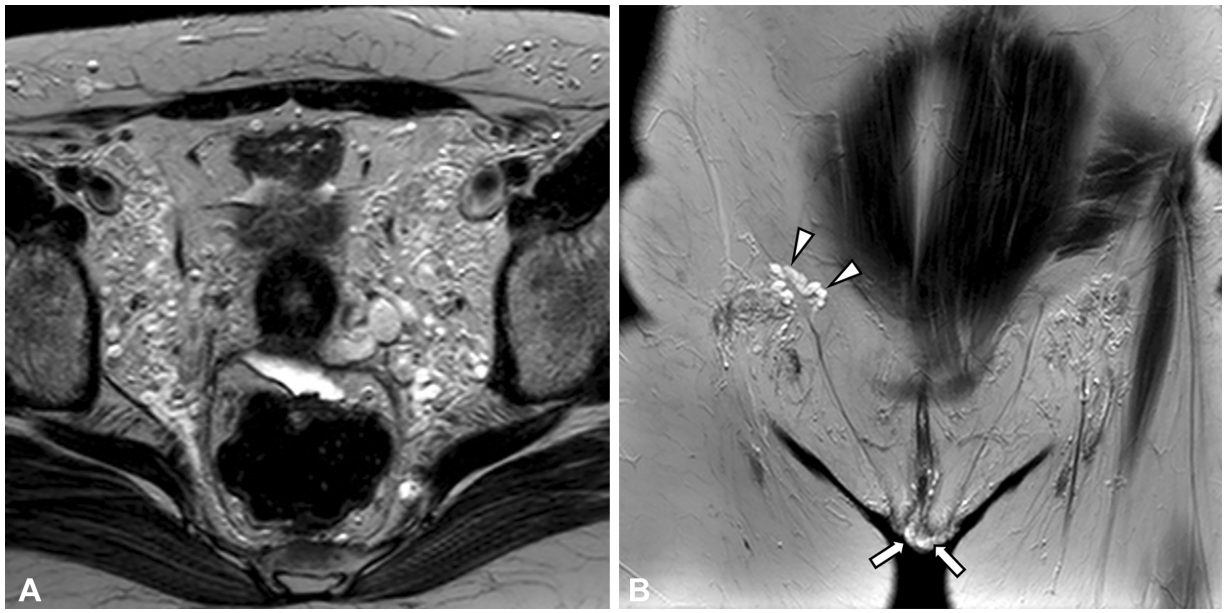

Fig. 1 MR scans for evaluation of vulvar and vaginal lymphorrhea. (**A**) Axial T2-weighted scan shows multiple dots and linear structures of high signal intensity (SI) involving bilateral sides of the pelvic cavity. (**B**) Coronal T2-weighted scan shows a prominent tubular structure (arrows) of high SI involving the right lower abdominal wall and high SI involving both vulvar areas (arrowheads). MR, magnetic resonance imaging.

history of vulvar and vaginal secretion and multiple millet-like lesions on her vulva. When she was 10 years old, the patient had undergone several sessions of percutaneous sclerotherapy and laser therapy, administered by a surgeon. At 20 years of age, percutaneous radiofrequency ablation was performed to ablate the dilated lymphatics at her vulva. These local therapies were not effective. At the age of 24 years, surgical lymphovenous connection was performed with no satisfactory effect. There was no sign of lymphedema.

On magnetic resonance images (MRIs), multiple dots and serpentine structures of T2 high signal intensity were observed in the bilateral vulvar areas and pelvic cavity, compatible with lymphangiectasia (►**Fig. 1**). Conventional lipiodol lymphangiography with or without adjunctive embolization was planned through a multidisciplinary discussion.

Intranodal lymphangiography through the right inguinal lymph node was performed using a 25-G spinal needle (Tae-Chang Industrial, Gongju, Korea) under ultrasound guidance. The injected ethiodized oil (Lipiodol; Guerbet, Paris, France) moved quickly toward the bilateral pelvic cavities, as well as the vulvar areas (►**Fig. 2A**). Reflux of lymphatic flow to the vulvar areas seemed to originate from a prominent tubular lymphatic structure in the right lower abdominal wall (►**Fig. 2A**). It was judged that coil embolization of the distal portion of this tubular lymphatic structure could reduce the lymphatic flow going upwards, and subsequent N-butyl cyanoacrylate (NBCA) embolization of this structure could block the lymphatic reflux into the vulvar areas. As planned, the tubular structure was punctured using a Chiba needle (Cook, Bloomington, Illinois) under ultrasound guidance, and a microguidewire (Meister; Asahi Intecc, Nagoya, Japan) was inserted (►**Fig. 2B**). Clear fluid leaked through the puncture

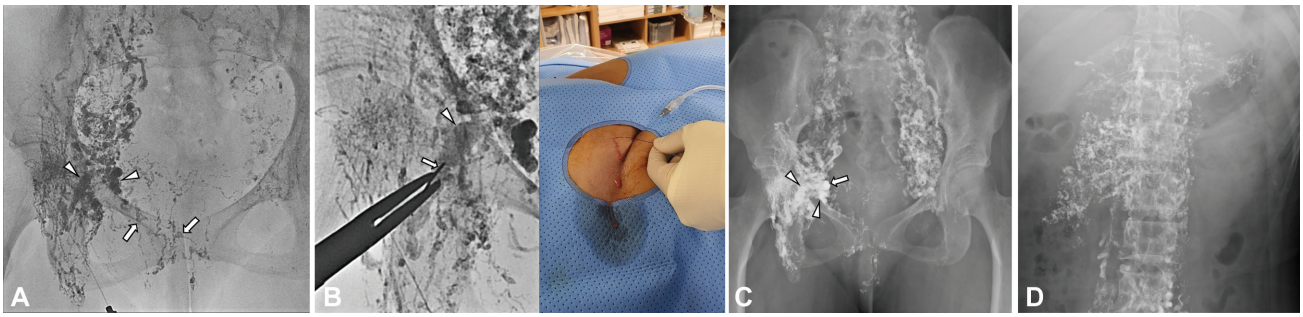

Fig. 2 Conventional intranodal lymphangiography and adjunctive embolization. (**A**) Right inguinal lipiodol lymphangiography shows prominent lymphatic opacification in the bilateral pelvic cavities as well as the vulvar areas. Note the reflux of lymphatic flow (arrows) to the vulvar area from a prominent tubular lymphatic structure (arrowheads). (**B**) The prominent tubular lymphatic structure (arrowhead) was punctured with a Chiba needle (arrow) under fluoroscopic guidance; clear fluid leaking through the puncture site is seen. (**C and D**) The prominent tubular lymphatic structure has been embolized with microcoils (arrow in **C**) for the distal portion and glue (arrowheads in **C**) for the rest. Note the prominent lymphatic opacification in the abdominal and pelvic retroperitoneum.

 © 2022. The Pan Arab Interventional Radiology Society. All rights reserved.

site (►**Fig. 2B**). A microcatheter (Progreat Lambda 1.9 Fr; Terumo, Tokyo, Japan) was advanced over the microguidewire. Subsequently, the distal portion of this tubular lymphatic structure was embolized using four microcoils (Micronester, Cook) for prevention of upward propagation of the NBCA. This was followed by embolization of the tubular lymphatic structure using a 1:2 mixture of NBCA (Histoacryl; B.Braun, Tuttingen, Germany) and lipiodol (►**Fig. 2C**). Prominent lymphatic channels were opacified with lipiodol in the abdominal and pelvic retroperitoneum.

At the 2-week follow-up visit, the multiple millet-like vulvar lesions had almost disappeared with complete resolution of vulvar or vaginal secretions. The patient reported no skin lesions or symptoms at the 1-year follow-up after the procedure.

Discussion

A review of the literature revealed a few case reports of gynecologic lymphatic leakage.[1,2,5] Most reported cases of gynecologic lymphatic leakage have been of chylous metrorrhea (uterine discharge), while vulvar and/or vaginal lymphatic leakage has rarely been reported.[1,2] Vulvar and/or vaginal lymphatic leakage can be associated with intestinal lymphangiectasia, skin xanthomatosis, or primary lymphedema.[2] Its etiology can be incompetent valvular system with extensive lymphangiectasis (primary) or an obstruction of the lymphatics (secondary).[1,6] The site of the reflux might be anywhere in the gynecologic tract: uterus, cervix, vagina, or vulva.[1]

This patient was considered to have genital involvement of diffuse lymphangiomatosis based on her history of early-onset symptoms and prominent retroperitoneal lymphatic channels on lymphangiography.[7] Since lymphangiomatosis and lymphatic reflux were confined to the retroperitoneal and genital regions in this patient, lymphedema did not develop. It is important to identify the disease extent as a thorough lymphatic evaluation of the whole body.

Conventional MR scans or MR lymphangiography can visualize the location and size of abnormal lymphatic fluid collections, and dynamic information can be obtained with the use of MR contrast agents.[8] In this report, although an MR lymphangiography was not obtained, the extent of lymphangiectasia was clearly demonstrated on conventional MR scans. CT findings of primary gynecologic lymphatic reflux was reported to be multiple tortuous vessels in the parametria and perirectal space[1] and seemed to be similar to the MR findings of the patient in this report. With the benefit of superior tissue-contrast resolution and space orientation, dynamic MR information can facilitate planning of the intervention. In this patient, MR scans were able to show the tubular lymphatic structures used for puncture target.

Good clinical outcome was achieved in the patient in this case because lymphatic flow into the vagina and vulva was effectively blocked by percutaneous NBCA embolization. Minimal amount of reflux can persist after the embolization procedure, but the minimal amount of refluxed lymphatic fluid can be resorbed; therefore, symptom improvement or resolution can be expected. When blocking abnormal lymphatic channels with NBCA embolization at a certain level, reducing the upward lymphatic flow with distal coil embolization may facilitate greater NBCA embolization of targeted reflux, as seen in this patient.

Conclusion

In conclusion, this study demonstrated feasibility and efficacy of conventional lipiodol lymphangiography and adjunctive glue embolization for vulvar and vaginal lymphorrhea.

Conflict of Interest
None declared.

References

1 Kornreich L, Idelson A, Shuper A, Ziv N, Mimouni M, Hadar H. The CT manifestations of the primary gynecological chylous reflux syndrome in the pediatric age. Pediatr Radiol 1988;18(06): 503–504
2 Karg E, Bereczki C, Kovacs J, et al. Primary lymphoedema associated with xanthomatosis, vaginal lymphorrhoea and intestinal lymphangiectasia. Br J Dermatol 2002;146(01): 134–137
3 Chu HH, Shin JH, Kim JW, Noh SY, Yang WJ, Park S. Lymphangiography and lymphatic embolization for the management of pelvic lymphocele after radical prostatectomy in prostatic cancer. Cardiovasc Intervent Radiol 2019;42(06):873–879
4 Hur S, Shin JH, Lee IJ, et al. Early experience in the management of postoperative lymphatic leakage using lipiodol lymphangiography and adjunctive glue embolization. J Vasc Interv Radiol 2016; 27(08):1177–1186.e1
5 Mitchell GW Jr, Adashi E, Millan V, Farber M, White RL. Chylous metrorrhea. Obstet Gynecol 1979;53(Suppl 3):88S–91S
6 Adashi EY, Mitchell GW Jr, Farber M. Gynecological aspects of the primary chylous reflux syndrome: a review. Obstet Gynecol Surv 1981;36(04):163–171
7 Lohrmann C, Foeldi E, Langer M. Diffuse lymphangiomatosis with genital involvement–evaluation with magnetic resonance lymphangiography. Urol Oncol 2011;29(05):515–522
8 Itkin M, Nadolski GJ. Modern techniques of lymphangiography and interventions: current status and future development. Cardiovasc Intervent Radiol 2018;41(03):366–376

 © 2022. The Pan Arab Interventional Radiology Society. All rights reserved.