



# Patellar Tendon Repair Using a Patellar Tendon Allograft and External Fixator in Three Dogs

Samuel J. Tidwell<sup>1</sup> Samuel P. Franklin<sup>1</sup>

<sup>1</sup>Colorado Canine Orthopedics, Colorado Springs, Colorado, United States

**Address for correspondence** Samuel P. Franklin, MS, DVM, PhD, DACVS-SA, DACVSMR, Kansas City Canine Orthopedics, Shawnee, KS 66218, United States (e-mail: samfranklin@kck9ortho.com).

VCOT Open 2022;5:e98–e102.

## Abstract

**Objective** The aim of this study was to report on complications and outcomes with repair of ruptured canine patellar tendons using primary tenorrhaphy coupled with patellar tendon allograft transplantation and use of a transarticular external skeletal fixator.

**Materials and Methods** This report includes three dogs with acutely ruptured patellar tendons, all of whom had surgical repair using a patellar tendon allograft. Dogs were assessed postoperatively by physical examination, owner input, and/or video review. Functional outcomes were classified as full, acceptable, or unacceptable based on previously established criteria.

**Results** Follow-up time was between 24 and 46 weeks. Two dogs obtained full function and one dog reached acceptable function. The acrylic connecting bars of the external fixator fractured and needed to be replaced in one dog. There were no other problems or complications. There was no evidence of rejection of any allograft.

**Clinical Significance** Primary tenorrhaphy supported by patellar tendon allograft transplantation and transarticular skeletal fixation appears to be a viable option without evidence of patellar tendon allograft rejection and acceptable or full recovery in the three dogs of this report.

## Keywords

- ▶ patellar tendon
- ▶ allograft
- ▶ transplantation
- ▶ dog

## Introduction

Rupture of the patellar tendon in dogs is an uncommon injury associated with direct trauma, iatrogenic surgical injury<sup>1,2</sup> or simultaneous forced flexion of the knee and contraction of the quadriceps muscle.<sup>3</sup> While it is a rare condition, there are multiple reports of such injury and associated surgical repair.<sup>1–15</sup> Within these reports, there is substantial variability in terms of suture patterns and suture materials that have been used. However, there is consensus that the strength of the repaired tendon is in general too low to fully sustain the loads of the quadriceps pull during normal weight bearing.<sup>4,5</sup> Consequently, the primary tenorrhaphy is often augmented with a transpatellar or circumpatellar stainless steel wire, monofilament

suture or braided polyethylene suture/implant, anchored to the tibial tuberosity.<sup>1,2,6,7</sup> Alternatively, fascia lata autografts,<sup>8,9</sup> patellar tendon and hamstring pedicle autografts<sup>5</sup> or a hook plate have been employed.<sup>10</sup>

An additional technique, successful in two dogs, was the use of a common calcaneal tendon allograft to support the tenorrhaphy.<sup>11,12</sup> One appealing characteristic of an allograft is that there is a lower likelihood of a second surgery to remove the allograft, when compared with circumpatellar or transpatellar wires that frequently break and require removal.<sup>2,8</sup> Other potentially advantageous characteristics of allograft use include a lack of donor site morbidity, probable superior strength in comparison to autologous fascia lata<sup>5</sup> and the possibility that with infection the allograft might not

received  
August 24, 2021  
accepted after revision  
February 23, 2022

DOI <https://doi.org/10.1055/s-0042-1750031>.  
ISSN 2625-2325.

© 2022. The Author(s).

This is an open access article published by Thieme under the terms of the Creative Commons Attribution License, permitting unrestricted use, distribution, and reproduction so long as the original work is properly cited. (<https://creativecommons.org/licenses/by/4.0/>)  
Georg Thieme Verlag KG, Rüdigerstraße 14, 70469 Stuttgart, Germany

need to be removed,<sup>16</sup> which contrasts with non-biologic materials. One potential advantage of a patellar tendon allograft versus a common calcaneal tendon allograft is that the patellar tendon allograft is more closely anatomically shaped to the native patellar tendon, potentially making its surgical implantation easier. There are multiple reports on successful application of patellar tendon allografts for patellar tendon reconstruction in people including with an infected patellar tendon rupture.<sup>16–18</sup> Potential disadvantages of allograft use include the cost and risk of disease transmission or immune-mediated reaction.<sup>11</sup> Risk of disease transmission or immune-mediated rejection is mitigated by screening of donor tissues for infectious disease and graft preparation which renders it acellular and typically non-immunogenic.<sup>19</sup>

Despite the potential advantages of a patellar tendon allograft, there are no reports on its use to repair the patellar tendon in dogs. Accordingly, the purpose of this report is to document complications and outcomes with repair of ruptured canine patellar tendons using primary tenorrhaphy coupled with patellar tendon allograft transplantation and use of a transarticular external skeletal fixator (ESF).

## Materials and Methods

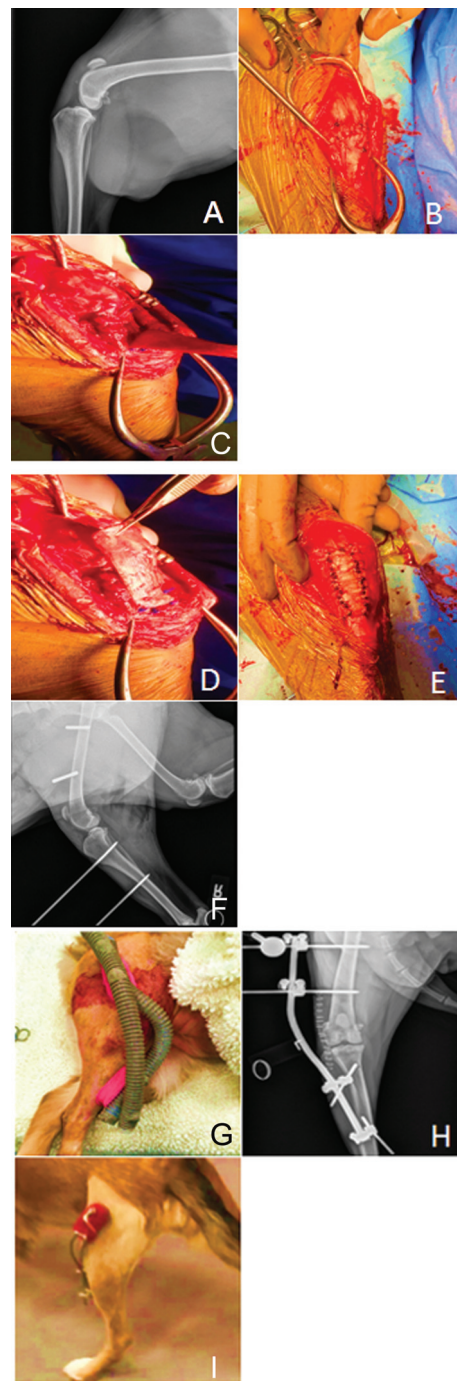
This report includes three dogs having undergone repair of a ruptured patellar tendon between February 2020 and February 2021.

There were two spayed females and one neutered male. The ages of the dogs were 2, 3, and 8 years old, weighing 25.7, 27.0, and 28.9 kg. All dogs suffered acute onset of lameness without any prior signs of lameness. The dogs suffered injury while playing with another dog ( $n=2$ ) or when playing unobserved ( $n=1$ ). In one dog, the injury was sustained 2 days prior to presentation and in two dogs the injury was sustained 3 weeks prior to treatment. None of them had any external wounds or signs of skin lesions.

Long-term follow-ups were performed at 24, 27, and 46 weeks in all three dogs. Surgical outcomes were established by physical examination or review of videos sent in by owners coupled with owner input. Definitions of outcome were based on previously established criteria.<sup>20</sup> Briefly, functional outcomes were considered full if the dog returned to pre-injury status without the need for medications, acceptable if pre-injury status was obtained but limited in level or duration or when use of medication was required, or unacceptable, which included all other outcomes. Success was defined as obtaining full or acceptable function.<sup>20</sup>

## Surgical Technique

A lateral approach to the stifle joint with lateral arthrotomy was performed in all patients. The ends of the ruptured patellar tendon were apposed and secured with one, two or three locking loop sutures of polypropylene ( $n=1$  dog), polydioxanone ( $n=1$  dog) or no. 2 fibrewire (Arthrex, Naples, Florida, United States;  $n=1$  dog). A simple continuous, epitendinous suture was then placed with 2–0 polydioxanone in the second dog (►Fig. 1).<sup>21</sup> In all cases, a



**Fig. 1** (A) Preoperative radiographs in first patient showing patella alta; (B) completion of primary tenorrhaphy using three locking loops and an epitendinous suture pattern; (C) initial application of the allograft to the distal, native patellar tendon using interrupted sutures; (D) application of the allograft by stretching the graft proximally, then extending the stifle (not shown) and suturing the allograft proximally; (E) imaging showing completed application of the allograft patellar tendon; (F) postoperative radiographs showing improvement of patella alta and two pins each in the femur and tibia for the external skeletal fixator (ESF), but prior to acrylic application; (G) postoperative acrylic ESF. An acrylic ESF is no longer used by the authors for such purpose because the acrylic fractured in the second dog of this series; (H) postoperative radiographs of another patient showing use of a titanium connecting bar for the ESF. Note that a second connecting bar was placed following the radiographs such that two titanium connecting bars were used for this patient; (I) image of the same patient as in H. The second titanium connecting bar can be seen.

patellar tendon allograft (Veterinary Transplant Services, Inc, Kent, Washington, United States; <https://www.vtsonline.com/>) was applied on top of the repaired patellar tendon. Grafts were selected to be at least as long and wide as the native patellar tendon, or slightly larger. This was based on calibrated radiographs of the contralateral stifle from which measurements of the native patellar tendon length and width could be made. Commercially available grafts (Veterinary Transplant Services, Inc, Kent, Washington, United States; <https://www.vtsonline.com/>) were selected/ordered from the tissue bank and graft selection was based on the measured width and length of the available allografts.

The commercially obtained grafts sell as a functional entity, that is, the package contains the tendon including the patella and the tibial tuberosity insertions (i.e., bone-tendon-bone); in our cases, the allograft tendon was dissected, and both the donor patella and the tibial tuberosity attachment were discarded. The allogeneic patellar tendon was then trimmed to match the width of the native patellar tendon. Then, the allograft was secured to the native patellar tendon distally near the tibial tuberosity with interrupted sutures (►Fig. 1). Under stifle joint extension, the allograft was secured under tension to the native patellar tendon at the distal extent of the patella. Any excess length of the patellar tendon allograft was trimmed and discarded. Additional sutures were then placed all around the periphery of the graft securing it to the native patellar tendon, including both proximal and distal to the location of tendon rupture (►Fig. 1). In the first dog, 0-polypropylene was used for suturing the allograft and in the other two dogs polydioxanone (size 1 and size 0) was used. Closure of the subcutaneous layers and skin was performed in routine fashion.

A transarticular ESF was applied in all dogs. In the first two dogs, the transosseous pins were transfixed with two connecting columns of acrylic (Technovit, Jorgensen Labs, Loveland, Colorado, United States). In the third patient, two titanium connecting bars were contoured and secured to the pins using ESF clamps (Imex Veterinary, Inc., Longview, Texas, United States).

Fixator removal was planned for 4 weeks following surgery. Owners were advised to start directed physical rehabilitation immediately following fixator removal and for leashed-only activity to progress slowly in duration and intensity over the subsequent 2 to 3 months before resuming off-leash activity. All dogs were prescribed 2 weeks of carprofen (2.2 mg/kg per os [PO] twice daily), 10 days of cephalexin (22 mg/kg PO thrice daily) and acepromazine (0.5 mg/kg PO thrice daily), the latter to be used as needed.

## Results

The first dog had surgical repair as described above using polypropylene suture for both the primary tenorrhaphy and when securing the patellar tendon allograft. The acrylic ESF was removed 29 days post-surgery. At the time of fixator removal, there was substantial loss of stifle flexion and range of motion. The owner commenced physical rehabilitation, and at 23.7 weeks following surgery the owner reported the

dog had regained full function of the limb and provided videos of the patient exercising. The videos show full flexion of the stifle, and there was no visible lameness on video review with high function apparent as the dog would run freely off leash. This dog was classified as having no complications and obtaining full function based on owner input and video review.

The second dog had surgical repair as described above using polydioxanone suture for the primary tenorrhaphy, the epitendinous suture pattern and securing the patellar tendon allograft. An acrylic ESF was applied. The acrylic connecting bars of the ESF broke 2 weeks following surgery. The acrylic was removed and two titanium connecting bars were contoured and placed without removing, changing or adding any external fixator pins. The fixator was then removed at 28 days following surgery. There was substantial reduction in stifle flexion at the time of fixator removal. The dog was seen in-house at 12.3 weeks following surgery and had regained full flexion of the stifle with mild thigh muscle atrophy and a mild asymmetry in pelvic limb weight bearing when walking. At 45 weeks following surgery, the owner reported the dog was '95% of normal' on that limb and had returned to off leash activity. Video review showed the dog jumping over 3-foot obstacles without difficulty and without visible lameness. The dog was not receiving any medications. Given the owners report that the dog was '95% of normal', this suggested that the dog had not reached full function even though we could not recognize lameness in the video provided. This dog was classified as having obtained an acceptable outcome.

The third dog had surgery as described above using no. 2 fibrewire for the primary tenorrhaphy and polydioxanone to secure the patellar tendon allograft. An ESF was applied using titanium connecting bars rather than acrylic connecting bars. The ESF was removed at 26 days following surgery and substantial reduction in stifle flexion was noted at that time. The dog was rechecked in house at 7.7 weeks following surgery and had regained full flexion of the stifle with minimal lameness. At 26.7 weeks following surgery, the owners reported the dog as being fully functional and videos showed the dog running and playing with other dogs off leash with a high level of function. This dog was classified as having obtained full function without any complications.

## Discussion

Most patellar tendon repairs are divided into three steps: primary tenorrhaphy, tenorrhaphy augmentation and temporary immobilization of the stifle.<sup>1</sup> Primary tenorrhaphy of the canine patellar tendon has been performed utilizing Bunnell, three-loop pulley, Krackow or locking loops employing different suture materials.<sup>2</sup> There are no studies, either in vivo or ex vivo, comparing different suture patterns or materials for primary tenorrhaphy of the canine patellar tendon, specifically. Rather, there are multiple studies assessing repair of other tendons such as the superficial digital flexor and gastrocnemius tendons,<sup>21,22</sup> or attachment of other tendons to bone.<sup>23</sup> There is also one report assessing

two suture techniques for re-attaching the patellar tendon to the patella,<sup>4</sup> but this study did not assess tendon-to-tendon repair. As locking loop sutures with different suture materials were used in this report, our data do not contribute to assessing the most favourable method of primary patellar tenorrhaphy. In the three cases described, a progression toward the use of absorbable suture materials was applied based on the supposition that addition of the allograft might be sufficiently strong to justify use of absorbable material. This report does not provide adequate data to determine which types of suture material are preferable.

As for protecting the primary repair, the allograft transplantation technique described was simple with no complications associated with the allograft use including no infections and no evidence of an immune-mediated rejection. Transplantation of allograft tendons has been described in dogs previously,<sup>11,12</sup> and immune-mediated rejection has not been reported in those studies either.

What makes this report unique is that it is the first report on transplantation of a patellar tendon allograft specifically. Size selection of the graft, based upon radiographs of the contralateral stifle, and surgical application as an onlay over the native patellar tendon were both simple. Furthermore, success was achieved in all three patients, but we cannot conclude superiority of this technique to any of the numerous other bolstering techniques described in the literature. However, we do speculate that use of a patellar tendon allograft may be superior to transplantation of a common calcaneal tendon for repairing ruptured patellar tendons. A patellar tendon allograft will more closely match the size and shape of the native patellar tendon, potentially making application easier. Conversely, the common calcaneal tendon is really composed of three separate parts and is more circular in cross-section, potentially creating more mismatch between the native tendon and transplanted tendon.

For the repair of ruptured patellar tendons, temporary transarticular stabilization in extension by ESF may be equally important. In the largest ( $n=43$ ) study to date on patellar tendon repairs,<sup>2</sup> 4 of the 18 dogs without stifle immobilization had failure and only 1 of 25 with stifle immobilization failed. Those authors recommended that temporary immobilization of the stifle joint with a transarticular ESF should be performed. We found the use of just four pins for the ESF, with two in the frontal plane in the femur and two in the sagittal plane of the tibia connected by contoured metal connecting bars, to be effective and easier to apply than use of acrylic or more complex frames using multiple connecting elements.<sup>5</sup> Data from a previous case report<sup>5</sup> and from our dogs, all of whom had the fixator removed at 4 weeks, suggest that the substantial loss in range of motion that occurs with the fixator use can be resolved if the fixator is removed at this time point and followed immediately by physical rehabilitation.

This report is limited in its scope because it includes only three cases. In addition, more objective parameters could have been used to assess presenting injuries and clinical outcomes, including ultrasonic examination of the healing

tendons and the transplanted allografts. The follow-up period was between 24 and 46 weeks; future reports on use of patellar tendon allograft transplantation should include longer postoperative assessments. Around 6 months follow-up would likely be sufficient to identify any immune-mediated reactions, which did not occur in our dogs. Finally, another limitation is that these three cases could not be compared with a control group repaired with other previously reported techniques. Nevertheless, the use of this commercially available tendon allograft for augmentation of patellar tendon rupture seems promising.

#### Authors' Contributions

S.J. Tidwell assisted with data collection and evaluation and drafted and revised the final manuscript. S.P. Franklin conceived of the study design, assisted with data collection and evaluation and assisted with and revised the final manuscript.

#### Conflict of Interest

No proprietary or conflict of interest for this project.

#### Acknowledgments

The authors thank the staff at Colorado Canine Orthopedics and the patient owners for their assistance with this study.

#### References

- 1 Witte P. Treating canine patellar ligament rupture. *Vet Rec* 2014; 175(15):368–369
- 2 Das S, Thorne R, Lorenz ND, et al. Patellar ligament rupture in the dog: repair methods and patient outcomes in 43 cases. *Vet Rec* 2014;175(15):370–370
- 3 Slatter D. *Textbook of Small Animal Surgery*. 3rd edition. Philadelphia: WB Saunders; 2003:2126–2126
- 4 Soula M, Shmalberg JW, Johnson MD. Biomechanical comparison of a modified three-loop pulley technique and a three-level self-locking technique for repair of patellar tendon rupture in dogs. *Am J Vet Res* 2019;80(04):335–341
- 5 Farrell M, Fitzpatrick N. Patellar ligament-bone autograft for reconstruction of a distal patellar ligament defect in a dog. *J Small Anim Pract* 2013;54(05):269–274
- 6 Smith ME, de Haan JJ, Peck J, Madden SN. Augmented primary repair of patellar ligament rupture in three dogs. *Vet Comp Orthop Traumatol* 2000;13(03):154–157
- 7 Johnson MD, Sobrino DR, Lewis DD, Shmalberg J. Surgical repair of a proximal patellar tendon avulsion in a dog utilizing triple patellar bone tunnels and modified tendon repair technique. *Open Vet J* 2018;8(03):256–264
- 8 Aron DN, Selcer BA, Smith JD. Autogenous tensor fascia lata graft replacement of the patellar ligament in a dog. *Vet Comp Orthop Traumatol* 1997;10(03):141–145
- 9 Gemmill TJ, Carmichael S. Complete patellar ligament replacement using a fascia lata autograft in a dog. *J Small Anim Pract* 2003;44(10):456–459
- 10 Sugiyama T. Technical challenges for sequential surgical failures of a patellar ligament rupture in a German Shepherd Dog. *Aust Vet Pract* 2020;50(04):260–269
- 11 Serra CI, Navarro P, Guillem R, Soler C. Use of frozen tendon allograft in two clinical cases: common calcaneal tendon and patellar ligament rupture. *J Am Anim Hosp Assoc* 2020;56(06): 315–319



- 12 Alam MR, Gordon WJ, Heo SY, et al. Augmentation of ruptured tendon using fresh frozen Achilles tendon allograft in two dogs; a case report. *Vet Med* 2013;58(06):50–55
- 13 Sarierler M, Akin I, Belge A, Kilic N. Patellar fracture and patellar tendon rupture in a dog. *Turk J Vet Anim Sci* 2013;37(01):121–124
- 14 Shipov A, Shahar R, Joseph R, Milgram J. Successful management of bilateral patellar tendon rupture in a dog. *Vet Comp Orthop Traumatol* 2008;21(02):181–184
- 15 Buttin P, Goin B, Cachon T, Viguier E. Repair of tendon disruption using a novel synthetic fiber implant in dogs and cats: the surgical procedure and three case reports. *Vet Med Int* 2020;2020:4146790
- 16 Choi HS, Jang BW, Chun DI, et al. Staged patellar tendon reconstruction using doubled bone-patellar tendon-bone allograft for infected patellar tendon rupture: a rare case report of three years follow-up. *J Exp Orthop* 2021;8(01):13
- 17 Zanotti RM, Freiberg AA, Matthews LS. Use of patellar allograft to reconstruct a patellar tendon-deficient knee after total joint arthroplasty. *J Arthroplasty* 1995;10(03):271–274
- 18 Fiquet C, White N, Gaillard R, Servien E, Neyret P, Lustig S. Partial extensor mechanism allograft reconstruction for chronic patellar tendon disruption shows superior outcomes in native knees when compared to same technique following total arthroplasty. *Int Orthop* 2018;42(11):2591–2599
- 19 Song YJ, Hua YH. Tendon allograft for treatment of chronic Achilles tendon rupture: a systematic review. *Foot Ankle Surg* 2019;25(03):252–257
- 20 Cook JL, Evans R, Conzemius MG, et al. Proposed definitions and criteria for reporting time frame, outcome, and complications for clinical orthopedic studies in veterinary medicine. *Vet Surg* 2010;39(08):905–908
- 21 Cocca CJ, Duffy DJ, Kersh ME, Kim W, Groenewold A, Moore GE. Biomechanical comparison of three epitendinous suture patterns as adjuncts to a core locking loop suture for repair of canine flexor tendon injuries. *Vet Surg* 2019;48(07):1245–1252
- 22 Wilson L, Banks T, Luckman P, Smith B. Biomechanical evaluation of double Krackow sutures versus the three-loop pulley suture in a canine gastrocnemius tendon avulsion model. *Aust Vet J* 2014;92(11):427–432
- 23 Moores AP, Comerford EJ, Tarlton JF, Owen MR. Biomechanical and clinical evaluation of a modified 3-loop pulley suture pattern for reattachment of canine tendons to bone. *Vet Surg* 2004;33(04):391–397