Article published online: 2022-07-11

Spectrum of Clinical and Radiological Presentation of Midgut Malrotation in Children and Adolescents: Case Series

Saurya Saurya[1] Poonam Sherwani[1] Garima Sharma[1] Sudhir Saxena[1]

[1] Department of Radiodiagnosis, All India Institute of Medical Sciences, Rishikesh, Uttarakhand, India

J Gastrointestinal Abdominal Radiol ISGAR 2022;5:217–221.

Address for correspondence Poonam Sherwani, DNB, EDIR, DICR, All India Institute of Medical Sciences, Virbhadra Road Shivaji Nagar, Near Barrage, Sturida Colony, Rishikesh 249203, Uttarakhand, India (e-mail: sherwanipoonam@gmail.com).

Abstract

Midgut malrotation is usually present in the early neonatal period with intestinal obstruction and bilious vomiting. However, sometimes it may present later in childhood and adolescence with atypical features and then may remain undiagnosed for long, adversely affecting the growth and development of the child. Here we describe three cases of intestinal malrotation with various atypical presentation and imaging findings.

Keywords

- malrotation
- midgut
- volvulus
- Ladd's band
- nonrotation
- reverse rotation

Introduction

Although intestinal malrotation usually presents in the neonatal period with intestinal obstruction, it can also have variable presentations later in childhood or adolescence.[1] Here we review three different cases of intestinal malrotation that presented in childhood and adolescence with varied clinical manifestations ranging from acute intestinal obstruction and superimposed infectious peritonitis to asymptomatic or chronic on and off intestinal obstruction, which remained undiagnosed for years.

Case 1

A 9-year-old male child presented to the pediatric emergency with pain in the abdomen for the past 15 days. The pain was localized to the right iliac fossa region. It was moderate to severe in intensity and was relieved on medication. The patient also had five to six episodes of bilious vomiting per day for the past 6 days. He also complained of fever for the past 6 days, which was relieved on medication. On examination, the abdomen was soft; however, there was tenderness in the right iliac fossa region.

The patient underwent an ultrasound abdomen that showed dilated small bowel loops with twisting of mesentery and vessels, giving a whirlpool sign, reversal of superior mesenteric artery (SMA) and superior mesenteric vein (SMV) relationship. Mild ascites with mesenteric lymphadenopathy were also present. There were also multiple focal areas of small bowel thickening. The child was diagnosed as midgut volvulus with superimposed infection. The left kidney was also ectopically placed in the pelvic location (►**Fig. 1**).

Further, a contrast-enhanced computed tomography (CECT) scan was done to look for other associated anomalies, bowel status, and the type of malrotation. Apart from findings that were present on the ultrasound, an abnormal position of the transverse colon was seen, which was located behind the SMA and anterior to the aorta. The Ileocecal

published online
July 11, 2022

DOI https://doi.org/10.1055/s-0042-1749674.
ISSN 2581-9933.

© 2022. Indian Society of Gastrointestinal and Abdominal Radiology. All rights reserved.
This is an open access article published by Thieme under the terms of the Creative Commons Attribution-NonDerivative-NonCommercial-License, permitting copying and reproduction so long as the original work is given appropriate credit. Contents may not be used for commercial purposes, or adapted, remixed, transformed or built upon. (https://creativecommons.org/licenses/by-nc-nd/4.0/)

Thieme Medical and Scientific Publishers Pvt. Ltd., A-12, 2nd Floor, Sector 2, Noida-201301 UP, India

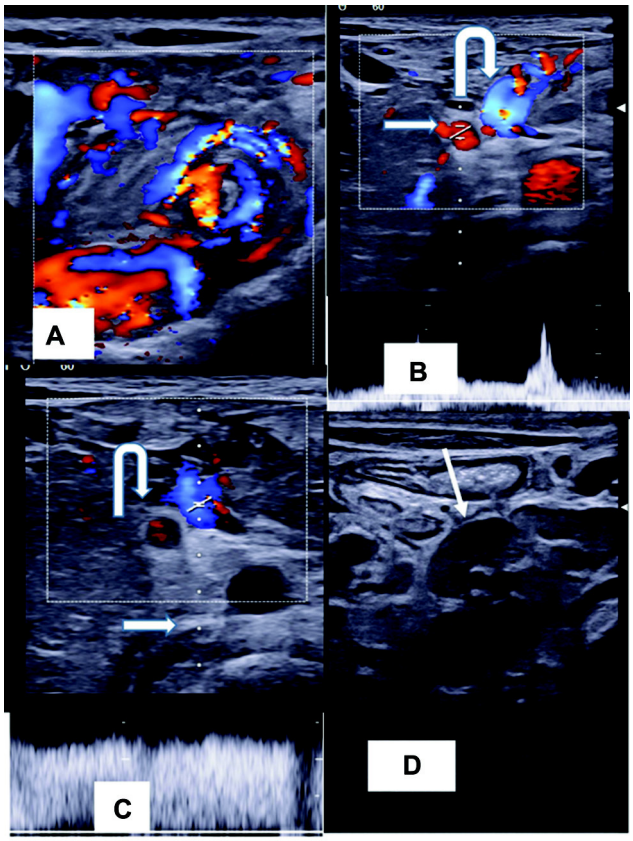

Fig. 1 Transverse color Doppler ultrasound through the abdomen using high-frequency a transducer shows twisting of mesentery with swirling of SMV around SMA giving whirlpool sign (**A**), reversal of SMA (arrow) and SMV (curved arrow) relationship with SMA being on right and SMV on left (**B** and **C**). Grayscale ultrasound shows enlarged mesenteric lymph nodes (**D**).

junction was located in the midline and there was diffuse thickening of ileal loops. There was mild ascites with enlarged heterogeneously enhancing mesenteric lymph nodes, a few of them showing central necrosis and conglomeration (►**Fig. 2**).

Based on ultrasound and CT findings, the final diagnosis was reverse malrotation of the bowel with midgut volvulus, complicated with infection. Ascitic tap showed raised adenosine deaminase levels (~58 IU/mL), suggestive of tubercular etiology. Incidental note was made of ectopic left kidney. The patient was managed conservatively and started on anti-tubercular treatment. Symptoms improved significantly after anti-tubercular treatment (ATT) administration.

Case 2

A 14-year-old male patient presented to the outpatient department (OPD) with recurrent on and off episodes of bilious vomiting with associated abdominal distention and pain since birth. There was no associated history of diarrhea, constipation, or fever. On examination, the abdomen was soft with mild diffuse tenderness. The child was referred to the radiology department.

A plain radiograph showed an overdistended stomach and duodenum. USG abdomen was done that showed the reversal

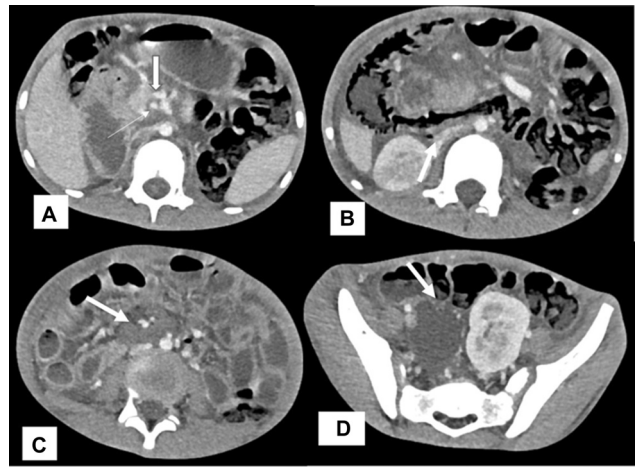

Fig. 2 Contrast-enhanced CT of the abdomen depicts the reversal of SMA and SMV relationship (thick arrow) with SMA on the right (thin arrow) SMV on left (thick arrow). (**A**) Retroperitoneal location of the transverse colon (**B**) enlarged necrotic mesenteric lymph nodes (white arrow) and the ectopic left kidney in the pelvis (**C**, **D**) were also seen.

of SMA and SMV relationship with the swirling of midgut bowel loops and mesenteric fat. The second part of the duodenum was dilated. A diagnosis of the midgut volvulus with malrotation was made.

The patient underwent CECT abdomen for further evaluation and assessing for other anomalies and bowel pathology. The stomach and duodenum were dilated, and duodenojejunal (DJ) flexure was seen on the right side of the midline. Large bowel loops were seen on the left side and small bowel loops on the right side. Ileocaecal (IC) junction was in the midline. There was a twisting of the mesentery, mesenteric vessels, duodenum, ascending colon, and cecum with reversal of SMA and SMV relationship. A diagnosis of incomplete intenstinal malrotation with midgut volvulus causing mechanical bowel obstruction was made (►**Fig. 3**).

The patient was taken for laparotomy. Intraoperatively stomach, as well as the whole duodenum, was found to be dilated. The small bowel was on the right side and the entire large bowel was on the left side. A thick fibrous band was seen extending from the abnormally located cecum to the lateral peritoneal wall, crossing, and compressing the duodenum in its course suggestive of Ladd's band.

Case 3

A 7-year-old male child presented with severe pain abdomen and bilious vomiting to the pediatric emergency. There was no fever or signs of any infection. The child appeared malnourished with body mass index (BMI) below the third percentile for age (World Health Organization [WHO] weight for age chart). He had multiple similar episodes of severe vomiting and abdominal pain in past since his infancy. He had been evaluated previously by various private practitioners; however, no definite diagnosis was made. During their stay at the hospital, he had six to seven episodes of bilious vomiting per day. An ultrasound of the whole abdomen of the child was done that showed distended duodenum

 © 2022. Indian Society of Gastrointestinal and Abdominal Radiology. All rights reserved.

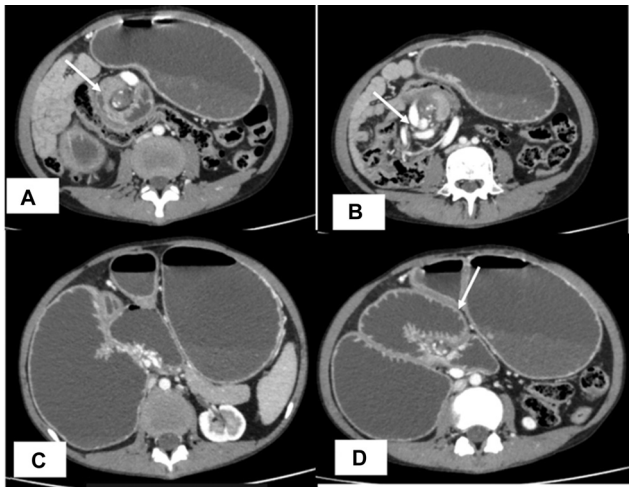

Fig. 3 Contrast-enhanced CT scan of the abdomen shows twisting of bowel loops mesentery and vessels giving whirlpool sign (arrow in **A** and **B**) (**C** and dilated duodenum with duodenojejunal junction on the right side (arrow in **D**).

and proximal jejunum with SMA lying to the right of SMV. It also showed twisting of mesentery giving a whirlpool sign. An upper GI series was done that showed the duodenojejunal junction on the right to the pedicle of the L2 vertebral body below the level of duodenal bulb. On the lateral view, it was lying just anterior and inferior to the duodenal bulb. No passage of contrast was seen beyond the DJ flexor (►**Fig. 4**). Findings were suggestive of incomplete intestinal malrotation with midgut volvulus.

The patient was taken for laparotomy immediately after upper GI series that demonstrated midgut volvulus with Ladd's band. Ladd's band was divided and broadened, and the volvulus was derotated.

Discussion

Malrotation refers to the abnormal position of small and large bowel loops in the abdominal cavity. Abnormally positioned bowel loops can be associated either with abnormal fixation of bowel loops by peritoneal bands, predisposing to obstruction or with the absence of fixation with narrow mesenteric base, rendering the bowel loops mobile, predisposing to twisting and obstruction.[2] Malrotation usually presents early in the neonatal period with intestinal obstruction and bilious vomiting; however, in the minority of cases, it may present late in childhood or adolescence with atypical features. Such children with atypical features sometimes remain undiagnosed and suffer chronically with recurrent obstruction on and off, adversely affecting their growth and development.[1]

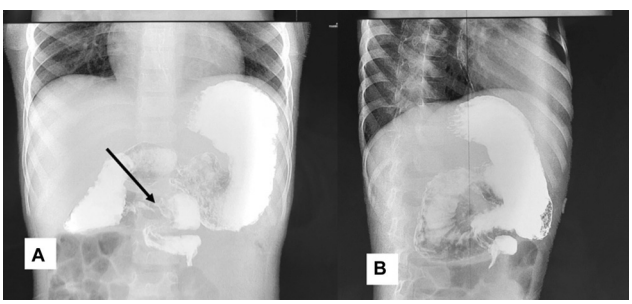

Fig. 4 Upper GI series showing the duodenojejunal junction right to the pedicel of L2 vertebral body below the level of duodenal bulb (**A**). On lateral view, DJ is seen lying just anterior and below the level of duodenal bulb (**B**).

At around 6 weeks of embryonic development, there is herniation of the midgut loop, which is supplied by SMA and divide the loops into pre-arterial and post-arterial segments in the amniotic cavity (►**Fig. 5**). The pre-arterial segment later would form the small bowel including the duodenojejunal junction, while the post arterial segment would later form the cecum and ascending colon. During this herniation, there is a 90-degree anti-clockwise rotation of the loop about the axis of SMA. At around the 10th week of embryonic development, the herniated loop returns to the abdominal cavity, during this time there is another 180-degree counterclockwise rotation, making it a total of 270 degrees counterclockwise rotation. As a result of this rotation, the duodenojejunal junction lies left to the spine and the cecum lies in the right iliac fossa region.[3]

Malrotation can be broadly classified into nonrotation, incomplete rotation, or reverse rotation depending on the stage of embryonic development at which there is abnormal rotation or arrest of the normally occurring rotation.[4]

In non-rotation, only the first 90 degree anticlockwise rotation occurs putting the pre-arterial segment on right and post-arterial segment to the left in the abdominal cavity (►**Fig. 5**). As a result, the small bowel loops are all seen on the right side of the abdominal cavity, while the large bowel loops are on the left side.

When there is only 180 degree counterclockwise rotation instead of the normal 270 degrees it is called incomplete rotation (►**Fig. 5**). The cecum lies in the midline in the epigastrium and the duodenojejunal junction lies posteriorly in the abdomen. This is the most common type of intestinal malrotation.[4]

Reverse rotation happens when 90 degree counterclockwise rotation is followed by a clockwise rotation of 180, resulting in a net 90 degree clockwise rotation (►**Fig. 5**). As a result, the transverse colon lies posteriorly behind the duodenum, separated from it by the superior mesenteric artery as was seen in our first case. This is the rarest of the three types of malrotation and accounts for 2 to 4% of all embryological midgut malrotation.[5] It may present with volvulus of the right colon or midgut or with symptoms due to compression of the retroarterial portion of the colon. The presentation may be typical in the neonatal period with bilious vomiting or atypical with on and off constipation in childhood or adolescence.[5]

The most common finding on plain radiographs in patients with malrotation is a normal bowel gas pattern, as was seen in two of our cases. However, it may demonstrate features of intestinal obstruction or may show large bowel lying on one side of the abdomen with small bowel on another side in cases of nonrotation, or double bubble sign

 © 2022. Indian Society of Gastrointestinal and Abdominal Radiology. All rights reserved.

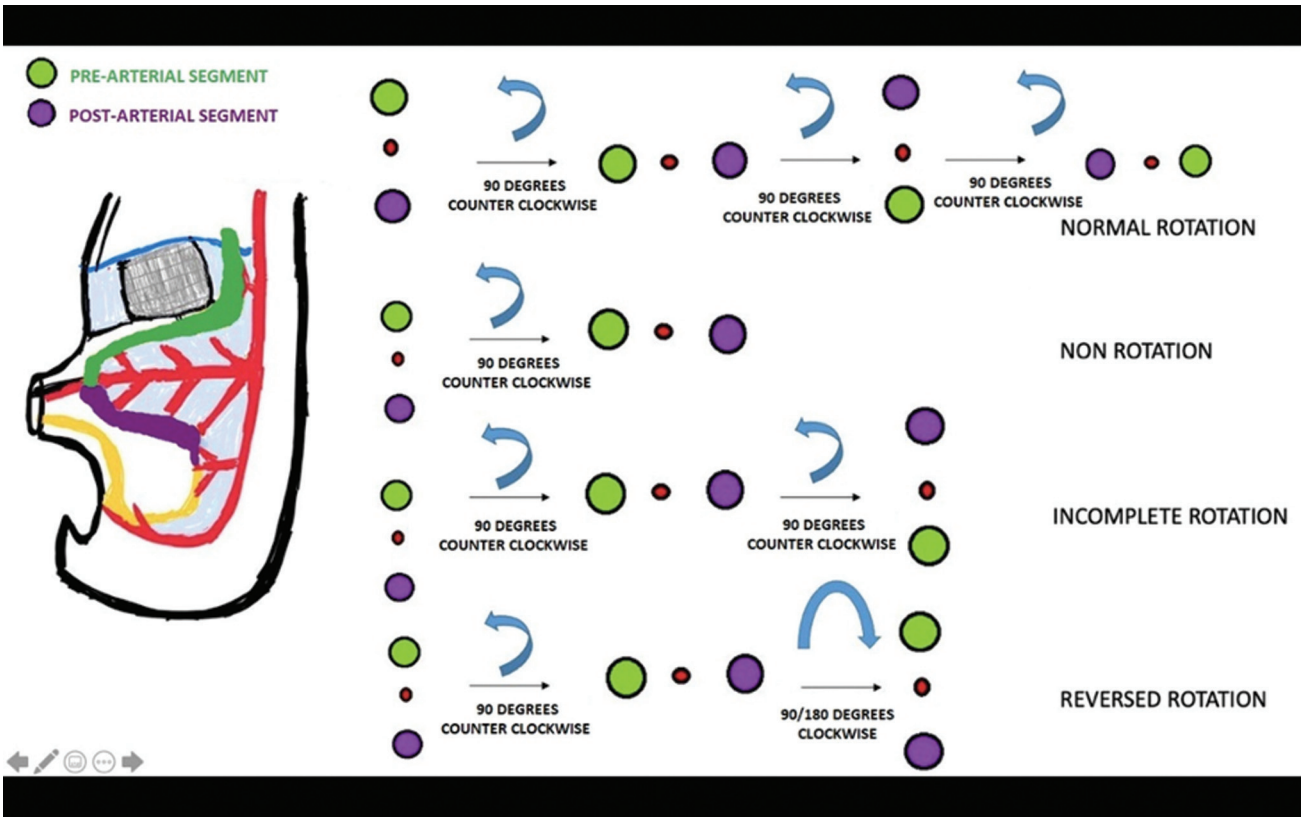

Fig. 5 Schematic drawing demonstrating the normal process of gut rotation with different types of malrotation.

in neonates.[6] Our second case showed a distended stomach and duodenum on a plain radiograph (►**Fig. 6**).

Ultrasonography demonstrated the reversed SMA-SMV relationship, which was seen in all three of our cases. Typically, the SMA lies to the left of SMV, reversal of this relationship is suggestive of malrotation. A whirpool of mesentery around the SMA is seen with twisting of the bowel loop in the midgut volvulus. However, it should be born in mind that the normal position of the SMA and SMV may also be seen in intestinal malrotation, and deviation from the classic position does not always imply malrotation; therefore, clinical correlation is essential. Using graded compression ultrasound, the position of D3 of the duodenum can be accessed. The retroperitoneal location between the aorta and SMA virtually excludes malrotation.[7]

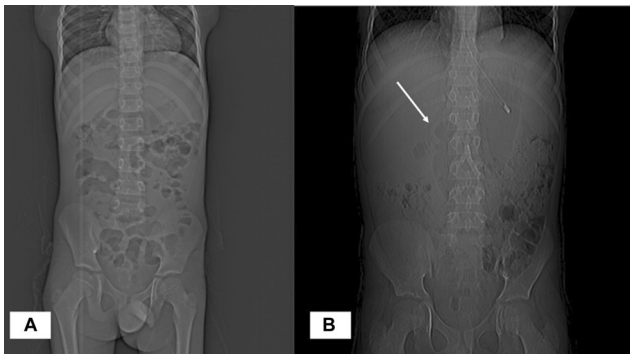

Fig. 6 Normal bowel gas pattern in case I (**A**), prominent duodenal loop in case 2 (**B**).

Upper gastrointestinal imaging is thought of as the gold standard to detect malrotation. Normally on AP projection, the duodenojejunal junction is located on the left of the vertebral body pedicle. On lateral projection, the duodenojejunal junction lies to the level and posterior to the duodenal bulb. Abnormal position of duodenum–jejunal junction or its corkscrew appearance can be demonstrated on upper GI studies as was seen in our third case with duodenojejunal junction lying to the right of the pedicle of L3 vertebral body and on lateral view was seen at the level of the third part of the duodenum.[8] A barium enema can be used to demonstrate the abnormal position of the cecum.

Cross-sectional MRI and CT studies can well delineate the position of the D3 segment of the duodenum and the anatomical location of SMA and SMV as was demonstrated in all our cases. Contrast CT scan also detect perfusion abnormalities and bowel ischemia. However, it carries the disadvantage of radiation exposure. CT can also demonstrate associated anomalies in malrotation such as the hypoplastic uncinate process of the pancreas, which was seen in our first and second case.[9] MRI can also delineate these findings without radiation exposure; however, the long duration of an MRI scan would require adequate sedation for the scan to be performed.

Cases of malrotation presenting with volvulus and acute intestinal obstruction require urgent surgical management. Ladd's procedure that involves reduction of volvulus, division

 © 2022. Indian Society of Gastrointestinal and Abdominal Radiology. All rights reserved.

of Ladd's band, and widening of the mesentery is sufficient in most cases. This procedure can be done either by open laparotomy or laparoscopically. Intra-abdominal adhesions formed during open laparotomy procedure prevents recurrence of malrotation .[10] In our second and third cases, open Ladd's procedure was done. The first case had a tubercular infection and was so initially managed conservatively on ATT.

Conclusion

Because malrotation can have varied presentations ranging from the typical presentation with intestinal obstruction and bilious vomiting in neonates to atypical presentation such as recurrent constipation, vomiting, and abdominal pain in late childhood and adolescence. An index of suspicion for malrotation should be kept in older children and adolescents with such symptoms. So, while imaging these children, careful assessment of SMA–SMV relationship and position of the third part of the duodenum should be looked at. Ultrasound is the first line of investigation and in case of suspicion or limited visibility due to bowel gas, further evaluation with either upper GI series or cross-sectional examination should be performed.

Conflict of Interest
None declared.

References

1 Pickhardt PJ, Bhalla S. Intestinal malrotation in adolescents and adults: spectrum of clinical and imaging features. Am J Roentgenol 2002;179(06):1429–1435
2 Applegate KE, Anderson JM, Klatte EC. Intestinal malrotation in children: a problem-solving approach to the upper gastrointestinal series. Radiographics 2006;26(05):1485–1500
3 Snyder WH Jr, Chaffin L. Embryology and pathology of the intestinal tract: presentation of 40 cases of malrotation. Ann Surg 1954;140(03):368–379
4 Alani M, Rentea RM. Midgut Malrotation. StatPearls; 2021
5 Balamoun H, Mohammad R, Hamade A. Reversed rotation of the midgut in adults–a case report. Ann R Coll Surg Engl 2010;92(07): W3-5
6 Tackett JJ, Muise ED, Cowles RA. Malrotation: Current strategies navigating the radiologic diagnosis of a surgical emergency. World J Radiol 2014;6(09):730–736
7 Orzech N, Navarro OM, Langer JC. Is ultrasonography a good screening test for intestinal malrotation? J Pediatr Surg 2006; 41(05):1005–1009
8 Sizemore AW, Rabbani KZ, Ladd A, Applegate KE. Diagnostic performance of the upper gastrointestinal series in the evaluation of children with clinically suspected malrotation. Pediatr Radiol 2008;38(05):518–528
9 Taylor GA. CT appearance of the duodenum and mesenteric vessels in children with normal and abnormal bowel rotation. Pediatr Radiol 2011;41(11):1378–1383
10 Shalaby MS, Kuti K, Walker G. Intestinal malrotation and volvulus in infants and children. BMJ 2013;347:f6949

 © 2022. Indian Society of Gastrointestinal and Abdominal Radiology. All rights reserved.