Article published online: 2022-08-15

An Unusual Presentation of Primary Hepatic Lymphoma

Pavan BS[1] Nishat Amina[1] Rama Anand[1] O.P Pathania[2]

[1] Department of Radiodiagnosis, Lady Hardinge Institute of Medical Sciences, Delhi, India
[2] Department of Surgery, Lady Hardinge Institute of Medical Sciences, Delhi, India

Address for correspondence Rama Anand, MD, Department of Radiodiagnosis, Lady Hardinge Institute of Medical Sciences, Delhi 110001, India (e-mail: rama_home@yahoo.com).

J Gastrointestinal Abdominal Radiol ISGAR 2022;5:209–212.

Abstract

Primary hepatic lymphoma (PHL) is a rare disease that usually manifests as a heterogenous solitary intrahepatic mass, multiple lesions or a diffuse infiltrative form. PHL presenting as a small focal area of hepatic involvement and a large predominant extrahepatic component is uncommon. We report a histopathologically proven case of primary hepatic lymphoma that caused significant diagnostic dilemma on contrast-enhanced computed tomography due to its unusual imaging appearance as a hypo-enhancing intra-abdominal solid mass with relatively small area of hepatic parenchymal involvement and a large exophytic component.

Keywords
- primary hepatic lymphoma
- exophytic
- CECT

Introduction

Lymphomatous involvement of the liver may manifest at imaging as a discrete focal liver mass or masses and diffuse infiltrating disease.[1–3] The most common imaging manifestation of PHL is a solitary discrete lesion, which is seen in ~60% of cases. Multiple lesions are seen in 35 to 40% of patients.[4] Diffuse infiltration is uncommon in PHL. Multifocal lesions or diffuse infiltration is the most common pattern of secondary hepatic lymphoma (SHL).[5] Here we report a case of PHL showing predominant exophytic component along with involvement of the antro-pyloric region of the stomach. The imaging appearances of PHL with differential diagnosis and a brief review of literature is discussed. To the best of our knowledge, this appearance of PHL with a predominant large exophytic component has not been reported previously in the literature.

Case Report

A 65-year-old woman presented with complains of slowly progressive abdominal distention since 6 to 8 months. The patient did not have any history of fever, icterus, night sweats, or weight loss. The patient had a past history of cholecystectomy 12 years ago. Chest radiograph was normal.

Physical examination per abdomen revealed a large mass approximately measuring 12×10 cm extending from the epigastrium up to the hypogastrium, firm in consistency, well-defined mostly with palpable margins. Laboratory investigations including liver function tests were normal and the patient was negative for HBsAg.

USG abdomen revealed a large well-defined solid homogenous hypoechoic mass (►**Fig. 1A**) involving the central and right side of the abdomen, extending from the epigastrium up to the suprapubic region along with periportal and peripancreatic lymphadenopathy (►**Fig. 1B**). A small area of focal hepatic involvement was noted in the left hepatic lobe. Other abdominopelvic structures, including uterus and bilateral adnexa, were normal.

CECT abdomen was performed subsequently with acquisition of limited plain scan, followed by post contrast scan in the portovenous phase. CECT revealed a large well-defined homogenous intraabdominal solid mass measuring ~16×12

published online
August 15, 2022

DOI https://doi.org/10.1055/s-0042-1749673.
ISSN 2581-9933.

© 2022. Indian Society of Gastrointestinal and Abdominal Radiology. All rights reserved.
This is an open access article published by Thieme under the terms of the Creative Commons Attribution-NonDerivative-NonCommercial-License, permitting copying and reproduction so long as the original work is given appropriate credit. Contents may not be used for commercial purposes, or adapted, remixed, transformed or built upon. (https://creativecommons.org/licenses/by-nc-nd/4.0/)

Thieme Medical and Scientific Publishers Pvt. Ltd., A-12, 2nd Floor, Sector 2, Noida-201301 UP, India

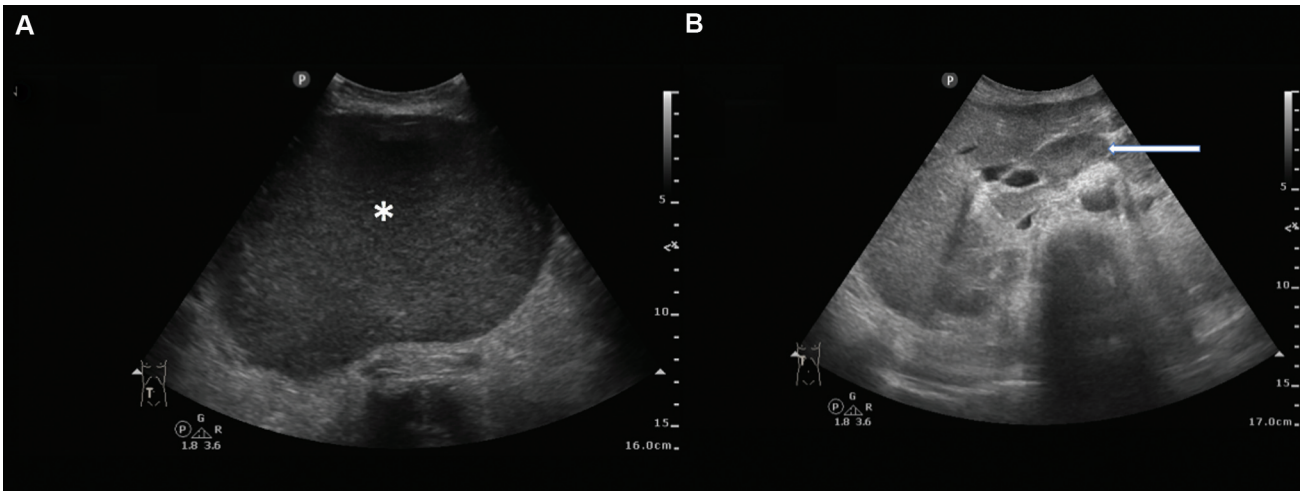

Fig. 1 Grayscale USG axial images (**A, B**) demonstrating A large hypoechoic mass (*) in the central abdomen with periportal lymphadenopathy (arrow) .

× 18 cm (TRxAPXCC) in the gastrohepatic region, in close proximity with the antro-pyloric part of the stomach (►**Fig. 2A**) closely abutting its anteromedial wall with loss of fat planes (possible site of origin). The mass was also infiltrating the segments IV a, IV b, and III of the liver (►**Fig. 2B, C**). The mass appeared hypoenhancing compared with rest of the liver parenchyma, and small branches from the left hepatic artery and gastroduodenal artery were seen supplying the mass.

It was causing posterior displacement of the transverse (TR) colon and pancreas and peripheral displacement of small bowel loops, suggestive of intraperitoneal location and was also abutting the anterior abdominal wall. A few hypodense necrotic areas were seen within the mass. No evidence of calcification/fat/hemorrhage was seen within the mass.

Multiple enlarged, homogenously enhancing discrete lymph nodes were noted in peri-portal, peri-pancreatic, peri-gastric (►**Fig. 2D**) along the lesser curvature of the stomach and epicardio phrenic region, the largest of them measuring 36 × 38 mm in the peri-portal region.

The rest of the solid organs including the spleen appeared normal in size and echotexture.

On the basis of imaging findings, likely diagnosis of gastrointestinal stromal tumor possibly originating from the

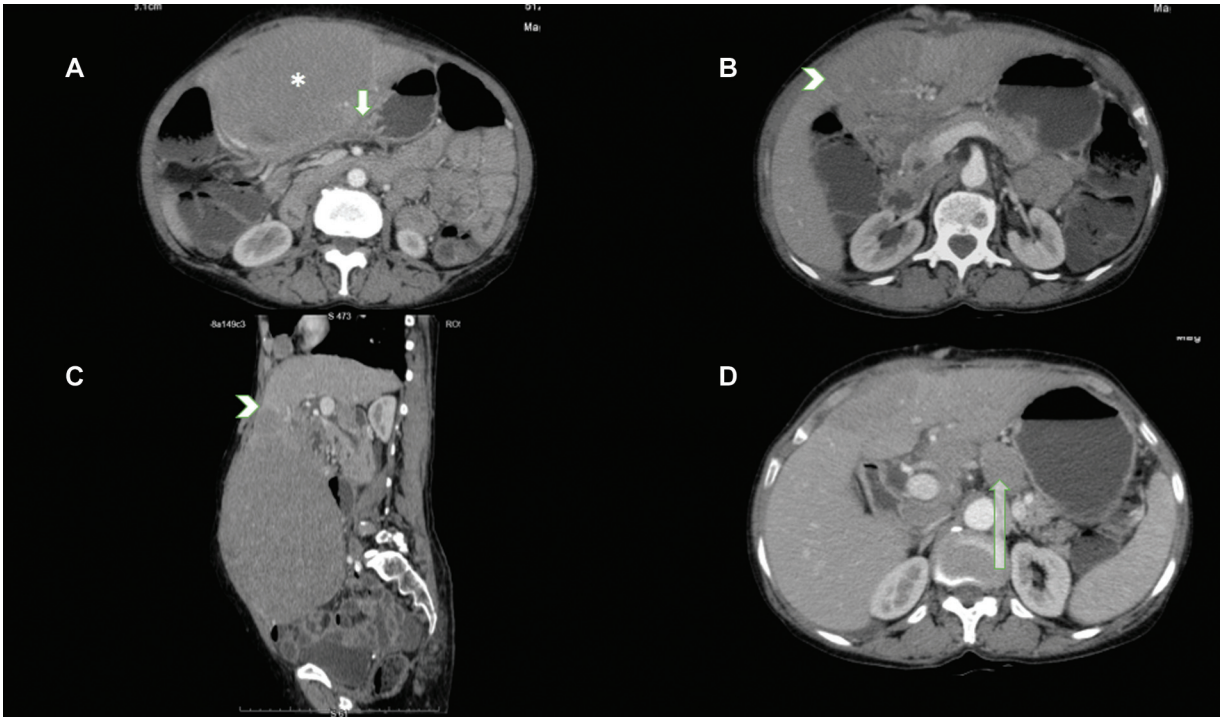

Fig. 2 Axial and sagittal CECT images (**A–C**) showing a large homogenous, hypoenhancing mass(*) in the gastrohepatic region, closely abutting the antropyloric region of the stomach (short arrow) with the involvement of the left lobe of the liver (arrow heads). Axial CECT image (**D**) at the level of porta hepatis displaying enlarged peri portal lymph nodes (long arrow).

 © 2022. Indian Society of Gastrointestinal and Abdominal Radiology. All rights reserved.

antro-pyloric region of the stomach with focal hepatic infiltration was suggested with a differential diagnosis of exo-enteric gastric lymphoma with focal hepatic involvement.

The patient was operated; intraoperatively, the mass was seen to abut the pyloric end of the stomach along with the involvement of segments III and IV of the liver. The mass was excised in toto with segmental hepatectomy along with distal gastrectomy and omentectomy.

On histopathology and immunohistochemistry (►**Fig. 3A, B**), the mass was diagnosed as primary non-Hodgkin's hepatic lymphoma B cell type with infiltration into the antropyloric region of the stomach and omentum.

Discussion

Secondary hepatic involvement can be seen in up to 50% of patients with non-Hodgkin's lymphoma and in ~20% of patients with Hodgkin's lymphoma.[6] PHL represents < 1% of all non-Hodgkin's lymphoma cases.[3,7] It is defined as a lymphoma that is confined to the liver and perihepatic lymph nodal sites at patient presentation, without distant involvement.[2,3]

The various known patterns of imaging manifestation of lymphomatous involvement of the liver are:

Nodular (Mass-forming) Pattern

(a) Solitary discrete lesion: PHL on imaging most commonly presents as a solitary lesion seen in ~60% of cases.[8] SHL, however, manifests as a solitary lesion in only ~10% of cases. It is homogeneously hypodense on non–contrast-enhanced computed tomographic scan. The majority of the lesions demonstrate minimal to no enhancement on all the phases. Enhancement, when present, is characteristically less than the surrounding hepatic parenchyma.[9]

(b) Multifocal lesions: Multiple variable sized discrete hepatic lesions have been reported in ~35 to 40% of cases of PHL[3,8] although one of the lesions is typically dominant.[9]

Diffuse Infiltration

Infiltration of tumor cells into the portal tracts as well as sinusoids is one of the most common patterns of hepatic involvement in cases of SHL. It is rare in PHL, but when present, it portends a poor prognosis.[10,11]

Periportal Mass

This variant manifests in the form of periportal soft-tissue cuffing or ill-defined mass.[10,11] Both primary and secondary forms of hepatic lymphoma can present in this manner.

Unlike the usual imaging presentations of PHL described in the literature, the mass in our case showed atypical imaging appearance, creating a diagnostic dilemma. Because the mass was located in the gastrohepatic region with only a small area of focal hepatic involvement and a large predominant extrahepatic component with infiltration of the antropyloric region of the stomach, we had kept a diagnosis of malignant gastric gastrointestinal stromal tumor (GIST) likely originating from the antropyloric region of the stomach with focal hepatic infiltration.

Another possible differential of gastric lymphoma was considered in view of the relatively hypoenhancing nature of the mass and bulky periportal, peripancreatic, perigastric lymphadenopathy.

The diagnosis of PHL was not considered based on imaging findings as, such a large exophytic solid mass with only focal hepatic involvement has not been described in the previous literature. However, histopathological examination showed that the mass was primary non-Hodgkin's lymphoma B cell type of the liver with metastases in the peritoneum and peripancreatic lymph nodes.

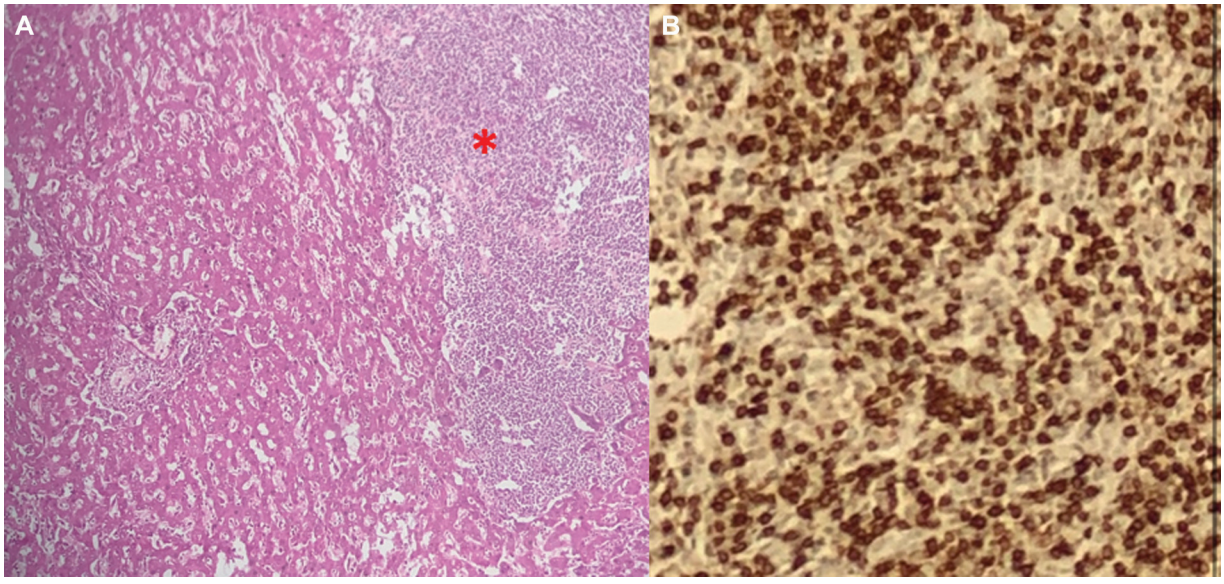

Fig. 3 Hematoxylin and eosin stain image (100 x) (**A**) showing normal liver and malignant lymphocytes (*) interface. Ventana stain image (400 x) (**B**) displaying CD20 immunohistochemistry.

 © 2022. Indian Society of Gastrointestinal and Abdominal Radiology. All rights reserved.

To the best of our knowledge, there has not been any previously reported case of PHL with predominantly exophytic component as described in our index case.

Conclusion

PHL is a rare disease that can sometimes show unusual imaging appearance as a relatively small area of hepatic parenchymal involvement with bulk of the lesion lying outside the liver parenchyma abutting the adjacent organs and leading to diagnostic dilemma. Therefore, the interpreting radiologist should be aware of different atypical imaging manifestations of PHL along with important differential diagnosis.

Funding
None.

Conflict of Interest
None declared.

References

1 Alves AMA, Torres US, Velloni FG, Ribeiro BJ, Tiferes DA, D'Ippolito G. The many faces of primary and secondary hepatic lymphoma: imaging manifestations and diagnostic approach. Radiol Bras 2019;52(05):325–330
2 Elsayes KM, Menias CO, Willatt JM, Pandya A, Wiggins M, Platt J. Primary hepatic lymphoma: imaging findings. J Med Imaging Radiat Oncol 2009;53(04):373–379
3 Tomasian A, Sandrasegaran K, Elsayes KM, Shanbhogue A, Shaaban A, Menias CO. Hematologic malignancies of the liver: spectrum of disease. Radiographics 2015;35(01):71–86
4 Bach AG, Behrmann C, Holzhausen HJ, Spielmann RP, Surov A. Prevalence and imaging of hepatic involvement in malignant lymphoproliferative disease. Clin Imaging 2012;36(05): 539–546
5 Ross A, Friedman LS. 2006The liver in systemic disease. In: Bacon BR, O'Grady JG, Di Bisceglie AM, Lake JRet al (eds) Comprehensive clinical hepatology 2nd ed. Mosby Elsevier Ltd.Philadelphia 537–547
6 Page RD, Romaguera JE, Osborne B, et al. Primary hepatic lymphoma: favorable outcome after combination chemotherapy. Cancer 2001;92(08):2023–2029
7 Maher MM, McDermott SR, Fenlon HM, et al. Imaging of primary non-Hodgkin's lymphoma of the liver. Clin Radiol 2001;56(04): 295–301
8 Emile JF, Azoulay D, Gornet JM, et al. Primary non-Hodgkin's lymphomas of the liver with nodular and diffuse infiltration patterns have different prognoses. Ann Oncol 2001;12(07): 1005–1010
9 Sanders LM, Botet JF, Straus DJ, Ryan J, Filippa DA, Newhouse JH. CT of primary lymphoma of the liver. AJR Am J Roentgenol 1989; 152(05):973–976
10 Coakley FV, O'Reilly EM, Schwartz LH, Panicek DM, Castellino RA. Non-Hodgkin lymphoma as a cause of intrahepatic periportal low attenuation on CT. J Comput Assist Tomogr 1997;21(05): 726–728
11 Park KY, Yu JS, Yoon SW, Park MS, Koo JS, Kim KW. Burkitt's lymphoma representing periportal infiltrating mass on CT. Yonsei Med J 2004;45(04):723–726

 © 2022. Indian Society of Gastrointestinal and Abdominal Radiology. All rights reserved.