



# Is Shoulder Imbalance a Useful Parameter in the Screening of Idiopathic Scoliosis? A Preliminary Study\*

## *O desequilíbrio do ombro é um parâmetro útil na triagem da escoliose idiopática? Um estudo preliminar*

Pedro Augusto Rocha Torres<sup>1</sup> Andre Moreira Castilho<sup>2</sup> Kamila Rayane Campos Lopes<sup>3</sup>  
Leonardo Pellizzoni<sup>4</sup> Orlando Righesso<sup>5</sup> Asdrubal Falavigna<sup>6</sup>

<sup>1</sup> Orthopedist, Department of Orthopedics and Spine Surgery, Fundação Hospitalar São Francisco de Assis (FHFSa), Belo Horizonte, MG, Brazil

<sup>2</sup> Orthopedist, Spine Surgeon, Department of Orthopedics and Spine Surgery, Hospital Mater Dei, Belo Horizonte, MG, Brazil

<sup>3</sup> Biomedic, Nursing Technician, Department of Biomedical and Nursing, Hospital Unimed, Belo Horizonte, MG, Brazil

<sup>4</sup> Information System Specialist, Universidade de Caxias do Sul, Caxias do Sul, RS, Brazil

<sup>5</sup> Orthopedist, Spine Surgeon, Department of Orthopedics, Universidade de Caxias do Sul, Caxias do Sul, RS, Brazil

Address for correspondence Pedro Augusto Rocha Torres, Rua da Bahia, 2596, 604, Belo Horizonte, MG 30160-012, Brazil (e-mail: pedroartorres@gmail.com).

<sup>6</sup> Neurosurgeon, Coordinator of the Health Science Postgraduate Program of Neurosurgery, Universidade de Caxias do Sul (UCS), Caxias do Sul, RS, Brazil

Rev Bras Ortop 2023;58(4):e625–e631.

### Abstract

**Objective** The present study aims to analyze the use of shoulder imbalance as a parameter for scoliosis screening as well as its relationship with other parameters of physical examination.

**Methods** This study assesses a smartphone application that analyzes several parameters of the physical examination in adolescent idiopathic scoliosis. Medical and non-medical examiners applied the screening tool in students in a public school and in a private sports club. After data collection, interobserver correlation was done to verify shoulder imbalance and to compare shoulder imbalance with Adam's bending test and with trunk rotation.

**Results** Eighty-nine participants were examined, 18 of whom were women and 71 of whom were men. Two subjects were excluded from the analysis. The mean age of subjects from the public school was 11.30 years and, for those from the sports club, it was 11.92 years. The examiners had poor-to-slight interobserver concordance on shoulder asymmetry in the anterior and posterior view. No significant statistical correlation was found between shoulder asymmetry and positive Adam's forward bending test.

### Keywords

- ▶ congenital abnormalities
- ▶ public health
- ▶ spine
- ▶ scoliosis
- ▶ mass screening

\* Study conducted at the Hospital Mater Dei, Belo Horizonte, Minas Gerais, Brazil.

received  
January 20, 2022  
accepted  
April 18, 2022

DOI <https://doi.org/10.1055/s-0042-1749462>.  
ISSN 0102-3616.

© 2022. Sociedade Brasileira de Ortopedia e Traumatologia. All rights reserved.

This is an open access article published by Thieme under the terms of the Creative Commons Attribution-NonDerivative-NonCommercial-License, permitting copying and reproduction so long as the original work is given appropriate credit. Contents may not be used for commercial purposes, or adapted, remixed, transformed or built upon. (<https://creativecommons.org/licenses/by-nc-nd/4.0/>)

Thieme Revinter Publicações Ltda., Rua do Matoso 170, Rio de Janeiro, RJ, CEP 20270-135, Brazil

**Resumo****Palavras-chave**

- ▶ anormalidades congênitas
- ▶ saúde pública
- ▶ coluna vertebral
- ▶ escoliose
- ▶ programas de rastreamento

**Conclusion** Our preliminary study shows that the shoulder asymmetry has a poor correlation with the Adam's forward bending test and measuring trunk rotation using a scoliometer. Therefore, the use of shoulder imbalance might not be useful for idiopathic scoliosis screening.

*Level of Evidence III; Diagnostic Study*

**Objetivo** O objetivo deste estudo é analisar o uso da assimetria de ombros como parâmetro para a triagem de escoliose e sua relação a outros parâmetros do exame físico.

**Métodos** Este estudo avalia um aplicativo para *smartphone* que analisa diversos parâmetros do exame físico de adolescentes com escoliose idiopática. Examinadores médicos e não médicos utilizaram o instrumento de triagem em alunos de uma escola pública e de um clube esportivo privado. Após a coleta de dados, a correlação interobservador foi determinada para verificar a assimetria de ombros e compará-la ao teste de inclinação de Adam e à medição de rotação do tronco.

**Resultados** Oitenta e nove participantes foram examinados, sendo 18 do sexo feminino e 71 do sexo masculino. Dois indivíduos foram excluídos da análise. A média de idade dos participantes da escola pública foi de 11,30 anos e do clube esportivo, 11,92 anos. Os examinadores apresentaram concordância interobservador baixa a branda quanto à assimetria de ombros em incidência anterior e posterior. Não houve correlação estatística significativa entre a assimetria de ombros e o resultado positivo no teste de inclinação do tronco de Adam.

**Conclusão** Nosso estudo preliminar mostra que a assimetria de ombros tem baixa correlação com o teste de inclinação de Adam e assim como com a medição de rotação do tronco com escoliómetro. Portanto, o uso da assimetria de ombros pode não ser útil na triagem da escoliose idiopática.

*Nível de Evidência III; Estudo Diagnóstico*

**Introduction**

Adolescent idiopathic scoliosis (AIS) is a structural, lateral, rotated curvature of the spine that arises in otherwise healthy children at or around puberty.<sup>1</sup> It is the most common spinal disorder in adolescents, with a prevalence of 1 to 4%.<sup>2</sup> Early diagnosis of scoliosis allows timely treatment of the condition in its initial stages, avoiding surgical treatment and deformity progression.<sup>3</sup> Consequently, scoliosis screening has been advocated for early detection of reversible spinal curves before their progression.<sup>4</sup>

The screening of idiopathic scoliosis is widely discussed in the medical literature.<sup>5</sup> It involves different types of assessment methods, including visual inspection, forward bending tests, scoliometer measurements, and individual Moiré topography, which are straight forward and easily accessible.<sup>6</sup> The main findings of scoliosis on physical examination are asymmetry of the shoulders, scapulae, pelvis, trunk, and ribcage.<sup>3</sup> The Adam's forward bend test is used to assess the presence of a hump and quantify the lateral curvature; it is considered essential for the screening of scoliosis in schools.<sup>1,7,8</sup> In Hong Kong, Netherlands and Singapore, countries with strong scoliosis screening programs, the most frequent parameter are the Adam's forward bending test and the measuring of trunk rotation using a scoliometer.<sup>5,9,10</sup>

Among all parameters on physical examination, shoulder imbalance has received a great deal of attention among spine surgeons and researches alike.<sup>11,12</sup> The normal healthy population is considered to have level shoulders.<sup>13</sup> In any measured biological parameter, it is of prime importance that the variability of what is classified as 'normal' is known, especially if surgery is planned to correct that parameter from what is judged as 'abnormal' back to being 'normal'.<sup>14</sup> In an attempt to define what is normal, Kuklo et al.<sup>11</sup> proposed shoulder balance as a lower than 1 cm side-to-side difference between the shoulders on clinical examination in adolescent idiopathic scoliosis patients.

The deficiencies of the traditional assessment methods for screening scoliosis remain unresolved.<sup>15</sup> Regardless, an even more effective method is still crucial for reducing morbidities associated with scoliosis. The present study aims to analyze the use of shoulder imbalance as a parameter for scoliosis screening and its relationship with other parameters of physical examination.

**Methods****Type of Study**

We performed a cross-sectional study to assess idiopathic scoliosis among students aged 8 to 17 years in a public and a private school as well as in an athletic club.

The project was approved by the ethics committee (CAAE 07926919.5.0000.5128). The confidentiality and privacy of the patients will be guaranteed throughout all stages of the study, according to the principles of medical ethics.

### Eligibility Criteria

#### Inclusion Criteria

1. Students at a public school, a private school, and members of an athletic club, aged 8 to 17 years, who accepted to participate willingly in the study and signed an informed consent document were included in the present study. The participants' guardians also needed to sign an informed consent form.

#### Exclusion Criteria

1. Previous spine surgery.
2. Previous diagnosis and treatment of scoliosis.
3. Diseases of the nervous system that compromise ambulation.
4. Understanding or cognitive problems.

#### Sample Size Calculation

The posthoc sample size calculation was done using the software R utilizing the Cohen Kappa coefficient (IRR) with a concordance level of 5% and a confidence interval of 95%. Considering the shoulder imbalance parameter in frontal and posterior view and the comparison of each examiner, the average number of participants was 74 (minimum 62 and maximum 87).

#### Study Locations

The locations were selected based on those that were the most representative of the sample: a public municipal school and a private athletic club. The data was first collected in the public school. Due to bureaucratic difficulties in the public school and also to have a more heterogeneous sample, we extended the locations to the athletic club and to a private school. In these two locations, we had a more controlled environment. In the sport club, we started the survey with the boys, all basketball players, but before we could enroll the female group in the analysis, we had to interrupt our study because of the coronavirus disease 2019 (COVID-19) pandemic. We could not evaluate the students at the private school for the same reason.

#### Selection and Training of Examiners

The examiners were selected aiming to include at least one examiner who was experienced in the evaluation of individuals with adolescent idiopathic scoliosis (gold-standard examiner), one orthopedist specialized in spinal surgery (inexperienced medical examiner), and one non-medical examiner.

The examiners were trained for this activity and supervised by the main researcher specialized in scoliosis. The team of examiners was composed of one orthopedist specialized in spinal surgery (ExL), one surgical instrument technician (Ex1), and one orthopedist in the 1st year of training in spinal surgery (Ex2).

### Description of the Application

The children and adolescents were evaluated by the Scoliosis Screen mobile app, available for iOS or Android (see electronic attachment: <https://youtu.be/fs3aNBnf404>). The application was developed at our university and is available in the Brazilian Apple and Google stores. The evaluators were trained to use the software app and its tutorials.

### Analyzed Variables

The application assesses the following variables: head, shoulder, waist, ribcage, and pelvic asymmetry in anterior and posterior view, the presence of kyphosis and of a hump (Adam's test); and, finally, the measurement of upper, mid, and lower thoracic scoliosis using the scoliometer (included in the sequence of evaluation utilizing the smartphone accelerometer). The interobserver correlation of these variables between the examiners was analyzed as well as the correlation of shoulder imbalance with the Adam's test, scoliometer measure, and presence of a hump. The definition of shoulder imbalance was visual, as seen in ►Figs. 1 and 2.

### Phases of the Evaluation

The examination of each subject was conducted by two alternate examiners in the following manner: - Ex1-ExL; Ex1-Ex2. The subjects wore a short-sleeved T-shirt and shorts or a jersey jacket. The examination was conducted

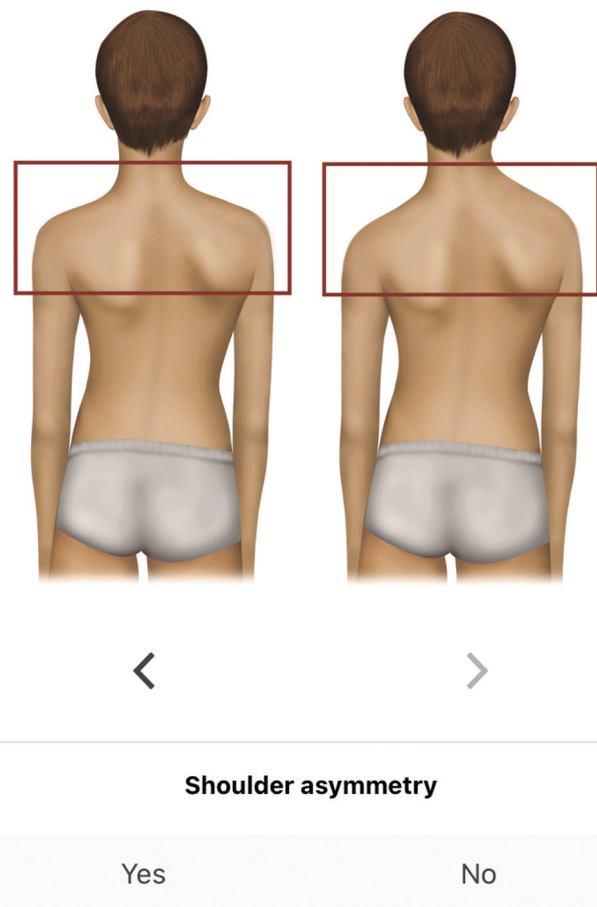


Fig. 1 Shoulder asymmetry parameter in posterior view.



**Fig. 2** Shoulder asymmetry parameter in anterior view.

in a reserved and quiet environment. The subjects who presented with positive Adam's test, shoulder asymmetry, and a reading superior to  $2^\circ$  on the scoliometer were invited to attend a free consultation with the leading researcher. This clinical criterion was chosen to assess the use of shoulder imbalance as a parameter for further investigation. The leading researcher receives an email from the application whenever the alterations are detected and sends a letter to the guardians inviting them to the specialized medical consultation.

### Statistical Analysis

The data collected were initially entered into an Excel spreadsheet (Microsoft Corp., Redmond, WA, USA) spreadsheet and subsequently analyzed using the IBM SPSS Statistics for Windows, Version 26.0 (IBM Corp., Armonk, NY, USA) statistical package. The normality of the continuous data was assessed using the Shapiro-Wilk test. The anthropometric data were expressed as means, standard deviations, medians, and minimum and maximum values. The changes observed on physical examination were presented in contingency tables and expressed as absolute (n) and relative (%) frequencies. The agreement between the researcher and the exam-

**Table 1** Description of age and anthropometric profile of the adolescents from the public school by different examiners

	Mean	SD	Median	Minimum	Maximum
Age of the adolescent (years)	11.3	1.5	11.0	9.0	16.0
Weight (kg)	39.0	8.5	38.0	23.0	57.00
Height (cm)	150.0	10.0	152.0	130.0	163.0
BMI	17.9	2.2	17.5	14.3	21.6

Abbreviations: BMI, body mass index; SD, standard deviation

iner was assessed with the Kappa test. The level of significance was set at 5% ( $p < 0.05$ ) in all analyses.

## Results

### Anthropometric Data

The data were collected between August and December 2019. The number of participants was 89. Of these, 18 were women and 71 were men. Two subjects were excluded from the analysis, namely one subject who had already been diagnosed with neuromuscular scoliosis and one with adolescent idiopathic scoliosis under medical monitoring. The mean age of subjects from the public school was 11.3 years, the mean weight 39,0 Kg, the mean height 1,5 meters, and a BMI (body mass index) of 17,9 (► **Table 1**). In the athletic club, the mean age was 11.92 years, the mean weight 61,2 Kg, the mean height 1,71 meters, and a mean BMI of 20,3 (► **Table 2**).

### Interobserver and Parameters Correlations

The ExL evaluated 54 individuals and referred 11 for re-assessment. Nine of these had shoulder asymmetry and 2 had a curvature with a rotation  $> 2^\circ$ . The Ex1 evaluated 87 individuals and referred 24 for re-assessment. Twenty-four of these had shoulder asymmetry, 5 had a hump, and 5 had changes in the scoliometer readings. The Ex2 evaluated 33 individuals and referred 11 of these, all with shoulder asymmetry. The ExL and Ex1 achieved poor concordance in shoulder asymmetry in anterior and posterior view and had slight agreement in posterior shoulder asymmetry, but poor concordance in anterior shoulder imbalance. ► **Tables 3** and **4** show

**Table 2** Description of age and anthropometric profile of the adolescents from the athletic club by different examiners

	Mean	SD	Median	Minimum	Maximum
Age of the adolescent (years)	11.9	1.4	12.0	8.0	14.0
Weight (kg)	61.2	19.1	56.0	34.0	99.0
Height (cm)	171.0	13.0	171.0	147.0	191.0
BMI	20.3	4.2	19.8	15.5	30.3

Abbreviations: BMI, body mass index; SD, standard deviation

**Table 3** Analysis of the agreement on shoulder asymmetry in posterior and anterior view between the examiners ExL and Ex1

	ExL n (%)	Ex1 n (%)	Total	Kappa	P-value
Shoulder asymmetry (posterior)	9 (16.7)	12 (22.2)	21 (19.4)	0.0	1.00
Shoulder asymmetry (anterior)	14 (25.9)	13 (24.1)	27 (25.0)	0.16	0.23

Abbreviations: %, relative frequency; Ex1, examiner surgical instrument technician; ExL, examiner orthopedist specializing in spine surgery; Kappa, Kappa test; n, absolute frequency; na, not applicable

**Table 4** Analysis of the agreement on shoulder asymmetry in posterior and anterior view between the examiners Ex1 and Ex2

	Ex1 n (%)	Ex2 n (%)	Total	Kappa	P-value
Shoulder asymmetry (posterior)	11 (33.3)	11 (33.3)	22 (33.3)	0.32	0.06
Shoulder asymmetry (anterior)	12 (36.4)	8 (24.2)	20 (30.3)	0.15	0.35

Abbreviations: %, relative frequency; Ex1, examiner surgical instrument technician; Ex2 orthopedist in the first year of training in spine surgery; Kappa, Kappa test; n, absolute frequency.

the analysis of the agreement on shoulder asymmetry in posterior and anterior view between the examiners.

The parameters that were found to have significant statistic association with shoulder asymmetry in posterior view, between ExL and Ex1, are waist and pelvis (posterior and frontal), ribcage (frontal) and shoulder frontal asymmetry. Between Ex1 and Ex2, the parameters that were found to have significant statistic association with shoulder asymmetry in posterior view are scapular, waist (anterior and posterior), pelvis (anterior and posterior), frontal ribcage, and shoulder anterior asymmetry and increased kyphosis. ► **Tables 5 and 6** show the analysis of comparison between shoulder asymmetry and other changes in physical examination.

► **Table 7** shows the relation between the presence of hump and shoulder asymmetry in frontal and posterior view. No significant statistical correlation between the parameters was found.

## Discussion

Shoulder asymmetry is a common parameter used in the clinical evaluation of adolescent idiopathic scoliosis. Our findings show that shoulder asymmetry has a poor-to-slight interobserver correlation. We also did not find a strong association between the presence of a hump and shoulder imbalance. However, the presence of a hump had a strong

**Table 5** Results of the comparison between shoulder asymmetry (posterior) and the other changes on physical examination

	Shoulder asymmetry n (%)		P-value*
	No	Yes	
Head asymmetry (posterior)	0 (0.0)	0 (0.0)	na
Scapular asymmetry (posterior)	9 (10.3)	10 (47.6)	< 0.001
Waist asymmetry (posterior)	9 (10.3)	10 (47.6)	< 0.001
Pelvic asymmetry (posterior)	9 (10.3)	8 (38.1)	0.002
Increased kyphosis	7 (8.0)	3 (14.3)	0.37
Reduced kyphosis	9 (10.3)	4 (19.0)	0.27
Increased lordosis	16 (18.4)	5 (23.8)	0.57
Reduced lordosis	5 (5.7)	0 (0.0)	0.26
Head asymmetry (anterior)	0 (0.0)	1 (4.8)	0.04
Shoulder asymmetry (anterior)	15 (17.2)	12 (57.1)	< 0.001
Ribcage asymmetry (anterior)	4 (4.6)	4 (19.0)	0.02
Waist asymmetry (anterior)	11 (12.6)	9 (42.9)	0.001
Pelvic asymmetry (anterior)	10 (11.5)	9 (42.9)	0.001
Upper thoracic scoliometer	2 (2.3)	1 (4.8)	0.53
Mid-thoracic scoliometer	2 (2.3)	1 (4.8)	0.53
Lower thoracic scoliometer	3 (3.4)	1 (4.8)	0.77

Abbreviations: %, relative frequency; \*Chi-squared test; n, absolute frequency; na, not applicable.

**Table 6** Results of the comparison between shoulder asymmetry (posterior) and the other changes on physical examination among Ex1 and Ex2

	Shoulder asymmetry n (%)		P-value*
	No	Yes	
Head asymmetry (posterior)	0 (0.0)	1 (4.5)	0.15
Scapular asymmetry (posterior)	6 (13.6)	13 (59.1)	< 0.001
Waist asymmetry (posterior)	6 (13.6)	11 (50.0)	0.001
Pelvic asymmetry (posterior)	6 (13.6)	8 (36.4)	0.03
Increased kyphosis	5 (11.4)	7 (31.8)	0.04
Reduced kyphosis	2 (4.5)	0 (0.0)	0.31
Increased lordosis	9 (20.5)	7 (31.8)	0.31
Reduced lordosis	2 (4.5)	1 (4.5)	1.00
Presence of hump (anterior)	0 (0.0)	1 (4.5)	0.15
Head asymmetry (anterior)	0 (0.0)	1 (4.5)	0.15
Shoulder asymmetry (anterior)	5 (11.4)	15 (68.2)	< 0.001
Ribcage asymmetry (anterior)	4 (9.1)	10 (45.5)	0.001
Waist asymmetry (anterior)	10 (22.7)	15 (68.2)	< 0.001
Pelvic asymmetry (anterior)	11 (25.0)	13 (59.1)	0.007

Abbreviations: %, relative frequency; \*Chi-squared test; n, absolute frequency.

**Table 7** Results of the comparison between presence of hump and shoulder asymmetry in posterior and anterior view

	Presence of hump n (%)		P-value*
	No	Yes	
Shoulder asymmetry (posterior)	20 (19.6)	1 (16.7)	0.86
Shoulder asymmetry (frontal)	25 (24.5)	2 (33.3)	0.62

Abbreviations: %, relative frequency; \*Chi-squared test; n, absolute frequency.

correlation with trunk asymmetry—scapular (posterior), waist and pelvis (posterior and frontal), ribcage (frontal), and shoulder frontal asymmetry.

The Adam's forward bend test is considered essential for the screening of scoliosis in schools.<sup>1,7,8</sup> In Hong Kong, Netherlands and Singapore, countries with a strong scoliosis screening program, the most frequent parameters are the Adam's forward bending test and the measurement of trunk rotation using a scoliometer.<sup>5,9,10</sup> However, Fong et al.<sup>5</sup> demonstrated that screening performed using only Adam's forward bend test is insufficient and results in a high rate of false positives. It is necessary to add other parameters to increase the quality of scoliosis screening. The combination of the scoliometer, Adam's forward bend test, and Moiré topography has a sensitivity and specificity close to 94% and 99%, respectively.<sup>15</sup> Even so, Moiré topography is not a widely used tool, and its application is restricted to a few centers.

Our study aims to evaluate the other physical parameters for scoliosis screening. We had a greater number of pupils with shoulder asymmetry than with positive result in the

Adam's test. This parameter needs an outpatient clinic's assessment to be validated. The subjects still need the next step of the evaluation with a specialized medical consultation and radiological images.

An important point is the definition of what constitutes shoulder asymmetry. Kuklo et al.<sup>11</sup> proposed shoulder symmetry as a side-to-side difference of less than 1 cm between the shoulders on clinical examination in adolescent idiopathic scoliosis patients. However, the study was done in patients with the diagnosis of scoliosis. Gardner et al.<sup>14</sup> demonstrated that a degree of asymmetry in shoulder and torso is also seen in a group of children and adolescents who do not have scoliosis. Akel et al.<sup>13</sup> demonstrated that healthy adolescents may have a difference of up to 27 mm between their shoulders without a change in their body image perception.

The difficulty in defining what is, in fact, shoulder asymmetry may be the cause of the low rate of interobserver concordance in our study. In our analysis, shoulder asymmetry was based on a visual observation of the patient comparing with an image of the application (► Figs. 1 and 2). The definition of shoulder asymmetry was subjective. Because of that, we found that an improvement of our application was needed to have a better concordance between the observers.

We did not find a significant difference in the prevalence of shoulder asymmetry between the school group and the athletic club group. The athletes analyzed in our study were all basketball players. Basketball is a sport that involves symmetrical effect on muscle structure. However, when first starting in the sport, the predominant use of the dominant side could lead to hypertrophy of the muscles involved. Despite that, our study did not show any difference between the groups.

The difficulty of data collection was one of the study's limitations. There was also greater difficulty because of COVID-19. Since this is a screening study, our sample is still not sufficiently representative, and another study will be required for further assessment and interpretation of the data.

The quality of the comparative analysis will improve once we obtain the data from the paired comparison between the leading examiner and other non-medical examiners (considering that the data collected so far were provided by only one non-medical examiner). It is important to analyze the results of the physical examination and X-ray after referral of individuals in whom the application showed alterations to a specialist. We will, then, be able to validate or not the use of shoulder imbalance as a useful parameter in the screening method.

## Conclusion

In conclusion, screening for idiopathic scoliosis is a public health concern. Our preliminary study showed a poor correlation between shoulder asymmetry, Adam's forward bending test, and measurement of trunk rotation using a scoliometer. Therefore, the use of shoulder imbalance might not be useful for scoliosis screening. However, this is a preliminary study, and the referred subjects still need the next step of the evaluation with a specialized medical consultation and radiological images.

### Financial Support

This study did not receive any financial support from public, commercial, or non-profit sources.

### Conflict of Interests

The authors have no conflict of interests to declare.

### Acknowledgments

We are grateful to the reviewers whose valuable comments were very helpful in improving the manuscript. We also thank the students and athletes for their availability and participation.

## References

- Weinstein SL, Dolan LA, Cheng JC, Danielsson A, Morcuende JA. Adolescent idiopathic scoliosis. *Lancet* 2008;371(9623):1527–1537
- Cheng JC, Castelein RM, Chu WC, et al. Adolescent idiopathic scoliosis. *Nat Rev Dis Primers* 2015;1:15030
- Hresko MT. Clinical practice. Idiopathic scoliosis in adolescents. *N Engl J Med* 2013;368(09):834–841
- Grivas TB, Wade MH, Negrini S, et al. SOSORT consensus paper: school screening for scoliosis. Where are we today? *Scoliosis* 2007;2:17
- Fong DY, Cheung KM, Wong YW, et al. A population-based cohort study of 394,401 children followed for 10 years exhibits sustained effectiveness of scoliosis screening. *Spine J* 2015;15(05):825–833
- Yang J, Zhang K, Fan H, et al. Development and validation of deep learning algorithms for scoliosis screening using back images. *Commun Biol* 2019;2:390
- Grauers A, Einarsdottir E, Gerdhem P. Genetics and pathogenesis of idiopathic scoliosis. *Scoliosis Spinal Disord* 2016;11:45
- Horne JP, Flannery R, Usman S. Adolescent idiopathic scoliosis: diagnosis and management. *Am Fam Physician* 2014;89(03):193–198
- Bunge EM, Juttman RE, Koning HJ. Steering Committee of the NESIO Group. Screening for scoliosis: do we have indications for effectiveness? *J Med Screen* 2006;13(01):29–33
- Wong HK, Hui JH, Rajan U, Chia HP. Idiopathic scoliosis in Singapore schoolchildren: a prevalence study 15 years into the screening program. *Spine (Phila Pa 1976)* 2005;30(10):1188–1196
- Kuklo TR, Lenke LG, Graham EJ, et al. Correlation of radiographic, clinical, and patient assessment of shoulder balance following fusion versus nonfusion of the proximal thoracic curve in adolescent idiopathic scoliosis. *Spine (Phila Pa 1976)* 2002;27(18):2013–2020
- Bago J, Pizones J, Matamalas A, D'Agata E. Clinical photography in severe idiopathic scoliosis candidate for surgery: is it a useful tool to differentiate among Lenke patterns? *Eur Spine J* 2019;28(12):3018–3025
- Akel I, Pekmezci M, Hayran M, et al. Evaluation of shoulder balance in the normal adolescent population and its correlation with radiological parameters. *Eur Spine J* 2008;17(03):348–354
- Gardner A, Berryman F, Pynsent P. What is the variability in shoulder, axillae and waist position in a group of adolescents? *J Anat* 2017;231(02):221–228
- Dunn J, Henrikson NB, Morrison CC, Blasi PR, Nguyen M, Lin JS. Screening for Adolescent Idiopathic Scoliosis: Evidence Report and Systematic Review for the US Preventive Services Task Force. *JAMA* 2018;319(02):173–187