



# Male-to-Female Gender Affirmation Vaginoplasty via Laparoscopic Pedicled Peritoneal Flap—An Initial Experience

Ashish Sachan<sup>1</sup> Pradeep Jain<sup>1</sup> Pankaj Sharma<sup>1</sup> Vivek Goel<sup>1</sup>

<sup>1</sup>Department of Gastrointestinal Surgery, Fortis Hospital, Shalimar Bagh, New Delhi, India

Address for correspondence Ashish Sachan, MCh, Department of Gastrointestinal Surgery, Fortis Hospital, Shalimar Bagh, Shalimar Bagh, New Delhi 110088, India (e-mail: ashuashuster@gmail.com).

Indian J Plast Surg 2022;55:211–215.

## Abstract

### Keywords

- ▶ gender affirmation surgery
- ▶ vaginoplasty
- ▶ laparoscopic pedicled peritoneal flap vaginoplasty
- ▶ pedicled peritoneal flap
- ▶ peritoneal vaginoplasty

**Objective** The objective of this study was to describe our early experience with laparoscopic pedicled peritoneal flap in patients undergoing male-to-female gender affirmation vaginoplasty.

**Methods** This is a case series of five patients who underwent laparoscopic pedicled peritoneal flap vaginoplasty for gender reaffirmation from October 2020 to July 2021. The clinical and functional outcomes were recorded.

**Results** Two patients underwent the surgery as a primary procedure, and three patients underwent surgery as a secondary deepening procedure after failed penile skin inversion. There were no complications after surgery, and the median length of hospital stay was 3 days. No patient developed vaginal stenosis in 6-month follow-up period, and the median vaginal depth was 6 inches with a healthy vaginal surface.

**Conclusion** Laparoscopic pedicled peritoneal flap can be considered as a first choice in gender affirmation surgeries for patients with inadequate penoscrotal skin or failed penile skin inversion.

## Introduction

Vaginoplasty is one of the most important steps in male-to-female gender affirmation surgery. The aim is to create a vaginal canal with adequate diameter and length, appropriate axial direction, and lubrication to accommodate for sexual intercourse.<sup>1</sup> The most commonly used techniques for the creation of a neovagina in gender affirmation surgery are penile skin inversion and intestinal vaginoplasty.<sup>2</sup> Peritoneal vaginoplasty is done for the reconstruction of the vagina in females born with congenital vaginal agenesis like the Mayer-Rokitansky-Kuster-Hauser (MRKH) syndrome.<sup>3</sup> The pedicled peritoneal flap in gender affirmation surgery can help in achieving a deeper neovaginal cavity with fewer

complications. We hereby describe our initial experience of five laparoscopic pedicled peritoneal flap vaginoplasty cases in male-to-female gender affirmation surgery.

## Patients and Methods

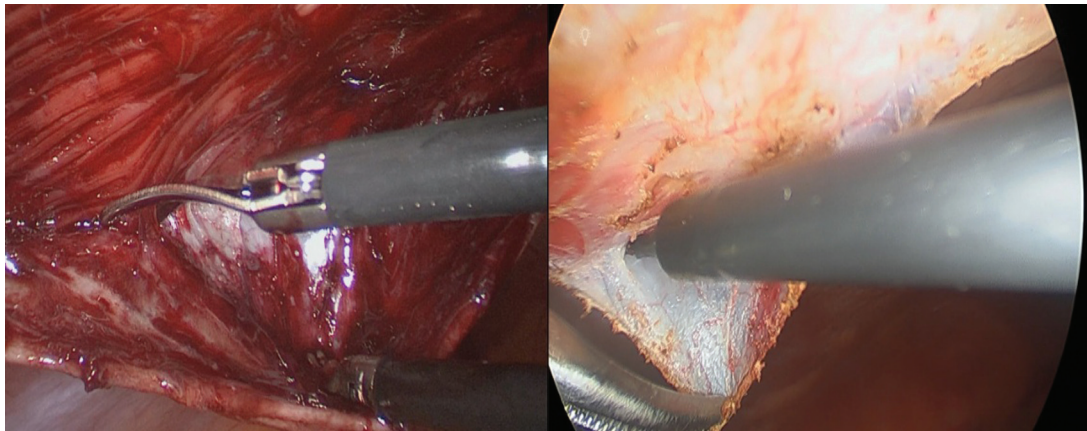
From October 2020 to July 2021, five patients underwent laparoscopic pedicled peritoneal flap vaginoplasty for gender reaffirmation in our center. Before surgery, all patients underwent diagnosis and evaluation by two different mental health professionals, as per the seventh version of standards of care (7th SOCs)<sup>4</sup> published by World Professional Association for Transgender Health, as well as ISOC 1, the Indian Standards of Care for persons with gender incongruence and

published online  
July 18, 2022

Issue Theme Gender  
Incongruence

DOI <https://doi.org/10.1055/s-0042-1749407>.  
ISSN 0970-0358.

© 2022. Association of Plastic Surgeons of India. All rights reserved. This is an open access article published by Thieme under the terms of the Creative Commons Attribution-NonDerivative-NonCommercial-License, permitting copying and reproduction so long as the original work is given appropriate credit. Contents may not be used for commercial purposes, or adapted, remixed, transformed or built upon. (<https://creativecommons.org/licenses/by-nc-nd/4.0/>)  
Thieme Medical and Scientific Publishers Pvt. Ltd., A-12, 2nd Floor, Sector 2, Noida-201301 UP, India



**Fig. 1** Flap creation laparoscopically.

people with differences in sexual development/orientation.<sup>5</sup> The patients had also lived in the desired gender role for a period of more than 12 months and took feminizing hormone therapy for more than 12 months. The patients were advised to stop hormone therapy from 4 weeks prior to surgery, to obviate the increased risk of thromboembolism. They were also advised to stop smoking for 1 month prior to surgery. Preoperative evaluation includes ultrasound abdomen, colonoscopy, and routine blood investigations. Preoperative bowel preparation was done in all patients. Patients' demographics, preoperative genitalia features, postoperative complications, length of hospital stay, and functional outcomes were recorded prospectively.

### Surgical Procedure

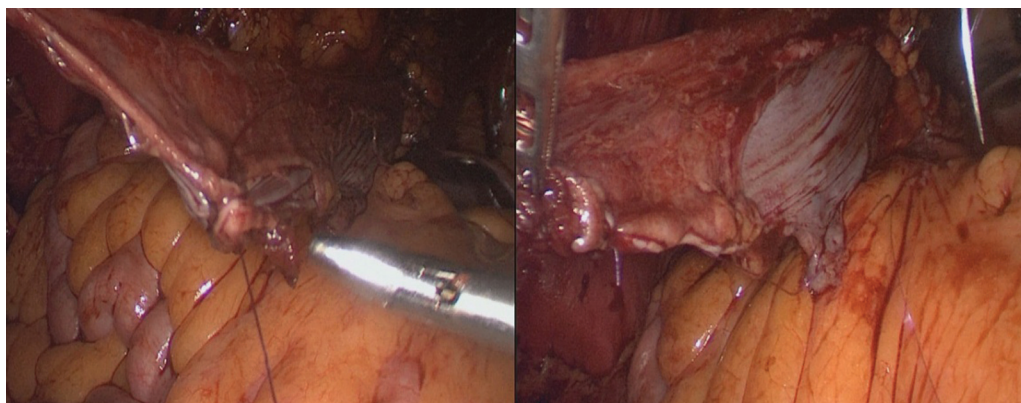
The surgical procedure was performed by a team of expert laparoscopic gastrointestinal surgeons and plastic surgeons. The procedure was divided into two parts—laparoscopic and perineal procedures.

### Laparoscopic Procedure

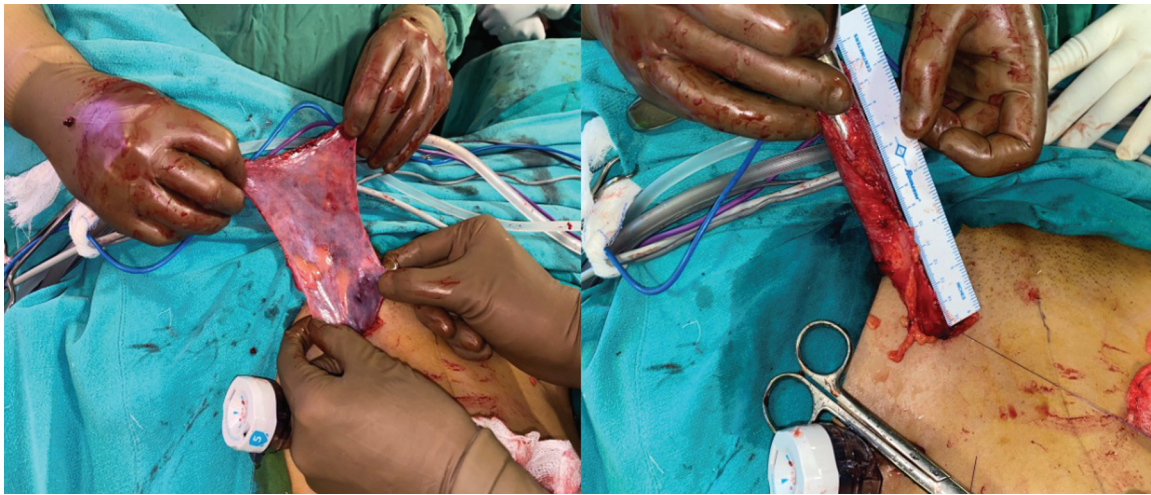
The three-dimensional laparoscopic vision system (Karl Storz SE & Co., Tuttlingen, Germany) was used for the surgery. The patient was placed in a lithotomy position with the table tilted

down to 30 degrees with the surgeon and cameraman standing on patient's right and assistant on the left. The pneumoperitoneum is created using Veress's needle and the CO<sub>2</sub> pressure was kept at 12 mm Hg. The camera port was inserted 8 cm above the umbilicus in the midline. The surgeon's right and left hand working ports were inserted 4 cm above the umbilicus along the midclavicular line on both sides. The peritoneal harvesting was started after marking the incision site initially with electrocautery. The flap was created starting from the cranial end toward the pelvis using sharp dissection with scissors to preserve the fine plexus over the peritoneal surface (**► Fig. 1**) (**► Supplementary Video 1**, online-only). The peritoneal branches of the deep inferior epigastric artery (DIEA) were preserved, and the perforators to the rectus abdominis muscle were divided. A rectangular flap of peritoneum 25 cm in length and 15 cm in width based on DIEA is created under vision. At the lower end, the DIEA pedicle was isolated and mobilized to the external iliac artery origin, which helped in rotating the flap toward the neovagina.

In one case, the flap tubing was performed intracorporeally. (**► Fig. 2**). In four cases, a left groin incision was given and developed in layers to reach the abdominal cavity. The harvested flap was taken out via the groin incision and was tubularized over a proctoscope using absorbable sutures



**Fig. 2** Intracorporeal flap tubularization.



**Fig. 3** Extracorporeal flap tubularization via groin incision over a proctoscope.

(► **Fig. 3**). After tubularization, the flap was delivered back to the abdomen with care, and attention was given to avoid any twisting of the flap.

#### Perineal Procedure

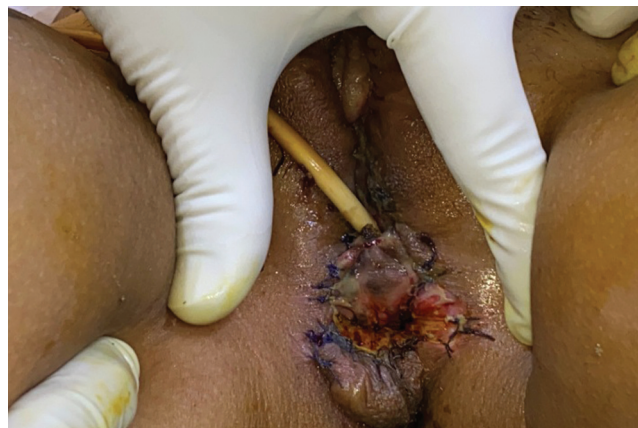The plastic surgery team began the perineal procedure simultaneously. The patient was placed in the Trendelenburg position and was catheterized. A 5-cm-long posteriorly based perineal flap was raised, centered over the perineal body. Incision was continued from the position of apex of the flap anteriorly, in midline raphe across the scrotal skin, midline of the ventral aspect of the penis, anteriorly, to join a circumcoronal penile degloving incision. Orchidectomy was done with the preservation of long lengths of cords bilaterally for incorporation in bilateral labia majora. Cavity dissection and penile disassembly were done as described in a previous publication.<sup>6</sup> Once the superior open end of the peritoneal flap reaches external incision, it was interdigitated with the triangular flap posteriorly and penile skin dartos flap anteriorly, to avoid a circular contracture (► **Fig. 4**). The neovaginal cavity was calibrated with a dilator and lightly packed

with a glove containing U foam, and a perineal dressing was done.<sup>6</sup>

#### Results

As per the standard follow-up protocol, the pack was removed after 1 week. The vaginal lining was inspected with a speculum, and the cavity was irrigated with betadine saline and dilated with the help of a dilator. The patient was also taught to self-dilate the neovaginal cavity and was advised to dilate three times a day for 3 months, at which time, she can resume regular sexual intercourse or continue dilatation with reduced frequency.

Five consecutive patients underwent pedicled peritoneal flap vaginoplasty between 2020 to 2021. Two patients underwent the surgery as a primary procedure, and three patients underwent surgery as a secondary deepening procedure after failed penile skin inversion. The patient's median age was 30 years. The median surgical time was 6 hours. The first surgery took 8 hours and gradually the operating time was reduced to 5 hours. There were no intraoperative or postoperative complications. The median hospital stay after surgery was



**Fig. 4** Final view.



3 days. In the median follow-up of 6 months, no patient developed vaginal stenosis. The median vaginal depth was 6 inches. The follow-up vaginoscopy showed a good lubricated and healthy vaginal surface (► **Supplementary Video 2**, online-only).

## Discussion

Among the vaginoplasty techniques for gender reaffirmation surgeries, penile skin inversion and intestinal vaginoplasty are the most popular techniques.<sup>2</sup> Penile skin inversion is the most commonly performed procedure and is often referred to as the gold standard technique for gender affirmation.<sup>7</sup> The common problems associated with the penile skin inversion technique are neovaginal stenosis and shallow vaginal depth. Intestinal vaginoplasty offers increased neovaginal length and well-lubricated mucosa but is associated with various disadvantages like intestinal resection and anastomosis, chances of anastomotic leak, and malodorous discharge from the vagina due to the production of mucus from the colonic graft.<sup>8</sup>

Davydov peritoneal vaginoplasty is used to reconstruct neovagina in patients with congenital vaginal atresia like the MRKH syndrome.<sup>9</sup> Peritoneal vaginoplasty offers various advantages like self-lubricating lining with elasticity, better vaginal depth, less risk of prolapse, and less discharge (compared with intestinal vaginoplasty). Also, it removes the potential risk associated with a bowel anastomotic leak.<sup>10</sup> According to Zhou et al, laparoscopic peritoneal vaginoplasty in the MRKH syndrome showed a good long-term functional outcome and sexual activity satisfaction was near 100% 1 year after surgery with continued sexual satisfaction in 80% patients at 15-year follow-up.<sup>11</sup>

According to a prospective randomized trial by Cao et al, the effectiveness and long-term anatomic and functional results of laparoscopic peritoneal vaginoplasty and laparoscopic sigmoid vaginoplasty in patients with vaginal agenesis were similar. The laparoscopic peritoneal vaginoplasty group had significantly less blood loss and shorter surgical time than the laparoscopic sigmoid colovaginoplasty group. Postoperative hospital stay was less for peritoneal vaginoplasty patients than for sigmoid vaginoplasty patients. Mean neovaginal length, excessive mucous production, sexual life initiation time, and sexual satisfaction rate were similar between groups. Patient complaints of abdominal discomfort, unusual odor from vaginal secretions, and vaginal contraction during intercourse were higher in the sigmoid colovaginoplasty group ( $p < 0.005$  vs. peritoneal vaginoplasty).<sup>12</sup>

Although Davydov peritoneal vaginoplasty is a popular approach in vaginal reconstruction, it is not used as an isolated technique for gender-affirming vaginoplasty and was used for vaginal deepening as a secondary procedure after failed penile skin inversion. Recently, Suwajo et al reported a case of successful laparoscopic pedicled peritoneal vaginoplasty for male-to-female gender reaffirmation surgery with a good neovaginal surface at 9 months after surgery and, histologically, the neovaginal lining was squamous epithelium.<sup>13</sup> In their study, the flap tubing was made

extracorporeally. In our study, the peritoneal flap was taken laparoscopically in all cases, flap tubing was made intracorporeal in one case and extracorporeal in other four cases. As per our literature search, this is the first reported case where the peritoneal graft was taken and tubularized laparoscopically in a gender affirmation surgery. Although we have a shorter follow-up of median 6 months, the patients have a good outcome after peritoneal vaginoplasty with good sexual outcomes and low complication rates.

## Conclusions

According to our experience, peritoneal vaginoplasty should also be offered as a primary procedure for patients desiring vaginal depths of up to 8 inches, not only in those patients with a secondary situation or having inadequate penoscrotal skin. Long-term follow-up will be needed to establish the laparoscopic pedicled peritoneal flap as an independent procedure for vaginoplasty in gender reaffirmation surgery.

### Supplementary Video 1

Creation of peritoneal flap laparoscopically. Online content including video sequences viewable at: <https://www.thieme-connect.com/products/ejournals/html/10.1055/s-0042-1749407>.

### Supplementary Video 2

Follow up vaginal dilatation. Online content including video sequences viewable at: <https://www.thieme-connect.com/products/ejournals/html/10.1055/s-0042-1749407>.

### Conflict of Interest

None declared.

## References

- 1 Langer M, Grünberger W, Ringler M. Vaginal agenesis and congenital adrenal hyperplasia. Psychosocial sequelae of diagnosis and neovagina formation. *Acta Obstet Gynecol Scand* 1990;69(04):343–349
- 2 Horbach SE, Bouman MB, Smit JM, Özer M, Buncamper ME, Mullender MG. Outcome of vaginoplasty in male-to-female transgenders: a systematic review of surgical techniques. *J Sex Med* 2015;12(06):1499–1512
- 3 Zhao XW, Ma JY, Wang YX, Zhang H, Zhang J, Kang S. Laparoscopic vaginoplasty using a single peritoneal flap: 10 years of experience in the creation of a neovagina in patients with Mayer-Rokitansky-Küster-Hauser syndrome. *Fertil Steril* 2015;104(01):241–247
- 4 Coleman E, Bockting W, Botzer M, et al. Standards of care for the health of transsexual, transgender, and gender-nonconforming people, version 7th. *Int J Transgend* 2012;13(04):. Doi: 10.1080/15532739.2011.700873
- 5 Gupta R, Kaushik N, Asokan A, et al. Surgical care: surgical management of Gender Incongruence. In: *Indian Standards of Care for Persons with Gender Incongruence and People with*

- differences in Sexual Development/ Orientation version 1. Delhi: Wisdom Publishers; 2020:66–165
- 6 Gupta R, Gupta R, Mehta R, Aggarwal A, Mathur A. Gender dysphoria. In: Agrawal K, Mahajan RK, eds. Textbook of Plastic, Reconstructive and Aesthetic Surgery Volume IV. Noida, Uttar Pradesh: Thieme Publishers; 2019:259–293
  - 7 Selvaggi G, Bellringer J. Gender reassignment surgery: an overview. *Nat Rev Urol* 2011;8(05):274–282
  - 8 van der Sluis WB, Bouman MB, de Boer NK, et al. Long-term follow-up of transgender women after secondary intestinal vaginoplasty. *J Sex Med* 2016;13(04):702–710
  - 9 Davydov SN, Zhvitiashvili OD. Formation of vagina (colpopoiesis) from peritoneum of Douglas pouch. *Acta Chir Plast* 1974;16(01):35–41
  - 10 Georgas K, Belgrano V, Andreasson M, Elander A, Selvaggi G. Bowel vaginoplasty: a systematic review. *J Plast Surg Hand Surg* 2018;52(05):265–273
  - 11 Zhou JH, Sun J, Yang CB, Xie ZW, Shao WQ, Jin HM. Long-term outcomes of transvestibular vaginoplasty with pelvic peritoneum in 182 patients with Rokitansky's syndrome. *Fertil Steril* 2010;94(06):2281–2285
  - 12 Cao L, Wang Y, Li Y, Xu H. Prospective randomized comparison of laparoscopic peritoneal vaginoplasty with laparoscopic sigmoid vaginoplasty for treating congenital vaginal agenesis. *Int Urogynecol J Pelvic Floor Dysfunct* 2013;24(07):1173–1179
  - 13 Suwajo P, Ratanalert W, Sooksatian K, et al. Pedicled peritoneal flap vaginoplasty in male-to-female gender affirmation surgery: a case report. *Female Pelvic Med Reconstr Surg* 2020;26(08):e23–e26