Article published online: 2022-06-24

Atypical Posterior Reversible Encephalopathy Syndrome in Intraorbital Lymphoma after Tumor Biopsy: An Illustrative Case

Jirapong Vongsfak[1] Thunya Norasethada[1] Kittisak Unsrisong[2]

[1] Division of Neurosurgery, Department of Surgery, Faculty of Medicine, Chiang Mai University, Chiang Mai, Thailand
[2] Department of Radiology, Faculty of Medicine, Chiang Mai University, Chiang Mai, Thailand

Address for correspondence Jirapong Vongsfak, MD, Division of Neurosurgery, Department of Surgery, Faculty of Medicine, Chiang Mai University, 110 Intawarorot Road, Suthep district, Muang, Chiang Mai, Thailand, 50300 (e-mail: jvongsfak@gmail.com).

J Neurol Surg Rep 2022;83:e50–e53.

Abstract

Introduction A 63-year-old male presented with visual loss and left eye proptosis. Magnetic resonance imaging revealed a left orbital tumor, measuring 1.4 cm × 0.9 cm. The patient underwent left frontotemporal craniotomy to perform a biopsy of the tumor. During the postoperative period, the patient developed the first episode of a generalized tonic–clonic seizure.

Case Summary Computed tomography of the brain showed hypodensity of the bilateral basal ganglia and thalami with associated edematous white matter hypodensity of bilateral temporo-occipital lobes compatible with atypical posterior reversible encephalopathy syndrome (PRES). The patient received antiepileptic medication and was observed for clinical seizure. One week later, computed tomography of the brain showed the reversible process of PRES. The pathology report revealed diffuse large B cell lymphoma. Following pathological diagnosis, the patient received treatment with whole-brain radiotherapy.

Conclusion This is the first reported case of atypical PRES associated with orbital lymphoma following craniotomy for the purpose of tumor biopsy. Early detection as well as seizure and blood pressure control, is essential for the proper treatment of PRES.

Keywords
- atypical posterior reversible encephalopathy syndrome
- orbital lymphoma
- craniotomy
- tumor

Introduction

Posterior reversible encephalopathy syndrome (PRES) is a reversible neurological condition associated with vasogenic brain edema, particularly in the parieto-occipital area. It is associated with several conditions, such as hypertension, renal disease, and autoimmune disease. In this article, we report a case of orbital lymphoma in a male presenting with visual loss and proptosis of the left eye. The patient developed a seizure after undergoing a craniotomy for the purpose of tumor biopsy. Examination through computed tomography of the brain showed the characteristics of PRES in an atypical location. Herein, we discuss the first reported case of PRES that developed in an orbital lymphoma patient after craniotomy. In addition, we outline the findings of a literature review regarding PRES associated with a brain tumor.

received
May 26, 2021
accepted
March 30, 2022

DOI https://doi.org/10.1055/s-0042-1749403.
ISSN 2193-6358.

© 2022. The Author(s).
This is an open access article published by Thieme under the terms of the Creative Commons Attribution-NonDerivative-NonCommercial-License, permitting copying and reproduction so long as the original work is given appropriate credit. Contents may not be used for commercial purposes, or adapted, remixed, transformed or built upon. (https://creativecommons.org/licenses/by-nc-nd/4.0/)
Georg Thieme Verlag KG, Rüdigerstraße 14, 70469 Stuttgart, Germany

Case Presentation

A 63-year-old male visited an outpatient clinic on April 2, 2019. He presented with blurred vision in the left eye lasting 6 months. Two weeks prior to the examination, he experienced progressive visual loss, orbital pain, and left eye proptosis. His underlying conditions were diabetes mellitus, hypertension, and chronic kidney disease. He received medication, including insulin, hydralazine, nifedipine, furosemide, and simvastatin. A physical examination using Snellen's chart showed that visual acuity of the left and right eye was hand movement and 6/6, respectively. An extraocular movement examination revealed impaired movement in all directions for the left eye.

The patient underwent magnetic resonance imaging of the brain, including the orbital part. The analysis revealed a 1.4 cm × 0.9 cm enhancing lesion with a slightly iso-intensity to hypo-intensity signal on T2-weighted images at the lateral compartment of the intraconal part of the left orbit, causing compression over the left optic nerve medially (►**Fig. 1**).

In May 2019, the surgeon performed a left frontotemporal craniotomy for the purpose of a biopsy of the orbital tumor. The color of the tumor in the intraorbital part was gray. During the intraoperative period, the blood pressure of the patient remained within normal range with an approximate systolic blood pressure of 130 to 140 mm Hg, and a brief period of hypertension reaching 150 mm Hg after 10 minutes. The intraoperative blood loss was 100 mL. There was no occurrence of unexpected events during the operation. At 2 hours following the procedure, his Glasgow coma score was E2V2M4. Thirty minutes later, he developed generalized tonic–clonic seizure for 1 minute. The patient received benzodiazepine intravenously and valproic acid for seizure control. Postoperative computed tomography of the brain showed newly observed hypodensity of the bilateral basal ganglia and thalami with associated edematous white matter hypodensity of the bilateral temporo-occipital lobes. This finding was suggestive of atypical PRES (►**Fig. 2**). One

Fig. 2 Postoperative computed tomography of the brain showing hypodensity of the bilateral basal ganglia and thalami with associated edematous white matter hypodensity of bilateral temporo-occipital lobes compatible with atypical posterior reversible encephalopathy syndrome.

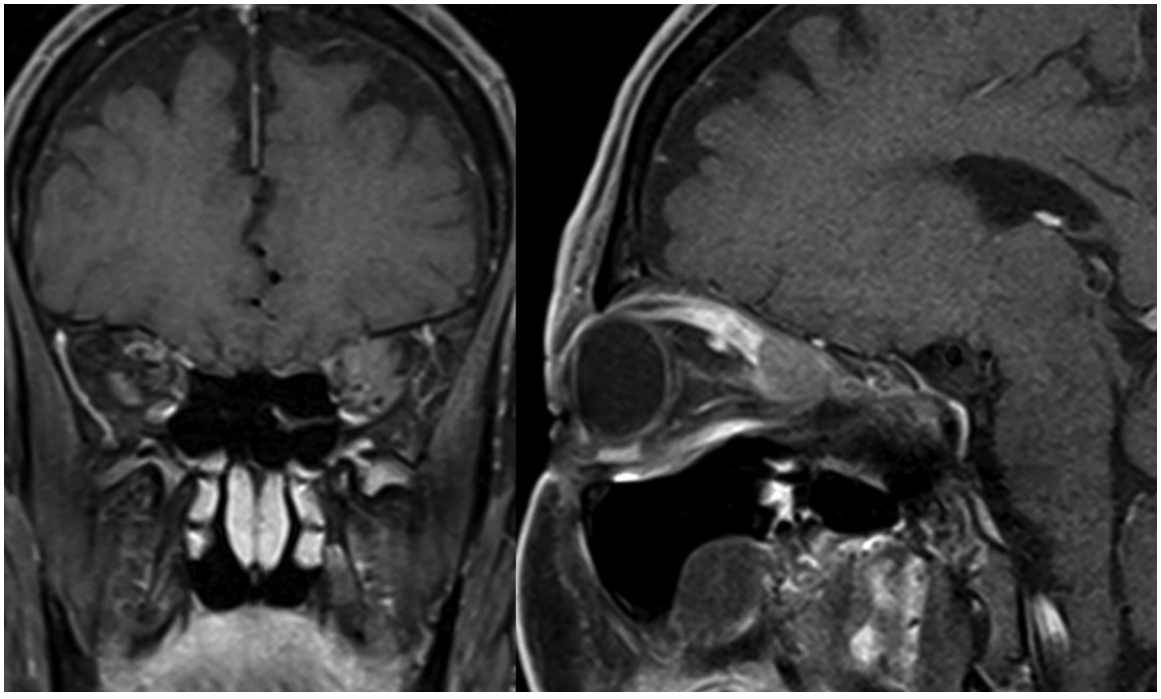

Fig. 1 T1-weighted magnetic resonance imaging of the brain with contrast coronal and sagittal views showing an enhancing lesion at the lateral compartment of the intraconal part of the left orbit.

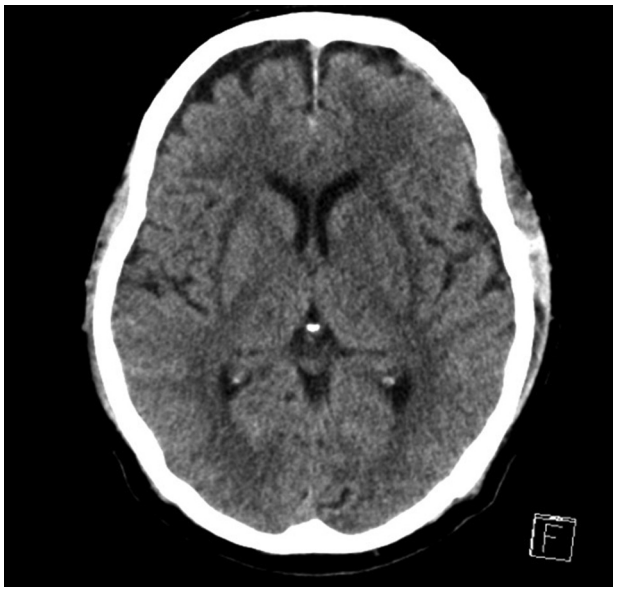

Fig. 3 Follow-up computed tomography of the brain 1 week after surgery showing the reversible process of posterior reversible encephalopathy syndrome.

week after the operation, the patient's condition returned to normal with good consciousness and absence of seizures. Follow-up computed tomography of the brain showed regression of multifocal hypodensity, which indicates the reversible process of PRES (►**Fig. 3**). The pathological examination reported diffuse large B cell lymphoma of the nongerminal center type (CD20: positive).

Following discharge from the hospital, we performed hematological examinations. Subsequently, the patient received whole-brain radiotherapy as treatment for intraorbital lymphoma. However, after whole-brain radiotherapy, the patient suffered from aspiration pneumonia and was bedridden. Therefore, he did not receive chemotherapy for curative treatment.

Discussion

PRES is a reversible neurological syndrome first described by Hinchey et al[1] in 1996. Its clinical presentation includes headache, alteration of consciousness, visual disturbance, and seizures.[2] A typical radiographic finding of PRES is vasogenic edema that affects the subcortical white matter tract of the parietal or occipital lobe. However, atypical PRES was defined as PRES that involves an atypical location of the brain (the brain stem, cerebellum, or basal ganglia) is characterized by a clinical persistence of seizures, residual neurological deficit, permanent visual impairment, and occasionally results in death.

Observations

Thus far, the pathophysiology of PRES remains unknown. Numerous studies suggested that it is caused by impaired autoregulation of blood vessels in the posterior circulation. When blood pressure increases beyond the upper limits for autoregulation, it causes a blood–brain barrier breakdown that leads to brain hyperperfusion and, eventually, vasogenic brain edema.[3] The posterior part of the cerebral cortex appears to be more vulnerable than the anterior cortex due to decreased capacity of vascular autoregulation. The second theory suggests that a hypertensive state causes vasospasm, leading to local brain ischemia.

The cause of PRES is usually associated with numerous medical conditions or medications, such as hypertensive crisis, preeclampsia/eclampsia, renal disease, autoimmune disease, or use of immunosuppressive drugs. According to the available literature, only eight patients with primary brain tumors had PRES that occurred in the ependymoma, glioma, or meningioma.[4] Most of these patients received chemotherapy (e.g., cisplatin, etoposide, and vincristine). Four patients (mainly pediatric cases) developed PRES during posterior fossa surgery. Several studies reported the development of PRES after triple-H therapy for vasospasm, placement of ventriculoperitoneal shunt, spinal operation, and lumbar puncture.[5–7] However, PRES also developed after the surgical clipping of an unruptured cerebral aneurysm. This was associated with the mechanism of vasogenic brain edema from increased cerebral perfusion pressure related to intracranial hypotension, such as the mechanism of PRES in cerebrospinal fluid shunting.[7]

The strategies for the management of PRES involve treatment of the associated condition and discontinuation of the causative drug. Seizures should be treated with antiepileptic medications and strict blood pressure control.[8]

According to the literature review, there are no reported cases of atypical PRES associated with orbital lymphoma or supratentorial craniotomy. This is the first report of an atypical presentation of PRES with orbital lymphoma after supratentorial craniotomy for the purpose of tumor biopsy. The etiology of PRES in the present case is probably vasogenic brain edema caused by intracranial hypotension after opening the dura mater that caused an excessive increase of cerebral perfusion pressure; the short and slight intraoperative hypertension period also contributed to the development of PRES.

Lessons

The present report illustrates a case of atypical PRES that occurred after craniotomy and biopsy of intraorbital lymphoma. Early detection, as well as seizure and blood pressure control, is essential for the proper treatment of PRES.

Funding

The article processing fee for Open Access Publishing was provided by the Research Unit, Department of Surgery, Faculty of Medicine, Chiang Mai University.

Conflict of Interest

The authors declare that the content of the article was composed in the absence of any commercial or financial relationships that could be construed as a potential conflict of interest.

Acknowledgments
The authors give Enago experts the right to proceed ahead with completion of the manuscript submission process to the journal on their behalf. This is to comply with the Good Publication Practice 3 guidelines and the International Committee of Medical Journal Editors criteria for ethical publication protocol.

References

1 Hinchey J, Chaves C, Appignani B, et al. A reversible posterior leukoencephalopathy syndrome. N Engl J Med 1996;334(08): 494–500
2 Stevens CJ, Heran MK. The many faces of posterior reversible encephalopathy syndrome. Br J Radiol 2012;85(1020):1566–1575
3 Aracki-Trenkić A, Stojanov D, Trenkić M, et al. Atypical presentation of posterior reversible encephalopathy syndrome: clinical and radiological characteristics in eclamptic patients. Bosn J Basic Med Sci 2016;16(03):180–186
4 Kamiya-Matsuoka C, Cachia D, Olar A, Armstrong TS, Gilbert MR. Primary brain tumors and posterior reversible encephalopathy syndrome. Neurooncol Pract 2014;1(04):184–190
5 Amin-Hanjani S, Schwartz RB, Sathi S, Stieg PE. Hypertensive encephalopathy as a complication of hyperdynamic therapy for vasospasm: report of two cases. Neurosurgery 1999;44(05):1113–1116
6 Hammad T, DeDent A, Algahtani R, et al. Posterior reversible encephalopathy syndrome secondary to CSF leak and intracranial hypotension: a case report and literature review. Case Rep Neurol Med 2015;2015:538523
7 Niwa R, Oya S, Nakamura T, Hana T, Matsui T. Rapid intracranial pressure drop as a cause for posterior reversible encephalopathy syndrome: two case reports. Surg Neurol Int 2017;8:103
8 Hobson EV, Craven I, Blank SC. Posterior reversible encephalopathy syndrome: a truly treatable neurologic illness. Perit Dial Int 2012;32(06):590–594