



# De Novo Glioblastoma Masqueraded within a Hemispheric Dural Meningiomatosis: Rare Imaging Findings and Rationale for Two-Stage Resection

Nicholas Zacharewski<sup>1,2</sup> Misha Movahed-Ezazi<sup>3</sup> Xianyuan Song<sup>3</sup> Tapan Mehta<sup>4</sup> Sunil Manjila<sup>1</sup>

<sup>1</sup>Department of Neurosurgery, Hartford Hospital, Hartford, Connecticut, United States

<sup>2</sup>Department of Trinity College, Hartford, Connecticut, United States

<sup>3</sup>Department of Pathology and Laboratory Medicine, Hartford Hospital, Hartford, Connecticut, United States

<sup>4</sup>Division of Neuro Intervention, Hartford Hospital, Hartford, Connecticut, United States

Address for correspondence Sunil Manjila, MD, Department of Neurosurgery, Hartford Hospital, 80 Seymour Street, Hartford, Connecticut 06102, United States (e-mail: sunil.manjila@gmail.com).

J Neurol Surg Rep 2022;83:e44–e49.

## Abstract

### Keywords

- ▶ case report
- ▶ collision tumors
- ▶ glioma
- ▶ glioblastoma
- ▶ meningioma
- ▶ meningiomatosis
- ▶ supplementary motor area syndrome

**Introduction** Collision tumors present as histologically different juxtaposed neoplasms within the same anatomical region, independent of the adjacent cell population. De novo intracranial collision tumors involving metachronous primary brain neoplasms alongside dural meningiomatosis are not well documented in the literature.

**Clinical Presentation** We present staged surgical management of a 72-year-old female with known left hemispheric stable dural-based convexity mass lesions over 10 years and new-onset expressive aphasia and headaches. MRI had revealed left supratentorial dural-based enhanced masses consistent with en plaque meningiomatosis. Embolization angiography showed an unusual tumor blush from an aberrant branch of anterior cerebral artery suggesting a deeper focal intra-axial nature; a stage 1 craniotomy for dural-based tumor resection was completed with diagnosis of a meningioma (WHO grade 1). Intraoperatively, a distinct intra-axial deep discrete lesion was verified stereotactically, concordant with the location of tumor blush. The patient made a complete neurological recovery from a transient postoperative supplemental motor area syndrome in a week. Subsequent postoperative follow-up showed worsening of right hemiparesis and MRI showed an increase in residual lesion size and perilesional edema, which prompted a stage 2 radical resection of a glioblastoma, WHO grade 4. She improved neurologically after surgery with steroids and physical

Poster/Abstract presentation at the American Association of Neuropathologist (AANP) meeting in St. Louis, Missouri/Virtual on June 10 to 13, 2021 with publication of abstract in the *Journal of Neuropathology & Experimental Neurology (JNEN)*.

received  
August 12, 2021  
accepted  
March 30, 2022

DOI <https://doi.org/10.1055/s-0042-1749215>.  
ISSN 2193-6358.

© 2022. The Author(s).

This is an open access article published by Thieme under the terms of the Creative Commons Attribution-NonDerivative-NonCommercial-License, permitting copying and reproduction so long as the original work is given appropriate credit. Contents may not be used for commercial purposes, or adapted, remixed, transformed or built upon. (<https://creativecommons.org/licenses/by-nc-nd/4.0/>)

Georg Thieme Verlag KG, Rüdigerstraße 14, 70469 Stuttgart, Germany

therapy. At 15 months following adjuvant therapy, she remains neurologically intact throughout the postoperative course, with no recurrent tumor on MRI.

**Conclusion** A de novo glioblastoma presented as a masquerading lesion within hemispheric convexity meningiomatosis in an elderly patient with no prior radiation/phakomatosis, inciting a non-causal juxtapositional coexistence. The authors highlight rare pathognomonic angiographic findings and the rationale for two-staged resections of these collision lesions that led to excellent clinicoradiological outcome.

## Background and Importance

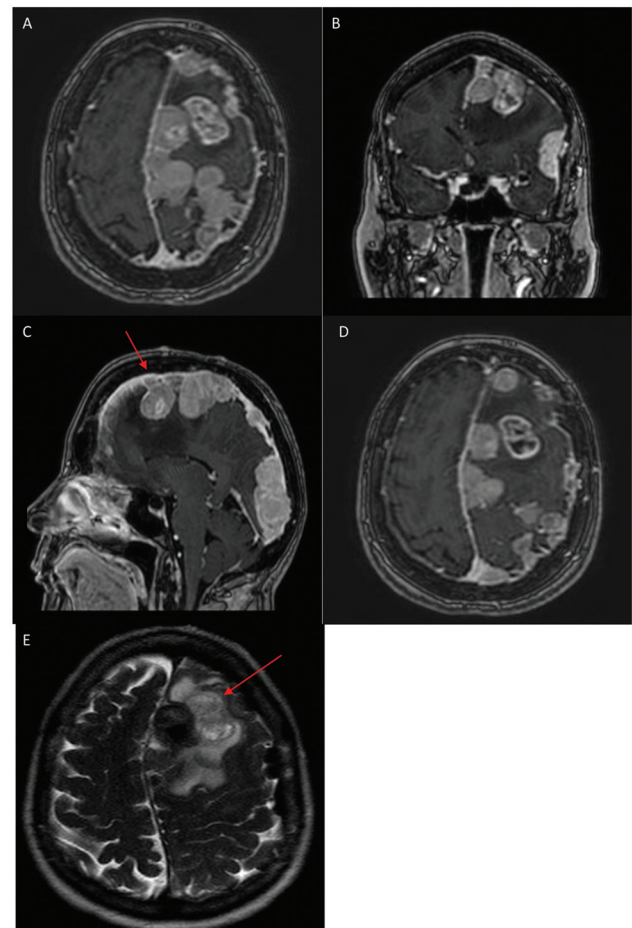
Meningioma and glioma are the two most common primary intracranial tumors which can present as collision tumors, typically associated with trauma, radiotherapy, or phakomatosis.<sup>1,2</sup> Collision tumors are histologically different neoplasms within the same anatomical region, independent of the adjacent cell population. Albeit the first collision tumor with no prior treatment history was reported in 1976, they continue to be a rare occurrence.<sup>3–8</sup> Intratumoral metastases and tumor “invasion” or “coalescent lesions” are observed in collision tumors; however, their “dynamic or metachronous” presentations and “unpredictable local invasiveness” give them an exceedingly rare histological property.<sup>9–13</sup> Intracranial collision or juxtaposed tumors involving metachronous primary brain tumors alongside a hemispheric dural meningiomatosis are not documented in literature.

## Clinical Presentation

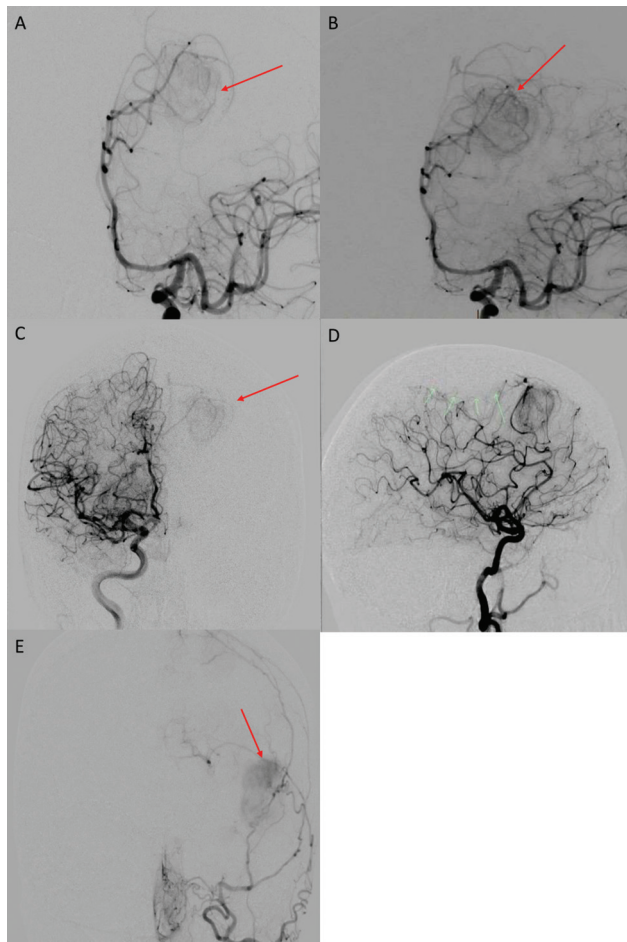
A 72-year-old female with documented left hemispheric dural-based meningiomas (with stable surveillance MR scans for 10 years), had presented with new onset expressive aphasia and worsening headaches. Previous MRIs showed stable dural-based, enhancing coalescent extra-axial masses predominantly in the left parasagittal region, posterior frontoparietal and occipital areas, with a separate anterior temporal, dural-based tumor (► Fig. 1A–F). Current MRI showed the largest coalescent lesion in the left parafalcine posterior frontal region measuring 4.6 × 3.0 cm, with “de novo” vasogenic edema and mass effect with displacement of the falx, highly suspicious of an atypical meningioma.

Despite intravenous steroids, her aphasia and perilesional edema on imaging both improved only minimally, prompting urgent surgical intervention. Considering symptomatic white matter edema of the left frontoparietal brain, a preoperative embolization of the left middle meningeal artery was performed with PVA particle and Onyx liquid embolic agent. During embolization, an aberrant “blush” was seen from a left A3 branch supplying the deep posterior frontal lesion suspicious for intra-axial pathology separate from the relatively avascular meningiomatosis. An occlusion of the middle third of the superior sagittal sinus was noted with displacement of engorged venous tributaries (► Fig. 2A–E). A stage 1 frontotemporal

oparietal craniotomy for resection of the extensive en plaque convexity meningiomatosis was performed with motor mapping. Intraoperative findings revealed a lobulated, firm, moderately vascular, dural-based lesion with poor brain interphase in its deeper parts. A discrete deeper solid tumor was then noted subcortically, verified under stereotactic navigation, however, not contiguous with the



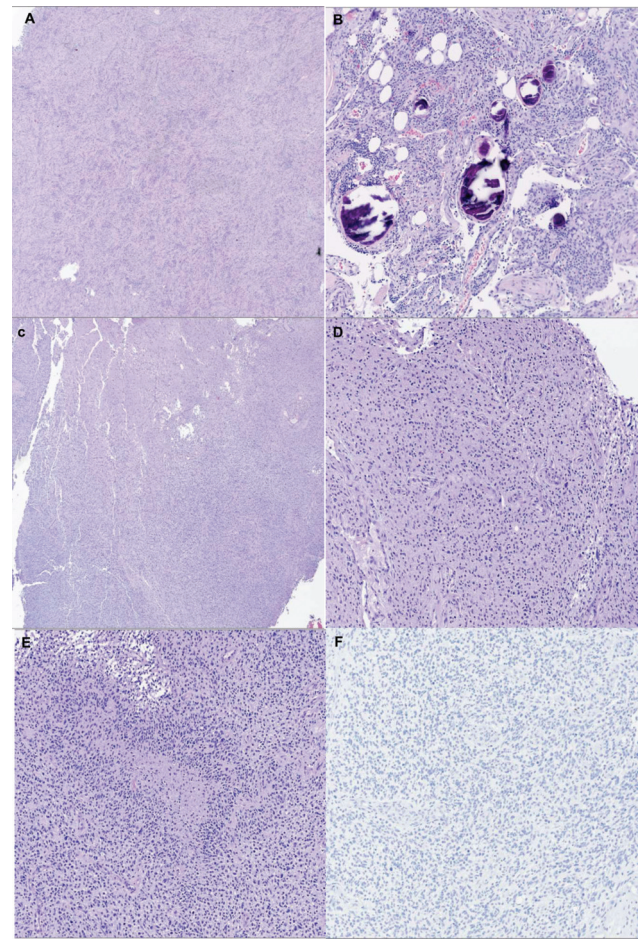
**Fig. 1** (A) Axial section MRI brain with contrast depicting enhanced left-sided hemispheric dural meningiomatosis. (B) Coronal section showing a heterogeneous component of the “collision” tumor in deep left frontoparietal brain with perilesional edema and an extra-axial separate lesion in the Broca’s area based on convexity dura mater. (C) Sagittal view showing a deep heterogeneous lesion with edema (red arrow), juxtaposed to dural meningiomatosis. (D) Better delineation of the heterogeneous component (glial) which was suspicious of glial origin, showing a discrete T2 FLAIR appearance compared with juxtaposed meningioma (red arrow) (E).



**Fig. 2** (A) Left internal carotid artery injection showing early A3 branch supplying the superior pole of the likely intra-axial mass (red arrow). (B) Late arterial phase of the same (red arrow). (C) Contralateral injection from right internal carotid artery showing the relatively avascular parasagittal lesion and independent supply of the left-sided deep lesion (red arrow). (D) Lateral view showing relatively avascular parasagittal meningiomatosis (see green arrows) and left external carotid arteriogram showing a tumor blush at the frontotemporal extra-axial mass based off the dura mater (red arrow) (E).

superficial en-plaque meningiomatosis. Histopathology of the superficial large lesion was confirmed as meningioma (WHO Grade I) with moderate cellularity and a whorling, syncytial growth pattern (► Fig. 3A), monotonous nuclei, pseudonuclear inclusions, and psammomatous calcifications (► Fig. 3B). MIB-1 labeling was averaging 1 to 2% and focally up to 4%.

Postoperatively, the patient had transient worsening of aphasia and right hemiparesis, consistent with supplementary motor area syndrome which recovered fully within a week. MRI confirmed focal resection of left dural meningiomatosis and Simpson grade 1 resection of the dural based temporal lesion; however, a discrete enhancing residual intra-axial lesion, likely a high-grade glial neoplasm was noted (► Fig. 4A–E). Follow-up clinic visit demonstrated a new progressive right hemiparesis (grade 3), and MRI showed an increase in residual lesion size and persistent edema around this residual mass. Hence a stage 2 limited frontoparietal re-craniotomy for microsurgical radical resec-

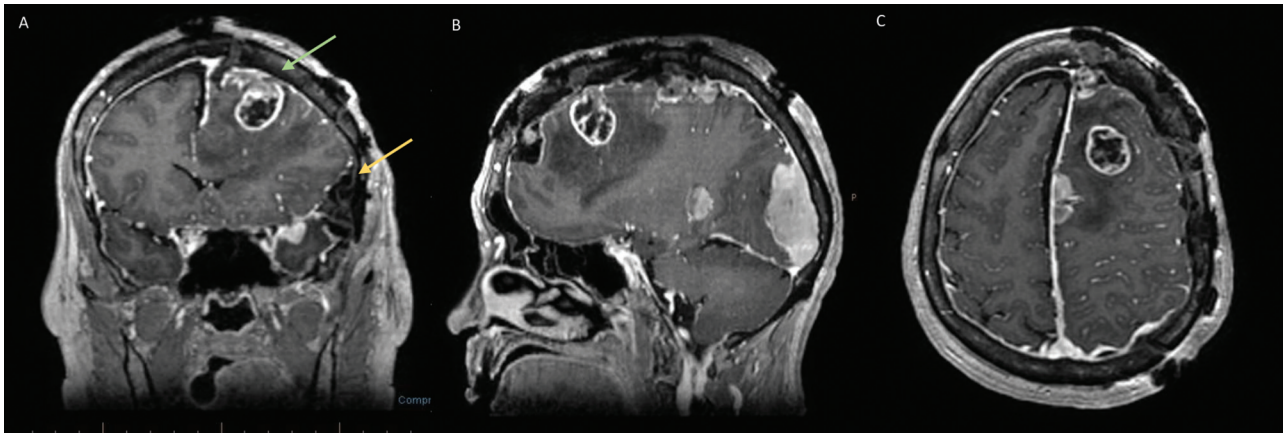


**Fig. 3** (A) Microscopic sections show a moderately cellular lesion with a whorling and syncytial growth pattern. (B) The tumor cells show round, uniform nuclei and eosinophilic cytoplasm. Abundant psammomatous calcifications are present. (C) Biopsy of the deeper suspicious focus identified on angiography shows an infiltrating glioma with high cellularity. (D, E) Higher power images display pleomorphic nuclei, brisk mitotic figures, prominent microvascular proliferation and pseudopalisading necrosis, characteristic of glioblastoma (WHO grade 4). (F) IDH-1 was negative on immunohistochemical analysis, showing a wild-type profile.

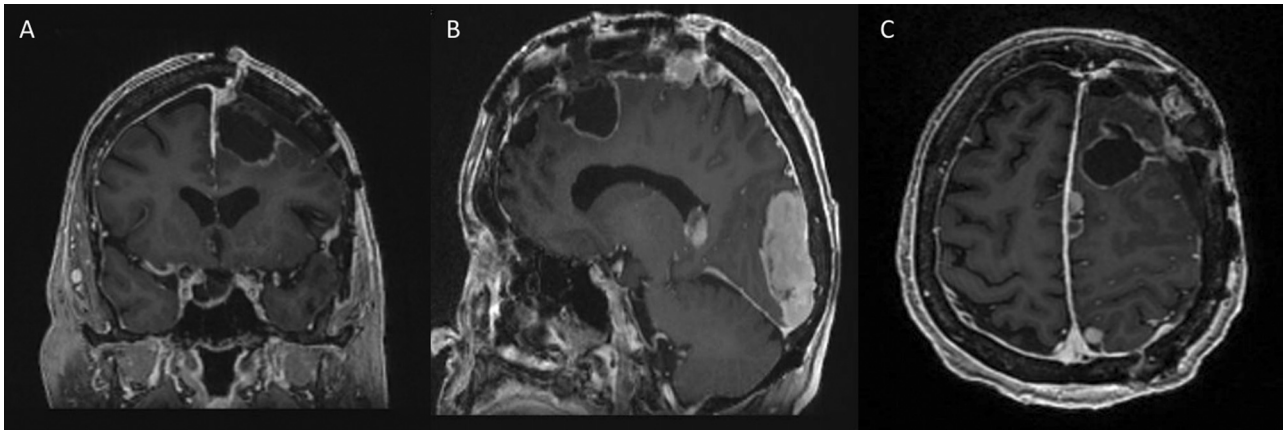
tion was performed with stealth-guidance and motor mapping. Surgical findings revealed an intra-axial cyst anterior to the central sulcus while the solid component was moderately vascularized with ill-defined boundaries adjacent to white matter.

Biopsy report confirmed an infiltrating glioma with high cellularity, pleomorphic nuclei (► Fig. 3C), microvascular proliferation, brisk mitosis and pseudopalisading/geographic necrosis, characteristic of GBM (► Fig. 3D, E) with MIB1 labeling up to 20 to 30%. Tumor cells were diffusely positive for GFAP and had intact nuclear expression on ATRX. p53 labeled 10% of the tumor cells (non-mutational pattern). IDH-1 mutant protein was negative on IHC (► Fig. 3F). Molecular studies showed MGMT promoter methylation, EGFR gene amplification, and CDKN2A gene deletion (on NGS).

Postoperative MRI showed no residual tumor or hemorrhage in the resection bed. Her hemiparesis gradually improved to normal over 2 weeks with steroids and physical therapy. At 6 months post-adjvant therapy, she was neurologically intact



**Fig. 4** (A) Coronal cranial MRI with contrast showing a heterogeneous enhancing frontoparietal intra-axial tumor (*green arrow*) likely of glial origin with perilesional white matter edema and postoperative changes of focal meningiomatosis resection and Simpson grade 1 resection of lesion near the Broca's area (*yellow arrow*). (B) Post stage 1 craniotomy, sagittal contrast MRI brain showing the heterogeneous enhanced frontoparietal intra-axial tumor, which was masqueraded by juxtaposed meningiomas. (C) Axial cranial MRI view with contrast showing the frontoparietal intra-axial tumor with remarkable perilesional white matter edema and postoperative changes of focal meningiomatosis resection.



**Fig. 5** (A, B, C) Early postoperative contrast MRI after stage 2 focal re-craniotomy for microsurgical radical resection of the intra-axial mass showing radical resection of the lesion. (A) coronal, (B) sagittal, and (C) axial sections

with no recurrent tumor on MR imaging (► **Figs. 5** and **6**) which remained status quo at 15 months after second surgery, consistent with a radical resection of GBM.

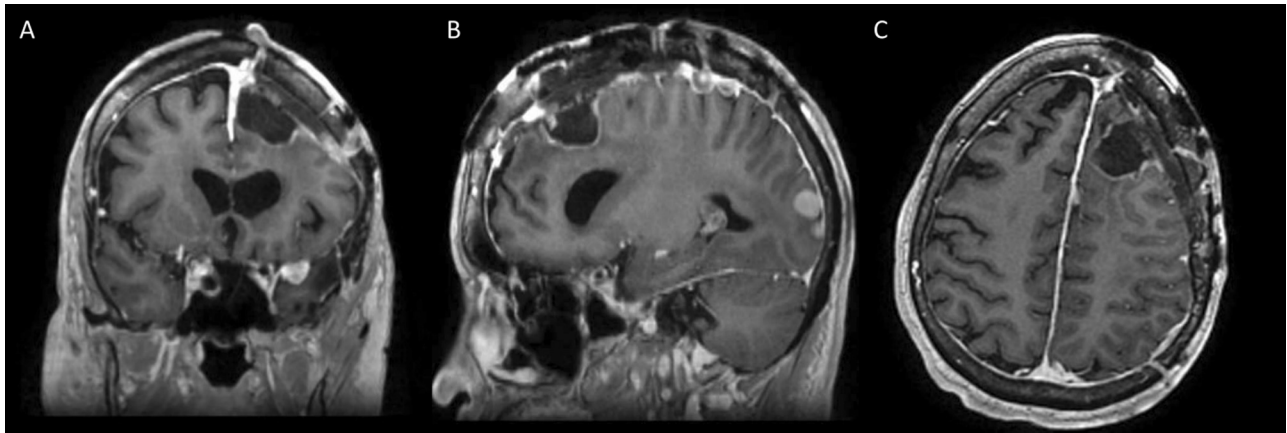
## Discussion

Collision tumors represent two coexisting lesions with distinct morphologies occurring in the same anatomical region, with or without pathologic invasion. Truong et al discussed a literature review of 67 cases of meningioma and glioma collision tumors with the first being reported in 1938 and the most recent in 2019.<sup>14</sup> Collision tumors can be benign–benign, benign–malignant, or malignant–malignant combination lesions.<sup>15–18</sup> Dural meningiomatosis represents approximately 1 to 10% of meningioma lesions, with 2% resulting in malignancy.<sup>19–22</sup> De novo GBMs appear to develop independent of histological evidence toward a precursor lesion of a lower malignancy.<sup>23–26</sup> Collision gliomas tend to occur peripheral of the meningiomas in a majority of cases.<sup>27</sup> In our case, arteriography played a

pivotal role in the characterization of the de novo lesion. An aberrant branch of the left ACA feeding an intra-axial mass raised suspicion for a parenchymal brain metastasis versus high-grade glioma.<sup>28,29</sup> Typically primary brain tumors in collision tumors are GBMs, anaplastic astrocytomas, or oligodendrogliomas.<sup>30</sup>

Environmental carcinogenic factors such as trauma or ionizing radiation are thought to stimulate formation of a concurrent secondary tumor.<sup>23</sup> Matyja et al postulated that collision tumors arise from one lesion stimulating growth of the other.<sup>31</sup> There is also not necessarily any pathologic invasion involving the secondary tumors, such as seen in our case and reported by Prayson et al.<sup>32</sup> Molecular studies have shown some genetic mutations found in these tumors including VEGF, EGFR, EDGFR, and NDRG2 according to Zhang et al.<sup>33</sup>

The decision to stage the resection was taken primarily based on heterogeneity of the lesion with an aberrant ACA blood supply on angiography. Two stage surgery was planned due to (1) the large flap craniotomy required for



**Fig. 6** (A, B, C) Six months follow-up of postoperative contrast MRI after stage 2 focal re-craniotomy for microsurgical radical resection of the intra-axial mass shows radical resection. (A) coronal, (B) sagittal, and (C) axial sections

meningiomas resection with resultant CSF leak and brain sag causing inaccurate stereotaxy, and (2) the morbidity of removing parasagittal meningiomas with engorged venous tributaries as shown on the angiography. The parasagittal draining veins draping and/or encased by the tumor could be thrombosed, arterialized as well as showing either an antegrade or retrograde flow. The adjacent cortical veins could impede tumor resection, cause venous ischemic or hemorrhagic strokes in eloquent brain (especially at middle one-third sagittal sinus) and also cause seizures from venous congestion, as well as impede or alter the collateral venous flow of the hemisphere. It was hence decided to let patient recover from these possible major vascular morbidities of first craniotomy, and then perform a stage 2 resection of the GBM using a smaller craniotomy allowing for lesser brain shift/retraction, reduced venous disruption, and better stereotactic guidance for focal tumor exposure and gross total or radical resection.

Treatment options for heterogenous group of collision tumors are still debated, with higher recurrence rates noted based on proliferation status.<sup>34–37</sup> Our patient was followed with temozolomide and NOVO-TTF treatment, with no residual tumor on cranial MRI at 15 months and no lateralizing neurological deficits on clinical examination.

## Conclusion

We present a rare case of a de novo GBM in a patient with juxtaposed intracranial meningiomatosis suspected from an abnormal branch of the left ACA and heterogenous enhancement of the deeper part of the lesion with disproportionate edema. Most significantly, a two-staged resection achieved a radical removal of the mass, followed by chemo-radiation therapy resulting in no significant residual or recurrent GBM at 15 months follow-up.

### NOTE

Patient consent was not required for this case report as it refers to only one patient and no patient identifiers are included in the manuscript or figures.

### Abbreviations

MRI, magnetic resonance imaging; WHO, world health organization; GBM, glioblastoma CSF, Cerebrospinal fluid; SMA, supplementary motor area; PVA, polyvinyl alcohol; MIB-1, Mindbomb E3 ubiquitin protein ligase; GFAP, glial fibrillary acidic protein; ATRX,  $\alpha$ -thalassemia/mental retardation, X linked; MGMT, O[6]-methylguanine-DNA methyltransferase; EGFR, epidermal growth factor receptor; IDH-1, isocitrate dehydrogenase 1; CDKN2A, cyclin dependent kinase inhibitor 2A; CT, computed tomography; ACA, anterior cerebral artery; NOVO-TTF, Novocure Inc.; IHC, immunohistochemistry; NGS, next generation sequencing

### Funding

None.

### Conflict of Interest

None declared.

### Acknowledgments

None

## References

- 1 Zhao Y, Zhang H, Lian W, et al. Collision tumors composed of meningioma and growth hormone-secreting pituitary adenoma in the sellar region: case reports and a literature review. *Medicine (Baltimore)* 2017;96(50):e9139
- 2 Thon N, Kreth S, Kreth F-W. Personalized treatment strategies in glioblastoma: MGMT promoter methylation status. *Oncotargets Ther* 2013;6:1363–1372
- 3 Sung CT, Shetty A, Menias CO, et al. Collision and composite tumors; radiologic and pathologic correlation. *Abdom Radiol (NY)* 2017;42(12):2909–2926
- 4 Ohgaki H, Kleihues P. Genetic pathways to primary and secondary glioblastoma. *Am J Pathol* 2007;170(05):1445–1453
- 5 Lee HS, Kim JH, Lee J-I. Glioblastoma following radiosurgery for meningioma. *J Korean Neurosurg Soc* 2012;51(02):98–101
- 6 Strong AJ, Symon L, MacGregor BJL, O'Neill BP. Coincidental meningioma and glioma. Report of two cases. *J Neurosurg* 1976;45(04):455–458
- 7 Bulte CA, Hoegler KM, Khachemoune A. Collision tumors: a review of their types, pathogenesis, and diagnostic challenges. *Dermatol Ther (Heidelb)* 2020;33(06):e14236

- 8 Mir SA, Farooqi KJ, Bhat MA, Koutwal S, Masoodi SR. Coexistence of growth hormone-secreting pituitary adenoma and intracranial meningioma. *JMS SKIMS* 2011;14(02):75
- 9 Tunthanathip T, Kanjanapradit K, Ratanalert S, Phuenpathom N, Oearsakul T, Kaewborisutsakul A. Multiple, primary brain tumors with diverse origins and different localizations: case series and review of the literature. *J Neurosci Rural Pract* 2018;9(04):593–607
- 10 Lyndon D, Lansley JA, Evanson J, Krishnan AS. Dural masses: meningiomas and their mimics. *Insights Imaging* 2019;10(01):11
- 11 Amirjamshidi A, Mehrazin M, Abbassioun K. Meningiomas of the central nervous system occurring below the age of 17: report of 24 cases not associated with neurofibromatosis and review of literature. *Childs Nerv Syst* 2000;16(07):406–416
- 12 Enam SA, Abdulrauf S, Mehta B, Malik GM, Mahmood A. Metastasis in meningioma. *Acta Neurochir (Wien)* 1996;138(10):1172–1177, discussion 1177–1178
- 13 Bender L, Lhermitte B, Carinato H, et al. Grade III meningioma with gastro-intestinal tract and brain metastases: case report and review of the literature. *World J Surg Oncol* 2019;17(01):70
- 14 Truong VT, Tran DDT, Dang CT. Collision occurrence of meningioma and astrocytoma: a case report and literature review. *Asian J Neurosurg* 2019;14(03):938–942
- 15 Tognetti L, Cinotti E, Perrot JL, Campoli M, Fimiani M, Rubegni P. Benign and malignant collision tumors of melanocytic skin lesions with hemangioma: dermoscopic and reflectance confocal microscopy features. *Skin Res Technol* 2018;24(02):313–317
- 16 Merrill SA, Sharma A, Carlin RE, et al. A rare intracranial collision tumor of meningioma and metastatic uterine adenocarcinoma: case report and literature review. *World Neurosurg* 2021;145:340–347
- 17 Bhavsar T, Liu J, Huang Y. Collision metastasis of urothelial and prostate carcinomas to the same lymph node: a case report and review of the literature. *J Med Case Reports* 2012;6(01):124
- 18 Mahmud W, Rohra P, Bitterman P, Reddy V, Gattuso P. 281 metastatic collision tumors: a clinicopathologic review. *Am J Clin Pathol* 2018;149(Suppl 1):S119–S119
- 19 Weigel J, Neher M, Schrey M, Wünsch PH, Steiner H-H. Collision tumor composed of meningioma and cavernoma. *J Korean Neurosurg Soc* 2017;60(01):102–107
- 20 Moreau JT, Hankinson TC, Baillet S, Dudley RWR. Individual-patient prediction of meningioma malignancy and survival using the surveillance, epidemiology, and end results database. *NPJ Digit Med* 2020;3(01):12
- 21 Perry A, Scheithauer BW, Stafford SL, Lohse CM, Wollan PC. “Malignancy” in meningiomas: a clinicopathologic study of 116 patients, with grading implications. *Cancer* 1999;85(09):2046–2056
- 22 Morgenstern PF, Shah K, Dunkel IJ, et al. Meningioma after radiotherapy for malignancy. *J Clin Neurosci* 2016;30:93–97
- 23 He H, Shao X, Li Y, et al. Targeting signaling pathway networks in several malignant tumors: progresses and challenges. *Front Pharmacol* 2021;12:675675
- 24 Jin L, Zhou Y. Crucial role of the pentose phosphate pathway in malignant tumors. (Review) *Oncol Lett* 2019;17(05):4213–4221
- 25 Egorov IK. Mouse models of efficient and inefficient anti-tumor immunity, with emphasis on minimal residual disease and tumor escape. *Cancer Immunol Immunother* 2006;55(01):1–22
- 26 Saez E, No D, West A, Evans RM. Inducible gene expression in mammalian cells and transgenic mice. *Curr Opin Biotechnol* 1997;8(05):608–616
- 27 Sanchez EQ, Marubashi S, Jung G, et al. De novo tumors after liver transplantation: a single-institution experience. *Liver Transpl* 2002;8(03):285–291
- 28 Kessler RA, Garzon-Muvdi T, Yang W, et al. Metastatic atypical and anaplastic meningioma: a case series and review of the literature. *World Neurosurg* 2017;101:47–56
- 29 Gu D-N, Huang Q, Tian L. The molecular mechanisms and therapeutic potential of microRNA-7 in cancer. *Expert Opin Ther Targets* 2015;19(03):415–426
- 30 Adib SD, Tatagiba M. Surgical management of collision-tumors between vestibular schwannoma and meningioma in the cerebellopontine angle in patients with neurofibromatosis type 2. *Acta Neurochir (Wien)* 2019;161(06):1157–1163
- 31 Matyja E, Kuchna I, Kroh H, Mazurowski W, Zabek M. Meningiomas and gliomas in juxtaposition: casual or causal coexistence? Report of two cases. *Am J Surg Pathol* 1995;19(01):37–41
- 32 Prayson RA, Chowdhary S, Woodhouse S, Hanson M, Nair S. Collision of a syncytial meningioma and malignant astrocytoma. *Ann Diagn Pathol* 2002;6(01):44–48
- 33 Zhang D, Yu J, Guo Y, Zhao S, Shao G, Huang H. An intraventricular meningioma and recurrent astrocytoma collision tumor: a case report and literature review. *World J Surg Oncol* 2015;13:37
- 34 Schizas D, Michalinos A, Alexandrou P, et al. A unique tripartite collision tumor of the esophagus: a case report. *Medicine (Baltimore)* 2017;96(49):e8784
- 35 Weiss NS, Koepsell TD. Cancer causes & control. *Cancer Causes Control* 2011;22(08):1215–1215
- 36 Shu P, Li R, Xie D, He Y, Wang X, Li Q. Clinical profile and treatment outcome of collision carcinoma in cervix. *Medicine (Baltimore)* 2020;99(11):e19131
- 37 Nestler U, Schmidinger A, Schulz C, et al. Glioblastoma simultaneously present with meningioma—report of three cases. *Zentralbl Neurochir* 2007;68(03):145–150