



Gender Affirming Body Contouring and Physical Transformation in Transgender Individuals

Arjun Asokan¹ Madhu K. Sudheendran¹

¹ Department of Plastic Surgery, Renai Medicity, Cochin, Kerala, India

Indian J Plast Surg 2022;55:179–187.

Address for correspondence Arjun Asokan, MS, MCh, DNB, MRCS, Department of Plastic Surgery, Renai Medicity, Cochin 682025, Kerala, India (e-mail: arjunashokan@gmail.com).

Abstract

There is a subset of transgender individuals, who after having undergone gender affirming surgeries want body contouring so that the overall body shape is congruent to the body image. Hormonal therapy can bring about a considerable change in the physical transformation. However, there is an increase in requests for specific body contouring procedures because of increased awareness in the society.

Keywords

- ▶ body contouring
- ▶ transgender
- ▶ shoulder feminization

There are significant differences between the skeletal as well as soft tissue characteristics of male and female body. Body contouring in transgender individuals can be achieved by altering the skeletal structure or the overlying soft tissues or combining both. In this article, we discuss body contouring as an adjunct to gender affirming surgeries, in both male to female and female to male transgender individuals.

Introduction

Recently, there has been an increased awareness as well as better acceptance of gender incongruent individuals in the society.¹ Accordingly, gender affirming surgeries have grown in volume and finesse in the recent past as a result of better awareness in addition to the efforts of various organizations. There is an increase in gender incongruent individuals seeking gender affirming surgeries, requesting more specific surgeries at a younger age.² Studies have shown that gender reaffirming surgery has a positive effect on life satisfaction and quality of life,³ reducing insecurity and improving self-perception of attractiveness and self-confidence.⁴

The various gender affirming surgeries sought after by transwomen are orchiectomy, vaginoplasty, breast augmentation, facial feminization, and reduction thyroid chondroplasty with or without voice change.⁵ The usual sought-after masculinization surgeries are chest masculinization surgery (top surgery), metoidioplasty, phalloplasty, and hysterectomy. There is still a subset of individuals who after having

undergone gender affirming surgeries still want improvement of the body contour so that the overall body shape is congruent to the body image.

In this article, we discuss body contouring as an adjunct to these surgeries in both male to female and female to male transgender individuals.

The Difference in the Male and Female Body Habitus

There are significant differences between the skeletal and soft tissue characteristics of males and females (→ **Figs. 1, 2**). Body contouring in transgender individuals can be achieved by altering the skeletal structure or the overlying soft tissues or combining both.

Surgical alteration of the skeletal framework, especially the pelvis, carries higher risks and morbidity; thus, soft tissue contouring is preferred. In the thorax and shoulder; however, there is less scope for soft tissue contouring due to the lesser proportion of body fat than the pelvic and gluteal regions.

published online
August 22, 2022

Issue Theme Gender
Incongruence

DOI <https://doi.org/10.1055/s-0042-1749099>.
ISSN 0970-0358.

© 2022. Association of Plastic Surgeons of India. All rights reserved. This is an open access article published by Thieme under the terms of the Creative Commons Attribution-NonDerivative-NonCommercial-License, permitting copying and reproduction so long as the original work is given appropriate credit. Contents may not be used for commercial purposes, or adapted, remixed, transformed or built upon. (<https://creativecommons.org/licenses/by-nc-nd/4.0/>)
Thieme Medical and Scientific Publishers Pvt. Ltd., A-12, 2nd Floor, Sector 2, Noida-201301 UP, India

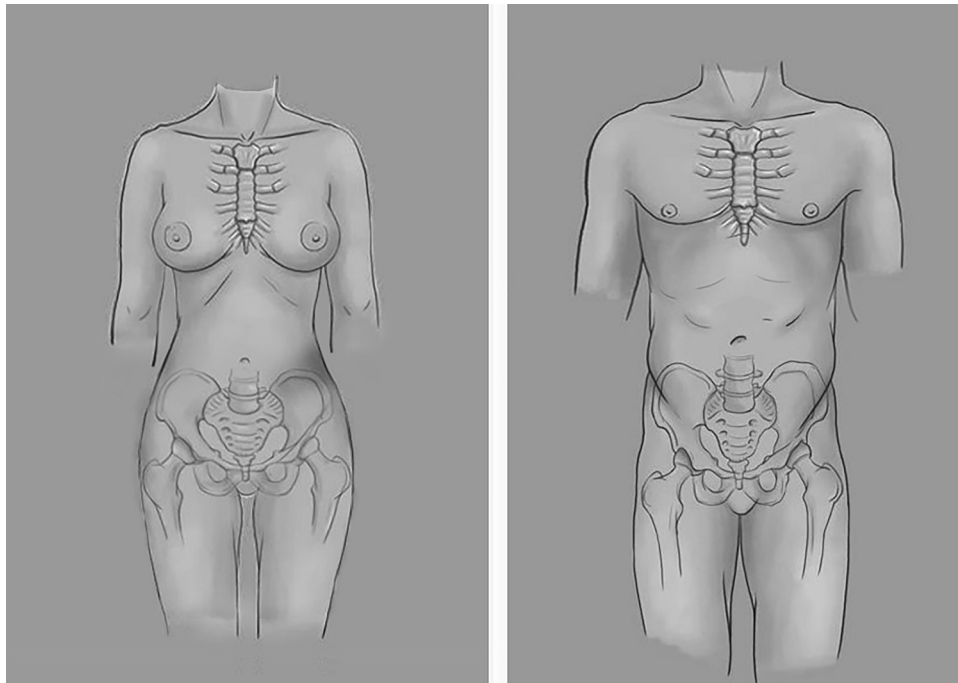


Fig. 1 Difference in skeletal framework in females and males.

Skeletal Framework of Thorax and Shoulder

The biacromial diameter is the measurement of shoulder width and averages 15.6 (14.3–17.0) inches in males. The female biacromial diameter is lesser, with an average value of 13.9 (12.8–15.2) inches.⁶ The male rib cage is also larger

compared with the female counterparts, with average lateral rib cage diameter of 14.16 cm/m (measurements normalized to standing height in meters) compared with 13.68cms/m⁷ The torso of females is more hourglass shaped as compared with a much straighter waistline in males.⁸

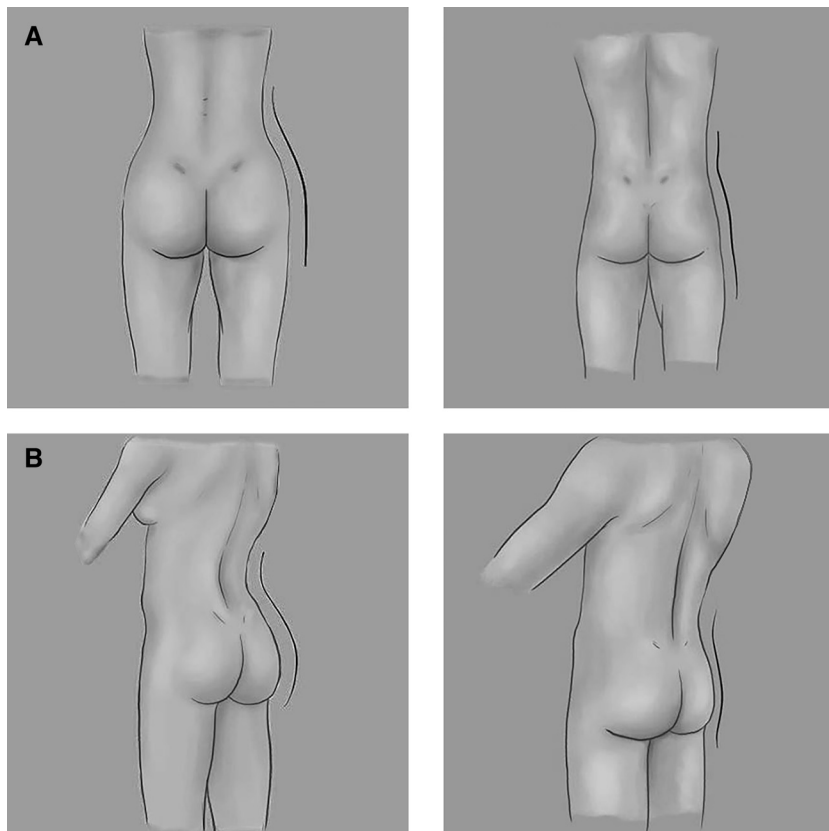


Fig. 2 (A, B) Differences of body habitus and fat distribution in females and males.

This might be in part due to the acute angulation of the ribs in females, an evolutionary adaptation designed to expand and accommodate for the increased volume during pregnancy.⁷

The Pelvis

The female pelvis is designed to be wide to be conducive for childbirth. In contrast, human male pelvis is optimized for bipedal locomotion. The female pelvis has a larger pelvic inlet and outlet than the male pelvis. Also, the hip is widely set in females than males.⁹ Male iliac crests are higher than females, causing their false pelvis to look taller and narrower.

Body Fat Distribution

Body fat distribution in both sexes, though comparable in childhood and old age, varies maximally after the effects of sex hormones come into action. Testosterone leads to preferential deposition of fat in the abdomen and inhibits deposition of fat in the hip area and the gluteal area leading to an android body habitus. On the other hand, estrogen produces a gynoid body habitus by preferential fat deposition in the hip and gluteal regions, leading to a narrow waistline and wide hips.

Role of Waist–Hip Ratio

Waist–hip ratio (WHR) in the ideal range is associated with increased physical attractiveness and considered a sign of a healthy body by both sexes. WHR can determine the female and male body fat distribution patterns by measuring the waist and hip circumferences.

Waist circumference is measured at the narrowest part of the body between the ribs and the iliac crest, whereas hip circumference is measured at the level of the maximum projection of the buttocks (–Fig. 3).

In females, there is preferential fat deposition in the hips and gluteal due to effect of estrogen, leading to a lower WHR, whereas in males the testosterone leads to more fat deposition in the abdomen area, leading to higher WHR.

Singh has proposed that though there are slight differences across various cultures, the ideal WHR range that men find attractive in females across ethnicities is 0.67 to 0.80.¹⁰ In males, ideal WHR ranges from 0.80 to 0.95.¹¹

Body Changes after Hormone Therapy

Sex steroid hormone is an important factor in the body form and habitus. It is a principal factor in the distribution of body fat, resulting in a gynoid or android appearance to the body. Though not mandatory as per guidelines, we advise body contouring surgeries after 1 year of hormone therapy, as hormone therapy will bring about favorable changes in the body habitus, mainly in the abdominal and gluteofemoral region.

Hormone therapy with estrogen and antiandrogens in male to female transgender individuals resulted in increase in subcutaneous fat deposition, mainly in the thigh region.¹² Hormone therapy with testosterone causes reduction in

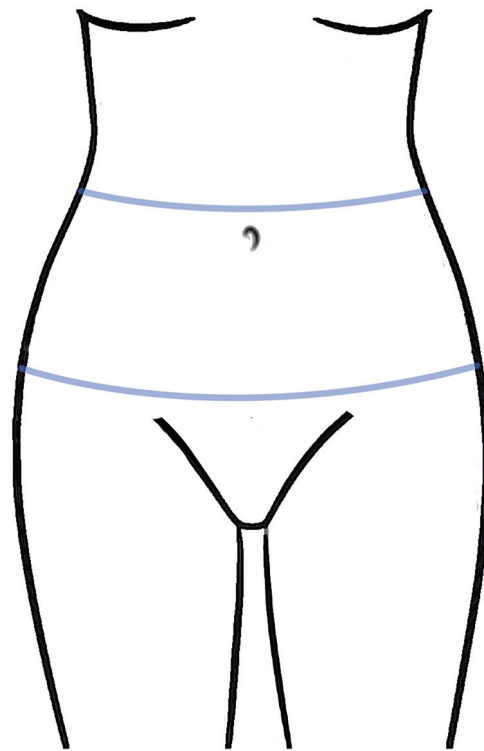


Fig. 3 Waist to hip ratio in a female. Ideal WHR in females is 0.67 to 0.80 and in males is around 0.90.

subcutaneous fat with increase in visceral fat, along with increase in thigh muscle mass.¹² Hence, hormone therapy has an important role in bringing about changes in body contour as well as physical transformation and should be emphasized before undertaking a body contouring surgery.

Body Contouring in Male to Female

Body contouring in male to female transgender individuals can be brought about by either soft tissue or skeletal contouring or a combination of both. Most transgender individuals who come for body feminization request breast augmentation as the initial surgery. However, other secondary contouring procedures that can be offered are waist and hip lipoplasty, buttock augmentation, torso contouring by excision of lower ribs and shoulder width reduction by clavicle reduction.

Soft Tissue Contouring

Soft tissue contouring methods like liposuction and fat grafting, though requires expertise and aesthetic sense, are much easier and safer to perform than skeletal modifications and is the mainstay of body contouring in male to female transgender individuals.

Liposculpturing of the Waist and Hip

As discussed earlier, the ideal female body has a narrower waist and a wider hip, with a smaller WHR. Male to female transgender individuals who undergo sex hormone therapy for a period of around a year develop changes in their body

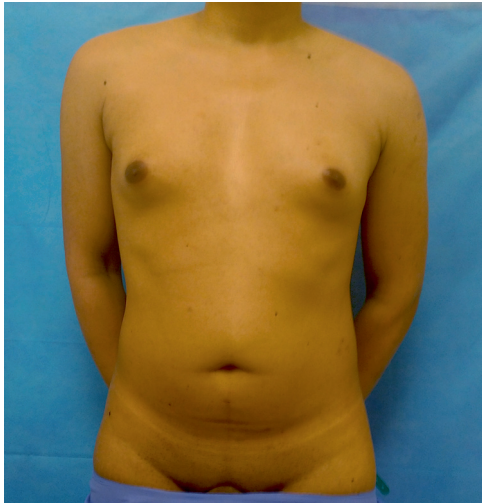

Fig. 4 A male to female transgender individual planned for body contouring for feminizing the waist hip ratio.

habitus with more fat distribution in the thighs and gluteo-femoral region, leading to a more feminine form (► **Fig. 4**).

If the individual desires a more feminine look, liposculpturing can be done to augment the feminine form. Typically, it consists of selectively performing liposuction in the waistline and abdomen, leading to a much slimmer waistline and grafting this fat to augment the hips and buttocks (► **Fig. 5**).

Special Considerations

Unlike genital or breast surgeries, World Professional Association for Transgender Health (WPATH) Standards of care doesn't specify definite criteria that must be met to undergo body contouring. Though liposculpturing in male to female transgender individuals is ideally performed after at least a year of hormone therapy to give time for fat redistribution, there are a subset of individuals who

does not have a substantial change in the body habitus or who are not candidates or unwilling to take hormonal therapy.

Owing to the more intra-abdominal deposit of fat due to testosterone, transgender individuals have less available fat deposits for fat grafting and liposuction compared with cisgender individuals.

Creating a feminine WHR involves creation of a waistline by liposuction of the waist and augmenting the hip diameter by fat grafting.

Roberts et al¹³ have suggested few characteristics of an ideal buttock shape, consisting of a gentle inward sweep of the lumbosacral area and waist, a feminine gluteal cleavage as the buttocks separate superiorly and inferiorly, maximum prominence in the middle and upper buttock, minimal intra-gluteal crease with no ptosis below this line.

Surgical Technique

Preferred donor areas for fat harvesting are the abdomen, flanks, waistline, and lumbosacral area. However, in most cases, fat available for harvest might be a limiting factor and hence prioritization of the injection sites needs to be done in discussion with the patient beforehand.¹⁴ It is our experience that liposuction of the bra rolls rarely yields significant fat in transgender individuals.

Marking is done with the patient in the standing position, and different color markings are done for areas that are planned for liposuction and fat grafting (► **Fig. 5**). The waistline is marked at the level 1 inch above the umbilicus.¹⁵

We perform liposuction using power-assisted suction liposuction (PAL) under general anesthesia using tumescent infiltration. Standard liposuction and fat grafting techniques are used. To minimize damage to the fat cells, we limit the negative suction pressure to 560 mm Hg.¹³ For large volume fat grafting, we employ expansion vibration lipofilling.¹⁶

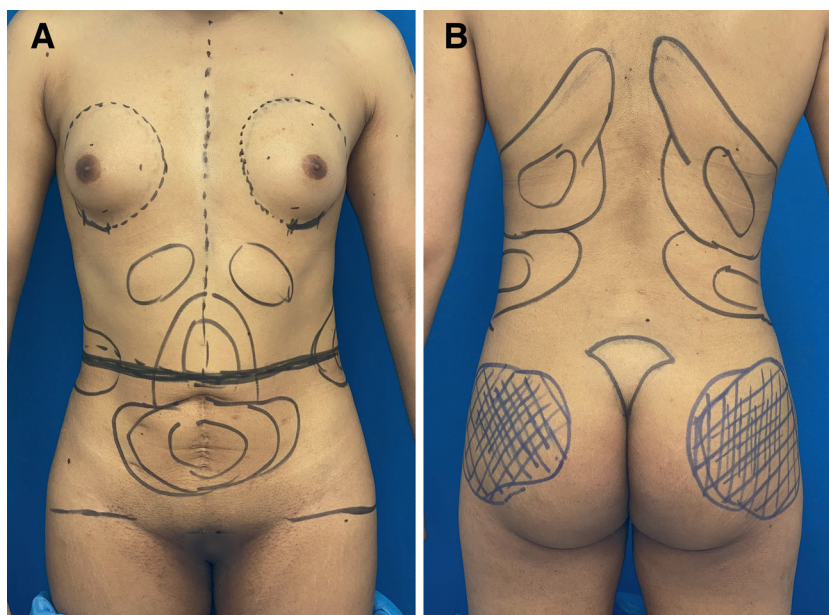


Fig. 5 Markings for liposculpturing. Areas marked in black are planned for liposuction, whereas areas marked in blue are planned for fat grafting.

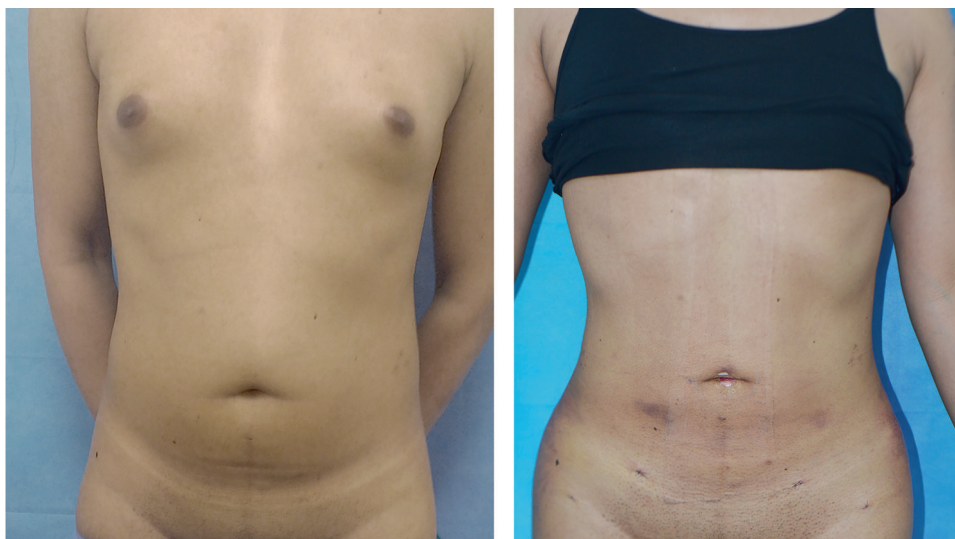

Fig. 6 Pre- and postoperative view of the patient who underwent liposuction of the abdomen and waist with fat grafting of the hips and buttocks.

Surgery is started initially in the supine position. The already marked waistline is accentuated with liposuction, continuing along the flanks to obtain a feminine gentle inward sweep. Paucity of fat deposits in these areas in transgender individuals might limit the extent of change that can be brought about.

In case of individuals in whom there is no paucity of fat obtained for correction of the hip dip, fat grafting to the hips is done before the patient is positioned to prone, to minimize the time from harvest to fat grafting. Any further fat grafting can be done using the fat obtained by liposuction in the prone position.

The patient is positioned prone and liposuction proceeds in the usual fashion. In our experience, our patients seldom ask for a shelf like transition between the lower back and buttock. Fat grafting is done using expansion vibration lipofilling method with priority given to the correction of the hip dip as well as projection of the centromedial buttock region.

As opposed to liposculpturing in females, in transgender individuals the body contouring relies heavily on the effects of liposuction and creating a lumbosacral inward sweep rather than on the augmentation by fat grafting. **Fig. 6** shows an individual who underwent liposuction of the waist with simultaneous fat grafting of the hips to create a more feminine WHR.

Postoperative Care

Customized compression garments are worn on the operation table. The garments are designed in such a way that the grafted areas are not under too much compression. A foam dressing is applied over the sacrum to promote skin adhesion and to prevent tenting up of the skin due to edema. This maintains the superior gluteal cleavage that is an important anatomical feature.¹³ Patient is nursed in the prone position. Standing and walking are allowed but sitting is prohibited for 2 weeks.

Skeletal Contouring

Shoulder Width Reduction

Shoulder feminization by surgical shortening of clavicle is a less researched procedure with hardly any published literature on it. The clavicle is the only skeletal structure that connects the upper limb to the axial skeleton. Any reduction in the clavicle length should therefore cause an equal decrease in the biacromial diameter. Shoulder width is measured in terms of biacromial diameter. On an average, the biacromial diameter in female is around 4.3 cm less than that of males.

The main concern about clavicle reduction is the potential functional disability to the shoulder joint. However, multiple studies done in clavicle fractures that were managed conservatively have shown that reduction in clavicle length of 2 cm or even greater does not affect the shoulder movements significantly.^{17,18}

The middle of the clavicle is the part that has least soft tissue attachments and is usually the site of a fracture in trauma. This part is also away from the articulation with the sternum medially and the acromioclavicular joint and the coracoclavicular ligament.

Clavicle reduction essentially consists of surgically removing a segment of the clavicle from the medial aspect of the middle third and an internal fixation using compression plates.

Surgical Technique

Markings are done in the standing position as the surface anatomy changes when the patient lies down. The skin is held stretched over the clavicle and the marking made so that the final scar is positioned in the supraclavicular fossa, which makes it less visible.

We perform clavicular reduction under general anesthesia. A skin incision around 4 to 5 cm long is made with the skin held stretched so that the marked incision site comes to lie over the clavicle. Incision is deepened through the

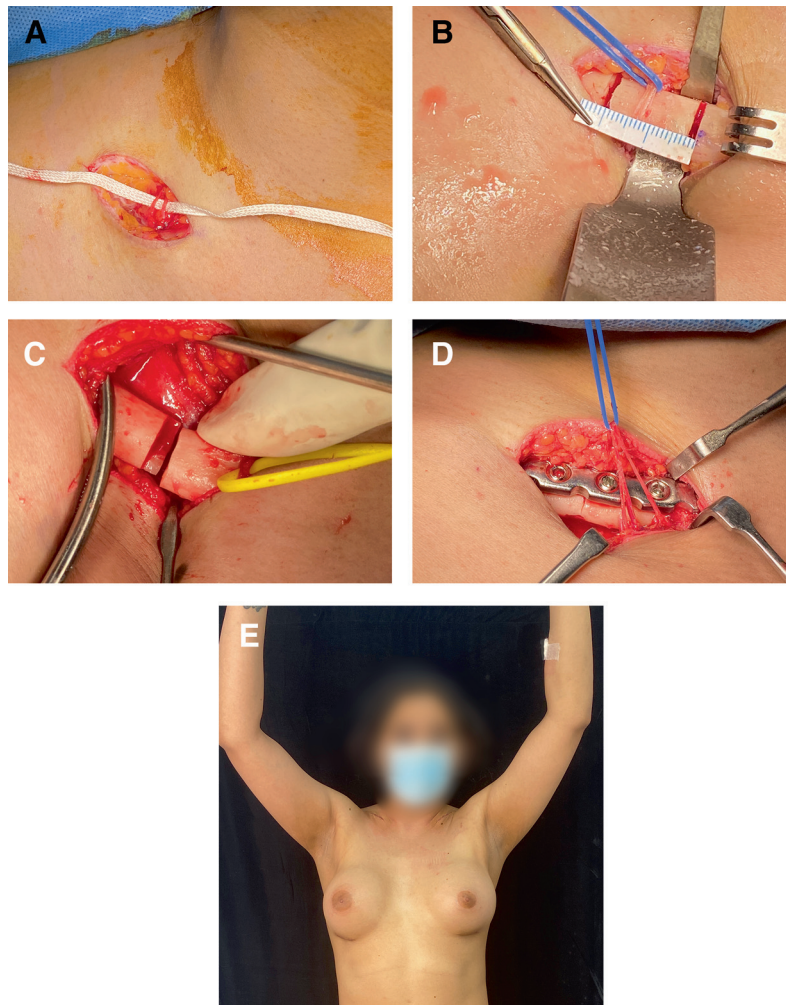


Fig. 7 (A) Skin incision made over the stretched skin and branches of supraclavicular nerves retracted. (B) 2–2.5 cm of clavicle bone (2.2 cm in this case) is removed with a saw. Underlying neurovascular structures are safeguarded. (C) A zig-zag step osteotomy is done for more stability and greater surface area of approximation. (D) Completion of internal fixation. (E) Same patient 10 days postsurgery showing complete range of motion of the shoulders.

clavipectoral fascia. Branches of supraclavicular nerves are safeguarded if encountered. Incision goes directly to the periosteum, which is incised and separated circumferentially. A segment of clavicle to be removed (around 2–2.5 cm long) is marked on the bone and it is excised with oscillating saw (► Fig. 7A–E).

This part of the procedure is to be performed keeping in mind the vital structures lying underneath—the brachial plexus, the subclavian vessels, and the apex of the lung.

After removal of the bone segment, congruence of the cross section of cut bone is confirmed. We plate the segments using a 3.5mm 6-hole dynamic compression plate with bicortical screws in the superior aspect of the clavicle. The approximation is confirmed, and incision closed meticulously to avoid contour abnormalities. The suture line retracts up into the supraclavicular fossa (► Fig. 8).

Postoperative Care

After plate and screw fixation, some authors advocate early full range mobilization of the shoulder the very next day.¹⁹

We, however, rest the upper limb in slings for the first week during which the patient performs activities of daily living with limited shoulder movements. It is followed by active motion of the shoulder. Full strength movements and sports are commenced at 3 months.

Outcomes

Two patients underwent clavicle shortening and both patients had uneventful recovery with return of full range of motion. Both patients described shoulder reduction as one of the most satisfying procedures they underwent (both patients had undergone facial feminization, feminization rhinoplasty and breast augmentation). However, a larger series of patients need to be studied to draw conclusive evidence.

Rib Cage Contouring

Ferreira et al in their review article has concluded that there is not enough scientific evidence to support the practice, effectiveness, and safety of the resection of ribs for aesthetic purposes.²⁰

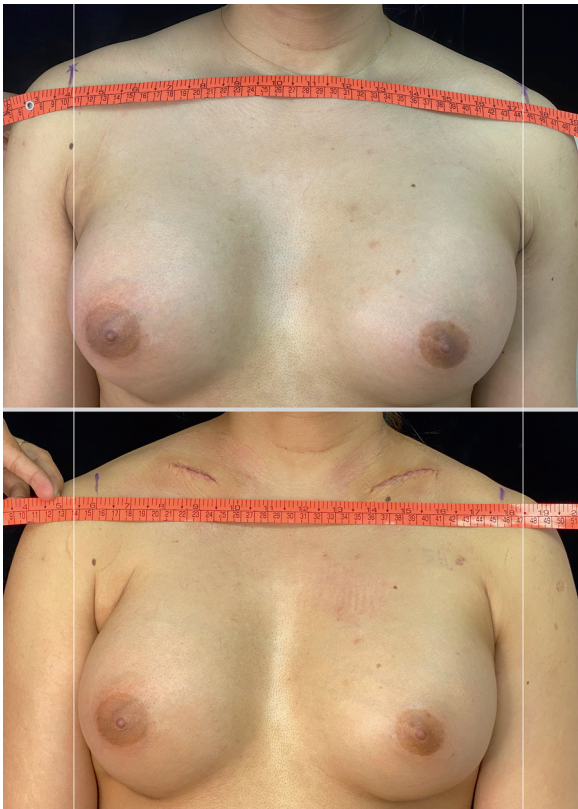

Fig. 8 Pre- and postoperative photos showing reduction in biacromial diameter by 5 cm.

Rib excision has the potential to affect lower lung inflation and can affect the structural integrity of the lower chest wall²¹ and the authors do not condone this procedure. Readers are encouraged to go through this article by Davison et al for detailed procedure.⁸

Body Contouring in Female to Male

Masculinizing procedures in female to male transgender individuals relies heavily on soft tissue rather than skeletal alteration.

Testosterone therapy can cause significant masculinization in the body including distribution of fat, increase of facial and body hair, masculine scalp hair line, masculine voice, and increased tone and bulk of muscles.

However, there are usually areas of unresponsive fat deposits, especially in the buttock and thigh areas that might need to be surgically contoured.

Contouring of Abdomen

The masculine WHR of 0.9 is considered as the most attractive,²² as opposed to values of 0.67 to 0.80 in females.

The fundamental aspect of body contouring in female to male transgender individuals is the reversal of this WHR to give a more masculine appearance. This is achieved by a combination of liposuction as well as fat grafting techniques.

Male Abdomen

Goals of contouring in female to male transgenders include:

1. Masculinization of the WHR
2. Obtaining a masculine defined appearance to anterior abdomen

Masculinization of the Waist–Hip Ratio

The male hip has a more concave hip dip compared with the convex contour of the feminine hip. Masculinization is accomplished by liposuction of the lateral hip and buttock areas and in select cases, grafting the fat to the waist region.

Surgical Technique

Markings are done with the patient in the standing position.

The areas planned for liposuction are the buttock area and the lateral thigh areas, but it needs to be tailored according to the body habitus of each patient.

The patient is positioned prone under general anesthesia and tumescent fluid is infiltrated. Liposuction is done as per standard protocols, and fat harvested into sterile containers if fat grafting to waist is planned. The suction pressure is maintained at no more than 560 mm Hg to increase viability of the fat cells. The volume of aspirate is highly variable, but around 200 to 400 cc of aspirate is obtained from one side of lateral hip and from each buttock. Liposuction of the infra-gluteal fold is not done to prevent contour abnormalities.

The patient is now made supine, and any further liposuction is performed.

The harvested fat is then grafted to the waistline to reduce the concavity as well as to give a more boxy appearance of the torso. We prefer expansion vibration lipofilling for fat grafting.¹⁶ To account for resorption of grafted fat, we perform overfilling by around 20 percentage more than the required amount. A customized compression garment is worn post-operatively for 6 weeks (►Fig. 9).

High-Definition Liposculpture of the Anterior Abdomen

High-definition liposculpturing is usually done along with top surgery and lateral chest wall contouring. We use the PAL system (Microaire, Inc., Charlottesville, Virginia, United States) for the liposculpturing. This was popularized by Hoyos²³ in 2003. Liposuction in the deeper plane is done to debulk the fat and in the superficial plane to deepen the natural grooves.²⁴

Surgical Technique

Markings are made in the supine and standing positions. The rectus muscle anatomy is delineated by palpating and marking the inscriptions with the patient flexing the abdominal muscles. Surgery is done in the supine position with arms abducted.

Tumescent infiltration is performed. Ports are made in the umbilicus, right and left lower iliac fossa along the lateral border of the rectus muscle, and at the levels of the inscriptions. Deeper followed by superficial liposuction is done.

No drains are used. Lateral chest and infra-axillary areas are also contoured to give a better definition to the lateral border of the pectoralis major muscle (►Fig. 10).

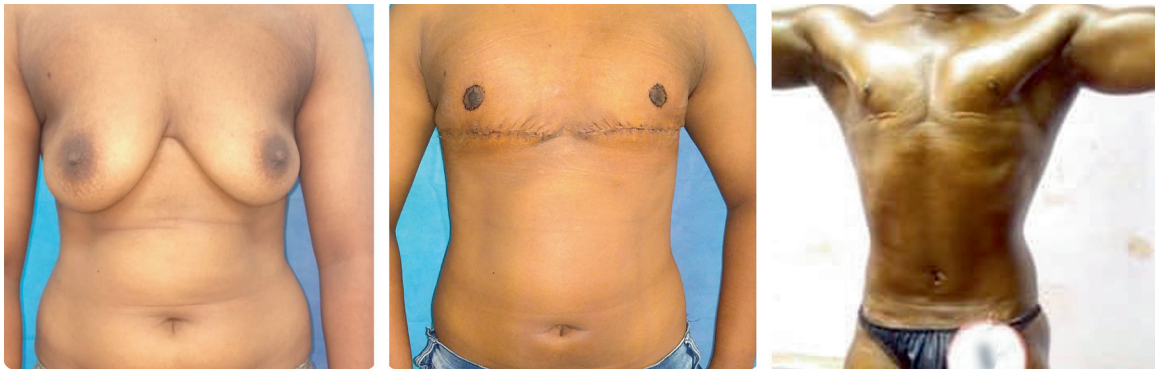

Fig. 9 Masculinization of the waist–hip ratio. (A) Preoperative photo. (B) One month post-surgery—liposuction of the waist along with double incision mastectomy. (C) Effect of hormone therapy (250 mg testosterone monthly injections) showing better muscle mass.

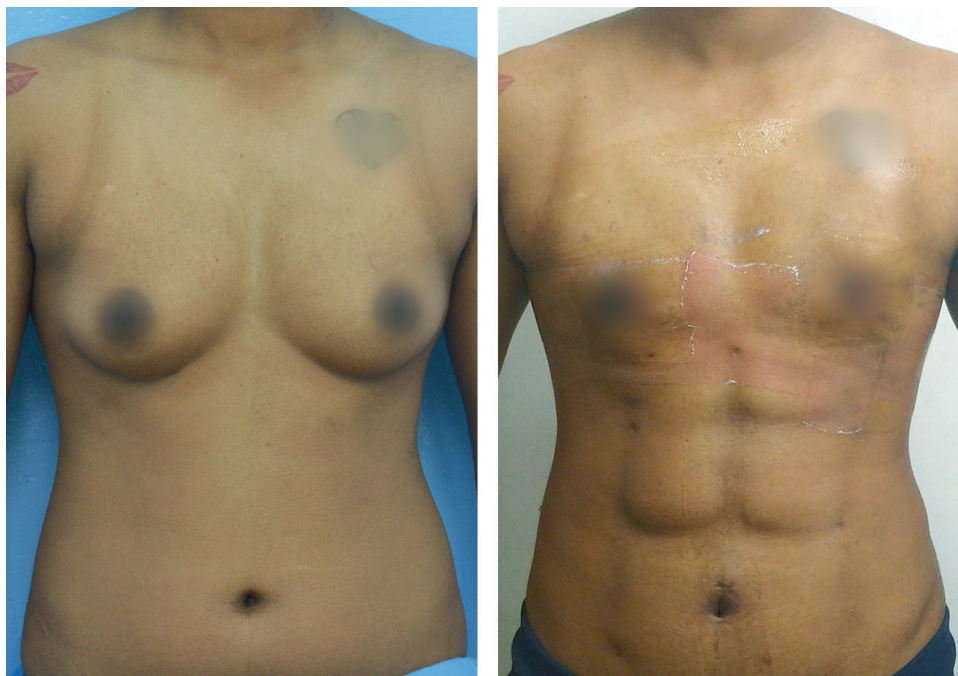

Fig. 10 High-definition liposuction of the abdomen using power-assisted liposuction. (Patient has also undergone periareolar concentric mastectomy).

Postoperative Care

Compression foam or folded paraffin gauze is used for dressing over the inscriptions and grooves. Custom compression garment is applied, and patient is instructed to continue it for 3 weeks.

Ancillary Procedures—Abdominoplasty

Lipoabdominoplasty might be required in female to male gender incongruent individuals who ask for masculinization who had prior pregnancies. Such individuals might have hanging panniculus and stretch marks in the lower abdomen with or without surgical scar of cesarean section. The aim in such cases is not only to get rid of the hanging panniculus but also to give a masculine appearance.

It differs from tummy tuck in females in that the scar is more horizontal. The umbilicus is made more round or hori-

zontal rather than vertical. In addition, fat grafting can be done to the waist in order to create a more masculine WHR.

Conclusions

Body contouring procedures are on the rise due to increased awareness in the community, starting at the primary level.²⁵ These are preferably performed after the individual has received hormone therapy for a year, which helps to redistribute the soft tissues and facilitates a better physical transformation. The surgical plan is tailored according to the wishes and concerns of each patient. Soft tissue contouring is an effective and safer method of physical transformation as compared with skeletal surgeries. More research is needed in gender affirming body contouring to understand the intricacies and provide quality healthcare to transgender individuals.

Conflict of Interest

None.

References

- 1 Colebunders B, Brondeel S, D'Arpa S, Hoebeke P, Monstrey S. An update on the surgical treatment for transgender patients. *Sex Med Rev* 2017;5(01):103–109
- 2 Olson-Kennedy J, Cohen-Kettenis PT, Kreukels BP, et al. Research priorities for gender nonconforming/transgender youth: gender identity development and biopsychosocial outcomes. *Curr Opin Endocrinol Diabetes Obes* 2016;23(02):172–179
- 3 Weinforth G, Fakin R, Giovanoli P, Nuñez DG. Quality of life following male-to-female sex reassignment surgery. *Dtsch Arztebl Int* 2019;116(15):253–260
- 4 Kraemer B, Delsignore A, Schnyder U, Hepp U. Body image and transsexualism. *Psychopathology* 2008;41(02):96–100
- 5 Wesp LM, Deutsch MB. Hormonal and surgical treatment options for transgender women and transfeminine spectrum persons. *Psychiatr Clin North Am* 2017;40(01):99–111
- 6 Stoudt HW, Damon A, McFarland R, Roberts J. Skinfolds, body girths, biacromial diameter, and selected anthropometric indices of adults: United States. National Center for Health Statistics. *Vital Health Stat* 1960–1962;11(35):23–27
- 7 Bellemare F, Jeanneret A, Couture J. Sex differences in thoracic dimensions and configuration. *Am J Respir Crit Care Med* 2003;168(03):305–312
- 8 Davison SP, Clifton MS, Futrell W, Priore R, Manders EK. Aesthetic considerations in secondary procedures for gender reassignment. *Aesthet Surg J* 2000;20(06):477–481
- 9 Smith FW, Smith PA. Musculoskeletal differences between males and females. *Sports Med Arthrosc Rev* 2002;10(01):98–100
- 10 Singh D. Adaptive significance of female physical attractiveness: role of waist-to-hip ratio. *J Pers Soc Psychol* 1993;65(02):293–307
- 11 Jones PR, Hunt MJ, Brown TP, Norgan NG. Waist-hip circumference ratio and its relation to age and overweight in British men. *Hum Nutr Clin Nutr* 1986;40(03):239–247
- 12 Elbers JM, Asscheman H, Seidell JC, Gooren LJ. Effects of sex steroid hormones on regional fat depots as assessed by magnetic resonance imaging in transsexuals. *Am J Physiol* 1999;276(02):E317–E325
- 13 Roberts TL III, Weinfeld AB, Bruner TW, Nguyen K. “Universal” and ethnic ideals of beautiful buttocks are best obtained by autologous micro fat grafting and liposuction. *Clin Plast Surg* 2006;33(03):371–394
- 14 Morrison SD, Wilson SC, Mosser SW. Breast and body contouring for transgender and gender nonconforming individuals. *Clin Plast Surg* 2018;45(03):333–342
- 15 Brown JE, Potter JD, Jacobs DR Jr, et al. Maternal waist-to-hip ratio as a predictor of newborn size: results of the Diana project. *Epidemiology* 1996;7(01):62–66
- 16 Del Vecchio D, Wall S Jr. Expansion vibration lipofilling: a new technique in large-volume fat transplantation. *Plast Reconstr Surg* 2018;141(05):639e–649e. Doi: 10.1097/PRS.0000000000004338 Erratum in: *Plast Reconstr Surg*. 2018 Jul;142(1):295. PMID: 29465484
- 17 Figueiredo GSL, Tamaoki MJS, Dragone B, et al. Correlation of the degree of clavicle shortening after non-surgical treatment of midshaft fractures with upper limb function. *BMC Musculoskelet Disord* 2015;16:151. Doi: 10.1186/s12891-015-0585-3
- 18 Nordqvist A, Redlund-Johnell I, von Scheele A, Petersson CJ. Shortening of clavicle after fracture. Incidence and clinical significance, a 5-year follow-up of 85 patients. *Acta Orthop Scand* 1997;68(04):349–351
- 19 Cole PA, Dyskin E, Dugarte AJ, Hesse D. Open reduction and internal fixation of a middle-third clavicle fracture with a superior plate. *JBJS Essential Surg Tech* 2017;7(02):e16
- 20 Ferreira LM, Ferreira PEN, Bernardes ABS, et al. Aesthetic contouring of the chest wall with rib resection. *Aesthetic Plast Surg* 2021;45(03):1099–1104
- 21 Israel GE, Tarver DEI II. (1997). *Transgender Care: Recommended Guidelines, Practical Information, and Personal Accounts*. Philadelphia, PA: Temple University Press
- 22 Singh D. Female judgment of male attractiveness and desirability for relationships: role of waist-to-hip ratio and financial status. *J Pers Soc Psychol* 1995;69(06):1089–1101
- 23 Hoyos AE. High definition liposculpture. Presented in the XIII International Course of Plastic Surgery, 2003, Bucaramanga, Colombia
- 24 Saad AN, Pablo Arbelaez J, De Benito J. High definition liposculpture in male patients using reciprocating power-assisted liposuction technology: techniques and results in a prospective study. *Aesthet Surg J* 2020;40(03):299–307
- 25 Sukumar S, Mittal R, Kalra S. Transgender medicine in primary care. *J Pak Med Assoc* 2020;70(10):1862–1863