

Israeli Innovations in the Field of Plastic Surgery

Lior Har-Shai, MD^{1,2} Sar-El Ofek, BSc² Stav Cohen, BMSc² Keren H. Cohen, MD^{1,2}
Dafna Shilo Yaacobi, MD^{1,2} Asaf Olshinka, MD^{1,2} Rami P. Dibbs, BA^{3,4} Dean D. Ad-El, MD^{1,2}

¹ Department of Reconstructive Plastic Surgery & Burns, Rabin Medical Center – Beilinson Hospital, Petach Tikva, Israel

² Sackler Faculty of Medicine, Tel Aviv University, Tel Aviv, Israel

³ Division of Plastic Surgery, Texas Children's Hospital, Houston, Texas

⁴ Michael E. DeBakey Department of Surgery, Division of Plastic Surgery, Baylor College of Medicine, Houston, Texas

Address for correspondence Dean D. Ad-El, MD, Department of Plastic Surgery & Burns, Rabin Medical Center – Beilinson Hospital, 39 Ze'ev Jabotinsky St., Petach Tikva, 4941492, Israel (e-mail: deana@clalit.org.il).

Semin Plast Surg 2022;36:55–65.

Abstract

Keywords

- ▶ innovation
- ▶ entrepreneurs
- ▶ start-up
- ▶ plastic surgery
- ▶ Israel

Numerous innovations within the field of plastic surgery have been developed in Israel over the last few decades. Many of these therapeutic devices and techniques have been established globally with demonstrable efficacy and respectable safety profiles. This article offers an overview of recent Israeli cutting-edge medical therapeutic solutions contributing to the global practice of plastic surgery.

Israel has become a global center of technological innovation over the last decade.¹ With one of the most dense and active technological ecosystems in the world and the highest per capita several start-up companies, Israel has earned its well-deserved nickname, “The Start-Up Nation.”² The Israel Innovation Authority, an independent government-funded agency, actively supports technological initiatives and organizes incentive programs to help entrepreneurs transfer their ideas into new products.^{3,4}

The healthcare industry is recognized as one of many areas that has benefited from Israeli ingenuity, from the development of cardiac stents to advances in gene therapy to the introduction of novel techniques for in vitro fertilization and bone marrow transplantation.^{2,5} Among the various medical fields, plastic surgery has witnessed great inroads in research and innovation, starting in the 1970s with the Sharplan Laser, developed by both Dr. Isaac Kaplan, founder of the Department of Plastic Surgery of Beilinson Hospital (now recognized as Rabin Medical Center), and Uzi Sharon, a mechanical engineer (▶ Fig. 1).⁶ In this review, we aim to present Israeli innovations in plastic surgery, some of which have evolved into widely used products that continue to impact clinical practice on a global scale and will serve to pave the way for novel advancements in the future.

Breast Reconstruction

B-Lite, G&G Biotechnology, Ltd., Haifa, Israel

Since their establishment in the United States in 1962, breast implants have been increasingly used for breast augmentation and reconstruction.^{7,8} Numerous types of breast implants have since been designed each with their own set of unique characteristics based on volume, texture, composition, and shape. However, the weight of the implant typically causes significant stress on the surrounding soft tissues resulting in gradual, continuous breast ptosis, atrophy, and deformity.⁸ Consequently, Dr. J. Govrin-Yehudain, former director of the Department of Plastic Surgery at Western Galilee Hospital, developed a novel, lightweight implant known as the B-Lite Lightweight Breast Implant to address these complications for patients undergoing breast augmentation (▶ Fig. 2). B-Lite breast implants are manufactured by G&G Biotechnology, which became a subsidiary of POLYTECH Health & Aesthetics GmbH, Dieburg, Germany in 2018. Additionally, the technology implemented in the B-Lite Lightweight Breast Implants has been granted ISO and CE quality assurance certification.⁹

The B-Lite Lightweight Breast Implant is composed of a silicone gel filler that maintains strong chemical bonds with inert, high-purity, hollow, borosilicate microspheres within




Fig. 1 Dr. Isaac Kaplan (1919–2012), a pioneer in the field of CO₂ laser medicine.



Fig. 2 The B-Lite lightweight breast implant, G&G Biotechnology.

the implant. The powerful bonds between the microspheres and the silicone gel help to ensure the form and structure of the implant remains over an extended time.⁹ Additionally, these breast implants are 30% lighter than their traditional silicone implant counterparts by nature of its unique composition, placing less stress on the breast tissues while preserving their stability and integrity over time.^{9–11}

B-Lite breast implants have demonstrated a high safety profile and have been associated with a relatively low postoperative complication profile. Preclinical studies have established that the structural integrity of the implant remains following numerous fatigue resistance tests.⁹ Govrin-Yehudain et al reported a 6.3% overall complication rate among 1653 B-Lite implants (655 patients) placed over a 5-year period requiring a total of 26 reoperations among 22 women. Additionally, only 14 patients presented with postoperative capsular contracture, and no patient demonstrated recurrent ptosis, postoperatively.⁸ In another study comparing women who underwent breast augmentation with lightweight implants and traditional silicone implants, the postoperative analgesic duration and recovery course were significantly shorter within the lightweight cohort.¹⁰

OrbiShape Breast Supporting System, Orbix Medical, Tel Aviv, Israel

Breasts progressively undergo ptosis with age. Traditional mastopexy techniques are typically performed to counteract this natural phenomenon by removing skin and/or manipulating the underlying soft tissue.¹² While this surgical procedure may temporarily correct breast ptosis, recurrent ptosis is a frequent postoperative complication. Concomitant procedures including horizontal glandular flaps, dermis strips, and fascial suspensions have also been performed to further mitigate ptosis; however, these techniques all rely on native tissue, which inherently undergo similar aging processes that affect their functional integrity and structural stability.^{12–14} Consequently, nonautologous tissue reinforcement have been utilized to minimize this complication.¹⁵ It has been shown that utilizing a nonautologous, internal breast support system can prevent recurrent ptosis following mastopexy while also providing a more youthful appearance.¹⁶ However, Atiyeh et al demonstrated that while the use of synthetic meshes for breast support has a good safety profile with promising results, no conclusive evidence supporting their use over autologous surgical options could be deduced because of the paucity of high-level evidence currently available in the literature.¹⁵

Orbix Medical is a privately owned company that develops and markets medical devices to provide minimally invasive solutions within the field of aesthetic surgery. The company was founded in 2004 by Dr. Eyal Gur, Director of the Department of Reconstructive and Aesthetic Surgery at the Tel Aviv Medical Center. Its revolutionary, minimally invasive OrbiShape Breast Support System, designed for use in breast reduction and mastopexy procedures, consists of a silicone sheet that covers and supports the underlying breast tissue functioning like a subdermal bra. The mesh is then sutured to the ribcage, creating a natural-looking breast that serves as a permanent reinforcement support (►Fig. 3).

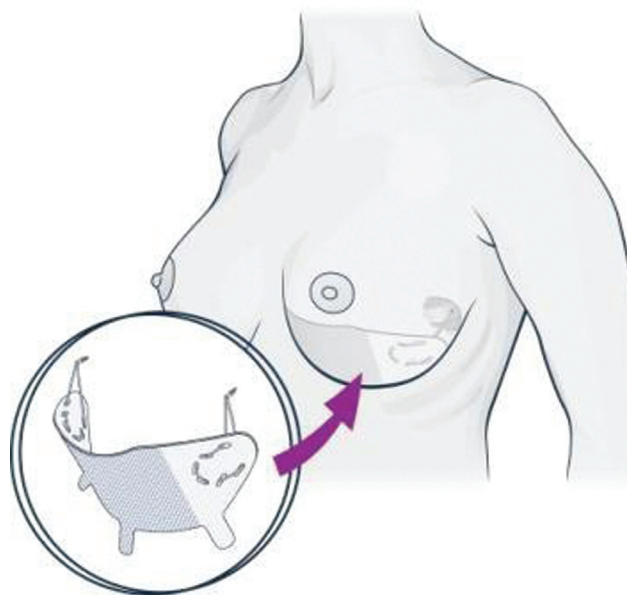


Fig. 3 OrbiShape Breast Support System, Orbix Medical.

From our experience, the Breast Support System has demonstrated superior postoperative results compared with other reconstructive techniques. We have not observed any significant recurrent ptosis utilizing the OrbiShape Support System. Other reconstructive options, however, frequently require that the breasts be lifted relatively higher than with the internal system to compensate for ptosis over time. Additionally, patients (particularly those who present with a C-cup size or larger) report that they rarely feel the implant. The Breast Support System is CE marked and has recently undergone a series of successful clinical trials in Europe.

Microsurgery

Vesseal, Lydus Medical, Raanana, Israel

Microsurgery is a critical component to any free-tissue transfer operation. The technical complexity involved with performing microsurgical anastomoses warrants the involvement of an experienced surgeon to optimize its success. In fact, the majority of free flap reconstruction failures can be attributed to technical errors associated with the vessel anastomosis.¹⁷ Microvascular coupling devices have been used to improve postoperative outcomes and mitigate the associated complexity of the given procedure. These devices have been proven to reduce operative time, flap failure rate, and technical skill needed to perform microsurgery.^{17–19}

Perfect intima-to-intima contact, vessel eversion, and rigid external stenting are all factors that contribute to the success of microvascular anastomosis when performed with an anastomotic coupler device.^{20,21} These elements function to reduce the risk of vessel collapse and spasm, minimize intima tears, and prevent contact between thrombogenic foreign bodies and the vessel lumen.^{17,20,21} Moreover, these devices have demonstrated considerable cost-savings over traditional hand-sutured venous anastomoses and recover the device's capital expenditure after 13 uses.²²

A unique microvascular coupling device has recently been manufactured in Israel by the company, Lydus Medical, and is in the final experimental testing stages required for U.S. Food and Drug Administration (FDA) approval. Lydus Medical was founded in 2017 by Dr. Dean Ad-El, Director of the Department of Reconstructive Plastic Surgery & Burns at Rabin Medical Center, and Kamall Daas, an entrepreneur, to provide simple, automated alternatives to manual small-vessel anastomosis. Its first product, the Vesseal, is a unique, automated microvascular suturing device and involves the placement and safe, automatic insertion of microsurgical needles into each of the juxtaposed vessel walls followed by simple thread-only anastomosis (– Fig. 4).

Wound Management

Sure-Closure, Life Medical Sciences, Princeton, NJ

Closure of skin and soft tissue defects can pose a challenge to the reconstructive surgeon. The successful coverage and closure of skin and soft tissue defects rely heavily on the



Fig. 4 The Vesseal for small vessel anastomosis, Lydus Medical.

operative technique performed as well as on the size, anatomical location, and depth of the defect.

The Sure-Closure system was invented by Dr. Bernard Hirshowitz, one of the founders of plastic surgery in Israel and former head of the Department of Plastic Surgery at RAMBAM healthcare campus. In their index study in 1993, Hirshowitz et al published their work on the novel skin-stretching device, Sure-Closure system, for closure of soft tissue defects.²³ This device is composed of three separate parts: two pins that are threaded through the dermis of the wound margins on either side of the defect, two “U” arms that each contain a pair of sharp hooks used to engage the two pins, and a threaded screw that attaches centrally to the two arms (– Fig. 5).^{23–25} Using this device, the skin undergoes incremental traction typically for around 20 to 30 minutes, but may be extended depending on the anatomical location and size of the defect.^{24–26}

The Sure-Closure system capitalizes on the viscoelastic properties present within the integumentary system by means of incremental traction.^{23,25,27} The skin undergoes two biomechanical processes under tension, which include creep and stress relaxation. Intraoperatively, mechanical creep refers to the acute physical forces that allow the skin to stretch as a direct result of realignment of the collagen fibers in parallel to the direction of tension, displacement of fluid from stretched tissue, and microfragmentation of elastic fibers.^{25,27,28} Stress relaxation is a phenomenon that allows the stretched skin to maintain its length under less tension over time.²⁵

This device has been utilized for a vast array of skin and soft tissue defect etiologies across diverse anatomical locations with demonstrable success. It has been used to aid in closures of fasciotomies, scalp reduction, burns, pedal wounds, fibula free flap donor sites, and groin defect following inguinal lymphadenectomy.^{23–27,29–31} Postoperative complications are uncommon and relatively mild with wound dehiscence, scar hypertrophy, and partial skin necrosis comprising the majority of adverse events.²⁵ In their comparison study, Narayanan et al also demonstrated that compared with their control group who underwent traditional closure methods (i.e., skin graft and local flaps), the operative time and total cost were lower for the device cohort.²⁴

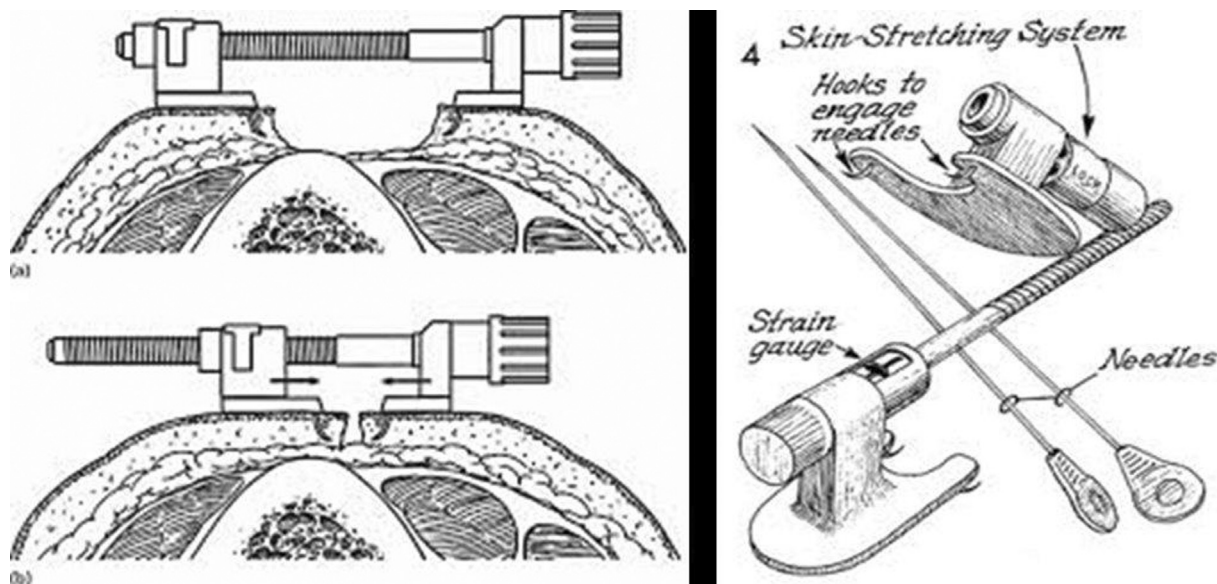


Fig. 5 The Sure-Closure skin-stretching device, Life Medical Sciences (Princeton, NJ).

Wisebands, Wisebands Ltd., Misgav, Israel

Wisebands also serves as a mechanical device used to aid in closure of skin and soft tissue defects and was invented by Dr. Jerry Weiss within the Department of Reconstructive and Aesthetic Surgery at Tel Aviv Medical Center. The device consists of three components, which include a band 50 cm long and 5 mm wide, a surgical needle on one end of the band, and a tension feedback control mechanism attached to the other end (→ Fig. 6).^{32,33} The needle is passed through the skin and underlying soft tissue through one side of the wound margins before being passed along through the soft tissue on the opposing wound margin and emerging superficially through the skin on the other end. The band is cut just proximal to the needle and is placed through the feedback tension control device. The knob on the device can be turned to place tension along the wound margins and aid in reapproximating the wound edges. Tension cannot exceed 1 kg/cm²; any attempt to surpass this tension amount will result in the device locking until the tension falls below this value and is ready for establishing additional tension between the wound margins.^{32,33}

Similar to Sure-Closure, Wisebands harnesses the viscoelastic properties of skin to reapproximate soft tissue defects by way of creep and stress relaxation. This mechanical device



Fig. 6 The Wisebands skin- and soft tissue-stretching device, Wisebands.

has garnered success for its efficacy, safety, and relatively low postoperative morbidity.^{32–34} In their initial study of 20 patients, Barnea et al reported a 90% success rate with two patients requiring removal of the device due to (1) intractable pain and (2) infection. Similarly in their follow-up study of 16 patients with fasciotomy wounds, 14 reported great outcomes.³³

While Wisebands not only offers similar advantages to other mechanical devices but also provides a set of benefits that are unique to it. Like other mechanical stretching devices, it mobilizes local tissue to provide an ideal color and texture match.^{23,33} It also does not involve the undermining of skin for reapproximating the wound edges, which minimizes the risk of neurovascular compromise.^{32–34} Unique to Wisebands, the device reapproximates both the skin and underlying soft tissue, thus obviating any dead space deep to the skin closure by nature of its procedural technique. Lastly, by controlling the tension placed along the wound margins (i.e., maximum of 1 kg/cm²), the risk of developing wound complications is reduced.³²

TopClosure and Vcare α, IVT Medical Ltd., Raanana, Israel

The TopClosure Tension Relief System (TRS) is another innovative mechanical skin-stretching system founded by Dr. Morris Topaz, former head of Plastic Surgery at Hillel Yaffe Medical Center and chair of the involved company, IVT Medical Ltd. Similar to the previously mentioned devices, TopClosure also utilizes the viscoelastic properties present in skin for closure of skin and soft tissue defects.^{35,36} The device is composed of two malleable polymer attachment plates (APs) that are fixed to the skin at a particular distance from the wound margins with adhesive tape and are stapled or sutured in place. The APs are incrementally pulled together to aid in reapproximating the wound margins using flexible approximation straps via a lock and release ratchet mechanism (→ Fig. 7).^{35,37,38} Multiple devices can be placed

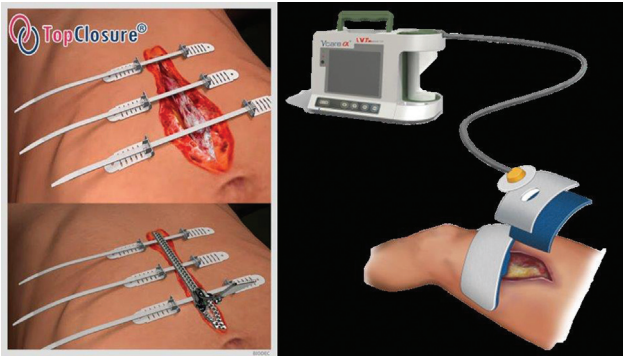


Fig. 7 The TopClosure Tension Relief System for the management of simple and complex wounds (left) and the Vcare α for enhancing healing of infected, complex, hard-to-heal wounds (right), IVT Medical.

perpendicular to the wound closure depending on the size of the defect.

Regulated negative pressure-assisted wound therapy (RNPT) is typically utilized concurrently with the TopClosure device.^{39–41} RNPT aids in wound closure, reduces the rate of infection, and enhances wound healing. The risk of infection is considered to be lower because RNPT helps in facilitating microvascular circulation, decreasing the number of dressing changes required, and providing a favorable healing environment.^{42,43} Similarly, it promotes wound healing by stimulating angiogenesis, forming granulation tissue, and removing healing inhibitors.^{42,44} The Vcare α system is also a novel vacuum therapy device developed by IVT Medical Ltd. This negative pressure device can be used with TopClosure and was designed primarily to decontaminate the wound and remove excess fluid (**Fig. 7**).^{38,40,45}

TopClosure TRS and negative pressure therapy have been utilized with demonstrable success across a variety of anatomical locations and for a diverse set of clinical presentations. Since its index study, TopClosure has been successfully used to manage congenital nevi, traumatic hemipelvectomy, bladder extrophy, enteroatmospheric fistula, and extensive abdominal wall defect following malignancy resection.^{35,37,40,43,45–47} Topaz has presented numerous studies in the literature reporting on its positive outcomes for managing medium and large soft tissue defects with a low posttreatment complication profile.^{35,36,38,47} Supplementing management with oxygen therapy has proven to be effective and may also reduce the risk of anaerobic bacterial contamination and mitigate risk of infection.^{38,39} When applied together with oxygen therapy, the TopClosure and the Vcare α offer a unique, innovative concept of wound management for use in a wide range of surgical applications.

NexoBrid, MediWound Ltd., Yavne, Israel

Burn injuries remain a global public health crisis and can result in significant morbidity and mortality.⁴⁸ Severe burns frequently develop eschars overlying the wound, which can serve as a nidus for infection and delay wound healing.^{49–51} Consequently, early removal of the eschar is critical to improve postoperative outcomes.⁴⁹ The current standard



Fig. 8 The NexoBrid enzymatic topical agent for eschar removal, MEdiWound.

of care involves surgical debridement of the eschar; however, high surgical acumen is required to assess the depth of injury to differentiate viable from nonviable tissue. Oftentimes, viable tissue is sacrificed thus requiring additional surgery to cover full-thickness defects. Operative intervention also results in substantial heat loss and blood loss.^{52,53}

Nonoperative approaches including hydrosurgery and enzymatic debridement have also been developed for burn management. NexoBrid is bromelain-based enzymatic debridement agent produced by MediWound Ltd. that is widely used in Europe and is currently undergoing a phase 3 trial in the United States (**Fig. 8**).^{52,54} It was developed by Dr. Lior Rosenberg, former Chair of the Department of Plastic Surgery, Soroka University Hospital.

NexoBrid's application follows a relatively simple protocol. After superficially debriding and preoperatively soaking the wound (if dry eschar is present), a thin (1.5mm–2mm) layer of NexoBrid is lathered along the wound and covered with sterile, occlusive dressings for 4 hours. The dressing is then removed, and the wound is soaked in a sterile saline solution for 2 hours. If incomplete debridement is observed, a second 4-hour application is performed.⁵²

NexoBrid application has proven to be an effective technique for managing burn eschars.^{49,52,54–56} This enzymatic debridement agent selectively debrides nonviable tissue and preserves unscathed deep dermal tissue, which can epithelialize without undergoing additional autografting.⁵² It has been used to manage burns across various anatomical areas from the perineum to the distal extremities with a predilection for improved outcomes in burns with total body surface areas less than 15%.^{55,57–59} Rosenberg et al were the first to report on the efficacy of this agent, demonstrating its comparable long-term outcomes compared with surgical debridement.⁵² Given its unique ability to preserve unburned tissue, NexoBrid has been shown to reduce blood loss, infection rate, surgical excisions, donor site morbidity, and length of hospital stay.^{49,52,55} Accordingly, it offers considerable advantages compared with the traditional standard of care.

Body Contouring

UltraShape, UltraShape Ltd., Yokneam, Israel

Liposuction ranked fourth among the most frequent cosmetic operative procedure performed in the United States with over 210,000 surgeries reported in 2020.⁶⁰ Liposuction involves the removal of excess fat deposits for the purpose of improving the shape of specific body areas. Though very commonly performed, however, liposuction is an invasive procedure with its own set of adverse complications. Ultrasound-assisted liposuction improves upon traditional liposuction techniques by disrupting adipose tissue via its delivery of thermal energy; however, these devices come at a cost due to their ability to cause injury to the overlying skin by virtue of thermal transmission.^{61,62}

The Contour I system created by UltraShape Ltd, was developed by Dr. Ami Glicksman, formerly of the Department of Plastic Surgery & Burns at Sheba Medical Center. This device aims to refine previously developed ultrasound-assisted liposuction by delivering focused ultrasound waves in the form of mechanical energy.⁶³ This device was CE marked in 2005 and was approved by the FDA in 2016.^{64,65} It is composed of a system console that controls its performance; ultrasonic transducer that transmits hemispheric energy and includes acoustic contact feedback; and real-time video tracking and guidance system to ensure appropriately targeted ultrasonic delivery (→Fig. 9).⁶⁶ This particular geometric ultrasound distribution facilitates focused energy emission within the subcutaneous fat layers deep to the skin obviating any significant skin damage.^{61,63}

The Contour I device has been shown to be both safe and effective.^{61–63,66,67} In their preclinical study, Brown et al ascertained that the device delivered focused energy in the form of cavitation followed by mechanical energy and established a high safety profile with no damage observed to adjacent neurovascular structures or connective tissue.⁶³ Wilkerson et al reported that there was a significant decrease in both fat thickness (19.23% reduction at 16 weeks) measured by ultrasound and thigh circumference (2.8 cm reduction at 16 weeks) following three biweekly treat-



Fig. 9 The UltraShape device for noninvasive body contouring, UltraShape.

ments.⁶⁷ Moreno-Moraga et al also demonstrated a significant reduction in fat thickness and body circumference (e.g., abdomen, thighs, flanks, breasts) with no adverse events observed.⁶²

Injectable Fillers

Crystallys, Luminera Derm, Lod, Israel

Injectable fillers have become more frequently employed for facial rejuvenation. They are utilized to manage volume loss, wrinkles, and contour deformities—all common manifestations that are associated with the aging skin. The most common injectable fillers contain either hyaluronic acid, calcium hydroxyapatite (CaHA), or a combination of the two.^{68–70} CaHA is a biodegradable filler that consists of calcium hydroxyapatite microspheres equally spaced apart and suspended in a soluble carrier gel.⁶⁸ Upon injection, the filler immediately provides a volumizing effect. Subsequently, the surrounding gel is absorbed and the CaHA microspheres then function to promote neo-collagenesis (type I collage replacement), stimulate elastin, and support angiogenesis.⁶⁹ All of these effects serve to strengthen and remodel the extracellular matrix, which consequently enhances functional and structural support and promotes a more youthful appearance.^{69,71,72} Crystallys, developed by Luminera Derm Ltd. (acquired by Allergan Aesthetics in 2020), is one such biodegradable CaHA filler designed to restore facial volume and correct natural facial contour deformities (→Fig. 10). Crystallys is CE-marked and produced under strict ISO9001 and ISO13485 conditions.

Though there is a paucity of data in the literature assessing the clinical efficacy of Crystallys,⁷³ numerous studies have reported on the efficacy and safety profile of other CaHA injectable fillers.^{69,74–76} Boen et al reported that CaHA reduced the degree of jaw wrinkling and skin drooping utilizing a 4-point Jawline Scale with no major complications observed over a 3-month period.⁷⁴ Bass et al demonstrated long-term improvements following injection of CaHA (Radiesse) with no adverse events observed 3 years postinjection.⁷⁵ CaHA has also been FDA approved for hand rejuvenation with respectable outcomes as well. Utilizing the Merz Hand Grading Scale, one study established clinical improvement in all 20 patients who underwent dorsal hand rejuvenation with CaHA.⁷⁶

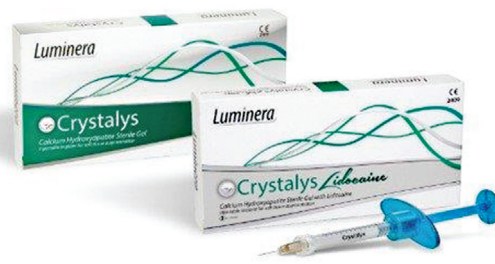

Fig. 10 The Crystallys injectable calcium hydroxyapatite-based dermal filler, Luminera Derm.



Fig. 11 The Sharplan CO₂ surgical laser system.

Lasers and Ablative Solutions

Lumenis Aesthetics, Yokneam, Israel

In the 50 years since the development of the Sharplan CO₂ Laser (►Fig. 11), which served as the first commercially available lightweight CO₂ laser device still utilized today, several other novel laser devices have been introduced by innovators in Israel.⁶ Intense pulsed light (IPL) and radio frequency technologies have been used for facial rejuvenation to manage the aging skin, scars, and skin hyper/hypopigmentation. Because of the noninvasive nature of the treatment, it has gained popularity as a treatment modality.^{77,78}

Lumenis Ltd. has manufactured an IPL to manage a variety of medical dermatological conditions with demonstrable success. Knight treated 10 facial acne vulgaris patients using the Lumenis's IPL system over five treatments separated by 1 to 2 weeks with significant reduction in lesions, improvement in skin texture, and patient-reported satisfaction with results after 4 weeks follow-up.⁷⁸ Hultman et al established that patients on average were highly satisfied and demonstrated a perceived efficacy of 4.5 and 4.4 on a 5-point Likert scale, respectively.⁷⁹ Another device termed MP-22 (Lumenis Ltd.) consists of both an IPL system and an ND:YAG module. Ullmann et al used the MP-22 device to treat several benign lesions (e.g., lentigo and vascular lesions) with 93% of participants reporting satisfaction and no major adverse events observed.⁸⁰

Radio frequency treatment can also be utilized for managing the aging skin.⁸¹ Radio frequency devices function by penetrating the skin with microneedles that cause partial destruction to the underlying epidermis and dermis. In turn, the affected skin undergoes wound healing via neocollagenesis, elastin production, glycosaminoglycan formation,

and neovascularization.^{77,82,83} These phenomena ultimately lead to skin rejuvenation. VoluDerm (Lumenis Ltd.) is a fractional radio frequency device designed for noninvasive treatment of dermatological conditions. In their prospective trial, Kauvar and Gershonowitz showed improvement in skin texture and wrinkles with no major complications noted following six treatments of VoluDerm.⁷⁷

Syneron Candela Ltd., Yokneam, Israel

Similar to Lumenis Ltd., Syneron Candela Ltd. (Israel) has developed numerous radio frequency devices for treating the aging skin and other dermatological conditions such as acne and scars. Ablative and nonablative modalities each demonstrate their own unique set of drawbacks that radio frequency technologies attempt to address. Particularly, radio frequency devices demonstrate improved outcomes while also minimizing damage to the underlying penetrated skin.^{84–86}

Syneron Candela Ltd. radio frequency devices have been used to manage numerous dermatological etiologies with demonstrated good outcomes (►Fig. 12).^{84,85,87,88} Acne vulgaris is a dermatological condition that affects roughly 85% of all Americans under 24 years of age; consequently, the development of innovative treatments to combat this condition is needed.^{88,89} Kaminaka et al reported significantly fewer acne lesions and enhanced quality of life for patients treated with eMatrix (Syneron Candela Ltd.), a bipolar fractional radio frequency system.⁸⁷ Using a combined pulsed light and radio frequency device, Aurora AC (Syneron Ltd.), Prieto et al demonstrated a 47% reduction ($p < 0.05$) in acne lesions following eight treatments in 32 patients with no major adverse events reported.⁸⁸ Facial scars are also a frequent complication of severe acne. Verner showed considerable improvement in acne scars following treatment with the eTwo system (Syneron Candela Ltd.), another bipolar fractional radio frequency technology.⁸⁴

Syneron Candela Ltd. radio frequency technologies have also established success for facial rejuvenation.^{90,91} Sadick et al reported overall skin improvement in 75.3% of patients with demonstrable improvement in wrinkles, skin laxity, and pore size appearance.⁹⁰ In Fitzpatrick skin types V–VI, Man and Goldberg also demonstrated significant improvement in wrinkles, texture, and fine lines with no complications observed using the eMatrix device.⁹¹

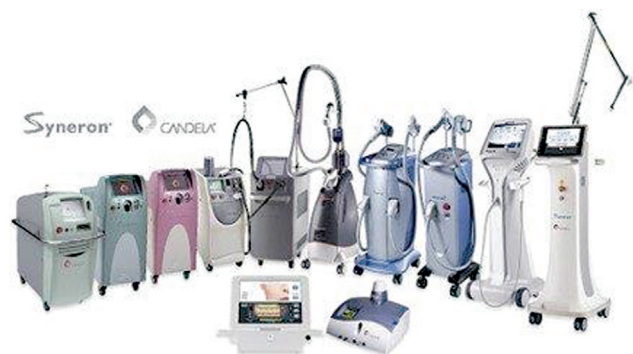

Fig. 12 Syneron Medical portfolio of products.




Fig. 13 The CryoShape cryoprobe for intralesional treatment of keloids and scars, Life by Ice.

Hypertrophic and Keloid Scars

CryoShape, Life By Ice Ltd., Haifa, Israel

Hypertrophic scars and keloids result from an abnormal wound healing process and can be both physically and psychologically debilitating for the patient. These scars are frequently conspicuous, and patients can present with symptoms including pain and pruritus.^{92,93} Management of these scars can be difficult given the high recurrence rates and potential for additional growth.^{94,95} Contact and spray cryotherapy have been more traditionally used for treatment; however, by virtue of their superficial approach, these techniques are associated with high recurrence rates, hypopigmentation of the epidermis, and no significant impact to the deeper dermal layers.⁹⁵ Intralesional cryotherapy, originally described by Weshahy and later revised and incorporated into the treatment of keloids by Zouboulis and Gupta, attempts to resolve these shortcomings.^{96–98}

CryoShape (Life by Ice Ltd.) is an intralesional cryoprobe that was invented by Dr. Yaron Har-Shai, Director of the Department of Plastic Surgery at Carmel and Linn Medical Centers and President of the International Society of Cryosurgery. It is composed of a double-lumen, uninsulated needle with a sharp sealed tip (→ **Fig. 13**).⁹⁴ The quality of the cryoprobe allows for relative ease in piercing the tougher scar tissue. Liquid nitrogen is passed through the needle where it is released within the center of the scar and impacts the surrounding tissue with a 5 mm extension from the needle tip.⁹³ This results in direct damage to the keloid cells and injury to the surrounding vascular structures, while leaving the epidermis relatively unharmed.^{95,99}

Earlier studies have demonstrated the effectiveness of CryoShape in treating hypertrophic scars and keloids.^{92–95,99} In their original report, Har-Shai et al reported an average of 51.4% reduction in scar volume with significant reduction in pain and no evidence of recurrence or adverse events.⁹⁴ In a follow-up study, they also reported a significant reduction in patient concern and perceived deformity of their scars.⁹² However, these studies were composed of a largely Caucasian population with small study sample sizes.^{92,94,99} Arguably, darker-skinned individuals are more likely to be impacted by intralesional cryotherapy. Other studies have also demonstrated the relative effectiveness of intralesional cryotherapy on this population. It appears that, while hypopigmentation is a known complication, this phenomenon

may be a temporary one, with reported repigmentation in 69 to 100% of affected individuals.^{95,100,101}

Conclusion

Numerous innovations within the field of plastic surgery have been developed in Israel over the last few decades. These novel therapies have been used within a variety of aesthetic and reconstructive settings from microsurgery to body contouring and intralesional cryotherapy. The combination of the highly evolving and innovative field of plastic surgery and the highly motivated and passionate leaders in the field makes the future of this specialty bright. With continued advancements and an expanding armamentarium of novel products and techniques, we trust that the next generation of Israeli plastic surgeons and entrepreneurs will take up the mantle of innovation and excellence to further ease, individualize, and optimize patient care in Israel and worldwide.

Conflict of interest

D.A-E. is co-founder and medical director of Lydus Medical; L.H-S. is the son of the founder of Life by Ice Ltd.

References

- 1 Haour G. Israel, a powerhouse for networked entrepreneurship. *Int J Entrep Innov Manag* 2005;5(1–2):39–48
- 2 Beyar R, Zeevi B, Rechavi G. Israel: a start-up life science nation. *Lancet* 2017;389(10088):2563–2569
- 3 Senor D, Singer S. *Start-up Nation: The Story of Israel's Economic Miracle*. 1st edition. New York and Boston: Twelve; 2009
- 4 Trajtenberg M. Innovation in Israel 1968–1997: a comparative analysis using patent data. *Res Policy* 2001;30(03):363–389
- 5 Yeheskel O, Shenkar O, Fiegenbaum A, Cohen E. Cooperative wealth creation: strategic alliances in Israeli Medical-Technology Ventures [and Executive Commentary] on *JSTOR. Acad Manage Exec* 2001;15(01):16–24
- 6 Kaplan I. The CO2 surgical laser. *Photomed Laser Surg* 2010;28(06):847–848
- 7 Powell LE, Andersen ES, Nigro LC, Pozez AL, Shah PA. Breast implants: a historical review with implications for diagnosis and modern surgical planning. *Ann Plast Surg* 2021;87(02):211–221
- 8 Orel GY, Noam C, Jacky GY. Five-year safety and satisfaction with the lightweight breast implant. *Aesthet Surg J* 2022;42(03):261–272
- 9 Govrin-Yehudain J, Dvir H, Preise D, Govrin-Yehudain O, Govreen-Segal D. Lightweight breast implants: a novel solution

- for breast augmentation and reconstruction mammoplasty. *Aesthet Surg J* 2015;35(08):965–971
- 10 Govrin-Yehudain O, Matanis Y, Govrin-Yehudain J. Reduced pain and accelerated recovery following primary breast augmentation with lightweight breast implants. *Aesthet Surg J* 2018;38(10):1092–1096
 - 11 Govrin-Yehudain O, Govrin-Yehudain Y. Lightweight implants for breast augmentation and breast reconstruction surgery - an easy solution to a weighty problem. *Harefuah* 2020;159(08):600–606
 - 12 de Bruijn HP, Johannes S. Mastopexy with 3D preshaped mesh for long-term results: development of the internal bra system. *Aesthetic Plast Surg* 2008;32(05):757–765
 - 13 Farage MA, Miller KW, Elsner P, Maibach HI. Characteristics of the aging skin. *Adv Wound Care (New Rochelle)* 2013;2(01):5–10
 - 14 Duarte Junior G, Duarte FC, Cervantes A. Mastopexy with an implant and the making of a horizontal flap of the upper pedicle, simulating an internal bra. *Aesthetic Plast Surg* 2022;46(01):11–21
 - 15 Atiyeh B, Ghieh F, Chahine F, Oneisi A. Ptosis and bottoming out following mastopexy and reduction mammoplasty. Is synthetic mesh internal breast support the solution? A systematic review of the literature. *Aesthetic Plast Surg* 2022;46(01):25–34
 - 16 van Deventer PV, Graewe FR, Würinger E. Improving the longevity and results of mastopexy and breast reduction procedures: reconstructing an internal breast support system with biocompatible mesh to replace the supporting function of the ligamentous suspension. *Aesthetic Plast Surg* 2012;36(03):578–589
 - 17 Maruccia M, Fatigato G, Elia R, et al. Microvascular coupler device versus hand-sewn venous anastomosis: a systematic review of the literature and data meta-analysis. *Microsurgery* 2020;40(05):608–617
 - 18 Grewal AS, Erovic B, Strumas N, Enepekides DJ, Higgins KM. The utility of the microvascular anastomotic coupler in free tissue transfer. *Can J Plast Surg* 2012;20(02):98–102
 - 19 Gundale AR, Berkovic YJ, Entezami P, Nathan CO, Chang BA. Systematic review of microvascular coupling devices for arterial anastomoses in free tissue transfer. *Laryngoscope Invest Otolaryngol* 2020;5(04):683–688
 - 20 Guo Z, Cui W, Hu M, et al. Comparison of hand-sewn versus modified coupled arterial anastomoses in head and neck reconstruction: a single operator's experience. *Int J Oral Maxillofac Surg* 2020;49(09):1162–1168
 - 21 Arora R, Mishra KS, Bhoje HT, Dewan AK, Singh RK, Naalla R. Mechanical anastomotic coupling device versus hand-sewn venous anastomosis in head and neck reconstruction—an analysis of 1694 venous anastomoses. *Indian J Plast Surg* 2021;54(02):118–123
 - 22 Head LK, McKay DR. Economic comparison of hand-sutured and coupler-assisted microvascular anastomoses. *J Reconstr Microsurg* 2018;34(01):71–76
 - 23 Hirshowitz B, Lindenbaum E, Har-Shai Y. A skin-stretching device for the harnessing of the viscoelastic properties of skin. *Plast Reconstr Surg* 1993;92(02):260–270
 - 24 Narayanan K, Futrell JW, Bentz M, Hurwitz D. Comparative clinical study of the sure-closure device with conventional wound closure techniques. *Ann Plast Surg* 1995;35(05):485–491
 - 25 Armstrong DG, Sorensen JC, Bushman TR. Exploiting the viscoelastic properties of pedal skin with the Sure Closure skin stretching device. *J Foot Ankle Surg* 1995;34(03):247–253
 - 26 Caruso DM, King TJ, Tsujimura RB, Weiland DE, Schiller WR. Primary closure of fasciotomy incisions with a skin-stretching device in patients with burn and trauma. *J Burn Care Rehabil* 1997;18(02):125–132
 - 27 Melis P, Bos KE, Horenblas S. Primary skin closure of a large groin defect after inguinal lymphadenectomy for penile cancer using a skin stretching device. *J Urol* 1998;159(01):185–187
 - 28 Braun TL, Hamilton KL, Monson LA, Buchanan EP, Hollier LH Jr. Tissue expansion in children. *Semin Plast Surg* 2016;30(04):155–161
 - 29 Stough DB, Spencer DM, Schauder CS. New devices for scalp reduction. Intraoperative and prolonged scalp extension. *Dermatol Surg* 1995;21(09):777–780
 - 30 Hussmann J, Kucan JO, Zamboni WA. Elevated compartmental pressures after closure of a forearm burn wound with a skin-stretching device. *Burns* 1997;23(02):154–156
 - 31 Futran ND. Closure of the fibula free flap donor site with the Sure-Closure skin-stretching device. *Laryngoscope* 1996;106(12 Pt 1):1487–1490
 - 32 Barnea Y, Gur E, Amir A, et al. Delayed primary closure of fasciotomy wounds with Wisebands, a skin- and soft tissue-stretch device. *Injury* 2006;37(06):561–566
 - 33 Barnea Y, Gur E, Amir A, et al. Our experience with Wisebands: a new skin and soft-tissue stretch device. *Plast Reconstr Surg* 2004;113(03):862–869, discussion 870–871
 - 34 Drossard G, Potier B, Steff M, Rousseau P, Payement G, Darsonval V. [Optimized negative pressure therapy. Case report]. *Ann Chir Plast Esthet* 2009;54(02):165–170
 - 35 Topaz M, Carmel NN, Silberman A, Li MS, Li YZ. The TopClosure® 3S System, for skin stretching and a secure wound closure. *Eur J Plast Surg* 2012;35(07):533–543
 - 36 Topaz M, Carmel NN, Topaz G, Li M, Li YZ. Stress-relaxation and tension relief system for immediate primary closure of large and huge soft tissue defects: an old-new concept: new concept for direct closure of large defects. *Medicine (Baltimore)* 2014;93(28):e234. Doi: 10.1097/MD.0000000000000234
 - 37 Zhu Z, Tong Y, Wu T, Zhao Y, Yu M, Topaz M. TopClosure® tension-relief system for immediate primary abdominal defect repair in an adult patient with bladder exstrophy. *J Int Med Res* 2020;48(01):300060519891266. Doi: 10.1177/0300060519891266
 - 38 Topaz M, Ashkenazi I, Barzel O, et al. Minimizing treatment complexity of combat-related soft tissue injuries using a dedicated tension relief system and negative pressure therapy augmented by high-dose *in situ* antibiotic therapy and oxygen delivery: a retrospective study. *Burns Trauma* 2021;9:b007. Doi: 10.1093/BURNST/TKAB007
 - 39 Topaz M. Improved wound management by regulated negative pressure-assisted wound therapy and regulated, oxygen-enriched negative pressure-assisted wound therapy through basic science research and clinical assessment. *Indian J Plast Surg* 2012;45(02):291–301
 - 40 Freund MR, Reissman P, Spira RM, Topaz M. Innovative approach to open abdomen: converting an enteroatmospheric fistula into an easily manageable stoma. *BMJ Case Rep* 2020;13(08):e234207. Doi: 10.1136/BCR-2019-234207
 - 41 Choke A, Goh TL, Kang GCW, Tan BK. Delayed primary closure of extensive wounds using the TopClosure system and topical negative pressure therapy. *J Plast Reconstr Aesthet Surg* 2017;70(07):968–970
 - 42 Lin DZ, Kao YC, Chen C, Wang HJ, Chiu WK. Negative pressure wound therapy for burn patients: a meta-analysis and systematic review. *Int Wound J* 2021;18(01):112–123
 - 43 Li J, Shi JB, Hong P, et al. Combined treatment with vacuum sealing drainage, TopClosure device, and Ilizarov technique for traumatic hemipelvectomy: a rare case report of successful repairing of large-size soft tissue defects. *Medicine (Baltimore)* 2019;98(04):e14205. Doi: 10.1097/MD.00000000000014205
 - 44 Liu Y, Tang N, Cao K, et al. Negative-pressure wound therapy promotes wound healing by enhancing angiogenesis through suppression of NLRX1 via miR-195 upregulation. *Int J Low Extrem Wounds* 2018;17(03):144–150
 - 45 Solomonov E, Khalifa M, Rozentsvaig V, Koifman I, Biswas S, Topaz M. Case report: delayed primary wound closure after extensive abdominal wall resection for infection and malignancy

- using TopClosure®. *Front Surg* 2021;8:684513. Doi: 10.3389/FSURG.2021.684513
- 46 Zhu Z, Yang X, Zhao Y, Fan H, Yu M, Topaz M. Early surgical management of large scalp infantile hemangioma using the TopClosure® Tension-Relief System. *Medicine (Baltimore)* 2015;94(47):e2128. Doi: 10.1097/MD.0000000000002128
 - 47 Topaz M, Gurevich M, Ashkenazi I. Simplified management of a giant forehead congenital nevus allows for early reconstruction. *BMJ Case Rep* 2020;13(07):e234164. Doi: 10.1136/BCR-2019-234164
 - 48 Smolle C, Cambiaso-Daniel J, Forbes AA, et al. Recent trends in burn epidemiology worldwide: a systematic review. *Burns* 2017;43(02):249–257
 - 49 Loo YL, Goh BKL, Jeffery S. An overview of the use of bromelain-based enzymatic debridement (NexoBrid®) in deep partial and full thickness burns: appraising the evidence. *J Burn Care Res* 2018;39(06):932–938
 - 50 Church D, Elsayed S, Reid O, Winston B, Lindsay R. Burn wound infections. *Clin Microbiol Rev* 2006;19(02):403–434
 - 51 Appelgren P, Björnhagen V, Bragderyd K, Jonsson CE, Ransjö U A prospective study of infections in burn patients. *Burns* 2002;28(01):39–46
 - 52 Rosenberg L, Krieger Y, Bogdanov-Berezovski A, Silberstein E, Shoham Y, Singer AJ. A novel rapid and selective enzymatic debridement agent for burn wound management: a multi-center RCT. *Burns* 2014;40(03):466–474
 - 53 Orgill DP. Excision and skin grafting of thermal burns. *N Engl J Med* 2009;360(09):893–901
 - 54 Arkoulis N, Mabvuure NT, Smith A, Barnes DE. Early experiences using bromelain-based enzymatic debridement in a tertiary burns centre in the United Kingdom: a retrospective case series review. *J Plast Reconstr Aesthet Surg* 2021;74(06):1402–1407
 - 55 Hirche C, Kreken Almeland S, Dheansa B, et al. Eschar removal by bromelain based enzymatic debridement (NexoBrid®) in burns: European consensus guidelines update. *Burns* 2020;46(04):782–796
 - 56 Di Castri A, Quarta L, Mataro I, et al. The entity of thermal-crush-avulsion hand injury (hot-press roller burns) treated with fast acting debriding enzymes (nexobrid): literature review and report of first case. *Ann Burns Fire Disasters* 2018;31(01):31–34
 - 57 Dadras M, Wagner JM, Wallner C, et al. Enzymatic debridement of hands with deep burns: a single center experience in the treatment of 52 hands. *J Plast Surg Hand Surg* 2020;54(04):220–224
 - 58 Bowers C, Randawa A, Sloan B, Anwar U, Phipps A, Muthayya P. Enzymatic debridement in critically injured burn patients - our experience in the intensive care setting and during burn resuscitation. *Burns* 2021;S0305-4179(21)00210-2. Doi: 10.1016/J.BURNS.2021.07.023
 - 59 Schulz A, Ribitsch B, Fuchs PC, Lipensky A, Schiefer JL. Treatment of genital burn injuries: traditional procedures and new techniques. *Adv Skin Wound Care* 2018;31(07):314–321
 - 60 American Society of Plastic Surgeons. Plastic Surgery Statistics Report 2020 <https://www.plasticsurgery.org/documents/News/Statistics/2020/plastic-surgery-statistics-full-report-2020.pdf>. Accessed April 6, 2022
 - 61 Teitelbaum SA, Burns JL, Kubota J, et al. Noninvasive body contouring by focused ultrasound: safety and efficacy of the Contour I device in a multicenter, controlled, clinical study. *Plast Reconstr Surg* 2007;120(03):779–789
 - 62 Moreno-Moraga J, Valero-Altés T, Riquelme AM, Isarria-Marcosy MI, de la Torre JR. Body contouring by non-invasive transdermal focused ultrasound. *Lasers Surg Med* 2007;39(04):315–323
 - 63 Brown SA, Greenbaum L, Shtukmaster S, Zadok Y, Ben-Ezra S, Kushkuley L. Characterization of nonthermal focused ultrasound for noninvasive selective fat cell disruption (lysis): technical and preclinical assessment. *Plast Reconstr Surg* 2009;124(01):92–101
 - 64 Coleman WP III, Coleman W IV, Weiss RA, Kenkel JM, Ad-El DD, Amir R. A multicenter controlled study to evaluate multiple treatments with nonthermal focused ultrasound for noninvasive fat reduction. *Dermatol Surg* 2017;43(01):50–57
 - 65 Hotta TA. Nonsurgical body contouring with focused ultrasound. *Plast Surg Nurs* 2010;30(02):77–82, quiz 83–84
 - 66 Ascher B. Safety and efficacy of UltraShape Contour I treatments to improve the appearance of body contours: multiple treatments in shorter intervals. *Aesthet Surg J* 2010;30(02):217–224
 - 67 Wilkerson EC, Bloom BS, Goldberg DJ. Clinical study to evaluate the performance of a noninvasive focused ultrasound device for thigh fat and circumference reduction compared to control. *J Cosmet Dermatol* 2018;17(02):157–161
 - 68 Chang JW, Koo WY, Kim EK, Lee SW, Lee JH. Facial rejuvenation using a mixture of calcium hydroxylapatite filler and hyaluronic acid filler. *J Craniofac Surg* 2020;31(01):e18–e21
 - 69 Yutskovskaya Y, Kogan E, Leshunov E. A randomized, split-face, histomorphologic study comparing a volumetric calcium hydroxylapatite and a hyaluronic acid-based dermal filler. *J Drugs Dermatol* 2014;13(09):1047–1052 <https://pubmed.ncbi.nlm.nih.gov/25226004/> Accessed April 6, 2022
 - 70 Eviatar J, Lo C, Kirsztot J. Radiesse: Advanced techniques and applications for a unique and versatile implant. *Plast Reconstr Surg* 2015;136(5, Suppl):164–170
 - 71 Quan T, Fisher GJ. Role of age-associated alterations of the dermal extracellular matrix microenvironment in human skin aging: a mini-review. *Gerontology* 2015;61(05):427–434
 - 72 Cole MA, Quan T, Voorhees JJ, Fisher GJ. Extracellular matrix regulation of fibroblast function: redefining our perspective on skin aging. *J Cell Commun Signal* 2018;12(01):35–43
 - 73 Segal T, Schwartz A, Konfino K. Post marketing study of safety and efficacy of Crystallys, a calcium hydroxylapatite based filler for facial soft tissue augmentation. *Cosmet Med* 2014;1(16):22–27 <https://www.luminera.com/wp-content/uploads/2019/02/Post-market-ing-study-Crystallys.pdf>
 - 74 Boen M, Alhaddad M, Goldman MP, Kollipara R, Hoss E, Wu DCA. A randomized, evaluator-blind, split-face study evaluating the safety and efficacy of calcium hydroxylapatite for jawline augmentation. *Dermatol Surg* 2022;48(01):76–81
 - 75 Bass LS, Smith S, Busso M, McClaren M. Calcium hydroxylapatite (Radiesse) for treatment of nasolabial folds: long-term safety and efficacy results. *Aesthet Surg J* 2010;30(02):235–238
 - 76 Bertucci V, Solish N, Wong M, Howell M. Evaluation of the Merz Hand Grading Scale after calcium hydroxylapatite hand treatment. *Dermatol Surg* 2015;41(Suppl 1):S389–S396
 - 77 Kauvar ANB, Gershonowitz A. Clinical and histologic evaluation of a fractional radiofrequency treatment of wrinkles and skin texture with novel 1-mm long ultra-thin electrode pins. *Lasers Surg Med* 2022;54(01):54–61
 - 78 Knight JM. Combined 400-600nm and 800-1200nm intense pulsed phototherapy of facial acne vulgaris. *J Drugs Dermatol* 2019;18(11):1116–1122 <https://pubmed.ncbi.nlm.nih.gov/31741354/> Accessed April 6, 2022
 - 79 Hultman CS, Friedstat JS, Edkins RE. Efficacy of intense pulsed light for the treatment of burn scar dyschromias: a pilot study to assess patient satisfaction, safety, and willingness to pay. *Ann Plast Surg* 2015;74(Suppl 4):S204–S208
 - 80 Ullmann Y, Elkhatib R, Fodor L. The aesthetic applications of intense pulsed light using the Lumenis M-22 device. *Laser Ther* 2011;20(01):23–28
 - 81 Hruza G, Taub AF, Collier SL, Mulholland SR. Skin rejuvenation and wrinkle reduction using a fractional radiofrequency system. *J Drugs Dermatol* 2009;8(03):259–265 <https://pubmed.ncbi.nlm.nih.gov/19271373/> Accessed April 6, 2022
 - 82 Hantash BM, Ubeid AA, Chang H, Kafi R, Renton B. Bipolar fractional radiofrequency treatment induces neocollagenesis and neocollagenesis. *Lasers Surg Med* 2009;41(01):1–9

- 83 Zheng Z, Goo B, Kim DY, Kang JS, Cho SB. Histometric analysis of skin-radiofrequency interaction using a fractionated microneedle delivery system. *Dermatol Surg* 2014;40(02):134–141
- 84 Verner I. Clinical evaluation of the efficacy and safety of fractional bipolar radiofrequency for the treatment of moderate to severe acne scars. *Dermatol Ther (Heidelberg)* 2016;29(01):24–27
- 85 Kaminaka C, Furukawa F, Yamamoto Y. Long-term clinical and histological effects of a bipolar fractional radiofrequency system in the treatment of facial atrophic acne scars and acne vulgaris in Japanese patients: a series of eight cases. *Photomed Laser Surg* 2016;34(12):657–660
- 86 Ong MWS, Bashir SJ. Fractional laser resurfacing for acne scars: a review. *Br J Dermatol* 2012;166(06):1160–1169
- 87 Kaminaka C, Uede M, Matsunaka H, Furukawa F, Yamamoto Y. Clinical studies of the treatment of facial atrophic acne scars and acne with a bipolar fractional radiofrequency system. *J Dermatol* 2015;42(06):580–587
- 88 Prieto VG, Zhang PS, Sadick NS. Evaluation of pulsed light and radiofrequency combined for the treatment of acne vulgaris with histologic analysis of facial skin biopsies. *J Cosmet Laser Ther* 2005;7(02):63–68
- 89 White GM. Recent findings in the epidemiologic evidence, classification, and subtypes of acne vulgaris. *J Am Acad Dermatol* 1998;39(2 Pt 3):S34–S37
- 90 Sadick NS, Alexiades-Armenakas M, Bitter P Jr, Hruza G, Mulholland RS. Enhanced full-face skin rejuvenation using synchronous intense pulsed optical and conducted bipolar radiofrequency energy (ELOS): introducing selective radiophotothermolysis. *J Drugs Dermatol* 2005;4(02):181–186 <https://pubmed.ncbi.nlm.nih.gov/15776775/> Accessed April 6, 2022
- 91 Man J, Goldberg DJ. Safety and efficacy of fractional bipolar radiofrequency treatment in Fitzpatrick skin types V-VI. *J Cosmet Laser Ther* 2012;14(04):179–183
- 92 Har-Shai Y, Brown W, Labbé D, et al. Intralesional cryosurgery for the treatment of hypertrophic scars and keloids following aesthetic surgery: the results of a prospective observational study. *Int J Low Extrem Wounds* 2008;7(03):169–175
- 93 Defty C, Cubitt JJ, Murison MS. Can intralesional cryotherapy reshape the management of difficult keloid scars? *Scars Burn Heal* 2016;2:2059513116678643. Doi: 10.1177/2059513116678643
- 94 Har-Shai Y, Amar M, Sabo E. Intralesional cryotherapy for enhancing the involution of hypertrophic scars and keloids. *Plast Reconstr Surg* 2003;111(06):1841–1852
- 95 van Leeuwen MCE, van der Wal MBA, Bulstra AJ, et al. Intralesional cryotherapy for treatment of keloid scars: a prospective study. *Plast Reconstr Surg* 2015;135(02):580–589
- 96 Weshahy AH. Intralesional cryosurgery. A new technique using cryoneedles. *J Dermatol Surg Oncol* 1993;19(02):123–126
- 97 Zouboulis CC. Principles of cutaneous cryosurgery: an update. *Dermatology* 1999;198(02):111–117
- 98 Gupta S, Kumar B. Intralesional cryosurgery using lumbar puncture and/or hypodermic needles for large, bulky, recalcitrant keloids. *Int J Dermatol* 2001;40(05):349–353
- 99 Har-Shai Y, Sabo E, Rohde E, Hyams M, Assaf C, Zouboulis CC. Intralesional cryosurgery enhances the involution of recalcitrant auricular keloids: a new clinical approach supported by experimental studies. *Wound Repair Regen* 2006;14(01):18–27
- 100 O'Boyle CP, Shayan-Arani H, Hamada MW. Intralesional cryotherapy for hypertrophic scars and keloids: a review. *Scars Burn Heal* 2017;3:2059513117702162. Doi: 10.1177/2059513117702162
- 101 Chopinaud M, Pham AD, Labbé D, et al. Intralesional cryosurgery to treat keloid scars: results from a retrospective study. *Dermatology* 2014;229(03):263–270