



# A Systematic Review of Staging and Flap Choice in Gender-Affirming Phalloplasty

Catherine A. Wu, BS<sup>1</sup> Divya Jolly, MS<sup>2</sup> Elizabeth R. Boskey, PhD, MPH<sup>2,3,4</sup> Oren Ganor, MD<sup>2,3</sup>

<sup>1</sup>Harvard Medical School, Boston, Massachusetts

<sup>2</sup>Department of Plastic and Oral Surgery, Center for Gender Surgery, Boston Children's Hospital, Boston, Massachusetts

<sup>3</sup>Department of Surgery, Harvard Medical School, Boston, Massachusetts

<sup>4</sup>Department of Social and Behavioral Sciences, Harvard T.H. Chan School of Public Health, Boston, Massachusetts

**Address for correspondence** Divya Jolly, MS, Center for Gender Surgery, Department of Plastic and Oral Surgery, Boston Children's Hospital, 300 Longwood Ave, Boston, MA 02115 (e-mail: dee.jolly@childrens.harvard.edu).

J Reconstr Microsurg Open 2022;7:e13–e26.

## Abstract

**Background** As phalloplasty becomes more routinely performed, there is a growing need for an evidence base to guide surgical decision-making. Recent reviews have suggested that flap type and number of stages may affect the high rates of urethral complications seen with phalloplasty, but no rigorous comparison of both has been performed.

**Methods** A systematic review was conducted across PubMed, Google Scholar, and ScienceDirect (PROSPERO #158722). All included studies examined urethral complications following gender-affirming phalloplasty in transgender men. Data were extracted in line with Preferred Reporting Items for Systematic Reviews and Meta-Analyses guidelines. Quality of evidence was assessed using the Grading of Recommendations, Assessment, Development and Evaluations system. All searches, extractions, and grading were completed by two authors.

**Results** Twenty-five studies were included with a total of 1,674 patients. Identified flap types included radial forearm, anterolateral thigh, abdominal, and fibular flaps. Surgical techniques varied widely within the flap types. Number of stages ranged from one to four. Stricture and fistula were the most frequently reported complications with considerable variation in the reported rates between studies, even within singular flap types. Data extraction indicated serious quality issues with the published literature, with the majority of studies at high risk of bias due to short follow-up times, inconsistent and incomplete reporting of outcomes, and inconsistent reporting of surgical technique.

**Conclusion** To date, there is insufficient data to support a preferred flap type to minimize the urethral complication rates of phalloplasty. Further high-quality literature is required to determine the impact of potential factors affecting complications of gender-affirming phalloplasty. Improved literature quality may be facilitated by a standardized set of reporting guidelines.

## Keywords

- ▶ gender-affirming surgery
- ▶ neophallus
- ▶ urethroplasty
- ▶ transgender man
- ▶ phalloplasty

received  
December 29, 2021

DOI <https://doi.org/10.1055/s-0042-1748884>.  
ISSN 2377-0813.

© 2022. The Author(s).

This is an open access article published by Thieme under the terms of the Creative Commons Attribution-NonDerivative-NonCommercial-License, permitting copying and reproduction so long as the original work is given appropriate credit. Contents may not be used for commercial purposes, or adapted, remixed, transformed or built upon. (<https://creativecommons.org/licenses/by-nc-nd/4.0/>)

Thieme Medical Publishers, Inc., 333 Seventh Avenue, 18th Floor, New York, NY 10001, USA

With recent increases in legal and social acceptance of transgender individuals, and as many as 1 to 1.4 million transgender adults living in the United States,<sup>1,2</sup> there has been a growing demand for gender-affirming medical procedures, including genital affirmation surgeries.<sup>3</sup> Genital affirmation options for transgender men include metoidioplasty and phalloplasty, often with urethral lengthening, scrotoplasty, and testicular implants. The most commonly described option in the literature is phalloplasty performed with the radial forearm flap, but other phalloplasty options include the free or pedicled anterolateral thigh (ALT) flap, the pedicled suprapubic abdominal wall flap, and the fibular free flap.<sup>4</sup> Such procedures can be completed in up to four planned stages, although unplanned surgical interventions are sometimes required during follow-up care.

In recent years, several reviews on masculinizing genital affirmation surgery have described various surgical techniques and examined both outcomes and complication rates associated with these procedures.<sup>4-9</sup> Overall, the rate of urethral complications exceeds 30% for masculinizing genital affirmation surgeries.<sup>8</sup> The most common complications of such procedures are generally related to urethral lengthening (urethroplasty), with urethral strictures and urethrocutaneous fistulae being the most commonly reported complications.<sup>10</sup> Additionally, complete flap loss presents as one of the most concerning complications related to gender-affirming phalloplasty. Some studies have suggested that the high rate of complications may be a result of several different factors, including flap type and number of stages.<sup>11-13</sup> However, rates of reported complications vary widely between studies and procedures, even when examining rates by flap type, making it challenging to identify a single surgical technique as the gold standard for masculinizing gender surgery without additional evidence.<sup>4,8,14</sup> To address this dearth, this systematic review investigates the question: do flap type and number of surgical stages affect complication rates of phalloplasty procedures performed in transgender men?

## Methods

Preferred Reporting Items for Systematic Reviews and Meta-Analyses<sup>15</sup> guidelines were used to develop the protocol for this systematic review, as reported in ►**Fig. 1**. Online database searches were conducted using PubMed, Embase, Web of Science, and Cochrane Central Register of Controlled Trials. Additional hand searches through the journals of *Plastic and Reconstructive Surgery*, *Journal of Sexual Medicine*, and the *International Journal of Transgender Health* (formerly known as the *International Journal of Transgenderism*) were completed. All searches were conducted from inception through February 2019. Searches were conducted in consultation with a research librarian using a combination of the terms “phalloplasty,” “metoidioplasty,” “transgender men,” “gender affirming surgery,” “sex reassignment surgery,” “gender dysphoria,” “female to male,” “genital affirmation,” “urethroplasty,” “urethral lengthening,” and “neophallus.” A full search term strategy is available through the PROSPERO registry in protocol 158722.

Inclusion criteria required articles to be full-text articles about transgender men who have undergone genital affirmation surgery, written in English, and include patient- or physician-reported outcomes. Following the removal of duplicate records, a title and abstract search was performed to include only papers on primary phalloplasty performed on transgender men. A full review of all remaining articles was then completed. Studies were excluded from the final analysis if they did not differentiate between cisgender and transgender men, reported phalloplasty for reasons other than gender affirmation, did not include outcome measurements, reported results of revision procedures, reported metoidioplasty, or were not full-text articles. A full review of all articles was then completed.

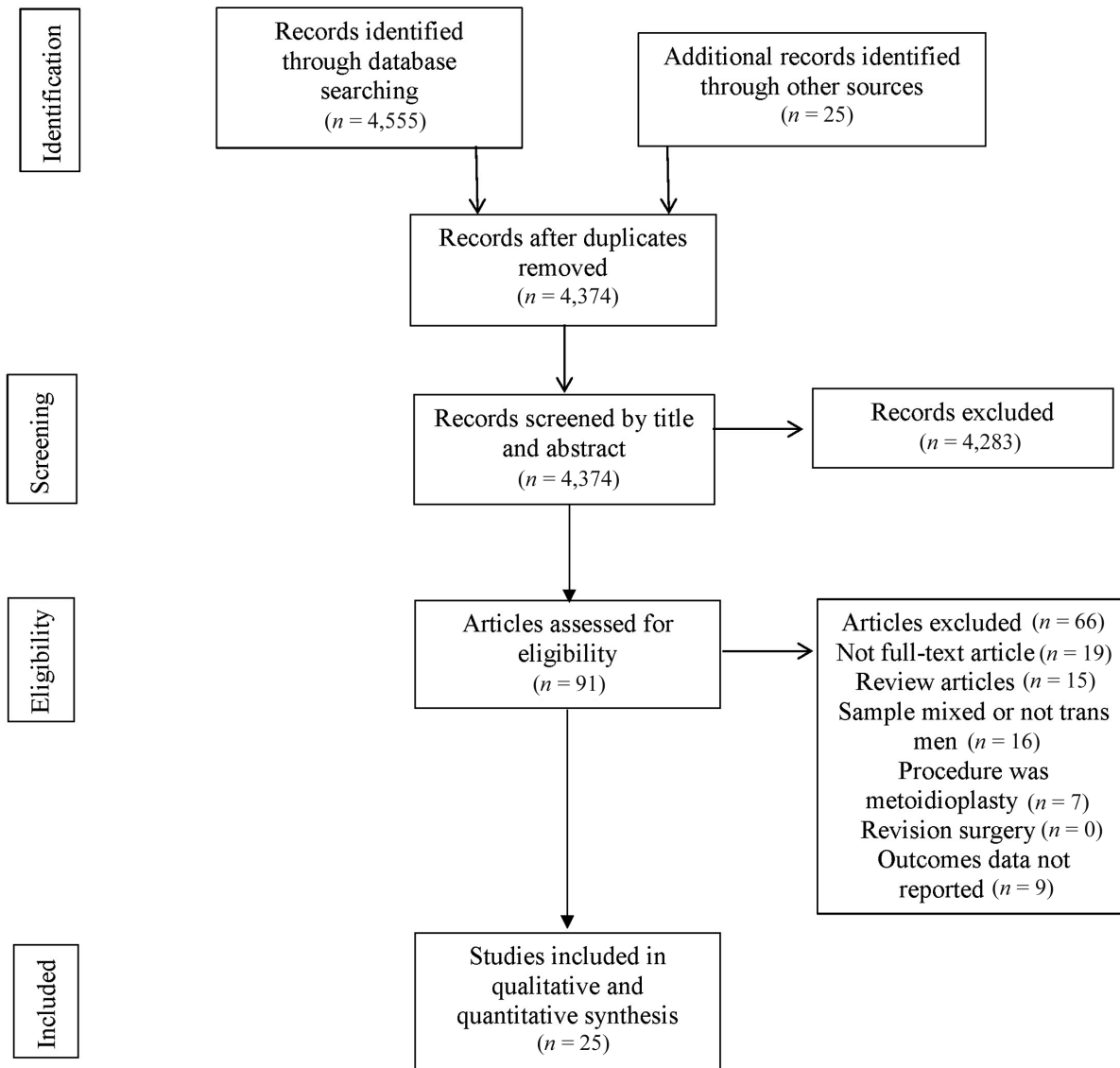
Data were independently extracted regarding sample demographics, sample size, sampling methods, cohort inclusion and exclusion, study type, institutional review board (IRB) approval, surgical flap type, facility type, type of surgeon, surgical stages, urethral reconstruction technique, follow-up care, surgical complications, and surgical restrictions. The total number of patients experiencing each complication was extracted from the article texts and proportions were then calculated using the total sample size. Data were stratified by number of stages and phallus flap type for each study. Each study was also evaluated for its level of evidence using Grading of Recommendations, Assessment, Development and Evaluations (GRADE) guidelines.<sup>16</sup> Bias was assessed through the Murad et al tool for assessing case series as no study contained a control group.<sup>17</sup> Extracted data were tabulated into systematic review tables both quantitatively and qualitatively summarizing the evidence wherever possible. All screening, data extraction, and analyses were completed by a minimum of two authors to prevent bias. Any conflicts following screening and data extraction were resolved through review by a third author.

## Results

Following the removal of duplicate records, our search strategy yielded 4,374 unique articles that were screened for inclusion by the authors. Ninety-one full-text articles were screened following a title and abstract screening. Using the aforementioned inclusion criteria, 25 full-text articles were included for analysis.<sup>13,18-41</sup> A full flow diagram with all screening and exclusion decisions is available in ►**Fig. 1**.

A total of 1,674 transgender men seeking phalloplasty as part of gender affirmation surgery, and who had not had prior metoidioplasty or phalloplasty, were identified across all included studies (►**Table 1**). Ages ranged widely, with reported ages between 19 years old and the 60s (not specified), with most mean ages falling between 27 and 37 years. Follow-up times ranged from 1 to 270 months. The GRADE quality of evidence for all included studies ranged from very low to low. Risk of bias ranged from low to high, with the majority of studies at moderate to high risk of bias. A statement confirming IRB approval was reported in two studies.<sup>13,31</sup>

Reporting of all assessed criteria varied widely across the identified papers. Sample size, patient age, follow-up time,



**Fig. 1** Flow diagram for literature search according to Preferred Reporting Items for Systematic Reviews and Meta-Analyses (PRISMA) guidelines.

flap types, number of stages, and rates of urethral fistulae and strictures were reported across most studies. Parameters that were rarely reported across studies included sample demographics, insurance status of patients, type of facility surgeries were performed in, types and number of surgeons involved, number of procedures per surgical encounter, number of surgical admissions, and restrictions for surgery.

### Surgical Techniques: Flap Choice and Number of Stages

RFF was the most commonly reported flap choice, representing 64% of identified cases<sup>13,22–24,26–28,30–32,35–37,39,40</sup> (► **Table 2**). Other commonly used flap types were ALT,<sup>13,18,30,41</sup> abdominal,<sup>19,21,25,41</sup> and fibular flaps.<sup>20,34,35,39</sup> Less commonly used flap types were free thoracodorsal artery perforator,<sup>29</sup> tensor fasciae latae island,<sup>38</sup> and combinations of flap types.<sup>33</sup> Within the identified flap types, there was substantial variation in flap subtype of the RFF, including the fasciocutaneous,<sup>28</sup> sensate

free,<sup>22,35,39</sup> free radial artery forearm flap,<sup>13,24,27,30–32,36,40</sup> and osteocutaneous free RFF.<sup>23,26,37</sup>

The number of stages varied by flap type. RFFs used anywhere between one and four stages, with the majority of procedures being performed in a single stage<sup>13,26,27,32,36</sup> (► **Table 2**). The majority of ALT phalloplasties, were completed in a single stage,<sup>13,18</sup> but some were performed in two,<sup>41</sup> and others left staging undefined.<sup>30</sup> Phalloplasty with fibular flap was completed in two<sup>20</sup> or three stages,<sup>34,35,39</sup> with a median of three stages. Abdominal phalloplasties were completed in one,<sup>19</sup> two,<sup>19,21,41</sup> or three stages.<sup>25</sup> Procedures that used other flaps or a combination of flaps were either completed in one<sup>33</sup> or three stages.<sup>29,38</sup>

As is standard for masculinizing phalloplasty, all studies reported completing two steps for urethral lengthening: the creation of the pars fixa, or the portion of the urethra between the native urethra and the base of the phallus, and the creation of the pars pendulans which extends throughout the neophallus. The pars fixa, or proximal

**Table 1** Summary of included studies sorted by type of procedure

Authors	Year	Sample size	Age	Follow-up time (mo)	IRB approval statement	Risk of individual bias (Murad et al)
Ascha et al	2018	213	ALT: $36.2 \pm 9.7$ ; RFFF: $36.7 \pm 11.5$	6	Included	Moderate; due to short follow-up time and lack of detail
Bettocchi et al	2005	85	34.4 (19–54)	–	–	High; due to no follow-up times provided
Dabernig et al	2006	5	30 (24–37)	25 (18–30)	–	High; due to small, nonrepresentative samples
Edgerton et al	1984	1	36	30	–	High; due to small, nonrepresentative sample
Fang et al	1999	22	–	–	–	High; due to small samples and no follow-up times provided
Fang et al	1994	56	–	–	–	High; due to small samples and no follow-up times provided
Garaffa et al	2010	115	20–55	26 (1–270)	–	Low
Hage et al	1993	25	33 (21–54)	34 (7–60 +)	–	Moderate; due to small samples
Kim et al	2010	70	34.6 (19–45)	54	–	Moderate; due to lack of comprehensive outcomes information
Krueger et al	2007	253	–	–	–	High; due to no provided follow-up time
Lerliche et al	2008	56	30 (20–44)	110	–	Low
Lin and Chen	2009	1	24	18	–	High; due to small, nonrepresentative sample
Massie et al	2017	224	VC: $37 \pm 11$ ; No VC: $35 \pm 7$	VC: $21.4 \pm 10.3$ ; No VC: $17.0 \pm 8.1$	–	Moderate; due to lack of staging information
Medina et al	2018	6	29 (21–47)	–	Included	High; due to small, nonrepresentative sample
Monstrey et al	2009	287	–	–	–	High; due to no follow-up times provided
Namba et al	2019	15	25–43	6	Included	High; due to small sample and short follow-up time
Papadopoulos et al	2008	32	22.1–51.5	12	–	Moderate; due to small sample
Rohrmann and Jakse	2003	25	33 (23–42)	–	–	High; due to small sample and no follow-up time provided
Salgado et al	2016	15	20s–60s	14.1 (2.5–25.1)	–	Moderate; due to small sample
Santanelli and Scuderi	2000	5	34.5	36–84	–	Moderate; due to small sample
Schaff	2007	66	–	14 (8–28)	–	High; due to lack of sample characteristics and differentiation between outcomes for different pars fixa techniques

**Table 1** (Continued)

Authors	Year	Sample size	Age	Follow-up time (mo)	IRB approval statement	Risk of individual bias (Murad et al)
Schaff and Papadopulos	2009	37	–	14 (9–26)	–	High; due to small sample with no information about how patients were selected
Song et al	2011	19	–	12–120	–	Moderate; due to small sample
van der Sluis et al	2016	19	21–57	35 (3–95)	–	Moderate; due to small sample
Zhang et al	2015	22	27.8 (19–34)	25.4 ± 6	–	Moderate; due to small sample

Abbreviations: ALT, anterolateral thigh; IRB, institutional review board; RFF, radial forearm flap.

urethra, was completed with a variety of different flaps including the anterior vaginal wall,<sup>20,24–26,28,29,31,32,34,37,39</sup> labia minora,<sup>13,25–27,30–33,35–37,40</sup> vaginal flap,<sup>23,33,36,39</sup> vaginal mucosa,<sup>41</sup> bladder,<sup>21</sup> urethral plate,<sup>36</sup> metoidioplasty,<sup>33,35</sup> and vestibular and infundibular skin strips<sup>18–20,22,38,40</sup> (►Table 2). The pars pendulans, or distal urethra, was typically created with the same flap used to create the body of the phallus, but other options included vaginal graft,<sup>31</sup> a full-thickness skin graft from the median forearm,<sup>29</sup> and subcutaneous island flap from the preputial apron.<sup>38</sup> When prelamination of the pars pendulans was performed, it was typically made with vaginal mucosa,<sup>22,23,29,31,35,37,39,41</sup> although usage of buccal mucosa,<sup>37</sup> lower abdominal wall,<sup>40</sup> and split-thickness skin grafts from the thigh<sup>20,31,34,38,39</sup> were also reported. Additionally, some studies reported providing reinforcement at the urethral anastomosis between the pars fixa and pars pendulans during urethral lengthening.<sup>13,19,24,26,30,31,37,40</sup> Such reinforcement was provided by layers of soft tissue,<sup>26</sup> the labia minora,<sup>31</sup> fascioliomatous tissue,<sup>30</sup> the Martius fat pad,<sup>19,24</sup> vascularized bulbospongiosus tissue,<sup>13</sup> the myofascial gracilis flap,<sup>37</sup> or perineal muscle.<sup>40</sup>

### Complications

Urethral stricture and fistula were the most commonly reported complications across studies (►Table 3). Less frequently reported complications included partial and complete flap loss, wound dehiscence, infection, donor-site morbidity, abscess, and venous or arterial thrombosis. Studies also reported on a variety of factors thought to have affected complication rates within their samples beyond flap type and number of stages. Factors hypothesized to reduce urethral stricture and fistula included procedure standardization,<sup>27</sup> experience levels of the surgical team,<sup>27</sup> prelamination of the pars pendulans,<sup>22,31,34</sup> vaginectomy,<sup>30</sup> flap rotations and shaping,<sup>24,26</sup> and reinforcement of the urethral anastomosis between the native urethra and pars fixa and between the pars fixa and pars pendulans.<sup>37,40</sup> Complications and the factors theorized to have impacted them have been qualitatively synthesized in ►Table 3, stratified by phallus flap type and number of stages.

Across all studies, rates of reported fistula formation ranged anywhere from none to 93.8%. Fistula rates for the RFF ranged from 9.5 and 67.9%, with most estimates falling between 15 and 35% (►Table 3). Phalloplasty with the ALT flap reported fistula formation in 10.5 to 20.3% of cases, while ranges of reported fistula rates for abdominal phalloplasty were between none and 93.8% of cases. Fibular flap phalloplasty had the lowest number of reported fistulae, ranging from none to 21.9% of patients.

Urethral strictures were frequently reported across all studies, occurring in anywhere between 0 and 93.8% of phalloplasty procedures completed with transgender men (►Table 3). Average rates of stricture varied widely by study and by flap type utilized. Urethral stricture occurred in 9.5 to 67.9% of RFF, 22.0 to 47.4% of ALT, 0 to 93.8% of abdominal flap, and 14.6 to 40.0% of fibular flap phalloplasties, respectively (►Table 3).

Complete flap loss was less frequently reported as having occurred across studies compared with urethral fistula or stricture, occurring in between 0 and 15.8% of phalloplasties performed (►Table 3). Notably, in contrast to other complications, such as wound dehiscence and partial flap loss, complete flap loss was explicitly mentioned to have not occurred in the majority of included studies where it was included. Similarly to urethral fistula and stricture, rates of complete flap loss varied widely between studies and flap types. Where reported, complete flap loss occurred in between 0 and 10.5% of RFF, 15.8% of ALT patients, between 0 and 4.6% of abdominal flaps, and 0 and 6.3% of fibular phalloplasty patients, respectively.

### Discussion

To our knowledge, this is the first systematic review to assess whether flap choice and number of stages affect complication rates of masculinizing phalloplasty in transgender men. Unfortunately, the low to very low quality of evidence and moderate to high risk of bias of the included studies raises concerns that the extracted data may not reflect true population values, which makes it challenging to draw firm

**Table 2** Surgical techniques associated with each study, sorted by flap type used

Authors	Year	Sample size	Phallus flap subtype	No. of stages	Pars fixa flap	Pars pendulans flap	Prelamination graft site	Reinforcement graft
Radial forearm flap (RFF)								
Ascha et al	2018	127	–	1	Labia minora	Radial forearm free	–	Vascularized bulbospongiosus muscle
Kim et al	2010	70	Osteocontaneous free	1	Labia minora and anterior vaginal wall	Radial forearm osteocontaneous free	–	One or two layers of soft tissue
Krueger et al	2007	253	–	1	Labia minora	Radial forearm	–	–
Monstrey et al	2009	287	–	1	Labia minora and anterior vaginal wall	Radial forearm	–	–
Rohrmann and Jakse	2003	25	–	1	Distal vaginal flap (n = 16), labia minora (n = 5), urethral plate (n = 4)	Radial forearm	–	–
Fang et al	1994	56	Sensate free	2	Vestibular skin with labia minora	Radial forearm sensate free	Tubed vaginal mucosa (n = 28)	–
Leriche et al	2008	56	Fasciocutaneous	2	Anterior vaginal wall	Radial forearm fasciocutaneous	–	–
Medina et al	2018	6	–	2	Anterior vaginal wall and labia minora	Vaginal graft	Posterolateral vaginal wall mucosa	Labia minora
Salgado et al	2016	15	–	2	Anterior vaginal wall and labia minora	Radial forearm osteocontaneous free	Buccal mucosa and thigh skin (n = 8), vaginal mucosa only (n = 2), buccal mucosa, vaginal mucosa, and abdominal skin (n = 2), thigh skin only (n = 1), uterine and vaginal mucosa (n = 1)	Pedicled myofascial gracilis flap (n = 4)
Song et al	2011	19	–	2	Vestibular skin with labia minora	Radial forearm	Lower abdominal wall	Perineal muscle flap
Fang et al	1999	22	Osteocontaneous free	3	Vaginal flap	Vaginal flap	Vaginal mucosa	–
Schaff	2007	25	Sensate free	3	Vaginal flap, labia minora, or metoidioplasty	Radial forearm sensate free	Vaginal epithelium or full-thickness skin graft (n = 29, n not stratified between RFF and fibula cases)	–
Schaff and Papadopoulos	2009	6	Sensate free	3	Anterior vaginal flap	Radial forearm sensate free	Vaginal mucosa	–
Garaffa et al	2010	115	Radial artery free	4	Labia minora and anterior vaginal wall	Radial forearm	–	Martius fat flap

Table 2 (Continued)

Authors	Year	Sample size	Phallus flap subtype	No. of stages	Pars fixa flap	Pars pendulans flap	Prelamination graft site	Reinforcement graft
<b>Anterolateral thigh flap</b>								
Massie et al	2017	155		–	Labia minora	Radial forearm	–	Fascioliipomatous tissue
van der Sluis et al	2016	19	Pedicled	1	Infundibular tissue between labia minora	Radial forearm free	–	–
Ascha et al	2018	59	Pedicled	1	Labia minora	Pedicled anterolateral thigh	–	Vascularized bulbospongiosus muscle
Zhang et al	2015	8	Pedicled	2	Pedicled vaginal mucosa	Pedicled anterolateral thigh	Vaginal mucosa	–
Massie et al	2017	67	Pedicled	–	Labia minora	Pedicled anterolateral thigh	–	Fascioliipomatous tissue
<b>Abdominal flap</b>								
Bettocchi et al	2005	32	Suprapubic	1	Clitoral and labia majora skin	Labia majora skin	–	–
Bettocchi et al	2005	33	Suprapubic	2	Clitoral and labia majora skin	Labia majora skin	–	Martius fat pad
Edgerton et al	1984	1	Midline bipedicle	2	Pedicled bladder	Pedicled bladder	–	–
Zhang et al	2015	14	–	2	Pedicled vaginal mucosa	Abdominal flap	Vaginal mucosa	–
Hage et al	1993	25	Abdominal skin (n = 16), rectus abdominis myocutaneous (n = 7), groin skin (n = 2)	3	Anterior vaginal wall and labia minora	Abdominal skin, groin skin, or rectus myocutaneous skin	–	–
<b>Fibular flap</b>								
Dabernig et al	2006	5	Sensate free septocutaneous	2	Anterior vaginal flap and vestibular skin strip	Sensate free septocutaneous fibular flap	Split-thickness skin graft from left thigh	–
Papadopoulos et al	2008	32	Sensate free osteocutaneous	3	Anterior vaginal flap	Sensate free osteocutaneous fibular flap	Split-thickness skin graft from anterior thigh	–
Schaff	2007	41	Sensate free osteofasciocutaneous	3	Vaginal flap, labia minora, or metoidioplasty	Sensate free osteofasciocutaneous fibular flap	Vaginal epithelium or full-thickness skin graft (n = 29, n not stratified between RFF and fibula)	–
Schaff and Papadopoulos	2009	31	Sensate free osteocutaneous	3	Anterior vaginal flap	Sensate free osteocutaneous fibular flap	Vaginal mucosa	–

(Continued)

Table 2 (Continued)

Authors	Year	Sample size	Phallus flap subtype	No. of stages	Pars fixa flap	Pars pendulans flap	Prelamination graft site	Reinforcement graft
Other flaps								
Lin and Chen	2009	1	Free thoracodorsal artery perforator	3	Anterior vaginal flap	Medial forearm full-thickness skin graft	Vaginal mucosa	—
Santanelli and Scuderi	2000	5	Tensor fasciae latae island	3	Skin strip between native urethral meatus to clitoris	Subcutaneous island flap from preputial apron	Full-thickness skin graft from lateral thigh	—
Namba et al	2019	15	Various, radial forearm and deep inferior epigastric artery perforator most common	1	Labia minora (n = 9), vaginal flap (n = 4), or metoidioplasty (n = 2)	Various, radial forearm whenever available	—	—

conclusions about the effects of any factors on complications of phalloplasty. Additionally, most complications other than fistulae, strictures, and complete flap loss were inconsistently reported in the literature, which limited the researchers' ability to perform rigorous analyses examining the effects of staging and flap type on complications such as donor-site morbidity or flap necrosis. Notably, information about complete flap loss was only included in 72% of studies compared with 88 and 96% of studies for urethral stricture and fistula, respectively.

The high level of heterogeneity in our extracted data, both within groupings by flap and in the total included study population, suggests that factors beyond the scope of this review, such as surgical expertise<sup>27</sup> and follow-up care protocols,<sup>42</sup> may have influenced the results of the reported studies. It is plausible that the variations in complication rates are due to a combination of small sample sizes and unmeasured factors such as differences in technique. As evidenced by **Table 3**, there are several factors that have been theorized to affect the outcomes of phalloplasty but none have been rigorously evaluated. One such factor potentially affecting complications may be the technique used for neourethral construction, which varies greatly between surgeons. Such variations may include flaps used for proximal and distal urethral lengthening, inclusion of prelamination, and choice of prelamination graft, several of which were reported by included studies as affecting intrapopulation outcomes.<sup>22,31,34,37,40</sup> As these techniques are not standardized and may be used with multiple flap types and staging, it is difficult to clearly assess their impact. Postoperative care protocols, which were not consistently reported, may have also impacted complication rates.

It is also possible that any reported differences between study types may be a result of reporting and publication bias. Several of the included studies report the development of new techniques, thus may have been subject to publication bias as publishers are more likely to publish a novel surgical technique with favorable results.<sup>43</sup> Further literature with more robust data are required to facilitate a comparison of surgical technique for masculinizing phalloplasty and should include other factors theorized to impact complications but were rarely reported across studies such as follow-up care protocols, patient comorbidities, and surgical expertise.

### Conclusion

Phalloplasty is a relatively young procedure with few standardized techniques, leading to poor quality data with inconsistent reporting of technique, outcomes, and confounding factors. Due to the limited number of surgeons across the globe who perform masculinizing gender-affirming surgeries and the relatively short history of these procedures, it is a challenge to draw firm conclusions from the available data. As the field evolves, it is critical to develop a standardized set of reporting parameters to allow for rigorous comparison between studies as well as further investigation into both patient and procedural factors that may affect surgical outcomes. The use of this reporting



**Table 3** Complications of phalloplasty for all included studies, sorted by flap type used

Authors	Year	Sample size	Phallus flap subtype	No. of stages	Urethral fistula [n (%)]	Urethral stricture [n (%)]	Complete flap loss [n (%)]	Other complications [n (%)]	Factors identified to impact complications
<b>Radial forearm flap (RFF)</b>									
Ascha et al	2018	127	–	1	15 (11.8)	20 (15.7)	–	Rectal injury: 1 (0.8) Hematoma: 5 (3.9) Abscess: 5 (3.9) Wound dehiscence: 2 (1.6) Partial flap loss: 5 (3.9) Meatus stenosis: 14 (11.0)	Anterolateral thigh flap associated with greater odds of urethral fistula, nonurethral complications, and phallus wound dehiscence compared with radial forearm flap
Kim et al	2010	70	Osteocutaneous free	1	21 (30.0)	–	1 (1.4)	–	Cylindrical siphon shape connecting pars fixa to pars pendulans associated with lower fistula rates
Krueger et al	2007	253	–	1	24 (9.5)	32 (12.6)	0	Venous thrombosis: 1 (0.3) Arterial thrombosis: 2 (0.8) Wound infection: 4 (1.6)	Standardization and experience of surgeon explicitly mentioned to reduce complications
Monstrey et al	2009	287	–	1	98 (34.1)	47 (16.4)	2 (0.7)	Partial flap necrosis: 21 (7.3) Partial flap loss: 21 (7.3) Anastomotic revision: 34 (11.8) Pulmonary embolism: 3 (1.0) Donor-site regrafting: 2 (0.7) Nerve compression: 2 (0.7) Delayed wound healing: 32 (11.1)	–
Rohrmann and Jakse	2003	25	–	1	11 (44.0)	10 (40.0)	–	–	Urethral plate technique of urethral lengthening may lower fistula and stricture rates
Fang et al	1994	56	Sensate free	2	38 (67.9)	7 (12.5)	1 (1.8)	Urethrolithiasis: 2 (3.6) Hair growth in urethra: 4 (7.1)	Prelamination with vaginal mucosa associated with fewer

(Continued)

**Table 3** (Continued)

Authors	Year	Sample size	Phallus flap subtype	No. of stages	Urethral fistula [n (%)]	Urethral stricture [n (%)]	Complete flap loss [n (%)]	Other complications [n (%)]	Factors identified to impact complications
Leriche et al	2008	56	Fasciocutaneous	2	15 (26.8)	3 (5.4)	3 (5.4)	Infection: 7 (12.5) Partial flap loss: 6 (10.7)	complications and lower fistula rate at anastomosis between pars fixa and pars pendulans
Medina et al	2018	6	–	2	2 (33.3)	1 (16.7)	–	–	Implantation of penile prosthesis associated with increased complications
Salgado et al	2016	15	–	2	7 (46.7)	–	–	–	Use of vaginal epithelium for prelamination associated with lower urologic complications
Song et al	2011	19	–	2	10 (52.6)	14 (73.7)	2 (10.5)	Cellulitis: 3 (15.8) Partial skin necrosis: 2 (10.5) Partial flap loss: 1 (5.3)	Gracilis flap used to cover urethral anastomosis associated with lower urologic complications
Fang et al	1999	22	Osteocutaneous free	3	14 (63.6)	3 (13.6)	0	Donor-site morbidity: 10 (45.5) Partial flap loss: 1 (4.5)	Urethral reinforcement with perineal muscle and repair prior to anastomosis reduces stricture and fistula
Schaff	2007	25	Sensate free	3	4 (16.0)	5 (20.0)	0	Partial flap necrosis: 1 (4.0) Partial flap loss: 1 (4.0)	–
Garaffa et al	2010	115	Radial artery free	4	20 (17.4)	9 (7.8)	3 (2.6)	Partial skin necrosis: 12 (10.4) Meatus stenosis: 9 (7.8)	A rotation of the anterior vaginal flap to be included in the dorsal aspect of the urethra can reduce urethral fistula by up to 75%
<b>Anterolateral thigh (ALT) flap</b>									
van der Sluis et al	2016	19	Pedicled	1	2 (10.5)	9 (47.4)	3 (15.8) (2 RFF, 1 ALT)	Donor-site infection: 1 (5.3) Partial flap loss: 1 (5.3)	Radial forearm flap failures partially attributed to outer flap complications affected

**Table 3** (Continued)

Authors	Year	Sample size	Phallus flap subtype	No. of stages	Urethral fistula [n (%)]	Urethral stricture [n (%)]	Complete flap loss [n (%)]	Other complications [n (%)]	Factors identified to impact complications
Ascha et al	2018	59	Pedicled	1	12 (20.3)	13 (22.0)	–	Hematoma: 1 (1.7) Abscess: 1 (1.7) Meatus stenosis: 2 (3.4) Partial flap loss: 5 (8.5) Wound dehiscence: 6 (10.1)	vascularization of inside flap Anterolateral thigh flap associated with greater odds of urethral fistula, nonurethral complications, and phallus wound dehiscence compared with radial forearm flap
<b>Abdominal flap</b>									
Bettocchi et al	2005	32	Suprapubic	1	30 (93.8)	30 (93.8)	3 (4.6)^	Urethral stones: 2 (6.3) Meatus stenosis: 10 (31.3)	Urethral fistula and stricture reduced in two-stage procedures
Bettocchi et al	2005	33	Suprapubic	2	15 (45.5)	21 (63.6)	3 (4.6)^	Urethral stones: 3 (9.1) Meatus stenosis: 12 (36.4)	Urethral fistula and stricture reduced in two-stage procedures
Edgerton et al	1984	1	Midline bipedicle	2	–	–	0	–	Postoperative course described as completely uneventful
Hage et al	1993	25	Abdominal skin (n = 16), rectus abdominis myocutaneous (n = 7), groin skin (n = 2)	3	3 (12.0)	2 (8.0)	0	Wound dehiscence: 6 (24.0)	–
<b>Fibular flap</b>									
Dabernig et al	2006	5	Sensate free septocutaneous	2	–	2 (40.0)	0	Meatus stenosis: 1 (20.0)	–
Papadopoulos et al	2008	32	Sensate free osteocutaneous	3	7 (21.9)	10 (31.3)	2 (6.3)	Infection: 2 (6.3) Partial flap loss: 4 (12.5) Wound dehiscence: 4 (12.5)	Prelamination of pars pendulans with split-thickness skin graft reduces urethral fistula
Schaff	2007	41	Sensate free osteofasciocutaneous	3	5 (12.2)	6 (14.6)	2 (4.9)	Partial flap necrosis: 5 (12.2) Partial flap loss: 5 (12.2)	–

(Continued)

**Table 3** (Continued)

Authors	Year	Sample size	Phallus flap subtype	No. of stages	Urethral fistula [n (%)]	Urethral stricture [n (%)]	Complete flap loss [n (%)]	Other complications [n (%)]	Factors identified to impact complications
<b>Other flaps</b>									
Lin and Chen	2009	1	Free thoracodorsal artery perforator	3	–	–	0	–	Postoperative course described as completely uneventful
Santanelli and Scuderi	2000	5	Tensor fasciae latae island	3	3 (60.0)	1 (20.0)	–	Partial flap necrosis: 1 (20.0) Partial flap loss: 1 (20.0)	–
<b>Complications not stratified by flap type</b>									
Schaff and Papadopulos	2009	37	Sensate free radial forearm (n = 6), sensate free osteocutaneous fibular flap (n = 31)	3	6 (16.2)	12 (32.4)	–	Partial flap necrosis: 6 (16.2) Partial flap loss: 6 (16.2)	–
Massie et al	2017	224	Radial forearm (n = 155), Pedicled anterolateral thigh (n = 67)	–	35 (15.6)	40 (17.9)	–	Hematoma: 6 (2.7) Abscess: 8 (3.6) Rectal injury: 1 (0.4) Scrotal complication: 1 (0.4) Wound dehiscence: 9 (4.0) Partial flap loss: 10 (4.5) Meatus stenosis: 19 (8.5)	Vaginectomy associated with decrease in urethral fistula and stricture
Zhang et al	2015	22	Pedicled anterolateral thigh (n = 8), abdominal flap (n = 14)	2	7 (31.8)	1 (4.5)	0	–	–
Namba et al	2019	15	Various, radial forearm and deep inferior epigastric artery perforator most common	1	5 (33.3)	–	0	Venous thrombosis: 3 (20.0) Urethral calculus: 2 (13.3) Arterial thrombosis: 1 (6.7) Rod infection: 1 (6.7) Partial flap loss: 1 (6.7)	–

Note: ^This number was not stratified by stage, and reflects the complete flap loss for both 1- and 2-stage procedures (i.e. full study sample).

framework and standardized data will help clinicians and patients alike by providing high-quality evidence. We believe that such a set of guidelines is essential to creating a solid evidence base with which to guide patient care decision making. As there is currently insufficient evidence to identify an ideal surgical technique, the choice of phallus flap(s) and number of surgical stages should depend on factors such as surgeon and patient preference, resources, anesthetic safety, and patient tolerance.

#### Funding

None.

#### Conflict of Interest

None declared.

#### References

- Meerwijk EL, Sevelius JM. Transgender population size in the United States: a meta-regression of population-based probability samples. *Am J Public Health* 2017;107(02):e1–e8
- Flores AR, Herman JL, Gates GJ, Brown TNT. How Many Adults Identify as Transgender in the United States? The Williams Institute. 2016. Accessed March 28, 2022 at: <https://williamsinstitute.law.ucla.edu/wp-content/uploads/How-Many-Adults-Identify-as-Transgender-in-the-United-States.pdf>
- Canner JK, Harfouch O, Kodadek LM, et al. Temporal trends in gender-affirming surgery among transgender patients in the United States. *JAMA Surg* 2018;153(07):609–616
- Hadj-Moussa M, Agarwal S, Ohl DA, Kuzon WM Jr. Masculinizing genital gender confirmation surgery. *Sex Med Rev* 2019;7(01):141–155
- Frey JD, Poudrier G, Thomson JE, Hazen A. A historical review of gender-affirming medicine: focus on genital reconstruction surgery. *J Sex Med* 2017;14(08):991–1002
- Frey JD, Poudrier G, Chiodo MV, Hazen A. An update on genital reconstruction options for the female-to-male transgender patient: a review of the literature. *Plast Reconstr Surg* 2017;139(03):728–737
- Weissler JM, Chang BL, Carney MJ, et al. Gender-affirming surgery in persons with gender dysphoria. *Plast Reconstr Surg* 2018;141(03):388e–396e
- Morrison SD, Chen ML, Crane CN. An overview of female-to-male gender-confirming surgery. *Nat Rev Urol* 2017;14(08):486–500
- Esmonde N, Bluebond-Langner R, Berli JU. Phalloplasty flap-related complication. *Clin Plast Surg* 2018;45(03):415–424
- Nikolavsky D, Hughes M, Zhao LC. Urologic complications after phalloplasty or metoidioplasty. *Clin Plast Surg* 2018;45(03):425–435
- Kim JH. Surgical tricks in female to male gender reassignment surgery; metoidioplasty & bilateral inguinal flap phalloplasty. *J Sex Med* 2013;10:189
- Remington AC, Morrison SD, Massie JP, et al. Outcomes after phalloplasty: do transgender patients and multiple urethral procedures carry a higher rate of complication? *Plast Reconstr Surg* 2018;141(02):220e–229e
- Ascha M, Massie JP, Morrison SD, Crane CN, Chen ML. Outcomes of single stage phalloplasty by pedicled anterolateral thigh flap versus radial forearm free flap in gender confirming surgery. *J Urol* 2018;199(01):206–214
- Courtois F, Terrier JÉ, Brassard P, Ruffion A, Morel-Journal N. Development of surgical phalloplasty techniques: is there a gold standard? *Sexologies* 2012;21(02):55–59
- Moher D, Shamseer L, Clarke M, et al; PRISMA-P Group. Preferred Reporting Items for Systematic Review and Meta-Analysis protocols (PRISMA-P) 2015 statement. *Syst Rev* 2015;4(01):1
- Guyatt G, Oxman AD, Akl EA, et al. GRADE guidelines: 1. Introduction-GRADE evidence profiles and summary of findings tables. *J Clin Epidemiol* 2011;64(04):383–394
- Murad MH, Sultan S, Haffar S, Bazerbachi F. Methodological quality and synthesis of case series and case reports. *BMJ Evid Based Med* 2018;23(02):60–63
- van der Sluis W, Smit JM, Pigot G, Buncamper M, Bouman MB. One-stage pedicled anterolateral thigh flap phalloplasty combined with free radial forearm flap urethral reconstruction in transgender men: surgical technique and outcome in nineteen patients. *J Sex Med* 2016;13(05):S223–S224
- Bettocchi C, Ralph DJ, Pryor JP. Pedicled pubic phalloplasty in females with gender dysphoria. *BJU Int* 2005;95(01):120–124
- Dabernig J, Chan LKW, Schaff J. Phalloplasty with free (septo-cutaneous) fibular flap sine fibula. *J Urol* 2006;176(05):2085–2088
- Edgerton MT, Gillenwater JY, Kenney JG, Horowitz J. The bladder flap for urethral reconstruction in total phalloplasty. *Plast Reconstr Surg* 1984;74(02):259–266
- Fang RH, Lin JT, Ma S. Phalloplasty for female transsexuals with sensate free forearm flap. *Microsurgery* 1994;15(05):349–352
- Fang RH, Kao YS, Ma S, Lin JT. Phalloplasty in female-to-male transsexuals using free radial osteocutaneous flap: a series of 22 cases. *Br J Plast Surg* 1999;52(03):217–222
- Garaffa G, Christopher NA, Ralph DJ. Total phallic reconstruction in female-to-male transsexuals. *Eur Urol* 2010;57(04):715–722
- Hage JJ, Bouman FG, Bloem JJAM. Preconstruction of the pars pendulans urethrae for phalloplasty in female-to-male transsexuals. *Plast Reconstr Surg* 1993;91(07):1303–1307
- Kim SK, Moon JB, Heo J, Kwon YS, Lee KC. A new method of urethroplasty for prevention of fistula in female-to-male gender reassignment surgery. *Ann Plast Surg* 2010;64(06):759–764
- Krueger DM, Yekani SAH, Hundt Dv, Daverio DPJ. One-stage sex reassignment surgery from female to male. *Int J Transgenderism* 2007;10(01):15–18
- Leriche A, Timsit MO, Morel-Journal N, Bouillot A, Dembele D, Ruffion A. Long-term outcome of forearm free-flap phalloplasty in the treatment of transsexualism. *BJU Int* 2008;101(10):1297–1300
- Lin CT, Chen LW. Using a free thoracodorsal artery perforator flap for phallic reconstruction—a report of surgical technique. *J Plast Reconstr Aesthet Surg* 2009;62(03):402–408
- Massie JP, Morrison SD, Wilson SC, Crane CN, Chen ML. Phalloplasty with urethral lengthening: addition of a vascularized bulbospongiosus flap from vaginectomy reduces postoperative urethral complications. *Plast Reconstr Surg* 2017;140(04):551e–558e
- Medina CA, Fein LA, Salgado CJ. Total vaginectomy and urethral lengthening at time of neourethral prelamination in transgender men. *Int Urogynecol J Pelvic Floor Dysfunct* 2018;29(10):1463–1468
- Monstrey S, Hoebeke P, Selvaggi G, et al. Penile reconstruction: is the radial forearm flap really the standard technique? *Plast Reconstr Surg* 2009;124(02):510–518
- Namba Y, Watanabe T, Kimata Y. Flap combination phalloplasty in female-to-male transsexuals. *J Sex Med* 2019;16(06):934–941
- Papadopoulos NA, Schaff J, Biemer E. The use of free prelaminated and sensate osteofasciocutaneous fibular flap in phalloplasty. *Injury* 2008;39(Suppl 3):S62–S67
- Schaff DJ. Enlarged range of free flaps for phalloplasty in transsexual reassignment surgery. *Int J Transgenderism* 2007;10(01):39–45
- Rohrman D, Jakse G. Urethroplasty in female-to-male transsexuals. *Eur Urol* 2003;44(05):611–614

- 37 Salgado CJ, Nugent AG, Moody AM, Chim H, Paz AM, Chen HC. Immediate pedicled gracilis flap in radial forearm flap phalloplasty for transgender male patients to reduce urinary fistula. *J Plast Reconstr Aesthet Surg* 2016;69(11):1551–1557
- 38 Santanelli F, Scuderi N. Neophalloplasty in female-to-male transsexuals with the island tensor fasciae latae flap. *Plast Reconstr Surg* 2000;105(06):1990–1996
- 39 Schaff J, Papadopoulos NA. A new protocol for complete phalloplasty with free sensate and prelaminated osteofasciocutaneous flaps: experience in 37 patients. *Microsurgery* 2009;29(05):413–419
- 40 Song C, Wong M, Wong CH, Ong YS. Modifications of the radial forearm flap phalloplasty for female-to-male gender reassignment. *J Reconstr Microsurg* 2011;27(02):115–120
- 41 Zhang YF, Liu CY, Qu CY, et al. Is vaginal mucosal graft the excellent substitute material for urethral reconstruction in female-to-male transsexuals? *World J Urol* 2015;33(12):2115–2123
- 42 Brooke BS, Stone DH, Cronenwett JL, et al. Early primary care provider follow-up and readmission after high-risk surgery. *JAMA Surg* 2014;149(08):821–828
- 43 Olson CM, Rennie D, Cook D, et al. Publication bias in editorial decision making. *JAMA* 2002;287(21):2825–2828