




# New Use of an Absorbable Adhesion Barrier (INTERCEED) for Temporary Diverting Ileostomy in Minimally Invasive Rectal Surgery

Toshiya Nagasaki<sup>1</sup>  Takashi Akiyoshi<sup>1</sup> Toshiki Mukai<sup>1</sup> Yukiharu Hiyoshi<sup>1</sup> Tomohiro Yamaguchi<sup>1</sup> Yosuke Fukunaga<sup>1</sup>

<sup>1</sup>Department of Gastroenterological Surgery, Gastroenterological Center, Cancer Institute Hospital, Japanese Foundation for Cancer Research, Tokyo, Japan

J Coloproctol 2022;42(2):152–158.

Address for correspondence Toshiya Nagasaki, MD, PhD, Gastroenterological Center, Department of Gastroenterological Surgery, Cancer Institute Hospital, Japanese Foundation for Cancer Research, 3-8-31 Ariake, Koto-ku, Tokyo 135-8550, Japan (e-mail: toshiya.nagasaki@jfc.or.jp).

## Abstract

**Objectives** Sometimes, severe adhesion occurs between the rectus abdominis muscle and the ileal intestinal limbs after temporary diverting ileostomy. This can make ileostomy reversal difficult. The aim of the present study is to assess whether absorbable adhesion barrier made of oxidized regenerated cellulose (INTERCEED) could contribute to improved surgical outcomes in stoma reversal.

**Methods** This was a single-institutional retrospective study. A total of 36 consecutive patients who underwent ileostomy reversal by a single surgeon were retrospectively reviewed. INTERCEED was inserted between the ileal limbs and the rectus abdominis muscle at the time of ileostomy creation in 12 patients. Surgical outcomes of the ileostomy reversal were compared between patients treated with and without INTERCEED.

**Results** The degree of adhesion formation between the ileal limbs and the rectus abdominis muscles, operating time, and estimated blood loss were significantly reduced in patients treated with INTERCEED compared with those treated by the conventional approach. None of the patients in the INTERCEED group had postoperative complications after the initial surgery and ileostomy reversal.

**Conclusions** INTERCEED is suitable for insertion between the ileal limbs and the rectus abdominis muscles because of its softness and flexibility. The use of INTERCEED for diverting ileostomy contributes to reduced adhesion formation, operative time, and blood loss in patients, and further research is needed to confirm our results.

## Keywords

- ▶ INTERCEED
- ▶ diverting ileostomy
- ▶ laparoscopic rectal surgery

## Introduction

Anastomotic leakage is the most feared complication after rectal surgery, the incidence of which is associated with a

low pelvic anastomosis.<sup>1</sup> Proximal fecal diversion can reduce the incidence of symptomatic anastomotic leakage and the need for reoperation related to leakage.<sup>2</sup> For these reasons, the creation of a temporary diverting stoma is recommended

received  
October 12, 2021  
accepted  
November 19, 2021

DOI <https://doi.org/10.1055/s-0042-1748838>.  
ISSN 2237-9363.

© 2022. Sociedade Brasileira de Coloproctologia. All rights reserved.

This is an open access article published by Thieme under the terms of the Creative Commons Attribution-NonDerivative-NonCommercial-License, permitting copying and reproduction so long as the original work is given appropriate credit. Contents may not be used for commercial purposes, or adapted, remixed, transformed or built upon. (<https://creativecommons.org/licenses/by-nc-nd/4.0/>)

Thieme Revinter Publicações Ltda., Rua do Matoso 170, Rio de Janeiro, RJ, CEP 20270-135, Brazil

for patients who have a high risk of anastomotic leakage. Stomas are generally brought through the rectus abdominis muscle to prevent parastomal herniation. However, at the time of stoma reversal, dense adhesions usually have formed between the bowel limbs and the rectus abdominis muscles. Adhesiolysis can be difficult to implement without injuring the stomal wall.<sup>3</sup>

INTERCEED (Johnson & Johnson, New Brunswick, NJ, USA) is a knitted fabric of oxidized regenerated cellulose. INTERCEED and other similar absorbable adhesion barriers have been reported to reduce adhesion formation after abdominal and gynecological surgery. Some of these adhesion barriers also prevent the formation of adhesions between the stomal limbs and subcutaneous tissues<sup>4-10</sup>; however, as yet, INTERCEED has not been reported as an intervention against adhesion formation in patients with temporary stomas.

Unlike other absorbable adhesion barriers, INTERCEED does not stick to soft tissues and is easy to manipulate because of its softness and flexibility<sup>11</sup>; therefore, INTERCEED could be effectively inserted between the stomal limb and the rectus abdominis muscle to prevent or reduce adhesion formation. The aim of the present study was to assess whether INTERCEED could contribute to improve surgical outcomes after stoma reversal.

## Methods

This is a retrospective study of consecutive patients who underwent ileostomy reversal between January 2016 and October 2020 at a single institution. All patients were originally treated by laparoscopic or robotic-assisted laparoscopic rectal surgery, with primary surgery and ileostomy creation performed by a single surgeon (Nagasaki T.) Among patients who underwent curative resection for primary rectal neoplasm, a diverting loop ileostomy was created for those who required a very low anastomosis (within 4 cm from the anal verge), and for those who received neoadjuvant treatment. We conducted the present study in compliance with the principles of the Declaration of Helsinki. All of the included patients signed a general consent form prior to surgery.


Preoperative chemoradiotherapy or radiotherapy was performed in low rectal cancer patients with clinical stage II/III, as previously described.<sup>12</sup> Patients with a more locally advanced stage received sequential chemotherapy and chemoradiotherapy.<sup>13</sup> Patients with pathological stage III were treated with 5-FU-based adjuvant chemotherapy.

The following data were compared between patients treated with and without INTERCEED: pathology of the primary tumor, clinical stage (UICC 8<sup>th</sup> edition), with or without neoadjuvant treatment, type of rectal anastomosis, operation time and estimated blood loss during the initial surgery, postoperative complications, white blood cell count (/ $\mu$ L), neutrophil count (/ $\mu$ L), C-reactive protein levels (mg/dL) on postoperative day 1, duration of hospital stay after rectal surgery, with or without adjuvant treatment, and time to ileostomy closure from the date of the initial surgery. Moreover, the following data after ileostomy reversal were com-

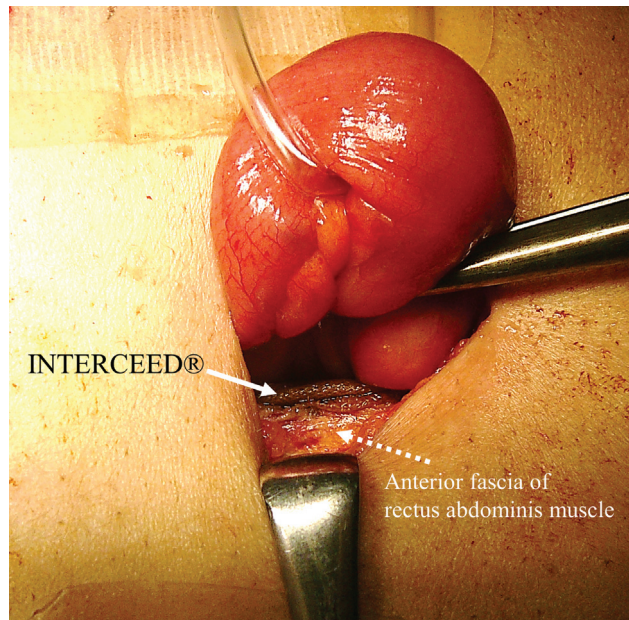
pared: gender, age, body mass index (BMI) at ileostomy reversal, American Society of Anesthesiologists (ASA) performance status, operation time and estimated blood loss of ileostomy closure, degree of the adhesion between the ileal limbs and rectus abdominis muscles, white blood cell count (/ $\mu$ L), neutrophil count (/ $\mu$ L), C-reactive protein levels (mg/dL) on postoperative day 1, postoperative complications (Clavien-Dindo grade 2 or higher), and postoperative hospital stay. The primary outcomes of the present study included operative time and estimated blood loss. The operative records of ileostomy reversal were reviewed to confirm the degree of adhesion formation between the ileal limbs and rectus abdominis muscles. The degree of the adhesion was classified as not severe or severe according to the descriptions in the operative records. The evaluation of the degree of adhesion was made based on the subjective impression of the surgeon at that time.

## Operative Procedures

Laparoscopic procedures were performed using the five-trocar approach, as previously described;<sup>14</sup> the hand-assisted technique was not used. Diverting ileostomy creation was performed after rectal anastomosis. The distal ileum – ~ 25 cm from the Bauhin valve – was lifted through a split rectus abdominis muscle at the right lower quadrant. To prevent stenosis, the ileostomy aperture was dilated to easily admit two fingers. For patients treated after July 2019, INTERCEED was inserted between the ileum and the rectus abdominis muscle. One-quarter of an INTERCEED sheet was cut (rectangular reed-shape) and inserted from the ventral side of the abdomen (► **Figures 1** and **2**). The sheet was used to separate the ileal limbs from the rectus abdominis muscles. The sheet was placed circumferentially without overlapping the edges to prevent stenosis. The ileum was opened after the sheet was inserted to prevent infection due to the use of a foreign material. The distal limb of the loop was located on the caudal side, and the ileal mucosa was sutured



**Fig. 1** INTERCEED is supplied as a knitted fabric measuring 15.2 × 12.7 cm. One-quarter of a sheet was cut into a rectangular reed-shape (red-dotted line) and inserted between the ileal limbs and the rectus abdominis muscle in 10 patients treated after July 2019.



**Fig. 2** INTERCEED was inserted between the ileal limbs and the rectus abdominis muscle from the ventral side of the abdomen.

circumferentially to the skin edges. Fixation to the rectus abdominis fascia was not performed. Except for the insertion of the INTERCEED, the procedures of stoma creation were the same for all patients. In the No INTERCEED group, no other adhesion barrier was not used.

The ileostomy was closed at about 3 months after the initial surgery or after the completion of adjuvant chemotherapy, and all surgeries were performed electively by the same single surgeon (Nagasaki T.). A circumstomal skin incision was made and the ileal loop was mobilized down to the peritoneal cavity. Adhesions surrounding the ileostomy, if present, were mobilized as much as possible after entering the peritoneal cavity. The mesentery of the ileostomy was divided, and small transverse incisions on the antimesenteric aspect were made just proximal and distal to the mobilized segments. A Proximate Linear Cutter (TVC55; Ethicon Endo-Surgery, Cincinnati, OH, USA) was inserted through the enterotomy into the afferent and efferent limbs. The stapler was fired after ensuring no interposition of the mesentery. The ileostomy-bearing segment and the enterotomy site were removed by firing a different Proximate Linear Cutter (TLC75; Ethicon Endo-Surgery, Cincinnati, OH, USA). The patency of the anastomosis was checked by the thumb and index fingers of the surgeon. The edges and junctions of the stapled lines were reinforced, and the mesenteric window was closed to prevent an internal hernia. The rectus abdominis fascia, subcutaneous fat, and the peritoneum were closed by interrupted sutures. The skin incision was closed with a purse-string suture without insertion of a drainage tube. The ileostomy reversal procedures were the same throughout the study period, and the same clinical pathway was used for all patients.

## Statistical Analyses

All data were analyzed using BellCurve for Microsoft Excel (Microsoft Corporation, Redmond, WA, USA) software, ver-

sion 3.20 (Social Survey Research Information Co., Ltd., Tokyo, Japan). Continuous data are presented as the median and range, with differences compared using the Mann-Whitney U-test. Differences between categorical variables were compared using the Fisher exact test. A  $p$ -value  $< 0.05$  was considered statistically significant.

## Results

In the present study period, 53 patients underwent rectal surgery and ileostomy reversal by the first author. Three patients who underwent another operation at the time of ileostomy reversal were excluded. Similarly, 14 patients who underwent simultaneous primary rectal resection and major abdominal surgery were also excluded. Finally, 36 patients were included in the analysis.

The present cohort comprised 21 (58.3%) men and 15 (41.7%) women with a median age of 63.5 years old (range: from 31 to 79 years old). The primary tumors included rectal adenocarcinoma in 28 patients and neuroendocrine tumor in 8 patients. Neoadjuvant treatment was performed in 8 (28.6%) patients with rectal adenocarcinoma. Adjuvant chemotherapy was administered in 7 of the 9 patients with pathological stage II/III rectal cancer. None of the patients underwent early stoma closure (within 60 days). A total of 24 consecutive patients who underwent ileostomy reversal between March 2016 and July 2019 were included in the No INTERCEED group, and 12 patients treated after July 2019 were included in the INTERCEED group. Two patients in the INTERCEED group underwent robotic-assisted laparoscopic surgery, whereas the other 34 patients underwent laparoscopic curative resection for the primary tumor. No patient required conversion to laparotomy.

► **Table 1** shows a comparison of the clinical characteristics and perioperative outcomes at the time of the initial surgery between the groups. Pathological type of the primary tumor, clinical stage, the administration of neoadjuvant treatment, type of rectal anastomosis, operation time and estimated blood loss during the primary surgery, inflammatory response on postoperative day 1, and postoperative hospital stay were similar between the 2 groups. None of the patients in the INTERCEED group had postoperative complications after the initial surgery, whereas two patients in the No INTERCEED group had grade 2 enteritis postoperatively. The time to ileostomy closure was not significantly different between the two groups. None of the patients experienced any severe morbidity or mortality.

► **Table 2** shows a comparison of the clinical characteristics and surgical outcomes following ileostomy reversal between the two groups. Patient gender, age at ileostomy reversal, BMI, and ASA performance status were similar between the groups. None of the patients in the INTERCEED group had severe adhesions between the ileal limbs and the rectus abdominis muscles, whereas 9 (37.5%) patients in the No INTERCEED group had severe adhesions ( $p = 0.0163$ ). There were no intraoperative bowel injuries or serosal tears among patients in the INTERCEED group, but one patient in the No INTERCEED group had intraoperative bowel injury

**Table 1** Comparison of clinical characteristics and surgical outcomes of the initial surgery between the two groups

	INTERCEED group (n = 12)	No INTERCEED group (n = 24)	p-value
Primary tumor			0.3974
Adenocarcinoma	8	20	
Neuroendocrine tumor	4	4	
Clinical stage of primary tumor			1.000
I	9	17	
II/III	3	7	
Neoadjuvant treatment for primary tumor			1.000
No	9	19	
Yes	3	5	
Type of initial anastomosis			0.2784
Double stapling technique	12	20	
Coloanal hand-sewn anastomosis	0	4	
Operation time of the initial surgery, minutes (range)	278 (174–345)	278.5 (147–451)	0.6748
Blood loss during the initial surgery, ml (range)	10 (5–50)	15 (3–290)	0.2981
Postoperative complications after rectal surgery			0.5429
No	12	22	
Yes	0	2	
Enteritis		2	
Laboratory results on postoperative day 1			
White blood cell count, / $\mu$ L (range)	9,650 (4,000–11,700)	8,750 (4,600–13,000)	0.5568
Neutrophil count, / $\mu$ L (range) <sup>#</sup>	7,570 (3,160–9,300)	7,715 (3,580–11,610)	0.9385
C-reactive protein, mg/dL (range)	4.77 (2.27–7.71)	3.81 (1.84–9.61)	0.2082
Hospitalization after primary surgery, days (range)	13.5 (11–20)	13 (10–19)	0.9730
Adjuvant treatment for primary tumor			0.6910
No	10	18	
Yes	2	6	
Time to ileostomy closure, days (range)	99.5 (85–213)	120.5 (64–366)	0.2902

<sup>#</sup>Neutrophil counts were not available for 3 patients in the INTERCEED® group and for 6 patients in the No INTERCEED group.

\*Postoperative complications were defined as Clavien-Dindo grade 2 or higher.

and another patient had serosal tears. Operation time was significantly shorter and estimated blood loss was significantly reduced in the INTERCEED group compared with the No INTERCEED group. Inflammatory response on postoperative day 1 was similar between the 2 groups. There were no complications among patients in the INTERCEED group after ileostomy reversal, whereas 2 patients in the No INTERCEED group had grade 2 enteritis postoperatively. Postoperative hospitalization was similar between the groups.

## Discussion

The present study demonstrates a novel use of INTERCEED in temporary diverting ileostomy. Our results show that INTERCEED can reduce operative time and blood loss during ileostomy reversal, which could be due to the prevention of dense adhesion formation between the ileal limbs and the rectus abdominis muscle. In the present study, none of the

patients in the INTERCEED group had severe adhesions, and adhesiolysis was easily performed. The ileostomy reversal was accomplished with  $\leq 5$  ml blood loss in 83.3% of the patients in the INTERCEED group; intraoperative blood loss in previous studies is much higher (15 to 50 ml).<sup>5,7–9</sup>

Significant progress in the design of surgical devices and multimodal therapy has provided patients with a broader range of sphincter-sparing procedures with low pelvic anastomosis.<sup>15</sup> The frequency of temporary stoma creation for proximal fecal diversion has also increased accordingly.<sup>16</sup> Although loop ileostomy is the preferred method of treatment for temporary proximal diversion, ileostomy reversal is associated with a certain morbidity. Previous studies have shown a wide range in the morbidity and mortality rates after ileostomy reversal of 16.4 to 36.5% and of 0.4 to 3.3%, respectively.<sup>17–24</sup> Schneider et al. reported that 5.4% of the patients suffered intraoperative bowel perforation, while 30.5% of the patients experienced serosal tears during

**Table 2** Comparison of surgical outcomes of ileostomy reversal between the two groups

	INTERCEED group (n = 12)	No INTERCEED group (n = 24)	p-value
Gender			0.1753
Male	5	16	
Female	7	8	
Age, years old (range)	66.5 (48–77)	62.5 (31–79)	0.2605
Body mass index, kg/m <sup>2</sup> (range)	22.8 (14.7–31.7)	22.7 (16.1–26.3)	0.9331
ASA performance status			1.000
1	5	10	
2	7	14	
Degree of the adhesion between the ileal limbs and the rectus abdominis muscles			0.0163
Not severe	12	15	
Severe	0	9	
Intraoperative bowel perforation or serosal tears	0	2	0.5429
Operation time, minutes (range)	58 (46–64)	64 (47–98)	0.0357
Estimated blood loss, ml (range)	5 (2–10)	10 (2–70)	0.0060
Laboratory results on postoperative day 1			
White blood cell count, / $\mu$ L (range)	9,100 (5,300–13,100)	9,000 (5,100–15,100)	0.7753
Neutrophil count, / $\mu$ L (range) <sup>#</sup>	9,870 (3,850–10,860)	7,400 (3,560–10,610)	0.7059
C-reactive protein, mg/dL (range)	2.30 (0.74–7.11)	2.95 (0.88–6.81)	0.5798
Postoperative complication <sup>*</sup>			0.5429
No	12	22	
Yes	0	2	
Enteritis		2	
Postoperative hospital stay, days (range)	7.5 (6–13)	8 (4–17)	0.2903

Abbreviation: ASA, American Association of Anesthesiologists

<sup>#</sup>Neutrophil counts were not available for 3 patients in the INTERCEED group and for 7 patients in the No INTERCEED group.

<sup>\*</sup>Postoperative complications were defined as Clavien-Dindo grade 2 or higher.

ileostomy reversal.<sup>3</sup> In addition, longer operating times and intraoperative complications are independent risk factors for readmission after ileostomy closure.<sup>18</sup> Although loop ileostomy reversal is regarded as a minor operation, it is not always easy to perform. Surgeons know empirically that the technical difficulties of loop ileostomy reversal depend on the degree of subcutaneous and intra-abdominal adhesions to the bowel loops. Although laparoscopic surgery tends to have lower rates of intra-abdominal adhesion formation,<sup>25</sup> dense adhesions often occur between the ileal limbs and the subcutaneous tissues (especially with the rectus abdominis muscles).

Previous studies have tried to solve this problem using various absorbable adhesion barriers. A solid adhesion barrier consisting of sodium hyaluronate and carboxymethylcellulose, known as Seprafilm, was used to reduce adhesion formation between the ileal limbs and subcutaneous tissues in four prospective randomized trials<sup>4–7</sup> and in one retrospective study.<sup>8</sup> Adhesion scores were significantly different between patients with and without Seprafilm in

all four randomized studies. However, only in one study<sup>5</sup> there was a significant reduction in operation time and estimated blood loss at the time of ileostomy closure with the use of Seprafilm; there was no significant improvement in either parameter for the other three prospective trials.<sup>4,6,7</sup> Another retrospective study demonstrated the significant reduction in operation time in the Seprafilm group, but there was no beneficial reduction in blood loss, and intraoperative bowel injury and wound infection were observed in 5.6 and 16.7% of the patients treated with Seprafilm, respectively.<sup>8</sup> A polyactide barrier film, Surgi-Wrap, has also been tested against adhesion around the stoma limb. Whereas operation time was significantly shorter in patients treated with SurgiWrap, intraoperative blood loss was unchanged, and wound infection occurred in 8.3% of the patients.<sup>9</sup> Finally, using a sprayable hydrogel adhesion barrier, SprayGel, one study showed that operation time was significantly reduced, but intraoperative serosal tears occurred in 26.3% of the patients and wound infection in 5.3% of the patients.<sup>10</sup>

In the present study, none of the patients in the INTERCEED group had intraoperative bowel injury or postoperative wound infection. Infection due to the placement of foreign materials is an important potential complication for surgeons. A key point in our procedure was that INTERCEED was cut into a rectangular reed shape that was inserted only into the space between the ileal limbs and the rectus abdominis muscle, not into the subcutaneous adipose tissue. In addition, the ileum was opened only after the sheet was placed. The bacteria-rich effluent from an ileostomy easily flows into the subcutaneous space and, therefore, a foreign body should not be placed into the subcutaneous fatty tissue around the stoma.

The main purpose of inserting INTERCEED was to prevent severe adhesion formation between the bowel wall and the rectus abdominis muscle. Adhesiolysis of the bowel loop from subcutaneous fat is not difficult; however, when there are severe adhesions between the bowel wall and belly muscle, it can be very difficult to identify the border. Furthermore, in the instance of intraoperative bowel injury, longer bowel segments might need to be sacrificed, and this, accordingly, increases operative time and blood loss. Therefore, the use of adhesion barriers that avoid the development of these adhesions would reduce the operative time and blood loss associated with longer surgeries. The choice of material is also important: INTERCEED is suitable for insertion into deep and narrow spaces because it is soft and malleable; a sticky and fragile material, for example, would be far less appropriate, as it would be difficult to place correctly.

Adhesions begin forming at the time of surgery and continue until 5 days after surgery.<sup>26–28</sup> INTERCEED forms a gel-like membrane 24 hours after application and covers the target site with a gelatinous material for 7 to 10 days. The material is completely absorbed within 4 weeks.<sup>29</sup> Unlike with intra-abdominal procedures, the stomal limbs continue to make contact with the rectus abdominis muscles after the material is absorbed. In the present study, the duration between the initial surgery and ileostomy closure tended to be longer in the No INTERCEED group than in the INTERCEED group. Theoretically, new adhesion formation would not occur after postoperative day 7,<sup>27,28</sup> therefore, a longer time to ileostomy closure should not affect the degree of adhesion formation between the stomal limbs and the rectus abdominis muscles.

One important strength of the present study was that ileostomy creation and reversal were performed by only one surgeon, which allowed for an accurate assessment of operation times between the two groups. Operation times and surgical outcomes will vary depending on technique, experience, and other preferences of the surgeon. There were also several limitations in the present study. First, this was a retrospective, single-institutional study with a small number of patients. The sample size of the study was too small to draw a definite conclusion; therefore, further research, such as a randomized controlled trial, is needed to confirm the present results. Second, because of the retrospective design of our study, the degree of adhesion between the ileal limbs and subcutaneous tissues was not scored. In the aforementioned studies, adhesion scores were significantly different between patients treated with and without adhesion bar-

riers. However, in many of these studies, improvement in adhesion scores following the use of absorbable barriers did not necessarily correlate with improved perioperative outcomes, including operative time and intraoperative blood loss.<sup>4,6,7</sup> Quantification of the degree of adhesion is difficult and highly subjective. An evaluation and improvement in the objective parameters for measuring adhesion might be more practical for clinical applications and is warranted in future studies examining the beneficial use of INTERCEED. Furthermore, we found that the operative time of the initial surgery tended to be longer in the No INTERCEED group than in the INTERCEED group. A longer operative time is reported to be associated with the formation of adhesion.<sup>30</sup> Therefore, patients in the No INTERCEED group might have more intra-abdominal adhesions. These differences between the groups might have affected the observed outcomes and should be measured in future studies.

## Conclusion

The present results show the potential clinical utility of INTERCEED for better outcomes among patients requiring ileostomy reversal. We believe that insertion of the INTERCEED absorbable adhesion barrier between the stomal limbs and the rectus abdominis muscle can contribute to improved operative outcomes among patients treated with temporary diverting ileostomy. Although the characteristics of INTERCEED are optimal for this purpose, the present concept may also be applied to the use of other absorbable adhesion barriers. Further studies with a larger cohort and additional quantitative measures are required.

### Contributions to the Submitted Work

Nagasaki T. designed the study and analyzed the data. All coauthors substantially contributed to the present study and fulfilled the requirements for authorship according to the guidelines of the International Committee of Medical Journal Editors.

### Ethics

Approval code issued by the institutional review board; protocol no. 2020-GA-1051

### Funding

The authors received no specific funding for the present article.

### Conflict of Interests

The author and coauthors have received lecture fees from Johnson & Johnson, outside the submitted work.

### Acknowledgments

The authors have no acknowledgments to declare.

## References

- 1 Akiyoshi T, Ueno M, Fukunaga Y, et al. Incidence of and risk factors for anastomotic leakage after laparoscopic anterior resection with

- intracorporeal rectal transection and double-stapling technique anastomosis for rectal cancer. *Am J Surg* 2011;202(03):259–264. Doi: 10.1016/j.amjsurg.2010.11.014
- 2 Matthiessen P, Hallböök O, Rutegård J, Simert G, Sjö Dahl R. Defunctioning stoma reduces symptomatic anastomotic leakage after low anterior resection of the rectum for cancer: a randomized multicenter trial. *Ann Surg* 2007;246(02):207–214. Doi: 10.1097/SLA.0b013e3180603024
  - 3 Schneider V, Lee LD, Stroux A, Buhr HJ, Ritz JP, Kreis ME, et al. Risk factors for reoperation after ileostomy reversal - Results from a prospective cohort study. *Int J Surg*. 2016;36(Pt A):233–9. Doi: 10.1016/j.ijssu.2016.10.043
  - 4 Tang CL, Seow-Choen F, Fook-Chong S, Eu KW. Bioresorbable adhesion barrier facilitates early closure of the defunctioning ileostomy after rectal excision: a prospective, randomized trial. *Dis Colon Rectum* 2003;46(09):1200–1207. Doi: 10.1007/s10350-004-6716-9
  - 5 Kusunoki M, Ikeuchi H, Yanagi H, et al. Bioresorbable hyaluronate-carboxymethylcellulose membrane (Seprafilm) in surgery for rectal carcinoma: a prospective randomized clinical trial. *Surg Today* 2005;35(11):940–945. Doi: 10.1007/s00595-005-3061-0
  - 6 Salum M, Wexner SD, Noguera JJ, et al; Program Directors Association in Colon and Rectal Surgery. Does sodium hyaluronate- and carboxymethylcellulose-based bioresorbable membrane (Seprafilm) decrease operative time for loop ileostomy closure? *Tech Coloproctol* 2006;10(03):187–190, discussion 190–191. Doi: 10.1007/s10151-006-0278-x
  - 7 Hu J, Fan D, Lin X, et al. Safety and Efficacy of Sodium Hyaluronate Gel and Chitosan in Preventing Postoperative Peristomal Adhesions After Defunctioning Enterostomy: A Prospective Randomized Controlled Trials. *Medicine (Baltimore)* 2015;94(51):e2354. Doi: 10.1097/md.0000000000002354
  - 8 Kawamura YJ, Kakizawa N, Tan KY, et al. Sushi-roll wrap of Seprafilm for ileostomy limbs facilitates ileostomy closure. *Tech Coloproctol* 2009;13(03):211–214. Doi: 10.1007/s10151-009-0504-4
  - 9 Hsu CW, Chang MC, Wang JH, Wu CC, Chen YH. Placement of SurgiWrap® adhesion barrier film around the protective loop stoma after laparoscopic colorectal cancer surgery may reduce the peristomal adhesion severity and facilitate the closure. *Int J Colorectal Dis* 2019;34(03):513–518. Doi: 10.1007/s00384-018-03229-3
  - 10 Tjandra JJ, Chan MK. A sprayable hydrogel adhesion barrier facilitates closure of defunctioning loop ileostomy: a randomized trial. *Dis Colon Rectum* 2008;51(06):956–960. Doi: 10.1007/s10350-007-9181-4
  - 11 Rajab TK, Kimonis KO, Ali E, Offodile AC II, Brady M, Bleday R. Practical implications of postoperative adhesions for preoperative consent and operative technique. *Int J Surg* 2013;11(09):753–756. Doi: 10.1016/j.ijssu.2013.07.019
  - 12 Nagasaki T, Akiyoshi T, Fujimoto Y, et al. Preoperative Chemoradiotherapy Might Improve the Prognosis of Patients with Locally Advanced Low Rectal Cancer and Lateral Pelvic Lymph Node Metastases. *World J Surg* 2017;41(03):876–883. Doi: 10.1007/s00268-016-3748-y
  - 13 Konishi T, Shinozaki E, Murofushi K, et al. Phase II Trial of Neoadjuvant Chemotherapy, Chemoradiotherapy, and Laparoscopic Surgery with Selective Lateral Node Dissection for Poor-Risk Low Rectal Cancer. *Ann Surg Oncol* 2019;26(08):2507–2513. Doi: 10.1245/s10434-019-07342-7
  - 14 Akiyoshi T, Kuroyanagi H, Oya M, et al. Safety of laparoscopic total mesorectal excision for low rectal cancer with preoperative chemoradiation therapy. *J Gastrointest Surg* 2009;13(03):521–525. Doi: 10.1007/s11605-008-0744-z
  - 15 Onaitis MW, Noone RB, Hartwig M, et al. Neoadjuvant chemoradiation for rectal cancer: analysis of clinical outcomes from a 13-year institutional experience. *Ann Surg* 2001;233(06):778–785. Doi: 10.1097/00000658-200106000-00007
  - 16 Garlipp B, Ptok H, Schmidt U, Meyer F, Gastinger I, Lippert H. Neoadjuvant chemoradiotherapy for rectal carcinoma: effects on anastomotic leak rate and postoperative bladder dysfunction after non-emergency sphincter-preserving anterior rectal resection. Results of the Quality Assurance in Rectal Cancer Surgery multicenter observational trial. *Langenbecks Arch Surg* 2010;395(08):1031–1038. Doi: 10.1007/s00423-010-0708-0
  - 17 Akiyoshi T, Fujimoto Y, Konishi T, et al. Complications of loop ileostomy closure in patients with rectal tumor. *World J Surg* 2010;34(08):1937–1942. Doi: 10.1007/s00268-010-0547-8
  - 18 Keller DS, Khorgami Z, Swendseid B, Khan S, Delaney CP. Identifying causes for high readmission rates after stoma reversal. *Surg Endosc* 2014;28(04):1263–1268. Doi: 10.1007/s00464-013-3320-x
  - 19 Chow A, Tilney HS, Paraskeva P, Jeyarajah S, Zacharakis E, Purkayastha S. The morbidity surrounding reversal of defunctioning ileostomies: a systematic review of 48 studies including 6,107 cases. *Int J Colorectal Dis* 2009;24(06):711–723. Doi: 10.1007/s00384-009-0660-z
  - 20 Sharma A, Deeb AP, Rickles AS, Iannuzzi JC, Monson JR, Fleming FJ. Closure of defunctioning loop ileostomy is associated with considerable morbidity. *Colorectal Dis* 2013;15(04):458–462. Doi: 10.1111/codi.12029
  - 21 Kaiser AM, Israelit S, Klaristenfeld D, et al. Morbidity of ostomy takedown. *J Gastrointest Surg* 2008;12(03):437–441. Doi: 10.1007/s11605-007-0457-8
  - 22 Man VC, Choi HK, Law WL, Foo DC. Morbidities after closure of ileostomy: analysis of risk factors. *Int J Colorectal Dis* 2016;31(01):51–57. Doi: 10.1007/s00384-015-2327-2
  - 23 Krebs B, Ivanecz A, Potrc S, Horvat M. Factors affecting the morbidity and mortality of diverting stoma closure: retrospective cohort analysis of twelve-year period. *Radiol Oncol* 2019;53(03):331–336. Doi: 10.2478/raon-2019-0037
  - 24 Mansfield SD, Jensen C, Phair AS, Kelly OT, Kelly SB. Complications of loop ileostomy closure: a retrospective cohort analysis of 123 patients. *World J Surg* 2008;32(09):2101–2106. Doi: 10.1007/s00268-008-9669-7
  - 25 Jeong WK, Park JW, Choi HS, Jeong SY, Oh JH. Comparison of peristomal adhesion formation between laparoscopic and open low anterior resection of rectal cancer. *World J Surg* 2013;37(11):2683–2687. Doi: 10.1007/s00268-013-2165-8
  - 26 Huang C, Ding DC. Outcomes of adhesion barriers in gynecologic surgeries: A retrospective study at a medical center. *Medicine (Baltimore)* 2019;98(50):e18391. Doi: 10.1097/md.00000000000018391
  - 27 Davey AK, Maher PJ. Surgical adhesions: a timely update, a great challenge for the future. *J Minim Invasive Gynecol* 2007;14(01):15–22. Doi: 10.1016/j.jmig.2006.07.013
  - 28 González-Quintero VH, Cruz-Pachano FE. Preventing adhesions in obstetric and gynecologic surgical procedures. *Rev Obstet Gynecol* 2009;2(01):38–45
  - 29 Naito M, Ogura N, Yamanashi T, et al. Prospective randomized controlled study on the validity and safety of an absorbable adhesion barrier (Interceed®) made of oxidized regenerated cellulose for laparoscopic colorectal surgery. *Asian J Endosc Surg* 2017;10(01):7–11. Doi: 10.1111/ases.12334
  - 30 Ordoñez JL, Domínguez J, Evrard V, Koninckx PR. The effect of training and duration of surgery on adhesion formation in the rabbit model. *Hum Reprod* 1997;12(12):2654–2657. Doi: 10.1093/humrep/12.12.2654